

INTEREST OF DERMOSCOPY FOR THE DIAGNOSIS OF ONYCHOMYCOSES IN INFANTS

Comment [Dsp1]: I'm not sure what you're referring to when you say "onychopathy". It's possible that you may have misspelled the term. Pls confirm first. I think it might be onychopathy.

Comment [Dsp2]: Align it properly

Abstract:

Aim: Onychomycosis is a rare pathology in infants which constitutes 15.5% of onychodystrophies in children, especially those with Down syndrome and the immunocompromised. Dermoscopy is an innocuous examination allowing to guide the clinical diagnosis and to avoid invasive examinations.

Presentation of Case: 5-month-old infant presents with thickening of the thumb nail of the left hand with xanthonychia evolving for 20 days without notion of trauma, or thumb sucking. On clinical examination, xantho-pachyonychia of the thumb nail of the left hand was noted reaching the latero-distal part with subungual hyperkeratosis and peronychia. Dermoscopy showed yellowish chromonychia, longitudinal striae, subungual hyperkeratosis with jagged edges. The mycological direct examination and culture was in favor of a candida

albicans infection. The patient was put on an antifungal cream with improvement after 3 months.

Discussion: The rarity of onychomycosis in infants can be attributed to several factors such as the difference in the structure of the nail plate, less exposure to trauma, rapidity of nail regrowth and absence of circulatory disorders.² The average age is 8 months, the sex ratio at 0.98 and the preferential location is the fingernails. Clinically the nail involvement is of the disto-lateral type with subungual hyperkeratosis and peronychia.⁴ Dermoscopy is a quick tool showing chromonychia, longitudinal streaks, subungual hyperkeratosis producing a "ruined appearance", distal onycholysis with jagged edges and linear hemorrhages.⁵ Infant onychomycosis is most often of candidal origin (*C. Albicans*).⁶ Topical antifungals (ciclopirox) are preferred.

Conclusion: This case is being reported to highlight the important role of dermoscopy in the diagnosis of onychomycosis and thus prevent unnecessary biopsies.

Keywords: infant; Onychomycosis, dermoscopy

Comment [Dsp3]: Make it justify alignment. Remove textbox you have been added under the titled "Aim". No references should be cited in this part. Total 4-8 keywords should be added.

Introduction

Onychomycosis occurred as age-related infections. It is a rare pathology in infants (incidence less than 0.3%) and which constitutes 15.5% of onychodystrophies in children, especially those with Down syndrome and the immunocompromised.¹ The differential diagnosis arises with psoriasis, atopic dermatitis, lichen planus, ichthyosis...

We are going to study the epidemiological characteristics of infant onychomycosis as well as the help of dermoscopy for the diagnosis

throughaclinical case.

Comment [Dsp4]: It should be mention on new page

Comment [Dsp5]: Add more information about the subject to which you have focused on.

Case report

5-month-old infant, with no particular personal history with notion of onychomycosis in the father, who presents with thickening of the thumbnail of the left hand with xanthonychia evolving for 20 days without notion of trauma, or thumb sucking.

Comment [Dsp6]: Pls construct it properly

On clinical examination, xantho-pachyonychia of the thumbnail of the left hand was noted reaching the latero-distal part with subungual hyperkeratosis and peronyxis (figure 1). No involvement of the other nails of the hands and feet, no mucosal lesions and the rest of the general examination was unremarkable.

Dermoscopy showed yellowish chromonychia, longitudinal striae, subungual hyperkeratosis with jagged edges (figure 2 and 3). The mycological sample with direct examination and culture was in favor of a candida albicans infection >50 colonies. The patient was put on an antifungal cream (ciclopirox olamine) with improvement after 3 months of treatment. (figure 4).

Comment [Dsp7]: Make it italics and sentence case

Comment [Dsp8]: Explain the case report properly

Discussion

Onychomycosis in infants is considered rare until now. This rarity can be attributed to several factors such as the difference in the structure of the nail plate, less exposure to trauma, the rapidity of nail regrowth and the absence of circulatory disorders.²

The contributing factors are difficult to determine: finger sucking, exogenous contamination from parents, endogenous contamination from another infected site such as the skin, etc.³ The average age is 8 months (1 month—1 year), the sex ratio at 0.98, the preferential location is the fingernails with possible simultaneous involvement of several fingers or toes. Clinically the nail involvement is of the disto-lateral type with subungual hyperkeratosis and peronyxis.⁴

Dermoscopy is a quick and easy tool showing chromonychia in all patients (100% yellowish), longitudinal streaks, subungual hyperkeratosis producing a "ruined appearance", distal onycholysis with jagged edges and linear hemorrhages.⁵

Infant onychomycosis is most often of candidal origin (*C. Albicans*) while dermatophyte onychomycosis (*T. rubrum* ++, *T. violaceum* ++) predominates in children aged 1-14 years.⁶ It is advisable to systematically search for a source of infection, in particular ringworm, interdigito-plantar involvement, familial dermatomycosis, etc.

Comment [Dsp9]: Must be in italics

Comment [Dsp10]: Make it italics

Comment [Dsp11]: Make it italics

Systemic antifungals only have Marketing Authorization from the age of 16, topical antifungals (ciclopirox) are preferred. A therapeutic abstention is possible given the faster growth of the nail.⁷

Conclusion

Infant onychomycosis is rare but with a markedly increasing prevalence. It is imperative to search for the source of infection and mycological confirmation allow early and adequate treatment.

Comment [Dsp12]: Font size must be similar to other text

Consent statement: The parents gave informed consent prior to their son's inclusion in the case report.

Ethical approval: The authors have obtained all necessary ethical approval from suitable Institutional or National or International Committee

References:

1. M. Larif¹, W. Saidi¹, A. Fathallah², A. Aounallah¹, A. Zaouali¹, L. Boussafara¹, N. Ghariani¹, M. Denguezli¹, C. Belajouza¹, R. Noura¹ Les onychomycoses chez les nourrissons de moins d'1 an (18 cas) *Annales de Dermatologie et de Vénérologie*

Volume 141, Issue 12, Supplement, December 2014, Pages S337-S338 <https://doi.org/10.1016/j.annder.2014.09.258>

Comment [DSp13]: List the first six authors followed by et al.

2. Nikolaos Kaparos, Sarah Norrenberg, Mahdi Al-Dhafiri, Stéphanie Christen-Zaech *Altérations unguéales de l'enfant. Revue médicale Suisse* 28 mars 2018; 600, *Dermatologie* <https://doi.org/10.53738/REVMED.2018.14.600.0676>

3. Daniela A Alfaro S¹, Carmen G González F² .Pediatric onychomycosis: Update and management] *Rev Chil Pediatr.* 2020 Feb; 91(1):131-138. <https://doi.org/10.32641/rchped.v91i1.1309>. Epub 2019 Dec 3

4. Martha Patricia Solís-Arias¹, María Teresa García-Romero¹ Onychomycosis in children. A review. *Int J Dermatol.* 2017 Feb; 56(2):123-130. <https://doi.org/10.1111/ijd.13392>

5. Manasa Narayan Kayarkatte¹, Archana Singal¹, Deepika Pandhi¹, Shukla Das², Sonal Sharma³. Nail dermoscopy (onychoscopia) findings in the diagnosis of primary onychomycosis: A cross-sectional study. *Indian J Dermatol Venereol Leprol.* 2020 Jul-Aug; 86(4):341-349. https://doi.org/10.4103/ijdv.IJDVL_100_19.

6. Sif Vestergaard-Jensen, Abdullah Mansouri MD, Lise Heilmann Jensen MD, Gregor B. E. Jemec MD, DrMedSci, Ditte Marie L. Saunte MD, PhD. Systematic review of the prevalence of onychomycosis in children. *Pediatric dermatology* Volume 39, Issue 6 November/December 2022. <https://doi.org/10.1111/pde.15100>

7. Aditya K Gupta^{1,2}, Maanasa Venkataraman², Neil H Shear^{1,3}, Vincent Piguet^{1,4}. Onychomycosis in children - review on treatment and management strategies. *Dermatol Treat.* 2022 May; 33(3):1213-1224. <https://doi.org/10.1080/09546634.2020.1810607>

Figures:

Figure 1: xantho-pachyonychia of the thumbnail of the left hand reaching the latero-distal part with subungual hyperkeratosis and peronyxis

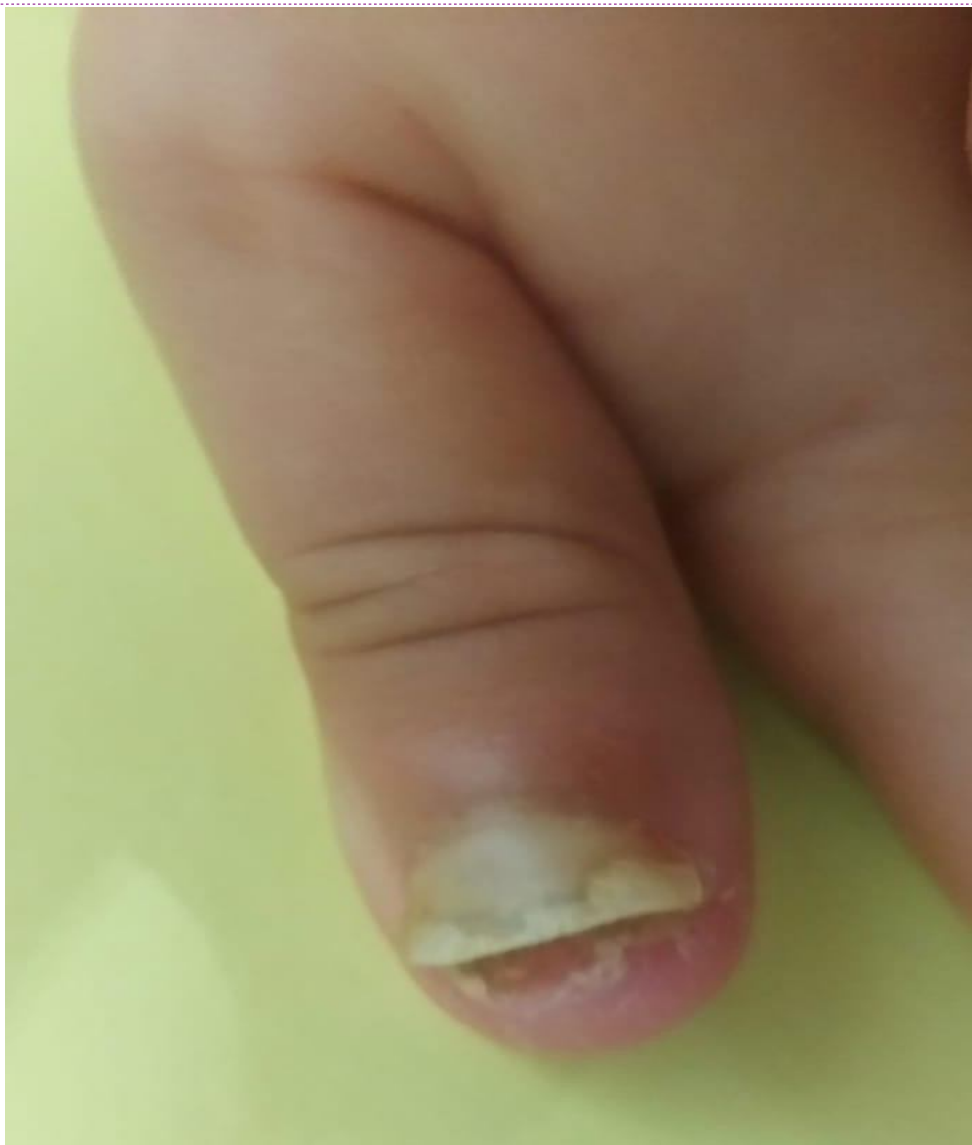Figure 2: Dermoscopy showed yellowish chromonychia with longitudinal

striae **Figure 3:** Dermoscopy showed subungual hyperkeratosis with jagged

edges **Figure 4:** improvement after 3 months of treatment

Figures:

Figure 1 :xantho-pachyonychia of the thumbnail of the left hand reaching the latero-distal partwithsubungualhyperkeratosisandperonyxis



Comment [Dsp14]: All theTables& figures should be placed inside the text. Tables and figures should be presented as per their appearance in the text

Figure 2: Dermoscopy showed yellowish chromonychia with longitudinal striae

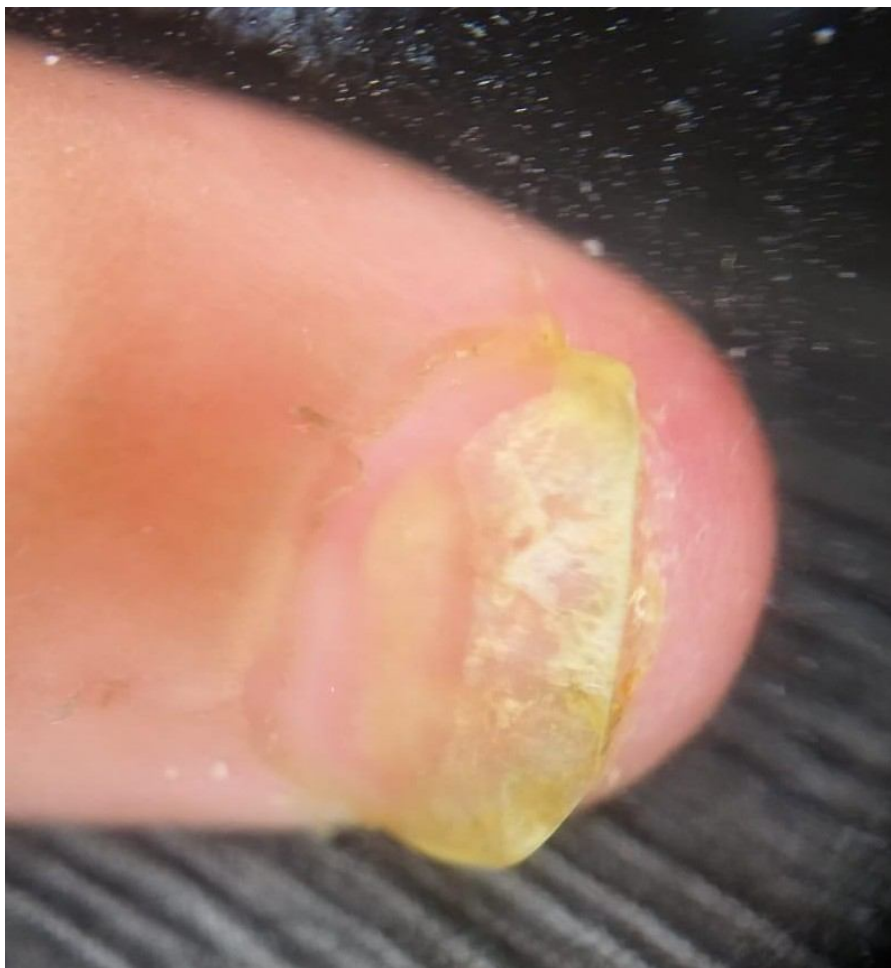

Figure 3: Dermoscopy showed subungual hyperkeratosis with jagged edges

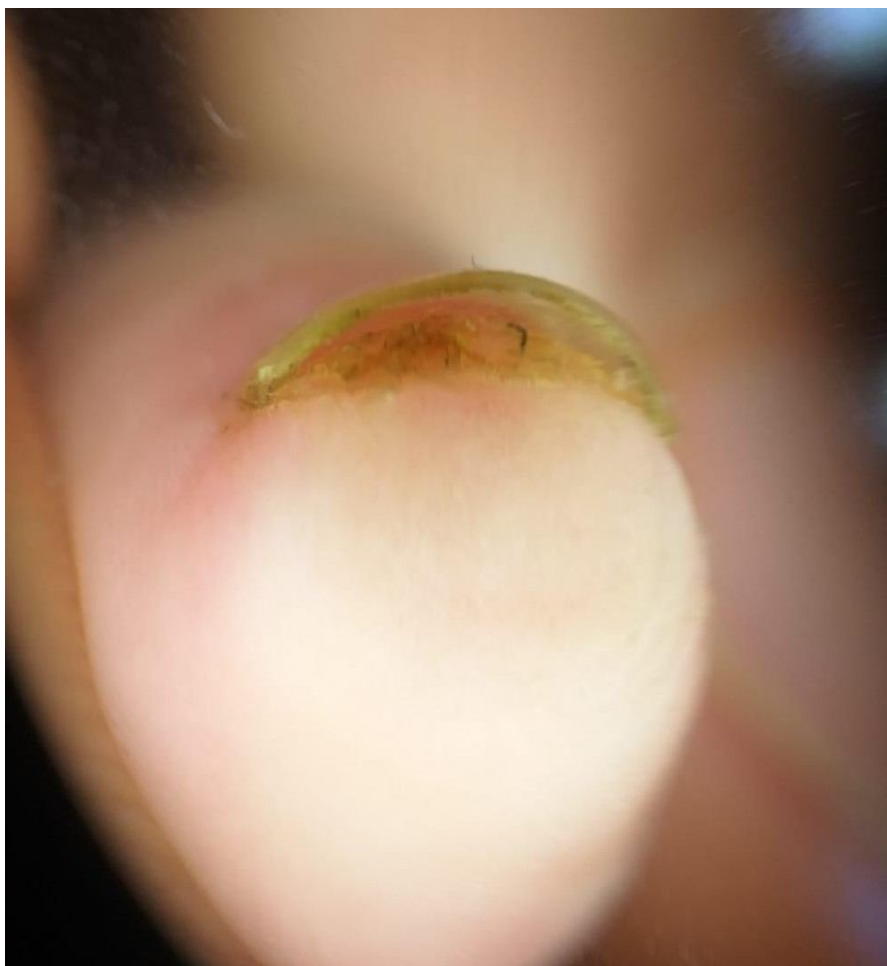
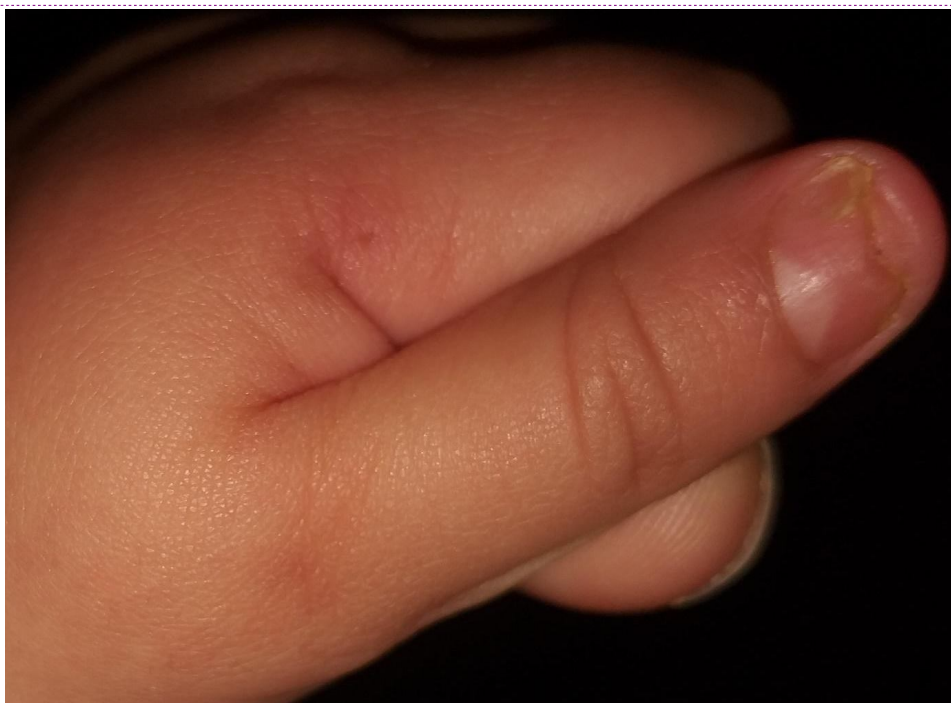

Figure4:improvementafter3monthsoftreatment



Comment [Dsp15]: Write the whole manuscript in proper margin and justify alignment