

Transposition of abdominal inferior vena cava to the left: A rare case report

ABSTRACT

Development of the vascular system in humans is a complex process that involves formation, retention, regression, and reconnection of primitive vascular channels, ultimately forming a definite pattern of the venous vascular architecture. Any errors in these processes would lead to anomalous venous structures, which would pose severe diagnostic and therapeutic challenges. Herein, we report a case of left-sided inferior vena cava (IVC) that was noticed in the posterior abdominal wall of a male cadaver aged about 80 years. Although venous anomalies are common in their occurrence, a left-sided transposition of inferior vena cava (IVC) considered to be a rare and significant finding in retroperitoneal surgeries because this can be misdiagnosed as para-aortic lymphadenopathy, a tumor or dilated gonadal vein that may result in iatrogenic damage during surgeries. The unusual location and course of the inferior vena cava and its embryological basis are discussed in this case.

Keywords: left-sided inferior vena cava; venous transposition; venous anomalies; inferior vena cava clinical implications

INTRODUCTION

The inferior vena cava (IVC) is a large vein normally located on the right side of vertebral column beside the aorta on its left. It is formed at the level of L₄ vertebrae by the union of the two common iliac veins¹. The formation of IVC is a complex process that involves the vitelline vein, supracardinal, subcardinal, and posterior cardinal veins for its definitive and uniform morphological existence. ~~Occurrence~~—The occurrence of the left-sided IVC is

Comment [A1]: Why isn't the exact age known for the individual?

Comment [A2]: Acronyms should not be used in an abstract.

considered to be ~~the~~second most common anomaly after duplicated IVC². These infrequent variations of IVC, which are incidentally found during diagnostic interventions may not stand solitary but may tend to show some associated variation in other vascular channels, ~~such as~~ ~~like~~ ovarian or testicular (~~gonadal~~), suprarenal, and renal venous channels, respectively³. Thorough assessment of structural anomalies, ~~such as~~ ~~like~~ transposition of ~~the~~ IVC, need to be understood from ~~point of~~ prophylactic, diagnostic, and therapeutic standpoints. This case ~~presentation reports~~ ~~report involved~~ a left-sided transposition of ~~the~~ IVC, found during routine anatomy dissection sessions.

CASE DESCRIPTION

During the routine dissection of the posterior abdominal wall contents in a male cadaver aged ~~about 80 years~~, we noticed an IVC located on the left side of the abdominal aorta (AA) possessing all the tributaries in its regular anatomical pattern (**Fig1**). ~~Upo~~ ~~On~~ further examination, it was found that the IVC was showing a disposition to the left just below the origin of the superior mesenteric artery, ~~which~~ later continued ascending further on crossing the ~~abdominal aorta~~ AA with an infrahepatic part of its course followed by retrohepatic location. ~~The left-sided IVC and~~ finally entered ~~ed~~ the thorax at the level of 8th thoracic vertebrae through the vena caval opening of the diaphragm. No other gross anomalies were noted in this case.

Comment [A3]: Please see earlier comment in the abstract.

DISCUSSION

Normal development of the IVC occurs between the sixth to tenth weeks of gestation⁴. This is the period during which all the anomalies of IVC are expected to take place. The embryogenesis of the human circulatory system is regulated by many molecular signalling

pathways and genes. Studies reported that the mutations in these genes, particularly *TIE3* gene mutations might cause venous channel malformations⁵. Embryologically, IVC is formed by the right supracardinal vein. In the case of left-sided IVC as seen in our case, the left supracardinal vein persists and the right supracardinal vein regresses. In cases of its failure in regression left supracardinal vein regression failure can lead to the retention of another parallel segment of the venous channel giving gives the an appearance of IVC duplication of the inferior vena cava in the posterior abdominal wall. In our case, it was showing a left-sided IVC was found lying beside the AA abdominal aorta without duplicating any remanent channel on the right side. Hence no duplication pattern was found.

Caval anomalies are sporadic, often they are incidental findings of radiological investigations. A rare case of left-sided IVC was encountered during the post-mortem study of a 36-year-old woman, who died due to accidental trauma. The IVC was showing its unusual origin from the point of confluence of the right and left iliac veins on the left side of the abdominal aortaAA. IVC possessed its regular tributaries like right and left renal veins. Later The IVC also showed was showing its contralateral course exactly at the point of drainage of its left renal tributary, and its further course was lying in the infrahepatic or supra renal region of the posterior abdominal wall. These findings are consistent with our present study findings encountered during cadaveric dissection². A systematic review conducted on left-sided IVC from 73 different studies revealed that the prevalence of IVC is as low as 0.1-0.4% showing a slight male preponderance⁶. Though these anomalies of IVC are rare and asymptomatic, deep vein thrombosis (DVT) is one of the most common associated risk factors which can be clinically correlated with the incidence of transposition of IVC. Its displacement and altered course may increase the susceptibility for thromboembolism due to undue compression of its venous channels⁷. It is also very important for surgeons to identify a left-sided IVC during complicated retroperitoneal surgical procedures such as abdominal

aortic aneurysm repair, left-sided nephrectomy, oblique lumbar fusion or IVC filter placement, and sigmoidectomy, respectively.^{8,9,10,11} However, these surgical complications of a left-sided IVC can be avoided with an accurate pre-operative evaluation of the retroperitoneal venous system using radiological interventions such as computed tomography (CT) or magnetic resonance imaging¹² (MRI).

CONCLUSION~~In conclusion,~~

Formatted: Centered

IVC anomalies are relatively less common when compared with superficial veins. It is very important to identify these eccentric anatomical variations from the perspective of clinical, diagnostic, and therapeutic standpoints to avoid fatal consequences in medical practice.

Permission:~~obtained~~ Obtained for cadaver dissection, presentation, and research.

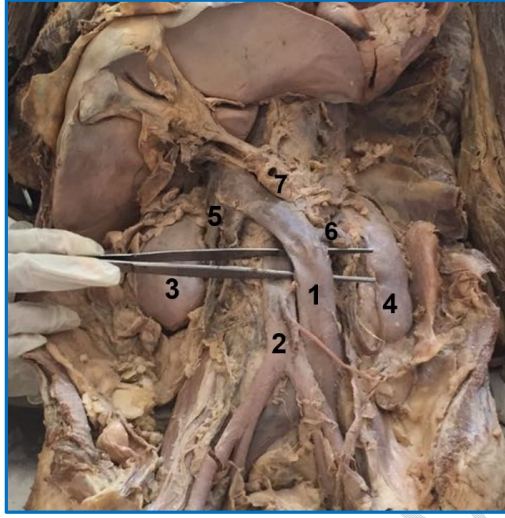
REFERENCES

1. Standring S (2016) Gray's anatomy: the anatomical basis of clinical practice. 41st ed. New York; Elsevier.
2. Rajabnejad Y, Aliakbarian M, Rajabnejad A, Motie MR (2016) Left sided inferior vena cava encountered during organ retrieval surgery: report of two cases. *Int J Organ Transplant Med*, 7:229-232.
3. Ghandour A, Partovi S, Karuppasamy K, Rajiah P (2016) Congenital anomalies of the IVC—embryological perspectives and clinical relevance. *CardiovascDiagnTher*, 6:482-492.
4. Giordano JM, Trout III HH (1986) Anomalies of the inferior vena cava. *J VascSurg*, 3:924-928.

5. Kim JS, Hwang SK, Chung HY (2020) The molecular pathophysiology of vascular anomalies: Genomic research. *Arch PlastSurg*, 47:203-208.
6. Ang WC, Doyle T, Stringer MD (2013) Left-sided and duplicate inferior vena cava: a case series and review. *Clin Anat*, 26:990-1001.
7. Zhang L, Guan WK (2021) Deep vein thrombosis in patient with left-sided inferior vena cava draining into the hemiazygos vein: A case report. *World J Clin Cases*, 9: 672-676.
8. Wu WK, Guth CM, Mulherin JL (2020) Abdominal aortic aneurysm repair requiring left-sided inferior vena cava interposition. *Ann VascSurg*, 68:573-575.
9. Wang LH, Liu B, Wu Z, Yang Q, Xiao L, Chen W, Sheng H, Luo W, Luo R, Sun Y (2011) Left transperitoneal laparoscopic partial nephrectomy in the presence of a left-sided inferior vena cava. *Urology*, 78:469-473.
10. Berry CA (2019) Oblique lumbar interbody fusion in patient with persistent left-sided inferior vena cava: case report and review of literature. *World Neurosurg*, 132:58-62.
11. Matsunaga M, Fukahori M, Ushijima T, Miwa K (2015) Left-sided inferior vena cava. *Case Reports*, 2015: bcr2015211268.
12. Li SJ, Lee J, Hall J, Sutherland TR (2021) The inferior vena cava: anatomical variants and acquired pathologies. *Insights Imaging*, 12: 123.

Figure legend:

Fig. 1.-Showing left-sided transposition of the inferior vena cava: 1: left-sided inferior vena cava; 2: abdominal aorta; 3: right kidney; 4: left kidney; 5: right renal vein; 6: left renal vein; 7: superior mesenteric artery.



UNDER PEER REVIEW

