

## Single-visit Apexification by Platelet-Rich Fibrin and Biodentin- A Case Report

**Abstract-** apexification procedure involves

### Abstract

Apexification is the procedure that involves the induction of the formation of an apical barrier. Nowadays, an artificial apical barrier is formed with the advancement of newer biomimetic and bioactive materials such as tricalcium phosphate, freeze-dried bone, freeze-dried dentin, and mineral trioxide aggregate (MTA). These treatment methods have succeeded in achieving more predictable, successful treatment outcomes. However, these are the materials that can lead to extruding from the apex and affecting the periapical tissue. An artificial barrier or matrix limits the material within the apex.

**Keywords-** Apexification, Platelet Rich Fibrin (PRF), Biodentin, open apex

### Introduction

Dental trauma during the root formation may lead to an incomplete root development which results in an open apex.<sup>1</sup> Dental traumatic injuries are responsible for 30% of necrosis of pulp in an immature permanent tooth. Dental injury results in the subsequent incomplete formation of the root apices.<sup>2</sup> It's challenging to treat teeth endodontically in the absence of natural apical constriction in nonvital immature permanent teeth.<sup>3</sup>

Traditionally, the treatment protocols of a nonvital immature young permanent tooth with an open apex were confined to leaving the canal untreated, cleaning and shaping the canal, custom fitting the filling material, short fill the canal, paste filling, and periapical surgery.<sup>3</sup> However, due to the limitations of these procedures apexogenesis and apexification were generated for the continued development of the apex.<sup>3</sup>

Apexification is the procedure to make the apical closure by the formation of mineralized tissue in the apical region in a non-vital young permanent tooth with an open apex.<sup>3</sup> In the past times, calcium hydroxide was the material of choice to form an apical barrier. In the limitation with prolonged treatment time and not properly formed apical barrier.<sup>3</sup>

“There are various materials have been used for the formation of hard tissue barriers as Mineral Trioxide Aggregate (MTA), Biodentine, Endosequence, etc”.<sup>4</sup> “there are certain drawbacks of MTA which has to prolong setting time, poor handling properties, and expensive”.<sup>4</sup>

“Biodentine is a calcium silicate-based cement. In this zirconium oxide has been added to the powder of Biodentine, which act as a setting accelerator and there is a water-reducing agent in the liquid. which reduces the setting time to 12 min and the compressive strength is also increased. Biodentine has good handling properties and superior push-out bond strength and is also used as a substitute for the repair of root perforations, apexification, and retrograde root-filling material”.<sup>5</sup>

“MTA is difficult to control during apexification which may lead to extruding from the apex. To overcome this limitation matrix material must be used. PRF as matrix material stimulates wound healing and repair. PRF is a second-generation platelet concentrate that is used as a resorbable matrix material after the apical barrier can be placed”.<sup>3</sup>

The aim of this report is to manage an immature open apex with a single-step apexification procedure with Biodentin and PRF.

### Presentation of Case

A 16-year-old male, visit the Department of conservative dentistry and endodontics, with the chief complaint of fracture in his upper front teeth in the past 6 years. And given history of trauma at the age of 10 years. No medical history was reported. On clinical examination, Ellis class II fracture irt 21. Teeth were non-tender on percussion irt 21(Figure 1.a). On vitality examination, teeth were nonvital.

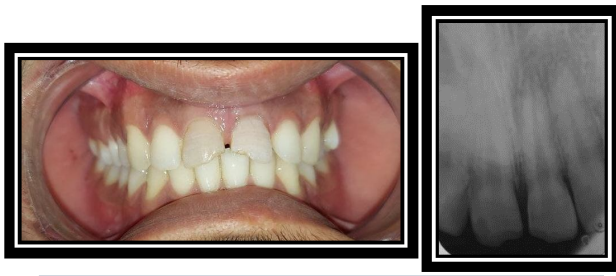

FIG.1 a. PREOPERATIVE IMAGE b. PREOPERATIVE RADIOGRAPH

On radiographic examination, periapical radiolucency was evident and open apex irt 21 [Figure 1.b].

The final diagnosis was made Ellis class II fracture and pulpal necrosis irt 21

The final treatment plan is one step apexification by PRF and Biodentin irt 21

In first appointment local anaesthesia was achieved than rubber dam was placed. An access cavity preparation was done with a high speed handpiece and round and tapered diamond burs irt 21. Then working length was determined using an apex locator (coltene), and Biomechanical preparation was done with a no. 80 k file. Canal was irrigated with 1% NaOCl followed by saline and final irrigation was done with 2% chlorhexidine. Then canal was dried with the absorbent paper point. Intracanal medicament(triple antibiotic paste) was placed for 1 week and the temporize the access cavity with cavit.

In second visit, the canal was irrigated with 1% NaOCl followed by saline and dried with absorbent paper points.

After that PRF membrane was prepared. Blood sample (8.5 ml) was taken by syringe and collected in a 10 ml sterile vial without anticoagulant and was centrifuged at 3000rpm for 10 min. After the centrifugation, the upper most layer was acellular platelet-poor plasma, PRF clot in the middle and red blood cells at the bottom [Figure 2]. The PRF was taken and placed on sterile gauze piece and placed into the canal using finger pluggers and compacted at the the apex level. [Figure 3.a].

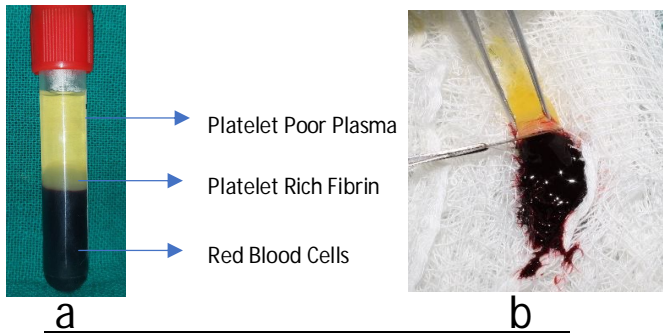


Fig.2 (a) & (b) PREPARATION OF PRF MEMBRANE

Biodentine was mixed according to the manufacturer's instructions and was placed and condensed using finger pluggers to achieve 5 mm apical plug [Figure 3. b].

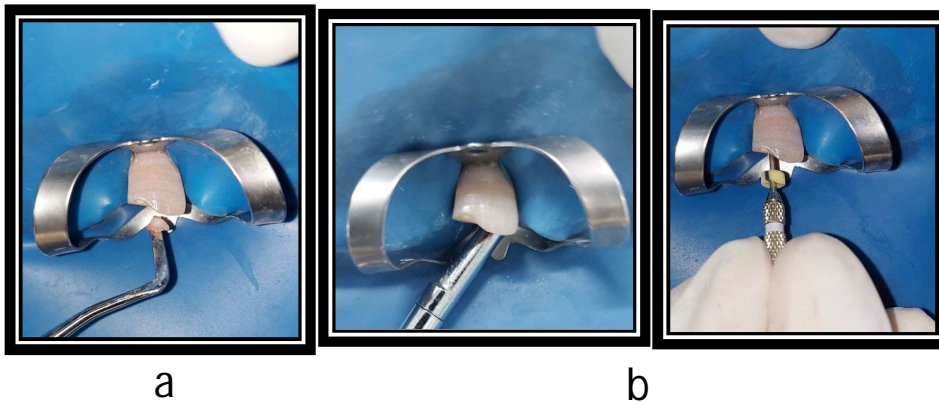
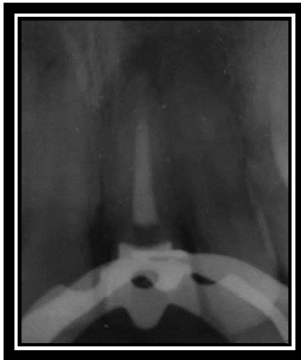

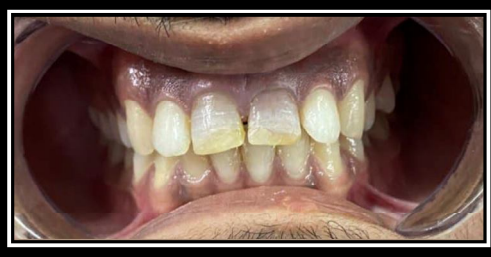Fig.3 a. PRF PLACEMENT

b. BIODENTIN PLACEMENT

After that, remaining canal was obturated by using thermoplasticized gutta-percha technique [Figure 4.a]. Post endodontic restoration and fracture was restored with composite restoration [Figure 4.b]. After 1 year radiograph showed complete healing of the lesion [Figure 5]



a



b

Fig 4

- a. OBTURATION BY THERMOPLASTISIZED GUTTA PERCHA
- b. POST-OPERATIVE IMAGE

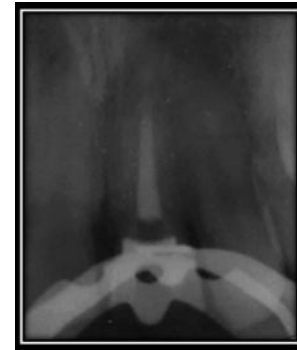

Fig 5 FOLLOW-UP AFTER 1 YEAR

## Discussion

“The management of an open apex consist of the formation of a natural or artificial apical barrier that can act as a stop for the obturating material”.<sup>4</sup> “The conventional apexification procedure is the induction of the formation of an apical barrier while the recent approach is to form an artificial apical barrier by the placement of an apical plug”.<sup>4</sup>

“Traditionally Calcium hydroxide was the material of choice for apexification. Studies have shown the 100% success rate using this technique. The mean time of the apical barrier formation is 12–19 months”.<sup>6</sup> limitations of this technique is long-term procedure and multiple appointment are required .Calcium hydroxide for longer time alters the intrinsic property of root canal dentine which can further lead to fracture.<sup>7</sup>

“There are various materials such as tricalcium phosphate, calcium hydroxide, freeze-dried bone, freeze-dried dentine, collagen calcium phosphate, and proplast are used for apexification”.<sup>3</sup> Biodentine, is the substitute of bioactive dentine which is based on “Active Biosilicate Technology”. “It has higher compressive strength, modulus of elasticity, and microhardness which are suitable with the natural dentine. It creates a tag-like crystalline structure within the dentinal tubules that forms the micromechanical bonding between dentin and calcium silicate material. In addition, it has less setting time, the completion of treatment on the same day is made possible unlike MTA, which requires a two-step technique”.<sup>5</sup> Biodentine induces mineralization by expressing markers of odontoblasts and it increases the secretion of transforming growth factor beta 1 from pulpal cells.<sup>8</sup>

The major problem in forming an artificial barrier at the apex is to limit the extrusion material beyond the apex, which may inhibit the repair of tissue.<sup>9</sup> there are various materials which are used as a matrix are calcium hydroxide, hydroxyapatite, resorbable collagen, and calcium sulphate. PRF is the platelet concentrate which is also used as a matrix.

PRF contains growth factors such as transforming growth factor-beta, vascular endothelial growth factor, and platelet-derived growth factor.

- To stimulates osteoblasts, gingival fibroblasts, and periodontal ligament cells proliferation
- Does not dissolve quickly after application

PRF has a soft consistency and moisture which act as a good matrix material. In this case, disinfection of the canal was done with sodium hypochlorite and chlorhexidine. Sodium hypochlorite is toxic, especially in higher concentrations. There are more chances of pushing the irrigant beyond the apex in open apex cases, therefore 1% sodium hypochlorite was used in this case. Further disinfection was achieved by using triple antibiotic paste.<sup>3</sup>

### **Conclusion**

Combination of PRF and Biodentin act as apical barrier for one-step apexification procedure with good success rate. Further, controlled clinical trials are needed to investigate the possible outcome of this technique. This innovative procedure is more predictable and less time-consuming with a high success rate and good patient compliance.

### **Consent**

As per international standard or university standard, parental(s) written consent has been collected and preserved by the author(s).

### **Ethical Approval:**

As per international standard or university standard written ethical approval has been collected and preserved by the author(s).

### **References**

1. Garg AJ., Shukla A., Kalaskar D., Thodsare H. Single Visit Apexification Using Mta: A Case Report. IJCSRR 2021; 04: 1193-1196.
2. Andreasen J.O., Bhask F. M., and Andersson L Eds., Textbook and Color Atlas of Traumatic Injuries to the Teeth, John Wiley & Sons, 2013.
3. Kumar A., Yadav A., Shetty N. One-step apexification using platelet-rich fibrin matrix and mineral trioxide aggregate apical barrier. Indi J Dent Rese 2014; 25: 809-812.
4. Dr Neha Joshi Tambake, Dr Sumit Tambake, Dr Deepak Metha, Dr Sayyed Mohammed Qadri, Dr Rohit Tambake, Dr Sejal Shinde Tambake. MTA Apexification: A case report. Int J of Allied Med Sci and Clin Res 2017; 5(2): 379-383.
5. Varghese VS, Uppin V, Kurian N. One-step apexification of blunderbass canal using biodentin. CHRISMED J Health Res 2017; 4:280-2.

6. Dominguez Reyes A, Muñoz Muñoz L, Aznar Martín T. Study of calcium hydroxide apexification in 26 young permanent incisors. *Dent Traumatol* 2005; 21:141-5.
7. Rafter M. Apexification: A review. *Dent Traumatol* 2005; 21:1-8
8. Khanduri N, Kurup D. Single-visit apexification with Biodentine and platelet-rich fibrin. *Endodontology* 2018; 30:181-3
9. Pradhan DP, Chawla HS, Gauba K, Goyal A. Comparative evaluation of endodontic management of teeth with unformed apices with mineral trioxide aggregate and calcium hydroxide. *J Dent Child (Chic)* 2006; 73:79-85.

