

# Primary Thyroid Tuberculosis: An Incidental Finding: Case Report

---

## ABSTRACT

Thyroid tuberculosis (TT) is a very rare condition, even in countries where tuberculosis is endemic. However, the global prevalence of tuberculosis has increased, and thyroid involvement can be a primary manifestation of the disease. The total number of such cases is about a hundred; most of them are autopsy findings. We present the case of a 60 years old female patient with primary thyroid tuberculosis who was managed with antitubercular drugs after left hemithyroidectomy and patient reported doing well after three months of medication. TT should be considered in the differential diagnosis of a thyroid nodule. Typical caseous necrotic granulomas are the hallmark in biopsy.

*Keywords: Thyroid nodule; Hemithyroidectomy; Thyroid tuberculosis (TT).*

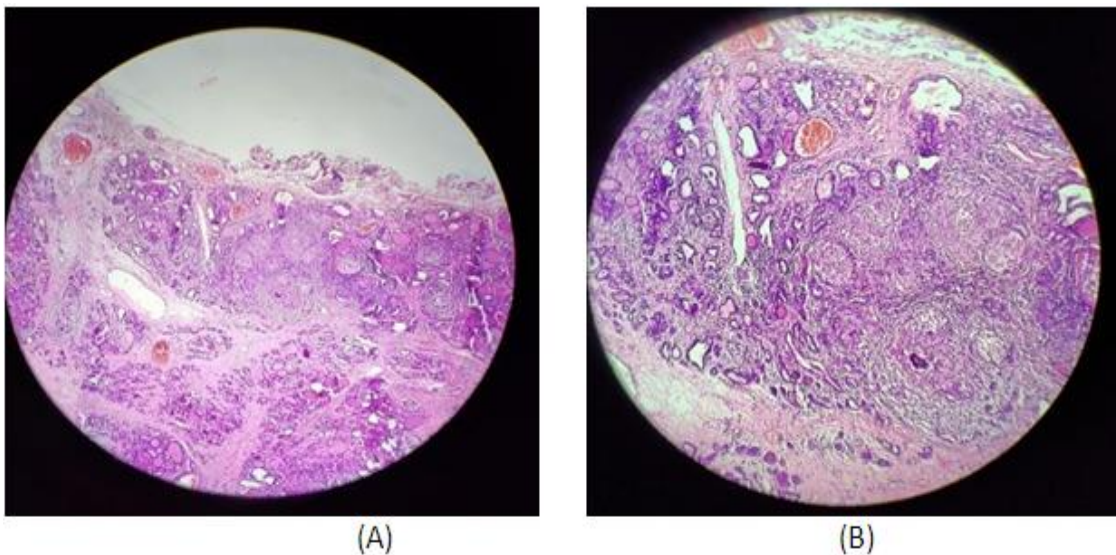
## 1. INTRODUCTION

"Tuberculosis of thyroid gland is extremely uncommon. The incidence of thyroid tuberculosis is low even in those countries where the prevalence of tuberculosis is high" [1]. "The supposed reasons for the relative immunity of thyroid gland from tuberculosis are the bactericidal attribute of the colloid, extensive vascularity and high iodine content of the gland" [2]. "Most of the cases are accompanied by other foci of the disease in the body elsewhere. Sometimes associated with regional lymph nodes, thyroid tuberculosis can mask a thyroid tumour, which poses diagnostic and therapeutic issues" [3]. "Tuberculosis of the thyroid gland assumes various forms, such as diffuse goitre, soft or hard nodule, painful and swollen thyroiditis, or an acute or cold abscess" [4].

## 2. CASE REPORT

A 60 years old woman presented to outpatient department with complaint of neck swelling on the left side since the last two years, which was sudden in onset and gradually progressive in size. Patient had history of breathing difficulty in lying down position for the last two weeks. There were no clinical findings of thyroid dysfunction; neither had she experienced fever or neck pain. General physical examination was unremarkable. On local examination swelling was present of

approximate size 4x3 cm on left side of neck with smooth surface, moving with deglutition & not moving with protrusion of tongue, skin over swelling was normal. On palpation firm swelling of size ~4x3 cm was present on left side of neck, non-tender, no cervical lymph nodes were palpable. Routine investigations and thyroid function tests were normal. Cervical ultrasonography showed left lobe thyroid to be bulky and showed heterogeneous lesion measuring 3.5x3.7cm in left lobe of thyroid with cystic changes and smooth margins (TIRADS-III). Right lobe was normal. Few cervical sub-centimetric lymph nodes were present. Fine-needle aspiration cytology (FNAC) was performed, obtaining colloid material which showed tiny clusters of epithelial cells with bare nuclei in the background of colloid, suggestive of colloid goitre. Patient underwent left hemithyroidectomy and histological findings were nodular goitre with extensive areas of haemorrhage. Surrounding thyroid tissue showed features of granulomatous thyroiditis. Zeihl Neelesen (ZN) staining for acid fast bacilli (AFB) with 20% H<sub>2</sub>SO<sub>4</sub> was positive (Fig.1a & 1b). Post-operatively contrast enhanced computed tomography (CECT) of neck & thorax was done to find out any evidence of pulmonary koch's but no evidence of pulmonary koch's was found (Fig. 2). Patient was put on anti-tubercular drugs and is doing well three months after surgery.



**Fig. 1. Microscopic image showing granulomatous changes (10x & 40x)**

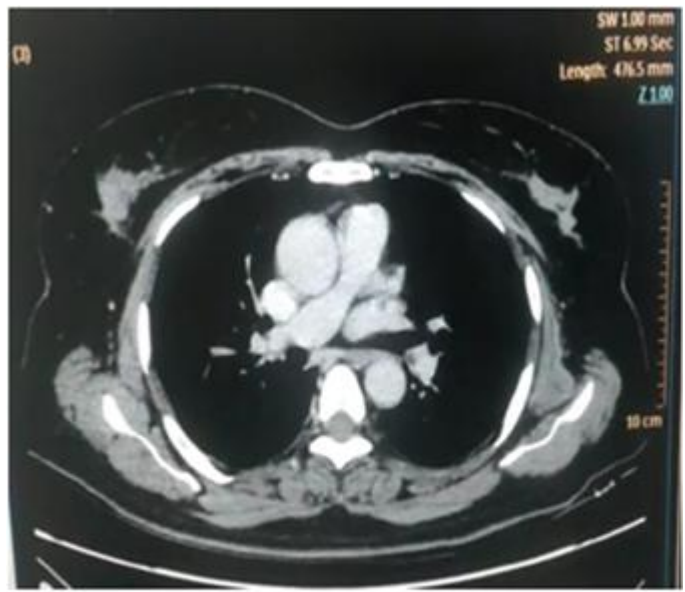
### 3. DISCUSSION

“It has been observed that primary or secondary form of thyroid gland tuberculosis is an extremely rare disease. According to various studies, its frequency is 0.1 to 0.4% in histologically diagnosed specimens. Middle-aged women are most frequently affected” [5]. Thyroid is resistant to infections because of colloid possessing bactericidal action [6]. The pathology of tubercular thyroiditis may be as follows: a) Multiple lesions throughout the gland like miliary tuberculosis; b) Enlargement of gland due to caseating granulomas; c) Cold abscess formation sometimes with multiple sinuses; d) Chronic fibrosing tuberculosis; e) Acute abscess formation [7]. Symptoms of thyroid tuberculosis are nonspecific and variable [8]. The patient may be asymptomatic or have symptoms of

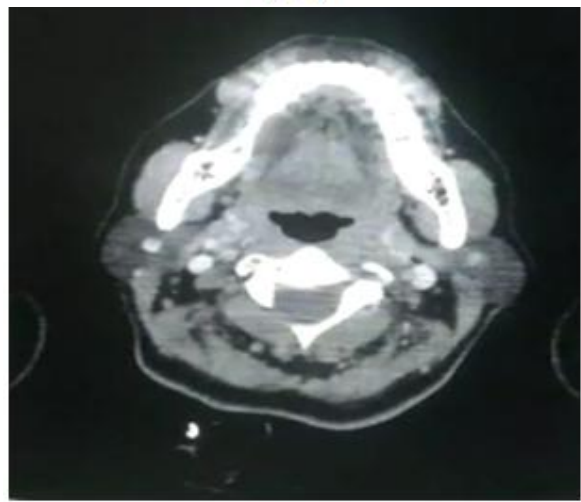
dysphonia, dysphagia, dyspnoea and rarely recurrent laryngeal nerve paralysis due to expanding gland [5]. Ultrasonographic and computed tomography (CT) findings can be helpful in making the diagnosis of tubercular thyroiditis. On ultrasonography heterogeneous hypoechoic mass is seen and on CT scan peripheral-enhancing low-density abscess with regional lymphadenopathy is demonstrated. Seed (1939) described three criteria for diagnosis of thyroid tuberculosis-1) Demonstration of acid fast bacilli within thyroid; 2) A necrosed or abscessed gland, and 3) Demonstration of tuberculous focus outside the gland. Histological and bacteriological confirmation is adequate to make diagnosis and fulfilment of third criteria is not essential [9]. In our case the diagnosis was made on histological examination (Fig. 1) and ZN staining. “Many

diseases may cause granulomatous inflammation in thyroid, like granulomatous thyroiditis, fungal infection, tuberculosis, sarcoidosis, granulomatous vasculitis, and foreign body reaction. However, caseating necrosis is characteristic feature of tuberculous inflammation" [10]. "Treatment of tubercular thyroiditis is complex and involves the administration of antituberculosis drugs combined with surgical removal of the affected parts of the thyroid gland or surgical drainage" [11]. "If tuberculosis is found in patients who have undergone subtotal or near-total thyroidectomy or thyroid lobectomy, an

antitubercular treatment for at least 6 months is administered, regardless of the presence of any additional foci" [12]. "Although there is a consensus on the medical treatment regimen, there is controversy as to which patients should be treated medically. Some suggest that a thyroidectomy alone is sufficient since primary TT is a localised disease, while others state that antitubercular treatment should be initiated. Failure to respond to anti-tubercular drugs and recurrence occur in around 1% of cases due to multi-drug resistance" [13]. In our case anti-tubercular drugs were started after left hemithyroidectomy.



(A)



(B)

Fig. 2. CECT images of thorax and neck

#### 4. CONCLUSION

Even though it is a rare condition, thyroid tuberculosis should be considered as a possible differential diagnosis when examining a thyroid nodule or abscess. The final diagnosis is determined by the specimen's histopathological examination. The treatment is mainly based on the anti-tubercular agents, but surgery or drainage sometimes required large abscess along with anti-tubercular drug therapy.

#### CONSENT

As per international standard or university standard, patient(s) written consent has been collected and preserved by the author(s).

#### ETHICAL APPROVAL

As per international standard or university standard written ethical approval has been collected and preserved by the author(s).

#### COMPETING INTERESTS

Authors have declared that no competing interests exist.

#### REFERENCES

1. Gupta R, Mohindroo NK, Azad R. Thyroid Tuberculosis: Yes, It is True. *Int J Head Neck Surg* 2015;6(4):193-194.
2. Zivaljevic V, Paunovic I, Diklic A. Tuberculosis of thyroid gland : A case report. *ActaChirBelg* 2007;107:70-72.
3. Rakotoarisoa AHN, Riel AM, Rakoto FA, Randriatahina PG, Razafimandimby T, Razafindrakoto HR, et al. Tuberculosis of the thyroid gland: A report of two cases. *Fr ORL* 2007; 92: 318-320.
4. Klassen KP, Curtis GM. Tuberculous abscess of the thyroid gland. *Surgery* 1945;17:552-559.
5. Abdulsalam F, Abdulaziz S, Mallik AA. Primary tuberculosis of the thyroid gland. *Kuwait Med J* 2005;37:116-118.
6. Gupta KB, Gupta R, Varma M. Tuberculosis of the thyroid gland. *Pulmonary* 2008;9:65-68.
7. Pandit AA, Joshi AS, Ogale SB, Sheode JH. Tuberculosis of thyroid gland. *Indian J Tub* 1997; 44: 205-207.
8. Mpikashe P, Sathekge MM, Mokgoro NP, Ogunbanjo GA. Tuberculosis of the thyroid gland: a case report: case study. *South African Family Practice*. 2004;46(7): 19-20.
9. Seed L. Goldberg's clinical tuberculosis. 2nd ed. Philadelphia (PA): F.A. Davis and Company; 1939.
10. Corton RS, Kumar V, Robbins SL. Robbin's pathological basis of disease. 5th ed. Philadelphia (PA): W.B. Saunders Company; 1994. p. 326, 382.
11. Terzidis K, Tourli P, Kiapekou E, Alevizaki M (2007) Thyroid tuberculosis. *Hormones (Athens)* 6(1):75–79.
12. Chacko A, Ajaykumar K, Geetha CG. 'Primary Thyroid Tuberculosis'—The Masquerader: A Case Report. *Indian Journal of Otolaryngology and Head & Neck Surgery*. 2021 Jul 7:1-4.
13. Anwar SL, Wahyono A, Dwianingsih EK, Avanti WS. Cold abscess as a primary manifestation of thyroid tuberculosis. *IDCases*. 2022;29.