

## Case report

### **Laparoscopic Lateral Pancreaticojejunostomy for Chronic Calcific Pancreatitis with Impacted Endoscopic Pancreatic duct stent for more than a decade: Double Trouble**

#### **Abstract**

**Aim :** To assess the feasibility and safety of Laparoscopic Lateral Pancreaticojejunostomy in a patient with impacted pancreatic duct stent which was retained for more than a decade.

**Presentation of case :** 62 year old male, known case of idiopathic chronic calcific pancreatitis with history of undergoing Endoscopic pancreatic duct stenting 12 years back presented with pain abdomen, steatorrhea , low grade fever and weight loss . A Contrast Enhanced Computerised Tomography scan done showed atrophic pancreas, dilated pancreatic duct, multiple stones along the pancreatic duct . An attempt to retrieve the stent by endoscopic approach was failed. In view of severe pain requiring escalating doses of analgesics and features of chronic pancreatitis he underwent totally laparoscopic lateral pancreaticojejunostomy with the retrieval of pancreatic duct stent. He was discharged on the 4<sup>th</sup> postoperative day . At 1 year follow up the patient is pain free and has also gained 9 kgs .

**Discussion:** Endoscopic pancreatic duct stenting provides relief from pain in severe chronic pancreatitis with ductal strictures and proximal dilatation. The stent needs to be exchanged frequently or on demand basis . Our patient underwent stent exchange twice and had lost for follow up for more than a decade. After extensive literature search ,we believe this is the first case report of totally laparoscopic lateral pancreaticojejunostomy performed in a patient with impacted and retained stent for more than a decade.

**Conclusion:** Laparoscopic lateral pancreaticojejunostomy for chronic calcific pancreatitis with retained ,impacted and infected previously placed endoscopic pancreatic duct stent is challenging, but safe and feasible in experienced hands.

**Keywords :** Laparoscopic Lateral Pancreaticojejunostomy , Impacted Pancreatic duct stent , Retained Pancreatic duct stent , Chronic Calcific Pancreatitis ,

## **INTRODUCTION**

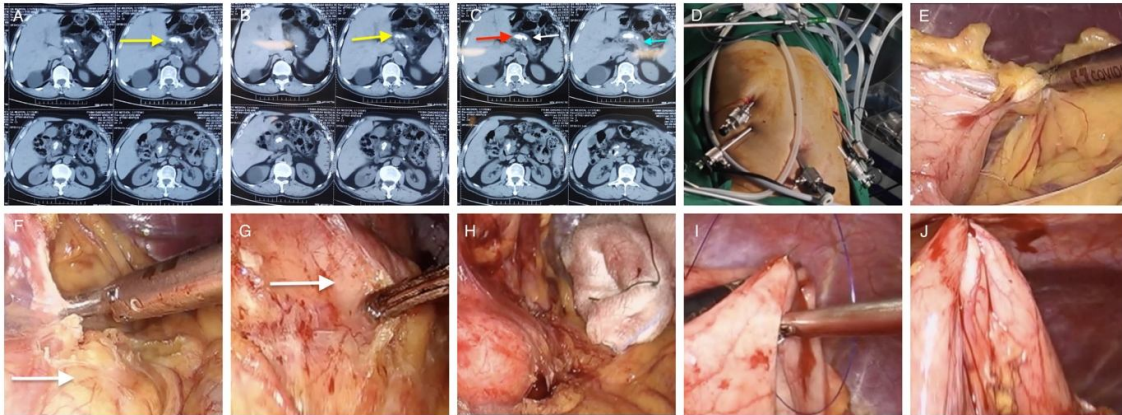
Chronic Pancreatitis (CP) is a inflammatory disease with relentless and progressive loss of pancreatic parenchymal tissue [1]It is characterized by recurrent abdominal pain and after recurrent attacks of pancreatitis ,exocrine and endocrine insufficiency appears [2].Although surgery was reported as superior to endotherapy for long term pain control in CP [3] ,endoscopic pancreatic duct (PD) stenting has been widely used as a primary treatment option for patients presenting with pain and ductal strictures[4]. Extracorporeal Shock Wave Lithotripsy(ESWL) and endoscopic lithotripsy are useful in fragmentation and extraction of PD stones [5].However the stones often recur for which treatment of Main PD stricture with stenting is required. This is believed to reduce the incidence of pain and recurrence of stones. The stent helps to drain the pancreatic juice and dilate the strictures of PD. However ,the PD stent needs to be exchanged every 3-6 months of its placement or “on demand basis” (Recurrent pain).[6] Impacted, infected and retained PD stent poses a major challenge during Lateral Pancreaticojejunostomy (LPJ) as there are high chances of bleeding , duodenal injury, and anastomotic leak leading to pancreatic fistula

## **PRESENTATION OF THE CASE**

62 year old male diabetic with history of undergoing endoscopic PD stenting 12 years back presented with recurrent pain abdomen , steatorrhea and weight loss since 1 year . He also had low grade fever since 1 month . There was no history of ethanol intake. He was a known case of Idiopathic CP. He had undergone stent exchange twice in 6 month interval. There was no significant pain abdomen requiring admission in the past 10 years. However from past 1 year he had pain abdomen requiring admission , injectable and oral analgesics for pain, steatorrhea and weight loss. There was no jaundice . Contrast Enhanced Computerised Tomography (CECT) of abdomen showed features of atrophic pancreas ,dilated Main PD with 8 mm diameter with multiple stones along the main PD. (Fig 1A,1B,1C ).His Liver function tests and Serum CA 19-9 were normal. An endoscopic attempt at removal of the stent failed . After complete preoperative evaluation he was planned for Laparoscopic LPJ. An informed consent was obtained from the patient.

## **OPERATIVE STEPS**

Under General anaesthesia with patient in leg split position , pneumoperitoneum was established with Verres technique . Ports placed as shown (Fig 1D). The lesser sac was widely opened by dividing the gastrocolic omentum by harmonic shears.(Fig 1E) All the gastro pancreatic adhesions were released.( Fig 1F) The borders of the pancreas was defined after dissecting the fatty tissues over it .(Fig 1G,1H) Gastric traction sutures were taken using interrupted 2-0 Polypropylene. (Fig 1I,1J )



**Figure 1**

A, B, C: CT scan showing stones in Main PD, Dilated duct, Atrophic pancreas (Yellow arrows: large stones in the head of pancreas, Red arrow : stones formed around the stent , white arrow : Atrophic pancreas , Blue arrow : Dilated MPD

D: Port positions (One 10 mm Camera port and Four 5 mm secondary ports)

E: Wide opening of lesser sac by dividing gastrocolic omentum

F: Releasing gastropancreatic attachments (White arrow: Note fatty replacement of pancreas)

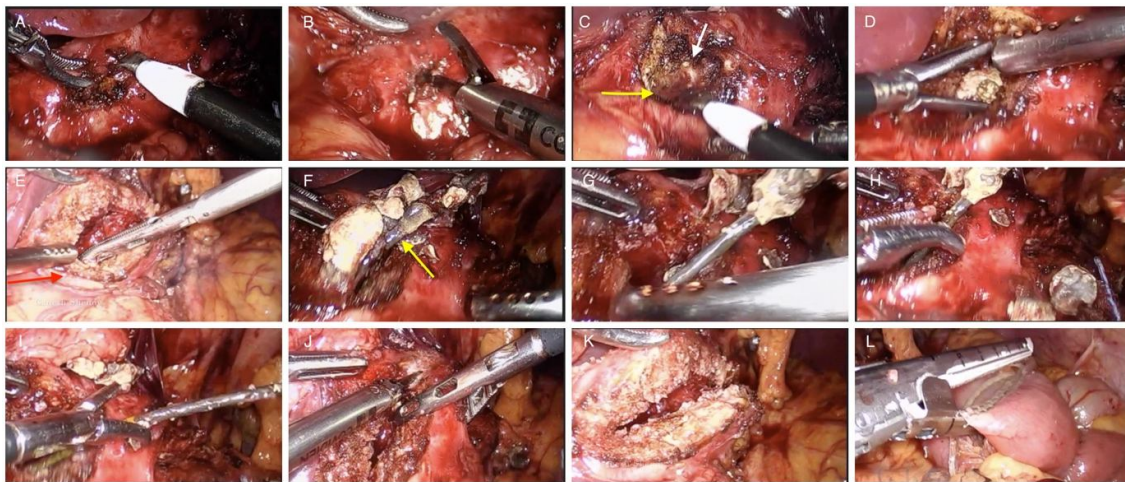
G: Dissection of fatty tissue over the pancreas

H: Borders of pancreas defined

I and J: Gastric traction sutures using polypropylene (Note the stomach fixed to abdominal wall)

The stones were palpated using an laparoscopic spatula as we did not have facility of Laparoscopic Ultrasound.(Fig 2A)The duct was also identified by aspiration using a needle The duct was opened initially near the head region .(Fig 2B) As soon as the duct was opened ,purulent fluid was drained suggesting infection due to the retained previously placed PD stent.(Fig 2C) The stones were retrieved from head region .(Fig 2D) The stent was found

impacted near the head of pancreas and it was not coming out by pulling out with a tooth grasper. Undue traction while pulling would have resulted in duodenal perforation or bleeding and hence decision taken to extend the incision on the head of pancreas. The incision on the head of pancreas was extended medially towards the second part of duodenum ( Fig 2E) and finally the stent along with the stones which were formed around it were extracted with difficulty.( Fig 2 F,2G,2H,2I). There was minimal bleeding during extraction which was controlled with bipolar diathermy. The duct was widely opened from head to tail of pancreas using harmonic shears and monopolar hook (Fig 2J,2K). All the stones were retrieved. The jejunum was divided 45 cm from duodenojejunal flexure using Endo GIA 60mm white cartridge. (Fig 2L)



**Figure 2**

A: Palpating stones using a spatula

B: Opening of pancreatic duct

C: Purulent fluid from pancreatic duct (Yellow arrow: fluid, White arrow: Pancreatic duct )

D: Extraction of stone from head region

E: Incision extended medially on head of pancreas to find the stent

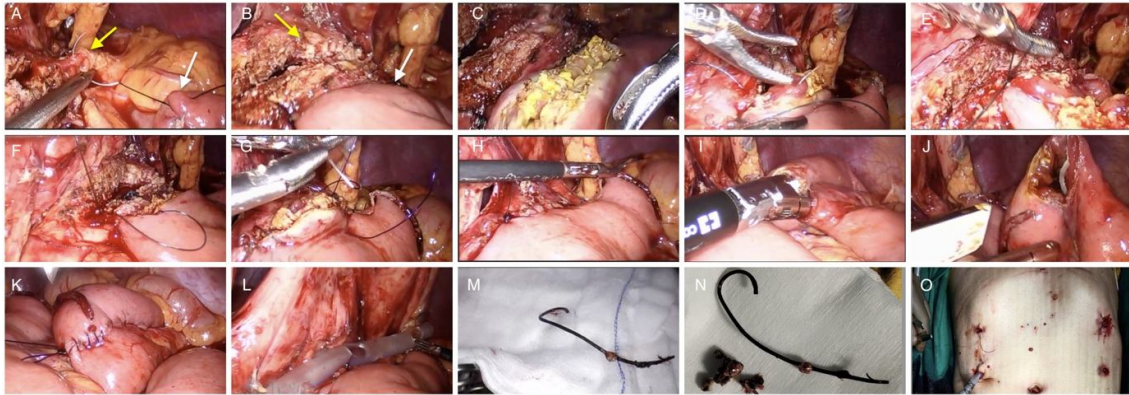
F, G, H, I: Retrieval of impacted stent along with stones (Yellow arrow: plastic stent)

J: Incision extended along the duct of pancreas

K: Duct opened from Head to tail of pancreas

L: Jejunum divided 45 cm from Duodenojejunal flexure using Endo GIA White cartridge

The Roux limb was fixed to the pancreas using interrupted 2-0 silk sutures.(Fig 3A,3B) Jejunotomy was performed using harmonic shears.(Fig 3C) An side to side LPJ was performed using continuous 2-0 Maxon sutures (Fig 3D,3E,3F,3G,3H) .Side to side jejunojenostomy was performed 45 cm from the LPJ using Endo GIA white stapler (Fig 3I, 3J).The enterotomy was closed with continuous 2-0 Polydioxanone (Fig 3K) An abdominal drain was placed in the lesser sac.( Fig 3L). The gastric traction sutures were released. All the stones and the stent were retrieved outside in an endobag( Fig 3M,3N). The operative time was 215 minutes.



**Figure 3**

A: Roux limb fixed to pancreas using 2-0 Silk sutures (White arrow: Roux limb, yellow arrow: Tail of pancreas)

B: Roux limb fixed to pancreas by interrupted silk sutures (White arrow: Roux limb, yellow arrow: Pancreas)

C: Jejunotomy

D, E, F: Side to Side Pancreaticojejunostomy ( Posterior layer using continuous 2-0 Maxon )

G: Anterior layer

H: Completed Lateral Pancreaticojejunostomy

I, J: Side to Side Jejunojenostomy using Endo GIA White cartridge

K: Enterotomy closed with continuous single layer 2-0 PDS

L: Drain placement

M: Retained plastic stent

N: Plastic stent and Pancreatic duct stones

O: Final scar and drain

The patient was started liquids orally on the 2nd postoperative day(POD) and on soft diet on the 4th POD. There was no evidence of pancreatic fistula after confirmation with serum

amylase and drain fluid amylase values. The patient was discharged on the 5th POD after drain removal .At 1 year follow up the patient is asymptomatic with no episodes of pain .He also gained 9 kgs of weight in one year period after the surgery.

## **DISCUSSION**

CP is an inflammatory disease leading to destruction of pancreatic parenchyma and ductal structures [7].It is characterized by persistent and often intolerable pain with weight loss and steatorrhea .The cause for pain is multifactorial .The most widely accepted mechanism is increased pancreatic ductal pressure, which may be secondary to outflow obstruction due to strictures, pancreatic intraductal stones, and/or compressing pseudocysts [8,9]

Endoscopic PD stenting provides relief from pain in severe CP with ductal strictures and proximal dilatation [10]).The technical success rate of Endoscopic PD stenting is 85%-98% and the symptom improvement rate is 65%-95 % [11]. Restenting may not be required if the patient is pain free after the removal of the stent and follow up scan shows no stricture of PD and all stones are cleared.

The reported complication rates associated with PD stents ranges from 4 to 10 % [12,13] These include stent migration, dislocation, fracture, bleeding , duodenal perforation , pancreatitis and occlusion leading to recurrent pancreatic obstruction. PD stent also induces anatomical changes in the pancreatic duct [14,15].Changes in Main PD morphology , consistent with CP have been reported after stent placement in 36-83% of patients [16,17].Periodic stent exchange is necessary because of stent deterioration, obstruction or due to above mentioned complications .

In our case the stent was retained by the patient for more than a decade. The patient was lost for follow up with medical gastroenterologist as he was pain free and had minimal requirement of analgesia. Since the past 1 year, he had recurrent episodes of pain requiring admission , increasing dose of analgesia , weight loss and steatorrhea. Attempt at endoscopic stent retrieval also failed as the stent was impacted and large stones were formed in the PD. Aggressive attempt at stent removal by endoscopic approach would have increased the rate of stent fracture, duodenal injury and bleeding. The patient was then referred to us for surgical management.

Since the patient had multiple large stones in PD and he was symptomatic for chronic pancreatitis ,a decision was taken for Laparoscopic LPJ . When the PD was opened near the head of pancreas, purulent fluid drained out and there were large stones obstructing the

PD. The stent was impacted and was not coming out easily in spite of applying pressure by a tooth grasper. We had to extend the incision on the head of pancreas medially towards the 2nd part of duodenum and with difficulty we could retrieve the stent along with stones which were formed around the stent.

Risk factors for failure of stent retrieval by endoscopic approach are distal duct stenosis, stent impaction, duct oedema, fragmentation and the type of stent used (pig tail, flapped stents) [18,19]. There are some case reports of endoscopic treatments for asymptomatic, non-complicated impacted PD stents after a follow up period of 2 years [20]. In a case report by Felipe Gonzalez et al [21] Laparoscopic Central Pancreatectomy and Pancreaticogastrostomy was performed for management of a proximally migrated PD stent after 3 months of placement when endoscopic retrieval was failed multiple times. Surgical options available in such cases include Trans duodenal ampullary approach, Pancreatotomy with reconstruction or resection procedures such as distal pancreatectomy or central pancreatectomy. Local anatomical factors, underlying indication for PD stent placement, patients age, comorbidities and location of retained stent within the pancreas will determine which surgical intervention is best for each patient.

In our case, the patient had symptoms of CP, with dilated main PD with stones and the stent was impacted at the head of pancreas we decided to do a drainage and reconstruction procedure with stent extraction. Parenchymal salvage was ideal due to diabetes and laparoscopic approach was considered due to its beneficiary effects compared to open counterpart and our experience in performing good numbers of LPJ and other pancreatic procedures by laparoscopic approach. Our patient clearly benefitted from a parenchymal sparing, minimal access approach to affect removal of the impacted stent and avoidance of complications of associated CP.

After extensive literature search, we believe this is the first report of totally laparoscopic LPJ performed in a patient with retained and impacted stent for more than a decade.

## **CONCLUSIONS**

Laparoscopic LPJ for Chronic Calcific Pancreatitis with retained, impacted and infected previously placed endoscopic pancreatic duct stent is challenging, but safe and feasible in experienced hands.

## REFERENCES

1. Kloppel G, Maillet B. The morphological basis for the evolution of acute pancreatitis into chronic pancreatitis. *Virchows Arch A Pathol Anat Histopathol* 1992;420:1–4.
2. Ammann RW, Akovbiantz A, Largiader F, Schueler G. Course and outcome of chronic pancreatitis. Longitudinal study of a mixed medical-surgical series of 245 patients. *Gastroenterology* 1984;86:820–8.
3. Dite P, Ruzicka M, Zboril V, Novotny I. A prospective, randomized trial comparing endoscopic and surgical therapy for chronic pancreatitis. *Endoscopy* 2003;35:553–8.
4. Binmoeller KF, Jue P, Seifert H, Nam WC, Izbicki J, Soehendra N. Endoscopic pancreatic stent drainage in chronic pancreatitis and a dominant stricture: long-term results. *Endoscopy* 1995;27: 638–44.
5. Naoki Sasahira, Minoru Tada, Hiroyuki Isayama, Kenji Hirano, Yousuke Nakai, Natsuyo Yamamoto, Takeshi Tsujino, Nobuo Toda, Yutaka Komatsu, Haruhiko Yoshida, Takao Kawabe, and Masao Omata **Outcomes after clearance of pancreatic stones with or without pancreatic stenting** *J Gastroenterol* 2007; 42:63–69  
DOI 10.1007/s00535-006-1972-1
6. Kondo, H. *et al.* Efficacy of pancreatic stenting prior to extracorporeal shock wave lithotripsy for pancreatic stones. *Dig. Liver Dis.* **46**, 639–644 (2014)
7. Majumder, S. & Chari, S. T. Chronic pancreatitis. *Lancet* **387**, 1957–1966 (2016).
8. Widdison AL, Alvarez C, Karanjia ND, Reber HA. Experimental evidence of beneficial effects of ductal decompression in chronic pancreatitis. *Endoscopy* 1991;23:151–4.

9. Bradley EL 3rd. Pancreatic duct pressure in chronic pancreatitis. *Am J Surg* 1982;144:313–6.
10. Binmoeller, K. F. *et al.* Endoscopic pancreatic stent drainage in chronic pancreatitis and a dominant stricture: long-term results. *Endoscopy* **27**, 638–644 (1995).
11. Dumonceau, J. M. *et al.* Endoscopic treatment of chronic pancreatitis: European Society of Gastrointestinal Endoscopy (ESGE) clinical guideline. *Endoscopy* **44**, 784–800 (2012).
12. B. Gong, B. Sun, L. X. Hao, and L. Bie, “Usefulness of an algorithm for endoscopic retrieval of proximally migrated 5Fr and 7Fr pancreatic stents,” *Hepatobiliary and Pancreatic Diseases International*, vol. 10, no. 2, pp. 196–200, 2011.
13. J. F. Johanson, M. J. Schmalz, and J. E. Geenen, “Incidence and risk factors for biliary and pancreatic stent migration,” *Gastrointestinal Endoscopy*, vol. 38, no. 3, pp. 341–346, 1992.
14. J. McCarthy, J. E. Geenen, and W. J. Hogan, “Preliminary experience with endoscopic stent placement in benign pancreatic diseases,” *Gastrointestinal Endoscopy*, vol. 34, no. 1, pp. 16–18, 1988.
15. S. D. Coleman, G. M. Eisen, A. B. Troughton, and P. B. Cotton, “Endoscopic treatment in the pancreas divisum,” *The American Journal of Gastroenterology*, vol. 89, no. 8, pp. 1152–1155, 1994.
16. Kozarek RA. Pancreatic stents can induce ductal changes consistent with chronic pancreatitis. *Gastrointest Endosc* 1990;36: 93-95
17. Pier Alberto Testoni Endoscopic pancreatic duct stent placement for inflammatory pancreatic diseases *World J Gastroenterol* 2007 December 7; 13(45): 5971-5978  
*World Journal of Gastroenterology* ISSN 1007-9327

18. Price LH, Brandabur JJ, Kozarek RA, Gluck M, Traverso WL, Irani S. Good stents gone bad: Endoscopic treatment of proximally migrated pancreatic duct stents. *Gastrointest Endosc.* 2009; 70(1):174-9. [PMID: 19559842].
19. Gong B, Sun B, Hao LX, Bie L. Usefulness of an algorithm for endoscopic retrieval of proximally migrated 5Fr and 7Fr pancreatic stents. *Hepatobiliary Pancreat Dis Int.* 2011; 10(2):196-200. [PMID: 21459728].
20. Lahoti S, Catalano MF, Geenen JE, Schmalz. Endoscopic retrieval of proximally migrated biliary and opancreatic stents: experience of a large referal center. *Gastrointest Endosc* 1998;50:124-5. [PMID: 9647373].
21. Felipe Gonzalez, Marc G Mesleh, Frank J Lukens, Michael B Wallace, Horacio J Asbun, John A Stauffer Laparoscopic Central Pancreatectomy and Pancreaticogastrostomy for the Management of a Proximally Migrated Pancreatic Stent *JOP. J Pancreas (Online)* 2013 May 10; 14(3):273-276.

UNDER PEER REVIEW