

Case study

Hodgkin lymphoma in an elderly rheumatoid patient on long term methotrexate therapy: A case report

Abstract:

Methotrexate associated lymphoproliferative disorders (MTX-LPD) are lymphomas that develop after administration of methotrexate (MTX). Here, we report a case of MTX-LPD in a 58-year-old female with rheumatoid arthritis (RA) who was on methotrexate for 10 years. She presented with complaint of cough for 1 month with no B symptoms. Chest and abdomen computed tomography showed hilar, mediastinal and abdominal lymphadenopathy. Biopsy and immunohistochemistry confirmed involvement with classical Hodgkin lymphoma. She was advised to stop methotrexate which resulted in complete regression of her lesions on PET CT within 1 month. For patients who are taking MTX for a long time, MTX associated LPD should be considered in the differential diagnosis in patients presenting with diffuse lymphadenopathy to avoid unnecessary treatment as many of these cases can be cured with discontinuation of methotrexate alone.

Keywords: methotrexate, Hodgkin lymphoma

Introduction:

Incidence of malignant lymphoma in patients with rheumatoid arthritis or other autoimmune diseases is higher, with many studies reporting 2-5.5 times higher prevalence in patients with RA than in healthy individuals (1-2).

Methotrexate (MTX), an antimetabolite and immunosuppressive drug, despite being highly effective in the treatment of rheumatoid arthritis, has been shown to be associated with serious adverse effects including myelosuppression, liver toxicity and interstitial pneumonia. MTX was the first drug found to be associated with lymphoproliferative disorder. Ellman et al. first reported lymphoma in a patient with RA treated with low dose MTX in 1991 (3). Since then, there have been various reports of benign or malignant lymphomas occurring after MTX administration; but few cases have been reported from India.

WHO categorizes immunodeficiency-associated LPD (IA-LPD) into 4 subclasses: LPD associated with primary immune disorders, lymphomas associated with HIV infection, post-transplant lymphoproliferative disorder (PTLD) and other iatrogenic immunodeficiency-associated lymphoproliferative disorder (OIIA-LPD). MTX-LPD falls under the OIIA-LPD class which typically develops in patients of autoimmune diseases receiving methotrexate and other biological immunosuppressive drugs like anti-TNF inhibitors (anti-tumour necrosis factor inhibitors). (4)

Pathogenesis of MTX-LPD is still uncertain and appears to be multifactorial and related to the hyperimmune state in RA, chronic immunosuppressive state associated with MTX and reactivation of EBV virus. MTX-LPD consists mainly of diffuse large B-cell lymphoma (DLBCL; 35–60% of cases) and classical Hodgkin lymphoma (12–25% of cases) [5]. Approximately 40–

50% of MTX-LPD cases occur at extra-nodal sites, such as the skin, salivary glands, oropharynx, lungs, digestive tract, liver and spine.

Although spontaneous remission of MTX-LPD can be seen in approximately 50% of cases after withdrawal of MTX [6], chemotherapy may be needed to treat lymphoma recurring or persisting after stopping MTX treatment.

Case presentation:

A 58-year-old female with RA and hypertension for 10 years presented to our clinic with complaints of dry cough and fatigue since last 1 month. She was on methotrexate 7.5 mg twice/week (cumulative dose = 7800 mg) for RA since 2012 and atenolol and amlodipine for hypertension. She did not complain of fever, weight loss, anorexia, night sweats or hemoptysis. She did not have dyspnoea, palpitations or pedal edema. There was no history of any swelling in body. Physical examination did not show any lymphadenopathy or hepatosplenomegaly. Laboratory tests showed LDH-228U/L, ESR- 120 mm/hr with normal renal and liver function tests. Lymphocyte count was 12% (2008/dl).

Plain radiography was suggestive of asymmetric bulkiness in right hilum (figure 1). Computed tomography (CT) of chest revealed asymmetric hypo-enhancing soft tissue density in right infra-hilar and perihilar region measuring 4.4×3.4×3.9cm encasing the right main pulmonary artery (MPA), right bronchus and pulmonary vein abutting the mediastinum with diffuse septal thickening in right lower lobe. Multiple mediastinal lymph nodes were also seen (Figure 2). Abdominal CT revealed enlarged lymph nodes involving the gastro-esophageal junction, gastro-hepatic region, retroperitoneum and common iliac region.

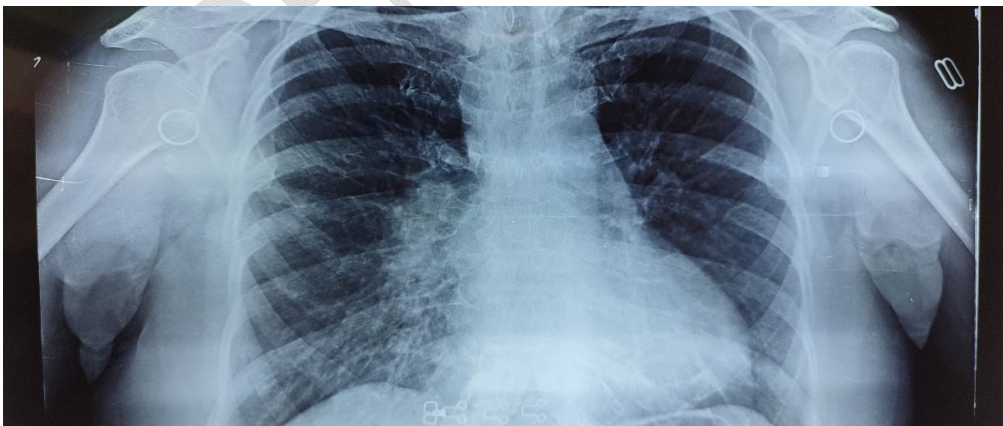


Figure 1: Chest X-Ray showing a bulky right hilum

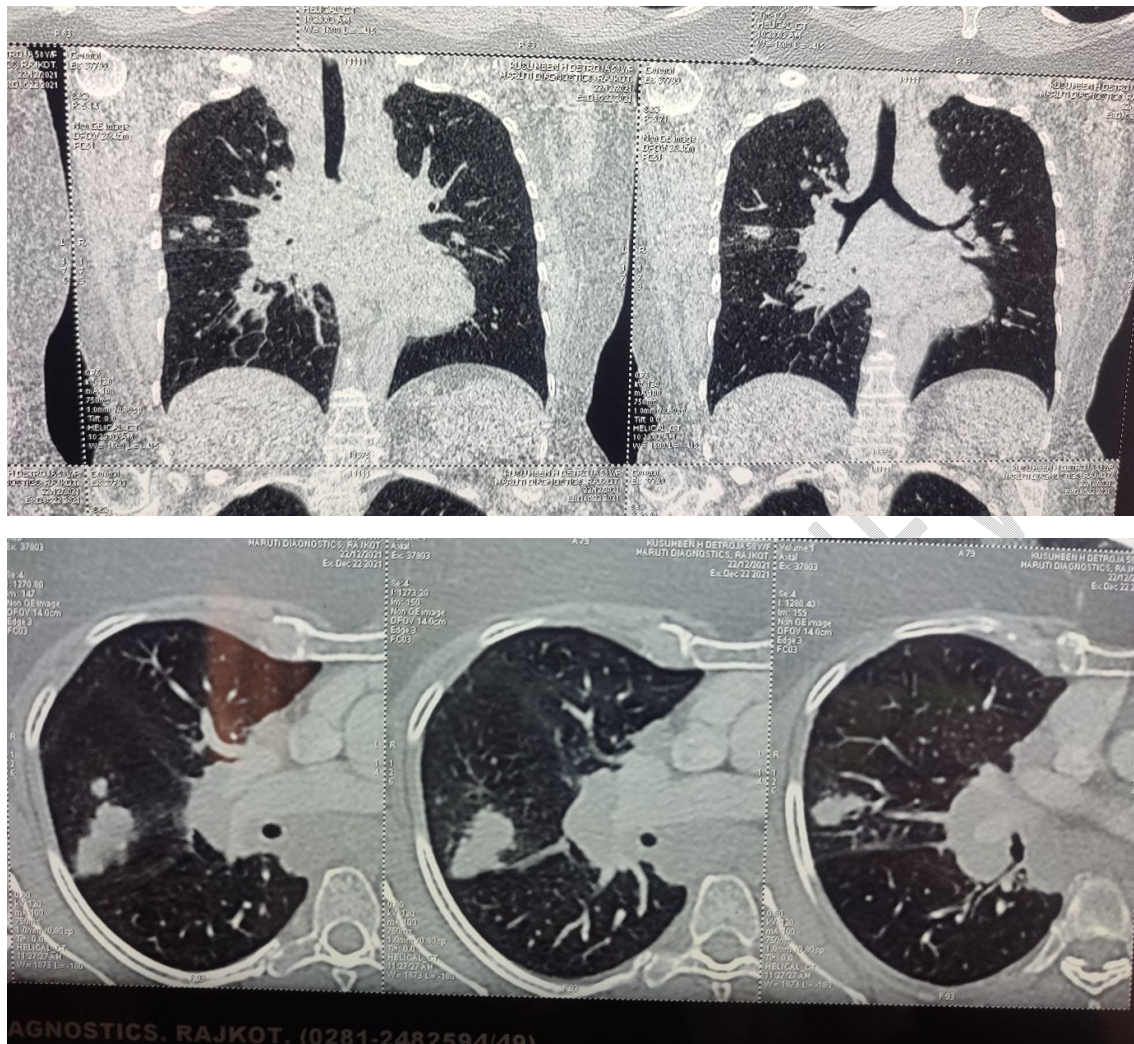


Fig.2: Right hilar STD with involvement of right MPA, right bronchus and pulmonary vein

Based on the radiological findings, differential diagnoses included disseminated Kocbs, malignant lymphoma and metastatic carcinoma of lung. CT guided biopsy was done and histopathological evaluation revealed fibrous tissue with admixed lymphoplasmacytic cells, histiocytes, eosinophils and occasional multinucleate giant cells. Few mononuclear and occasional binucleate large cells were also evident with prominent nucleoli. An impression of Hodgkin lymphoma was made (figure 3). IHC showed CD30 and PAX5 positive, CD15 and CD20 negative atypical cells. Based on these findings along with the patient's history of treatment with MTX for RA, she was diagnosed as a case of MTX-LPD showing features of stage III E classical Hodgkin lymphoma (Lugano classification).

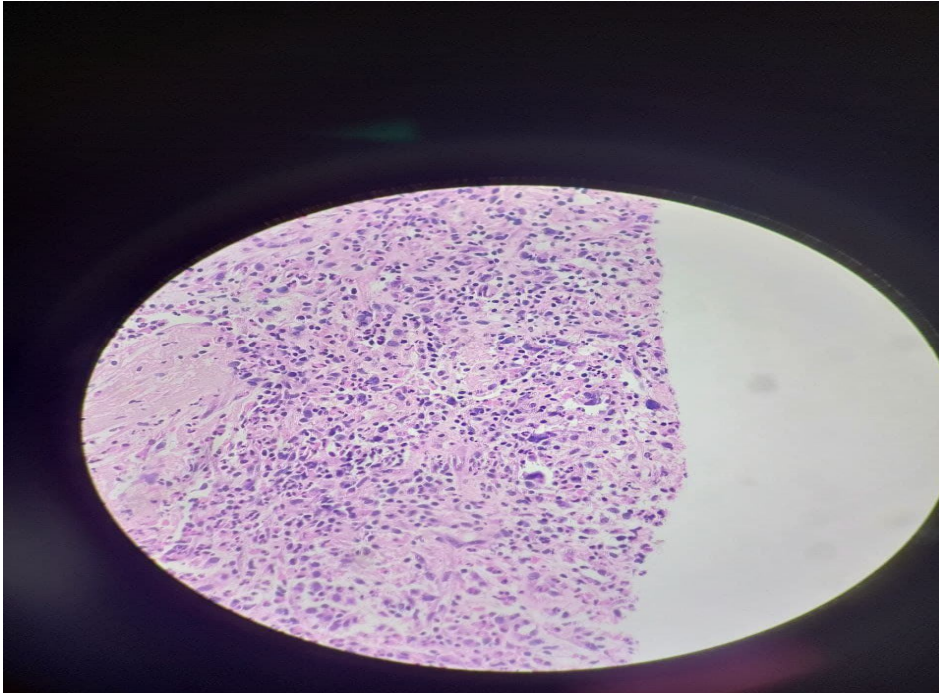


Figure 3: Histopathological section

Patient was initially managed with discontinuation of methotrexate which resulted in significant improvement in symptoms within 4 weeks. PET-CT done after 4 weeks showed complete response with no metabolic abnormality related to primary disease. **Nine** weeks after MTX withdrawal, lymphocyte **count** increased from 12% to 30% (2008/ μL to 3684/ μL). CT done after 10 weeks **showed few sub-centimetric** lymph nodes in **the** mediastinum and abdomen with resolution of **the** primary lesion. (Figure 4)

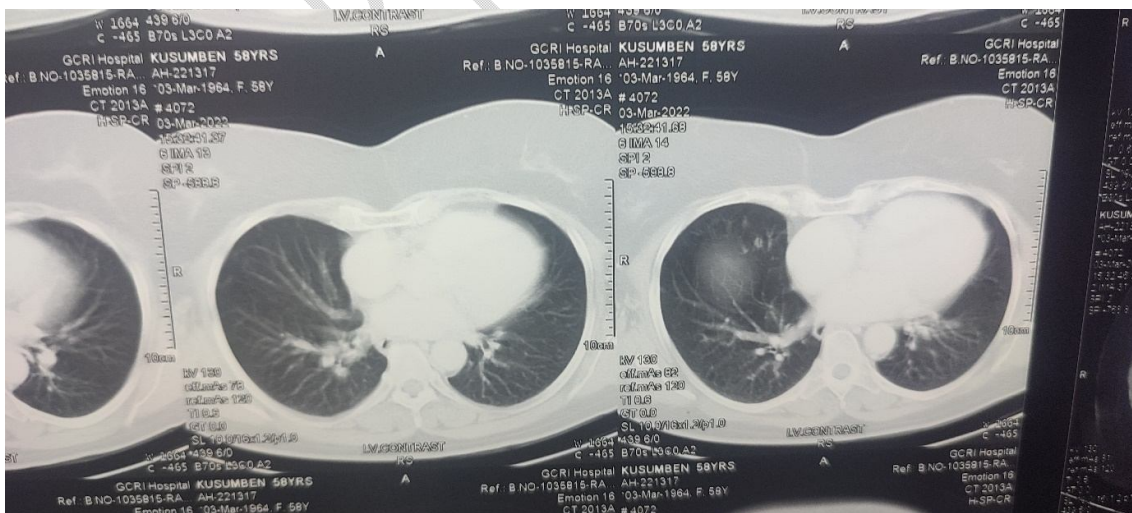


Figure 4 CT Chest post 9 weeks of MTX withdrawal showing resolution of primary lesion

PET-CT done after 6 months showed ametabolic to low grade metabolically active nodes in the mediastinum and retroperitoneum (Deauville score = 3) suggestive of good response to MTX withdrawal. Patient was last followed up in November 2022 when her PET-CT was still suggestive of ametabolic nodes (Deauville Score = 3).

After discontinuation of MTX, patient complained of aggravation in joint pain which was managed conservatively with NSAIDs. Rheumatologist's opinion was taken who advised to switch to alternate immunosuppressant other than MTX after 3 months of observation.

Discussion

MTX-LPD is a serious and uncommon complication in patients of various autoimmune disorders including RA, psoriasis, dermatomyositis, and inflammatory bowel disease who are on MTX for their chronic condition (7-10). The rising incidence of MTX-LPD is related partly to the increased use of MTX as an anchor drug in the management of RA .

Pathogenesis of MTX-LPD is poorly understood: combination of immunodeficiency as a result of RA and the immunosuppressive effect of MTX has been implicated in the pathogenesis of MTX-LPD (11,12). Chronic MTX administration leads to suppression of the immune system leading to reactivation of viral infections like EBV, (including subclinical infections) leading to clonal proliferation of cells (13). Activation of EBV is identified in the majority of MTX-LPD cases, including the present case, which was characterized by the presence of positive EBV viral DNA (845.35 copies/mL) detected on RTPCR.

Clinically MTX-LPD is seen predominantly in females with a median age of 60-70 years and usually develops after 5-10 years of MTX administration. MTX-LPD is characterised by diffuse lymphadenopathy with or without B symptoms. Involvement of extra lymphatic tissue is relatively high (11,12,13) with approximately 40–50% of MTX-LPD cases occurring at extra nodal sites, such as the skin, salivary glands, lungs, digestive tract, liver and spine. In the present case, lung lesions with mediastinal and abdominal lymphadenopathy were seen.

MTX-LPD can originate from different cell types, including B cells, T cells and NK cells. Histologically, MTX-LPD can be diverse: but the most common finding is diffuse large B-cell lymphoma accounting for 50% of cases, followed by Hodgkin lymphoma (20-35%). (11,14) Other rare phenotypes like peripheral T-cell lymphoma, Hodgkin like lesions, EBV positive mucocutaneous ulcers or polymorphic/lymphoplasmacytic infiltrates have also been reported (14). The patient in the present case had Hodgkin lymphoma (MTX-HD).

Most MTX-DLBCL are activated B cell type (ABC). MTX-HD is a rare disease. MTX-HD is more frequently found to be mixed cellularity subtype (61% in one study) (15) and more commonly associated with EBV infection (83% vs 45% in sporadic CHL) (16). MTX-HD is less frequently CD20 positive compared to the sporadic type. Clinically, in contrast to sporadic HD, MTX-HD more commonly presents in an advanced stage and is often associated with extra nodal disease in 40-70% of cases. (15,16).

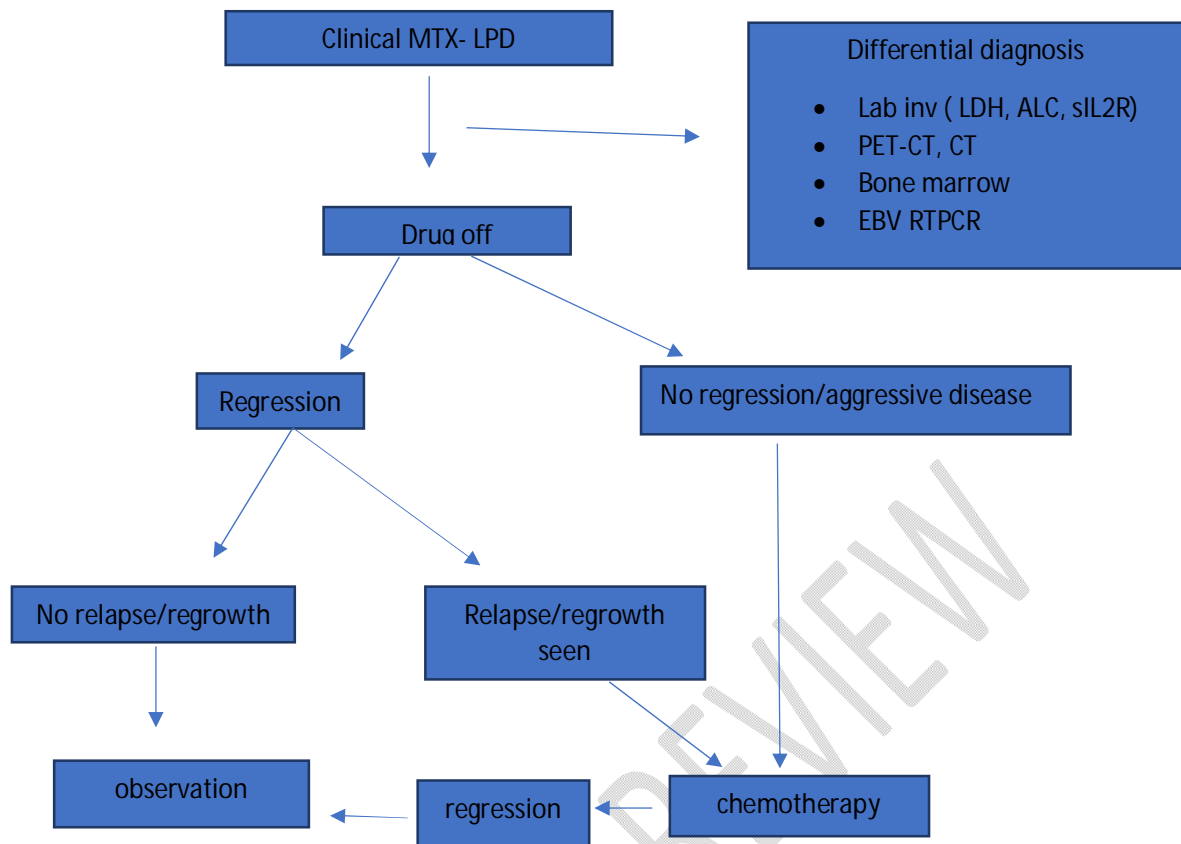
The duration and dose of MTX treatment leading to MTX-LPD has varied across studies. The duration ranged from 2-131 months (12) with reports even after 20 years. The cumulative

dose observed varies from 24mg to 4785mg (median 940mg). (12) In one case-control study conducted by Kameda et al, higher mean MTX dose was found to be an independent risk factor for LPD development in RA patients.[11] In our patient HD developed after 10 years with a cumulative dose of 7800mg.

Three clinical courses following MTX withdrawal have been suggested:

- LPD regression after ISD withdrawal without relapse/regrowth
- LPD regression after ISD withdrawal with relapse/regrowth
- Persistent LPD

Spontaneous resolution of LPD after withdrawal of MTX treatment is observed in ~50% of all affected patients (14,17). In one of the studies, 76.7% had regression of LPD after MTX withdrawal (18). In another study, the majority of DLBCL-type MTX-LPD patients (81%) achieved remission with MTX discontinuation alone. Thus, the first choice of treatment of MTX-LPD is rapid cessation of MTX (14,17,18). However, subsequent recurrence of MTX-LPD has been reported in 18–45% of patients and chemotherapy is indicated in cases of recurrence, aggressive LPD and in those not reaching remission after > 3 months (17,19). OS is better in patients with LPD regression without relapse or regrowth compared to those with persistent LPD or those who relapse following regression. MTX- DLBCL requiring chemotherapy has better prognosis than sporadic DLBCL after receiving rituximab-based therapy (19). As opposed to MTX-DLBCL, rate of spontaneous regression following MTX withdrawal is lower with MTX-HD and roughly 3/4th require additional chemotherapy (15) but have similar PFS and OS compared to sporadic HD following treatment.



Flowchart 1 : Treatment analytical procedure for Pathogenesis of MTX- LPD

Increase in lymphocyte count following withdrawal of MTX has been shown to be a marker of higher rate of spontaneous regression of MTX-LPD (20). As reported by Saito et al., lymphocyte count increased more than 220/ μ l in the regressive group compared to less than 150/ μ l in the persistent group at 2 weeks after withdrawal of MTX (20). This finding was consistent with our case too as the lymphocyte count increased from 12% to 30% (2008/uL to 3684/uL), though the recovery was seen at nine weeks.

EBV positivity in MTX-LPD has been proved to be an important prognostic factor. Prevalence of EBV in RA patients with LPD has been reported to be significantly higher than that in sporadic LPD (27.6% vs. 9.9%) (12). Patients with EBV DNA positivity in peripheral blood have a better outcome with higher rate of spontaneous regression compared to those who are negative. (18) This finding is also consistent with our experience, as the patient in the present case was EBV-positive and has not developed any recurrence.

Use of alternative immunosuppressant drug after development of MTX-LPD is poorly defined. Generally, it is recommended to not use MTX and anti TNFi.

Although the treatment of RA has changed over the years with the use of high efficacy drugs such as the biological agents, MTX, being cost effective and highly efficacious - will remain the first-line drug. Hence, studies should be conducted to elucidate the pathogenesis of MTX-LPD.

Conclusion

MTX-LPD should be suspected in patients who are on MTX and presents with clinical features of Lymphoma. First-line therapy is the withdrawal of MTX. Even after the remission of MTX-LPD, close observation is important, and if the disease recurs, chemotherapy should be started promptly.

References

1. Goldin LR, Landgren O. Autoimmunity and lymphomagenesis. *Int J Cancer* 2009;124:1497–1502.
2. Hoshida Y, Xu JX, Fujita S, et al. Lymphoproliferative disorders in rheumatoid arthritis: clinicopathological analysis of 76 cases in relation to methotrexate medication. *J Rheumatol* 2007;34:322–331.
3. Ellman MH, Hurwitz H, Thomas C, Kozloff M. Lymphoma developing in a patient with rheumatoid arthritis taking low dose weekly methotrexate. *J Rheumatol*. 1991;18:1741–3.
4. Swerdlow SH, Campo E, Harris NL, Jaffe ES, Pileri SA, Stein H, et al. World Health Organization classification of Tumours of Haematopoietic and lymphoid tissues. Revised 4th ed. Lyon: IARC Press; 2017. p. 462–4.
5. Gion Y, Iwaki N, Takata K, Takeuchi M, Nishida K, Orita Y, et al. Clinicopathological analysis of methotrexate-associated lymphoproliferative disorders: comparison of diffuse large B-cell lymphoma and classical Hodgkin lymphoma types. *Cancer Sci*. 2017;108:1271–80.
6. Takanashi S, Aisa Y, Ito C, Arakaki H, Osada Y, Amano Y, et al. Clinical characteristics of methotrexate-associated lymphoproliferative disorders: relationship between absolute lymphocyte count recovery and spontaneous regression. *Rheumatol Int*. 2017;37:1629–33.
7. Padeh S, Sharon N, Schiby G, Rechavi G, Passwell JH. Hodgkin's lymphoma in systemic onset juvenile rheumatoid arthritis after treatment with low dose methotrexate. *J Rheumatol* 1997;24:2035-7
8. Kamel OW, van de Rijn M, Weiss LM, Del Zoppo GJ, Hench PK, Robbins BA, et al. Brief report: reversible lymphomas associated with Epstein-Barr virus occurring during methotrexate therapy for rheumatoid arthritis and dermatomyositis. *N Engl J Med* 1993;328:1317-21.

9. Moseley AC, Lindsley HB, Skikne BS, Tawfik O. Reversible methotrexate associated lymphoproliferative disease evolving into Hodgkin's disease. *J Rheumatol* 2000;27:810-3.
10. Jardine DL, Colls BM. Hodgkin's disease following methotrexate therapy for rheumatoid arthritis. *N Z Med J* 2002;115:293-4.
11. Kameda T, Dobashi H, Miyatake N, Inoo M, Onishi I, Kurata N, Mitsunaka H, Kawakami K, Fukumoto T, Susaki K, *et al*: Association of higher methotrexate dose with lymphoproliferative disease onset in rheumatoid arthritis patients. *Arthritis Care Res (Hoboken)* 66: 1302-1309, 2014.
12. Hoshida Y, Xu JX, Fujita S, Nakamichi I, Ikeda J, Tomita Y, Nakatsuka S, Tamaru J, Iizuka A, Takeuchi T, *et al*: Lymphoproliferative disorders in rheumatoid arthritis: Clinicopathological analysis of 76 cases in relation to methotrexate medication. *J Rheumatol* 34: 322-331, 2007.
13. Mokuda S, Miyazaki T, Saeki Y, Masumoto J, Kanno M and Takasugi K: Epstein-Barr virus-related MTX-LPD in rheumatoid arthritis patients exhibits a viral pattern of the CD64 and CD35 expression on neutrophils: Three case reports. *Mod Rheumatol* 25: 166-168, 2015.
14. Tokuhira M, Watanabe R, Nemoto T, Sagawa M, Tomikawa T, Tamaru J, Itoyama S, Nagasawa H, Amano K, Kameda H, *et al*: Clinicopathological analyses in patients with other iatrogenic immunodeficiency-associated lymphoproliferative diseases and rheumatoid arthritis. *Leuk Lymphoma* 53: 616-623, 2012.
15. Loo EY, Medeiros LJ, Aladily TN, Hoehn D, Kanagal-Shamanna R, Young KH, Lin P, Bueso-Ramos CE, Manning JT Jr., Patel K, Thomazy V, Brynes RK, Goswami M, Fayad LE, Miranda RN. Classical Hodgkin lymphoma arising in the setting of iatrogenic immunodeficiency: a clinicopathologic study of 10 cases. *Am J Surg Pathol*. 2013;37:1290–1297. PMID: 23774171. DOI: 10.1097/PAS.0b013e31828e6564.
16. Yoshifuji K, Umezawa Y, Ichikawa A, Watanabe K, Miura O, Yamamoto M. Methotrexate-associated Classical Hodgkin Lymphoma Shows Distinct Clinicopathological Features but Comparable Clinical Outcomes With Sporadic Cases. *In Vivo*. 2019;33(5):1599-1604. doi:10.21873/invivo.11642
17. Ichikawa A, Arakawa F, Kiyasu J, Sato K, Miyoshi H, Niino D, Kimura Y, Takeuchi M, Yoshida M, Ishibashi Y, *et al*: Methotrexate/iatrogenic lymphoproliferative disorders in rheumatoid arthritis: Histology, Epstein-Barr virus, and clonality are important predictors of disease progression and regression. *Eur J Haematol* 91: 20-28, 2013
18. . Katsuyama T, Sada KE, Yan M, Zeggar S, Hiramatsu S, Miyawaki Y, Ohashi K, Morishita M, Watanabe H, Katsuyama E, *et al*: Prognostic factors of methotrexate-associated lymphoproliferative disorders associated with rheumatoid arthritis and plausible application of biological agents. *Mod Rheumatol* 27: 773-777, 2017

19. Niitsu N, Okamoto M, Nakamine H, Hirano M. Clinicopathologic correlations of diffuse large B-cell lymphoma in rheumatoid arthritis patients treated with methotrexate. *Cancer Sci.* 2010;101:1309–13.
20. Saito S, Kaneko Y, Yamaoka K, Tokuhira M, Takeuchi T. Distinct patterns of lymphocyte count transition in lymphoproliferative disorder in patients with rheumatoid arthritis treated with methotrexate. *Rheumatol.* 2017;56:940–6.

UNDER PEER REVIEW