

Gastric Trichobezoar that Manifested with Chronic Epigastric Pain: A Case Report and Literature Review

ABSTRACT

Gastric trichobezoar consist of the accumulation of chewed hair in the stomach. The hair can also extend to other structures of the digestive tract. It is a rare presentation which is usually associated with trichotillomania and trichphagia.

Trichobezoars are rare and present both a diagnostic and therapeutic challenge.

We report a case of a young adult female who presented with gastric pain.

Surgery consisted of a small laparotomy and evacuation of the trichobezoar through a small gastrotomy. Treatment should be coupled to psychiatric evaluation and therapy to prevent recurrence.

Keywords: Trichobezoar; gastric; abdominal pain; laparotomy; gastrotomy and trichophagia.

1. INTRODUCTION

Gastric bezoars are masses of foreign material found in the stomach, generally forming into a hard object. Gastric bezoars are categorized by the material of which they are composed, including but not limited to phytobezoars (plant matter), trichobezoars (hair), pharmacobezoars (medications), and others (e.g., tissue paper or Styrofoam)" [1].

"Gastric bezoars appear to be rare; Kadian et al. reported an incidence of only 0.3% on endoscopy" [2].

"Trichobezoars are far more common in females (90%) and have the highest incidence before the third decade of life. In addition, trichobezoars are associated with psychiatric disorders, such as trichotillomania and trichophagia" [3].

2. CASE REPORT

An 18-year-old patient, with no notable medical or surgical history, consults for chronic abdominal pain.

The clinical examination found a patient in good general condition. She was afebrile with normal colored conjunctivae.

Abdominal examination revealed pain on deep palpation of the epigastric region without mass individualization.

The complete blood count showed the white blood cells at 7600 elements/mm³, hemoglobin at 8.6g/dL, platelets at 361,000 elements/ mm³ and a prothrombin time (PT) at 86 percent.

The ionogram found a CRP of 195 mg/L and normal renal function.

An abdominal CT scan after IV injection of the contrast product (Fig.1) was performed.

Abdominal computed tomography with injection of contrast product reveals the presence of a large gastric endoluminal mass. The mass occupied almost all of the lumen, measuring approximately 170x65mm, without parietal attachment. The mass was heterogeneous and contained air bubbles ; it was not enhanced after injection of contrast product.

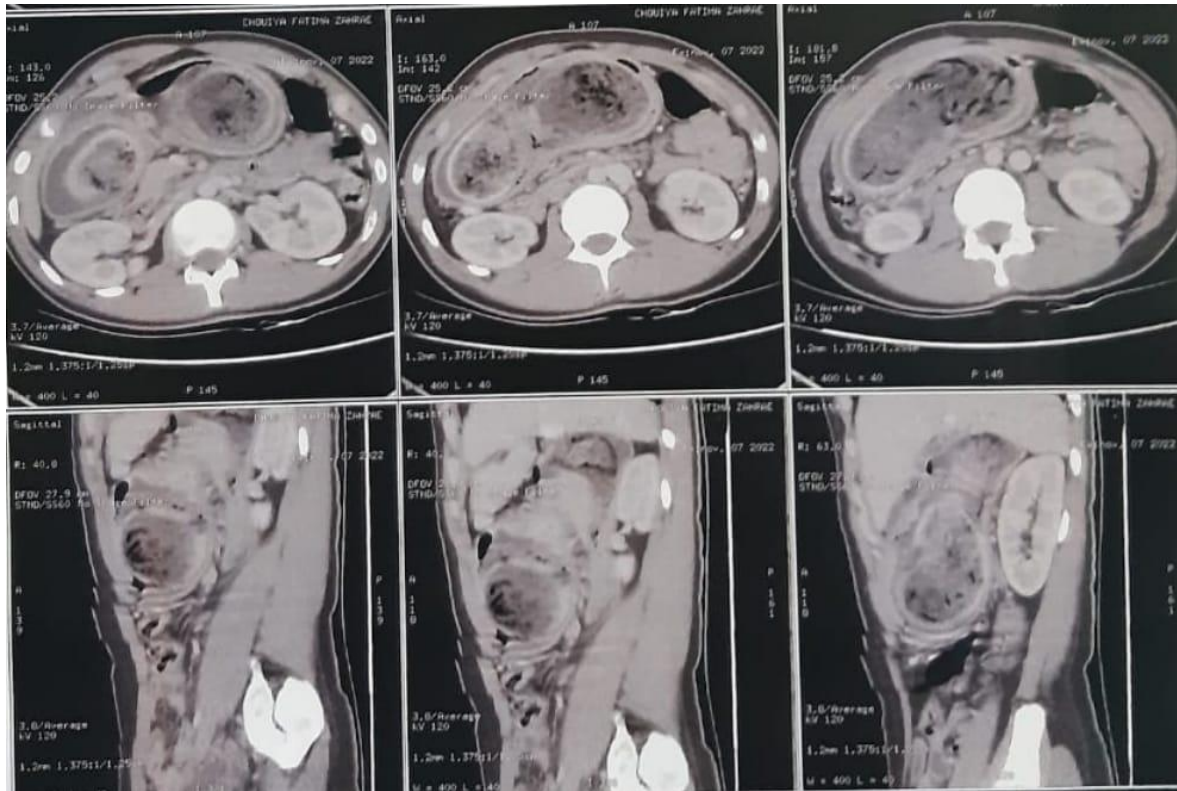


Fig. 1. Abdominal CT in axial and longitudinal section after IV injection of the contrast product
 Faced with this CT appearance, the diagnosis evoked was a gastric trichobezoar. The patient was subsequently referred for psychiatric follow-up to prevent recurrence.

This patient was not subject to any endoscopic examination because we were certain that the patient would need mass extraction regardless of the type of bezoar.

The patient was operated with a median supra umbilical incision, then a longitudinal gastrotomy of 10 cm was performed objectifying a trichobezoar obstructing the gastric lumen.

The trichobezoar was then extracted (Fig. 2).

It weighed 830 gm.

3. DISCUSSION

"Bezoar" is etymologically derived from the Arabic "bedzher" or "bezhhr" which dates from 2000 years ago, meaning antidote or counter-poison [4].

"Historically, it was described as a greenish hard mass found inside the stomach of Syrian goats, which was believed to be a treatment for poison. Trichobezoar had been recognized as early as autopsy reports in 1779" [5].

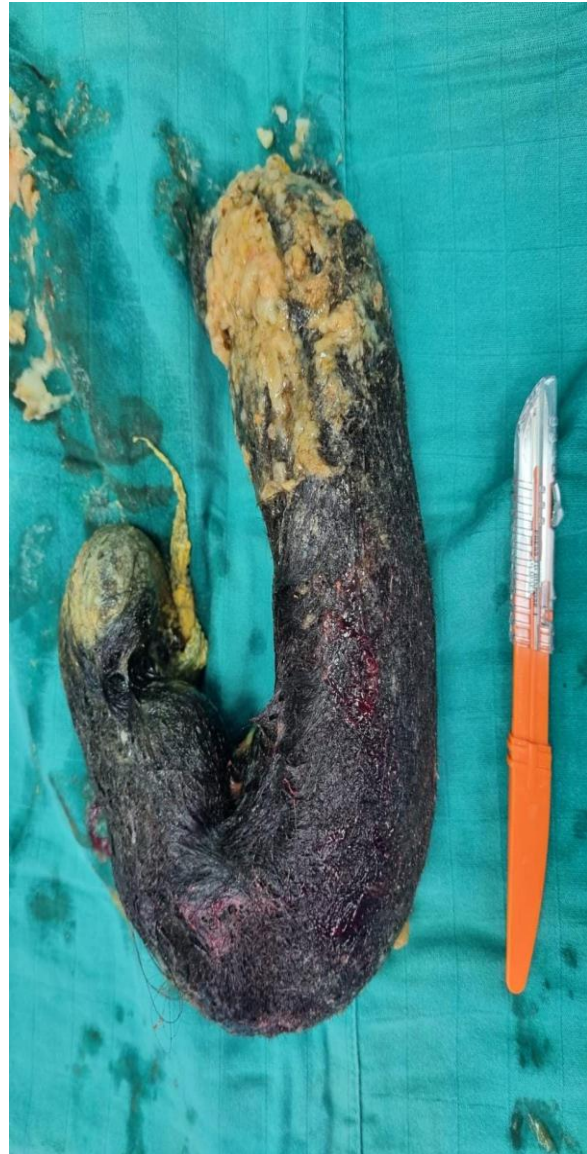
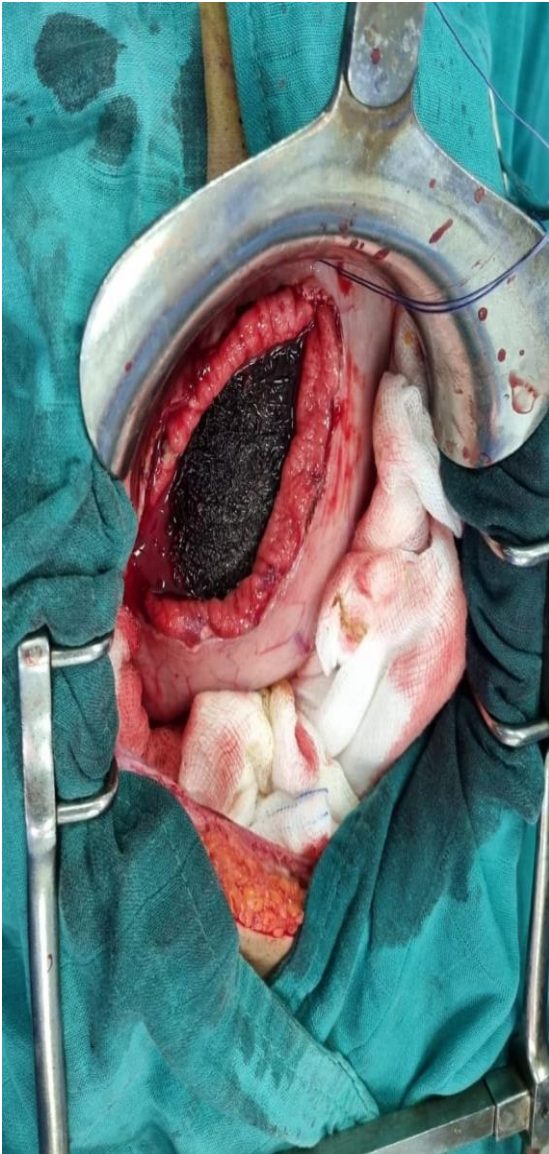
Fig. 2. Gastrotomy allowing manual extraction of the trichobezoar

"It may happen to both younger age groups and adults. However, both of these groups are usually associated with psychiatry illness and sometimes the former one related to congenital health problems. In younger age groups, psychiatry-related mood or anxiety disorders can be contributed to by background social history such as parenting or sometimes environment in school" [6].

"In adults, this may be associated with trichotillomania. Trichotillomania is a condition whereby patients are anxiously pulling their hair to get relief or satisfaction. This is followed later by the compulsive act of trichophagia. This may result due to a depression secondary to the underlying poor social background or underlying disease" [7].

"Initially asymptomatic during the earlier stages persistent collection of hair increases obstruction, resulting in a presentation of malaise, vomiting, generalized abdominal pain and anorexia over time resulting in loss of weight and cachexia" [8].

"The most common features include abdominal pain, epigastric discomfort, nausea and vomiting, early satiety, dyspepsia, weight loss, transit disorder. Other less common presenting features are obstruction, gastric perforation, gastrointestinal bleeding, intussusceptions, jaundice, pancreatitis biliary perforation. Other malabsorption related complications include protein losing enteropathy, iron deficiency, and megaloblastic anemia" [9].

"Eventually over time, the trichobezoar will extend into the small intestine as a tail, a condition called Rapunzel syndrome, reported initially by Vaughan and colleagues in 1963. Rapunzel syndrome is a rare progression of trichobezoar as over time the accumulation of hair will cause the trichobezoar to grow beyond the stomach and into the small intestine, over the decades various criteria have been utilised in literature to describe the condition, Descriptions include a tail extending up to jejunum and further beyond" [10].

This is the case of our patient who started to develop Rapunzel's syndrome, as shown in the trichobezoar extract.

"Physical examination is often poor in uncomplicated forms but may reveal a well-limited, smooth, firm, and mobile epigastric mass" [11].

"For additional studies requested to support the diagnosis, the indication differs according to the clinical presentation. For uncomplicated forms or forms complicated by hemorrhage, the reference examination requested in the first line remains the esophagogastroduodenoscopy (EGD) which allows a dual role both diagnostic and therapeutic" [11].

"Diagnosis of complicated forms is based on urgently requested imaging. The abdominal X-ray without preparation is a non specific examination that may show hydroaeric levels in order to confirm a clinical diagnosis of occlusion or an image of pneumoperitonium synonymous to gastro-intestinal perforation. Abdominal ultrasound, visualizing a superficial band, hyperechogenic, curvilinear with a posterior shadow cone leads to correct diagnosis in 25% of cases" [12].

"Abdominal CT remains the preferred imaging modality requested urgently in case of an occlusion or peritonitis presentation. It allows positive diagnosis by showing a mass of variable, heterogeneous volume, occupying almost the entire gastric lumen and consisting of multiple concentric circles of different densities distributed in onion bulbs. Two pathognomonic and constant signs are the presence of tiny air bubbles dispersed within the mass and the absence of any attachment of the mass to the gastric wall. The scanner also allows to specify the size of the obstacle, its location and its extension, and determines the signs of complications such as ischemia or perforation" [13].

"Although Endoscopy has been used increasingly over the past decade but it is not a viable option for larger trichobezoars and repeatedly performing this procedure can lead to devastating complications like esophageal perforation" [14].

"Exploration by Laparotomy is considered to be the most effective treatment for trichobezoars having the highest success rate, and the gold standard for large trichobezoars which may extend beyond the pylorus such in the cases of Rapunzel syndrome where a trichobezoar can extend to small intestine and even to ileo-cecal valve where an enterotomy and retrieval is done" [15].

"A retrospective study by Gorter et al. on 108 patients compare different treatment modalities, endoscopic treatment 5%, laparoscopic approach 75% and laparotomy a 100% success rate which is also preferred in complicated cases" [16].

"The surgical treatment of the trichobezoars is however not the only element, as the underlying psychiatric disorder is the causative factor in the development of trichobezoars and psychiatric care makes an important part of the management"[17].

"Thus a multi-disciplinary approach is the mainstay of treatment" [4].

"The long-term prognosis of these patients depends completely on preventing recurrences and psychiatric and psychological support and close follow-up are essential" [9].

4. CONCLUSION

Trichobezoars are rare and present both a diagnostic and therapeutic challenge. Clinical symptomatology depends on the size of the trichobezoar and whether or not complications are present. Physicians, surgeons and radiologists should consider trichobezoars among the differential diagnosis for young females with abdominal pain and presence of an upper abdominal mass. Diagnosis of the trichobezoar was established with a Abdominal CT. It was successfully removed through a small laparotomy and gastrotomy. A post-operative psychologic management is essential to correct psychobehavioural disorders of patients to prevent recurrence.

CONSENT

As per international standard or university standard, patient(s) written consent has been collected and preserved by the author(s).

ETHICAL APPROVAL

As per international standard or university standard written ethical approval has been collected and preserved by the author(s).

COMPETING INTERESTS

Authors have declared that no competing interests exist.

REFERENCES

1. Weston LaGrandeur, Melissa Zukowski. Visual Diagnosis in Emergency Medicine. The Journal of Emergency Medicine. 2021 ;61(6) :e167–e169. © 2021 Elsevier Inc.
2. Kadian RS, Rose JF, Mann NS. Gastric bezoars—spontaneous resolution. Am J Gastroenterol. 1978;70:79–82.
3. Gorter RR, Kneepkens CM, Mattens EC, Aronson DC, Heij HA. Management of trichobezoar: Case report and literature review. *Pediatr Surg Int*. 2010;26:457–63.
4. Aishath Azna Ali, Rajan Gurung, Zeena Mohamed Fuad, Muaz Moosa, Isha Ali, Ahmad Abdulla, Assikin Muhamad, Firdaus Hayati, Nicholas Tze Ping Pang. Gastric trichobezoar in an end-stage renal failure and mental health disorder presented with chronic epigastric pain: A case report. *Annals of Medicine and Surgery*. 2020;58: 76–79.
5. Caiazzo P, Di Lascio P, Crocoli A, Del Prete I The Rapunzel syndrome. Report of a case.. *Chiryo*. 2016;37(2):90–94.
6. Larik S, Ahmed H, Khalid M, Mehmood Z. Ileal trichobezoar in a boy with cerebral palsy. *J. Surg. Pakistan*. 2018;23:119–120.
7. Pinto ACVD, de Brito FF, Cavalcante MLLL, de Andrade, G.V. da Silva, A.C.C. Martelli, An. Bras. TCPC. Trichotillomania, A case report with clinical and dermatoscopic differential diagnosis with alopecia areata. *Dermatol*. 2017;92(1): 118–120.
8. Murad Habib, Muhammad Bin Amjad, Muhammad Abbas, Muhammad Amjad Chaudhary. Gastric Trichobezoars in paediatric population– A series of six cases and literature review. *Annals of Medicine and Surgery*. 2022;84:104906.
9. Sameh Tlili, Malak Boughdir, Aida Daib, Rim Kchaou, Youssef Hellal, Rabiaa ben Abdallah, Nejib Kaabar. Trichobezoar presenting as an abdominal mass. *Journal of Pediatric Surgery Case Reports*. 2021; 75:102076.
10. Gupta A, Gupta PL. Gastric trichobezoar and Rapunzel syndrome: A case report. *Int. J. Surg*. 2020;7(5):1634–1636.
11. Mohamed Ben Khalifa, Mossaab Ghannouchi, Karim Nacef, Asma Chaouch, Mohamed Sellami, Moez Boudokhane. Trichobezoar: A case report of a double gastric and ilial localization revealed by an occlusion. *International Journal of Surgery Case Reports*. 2022;91:106782.
12. Ezziti M. Trichobézoard gastrique: A propos d'un cas. *Pan Afr. Med. J*. 2017; 26(74):74.
13. Lyons R, Ismaili G, Devine M, Malik H. Rapunzel syndrome causing partial gastric outlet obstruction requiring emergency laparotomy. *BMJ Case Rep*. 2020;13(1).
14. Al-Osail EM, Zakary NY, Abdelhadi Y. Best management modality of trichobezoar: A case report. *Int. J. Surg. Case Rep*. 2018; 53:458–460.
15. Naik S, Gupta V, Naik S, Rangole A, Chaudhary AK, Jain P, Sharma AK. Rapunzel syndrome reviewed and redefined, *Dig. Surg*. 2007;24(3):157–161.
16. Gorter RR, Kneepkens CM, Mattens EC, Aronson DC, Heij HA. Management of trichobezoar: Case report and literature review. *Pediatr. Surg. Int*. 2010;26(5): 457–463.
17. Chahinea E, Baghdadya R, El Karya N, Dirania M, Hayeka M, Saikalyb E, Chouillarda E. Surgical treatment of gastric outlet obstruction from a large trichobezoar: A case report. *International Journal of Surgery Case Reports*. 2019;57 :183–185.