

Surgical Management of a Maxillary Peripheral Ossifying Fibroma

ABSTRACT

Peripheral ossifying fibroma (POF) is a fibromatous and non-neoplastic enlargement of the gingiva that exhibits regions of calcification/ossification. The present case shows a peripheral ossifying fibroma of the maxilla. The lesion was evident on the attached gingiva of maxillary posterior teeth extending from canine to first molar teeth. For management, fibroma was surgically excised and L-PRF membrane was placed over the underlying exposed bone under local anesthesia. Histological examination was done to confirm the diagnosis of Peripheral Ossifying Fibroma. L-PRF membrane as a biomaterial to cover the exposed areas of the bone after surgical excision is an effective option for better secondary intention healing and it provides acceptable results for tissue regeneration.

Keywords: Fibroma; ossifying; calcification; granuloma; pyogenic; peripheral; surgical; biopsy.

1. INTRODUCTION

Isolated reactive lesions are very common findings on the gingiva which include 'fibrous hyperplasia', 'peripheral ossifying fibroma', 'peripheral giant cell granuloma', and 'pyrogenic granuloma' [1,2]. Most prevalent gingival finding is a solitary gingival enlargement; usually due to a reactive response to local irritation, however other potential causes include microorganisms, plaque, calculus, restorations, irritants, and dental appliances.

Fibromas are of two types: 'central' type and 'peripheral' type. The peripheral type primarily impacts the soft tissues covering the tooth-containing areas of the jaws, whereas the central type causes an expansion of the medullary cavity and originates from the endosteum or periodontal ligament closer to the root apex [2]. POF is a fibromatous, non-neoplastic gingival growth characterised by areas of calcification or ossification. The surface may be intact (34%) or ulcerated (66%) and the colour may correlate with normal mucosa or lightly reddish [3]. It consists of a cellular fibroblastic connective tissue stroma and haphazardly distributed calcification foci that are composed of bone or cementum-like tissue [4]. It was originally introduced as "maxillary exostosis" in 1844 by 'Shephard'. 'Eversol and Robin' initially coined the term "Peripheral Ossifying Fibroma" in 1972.

Various other synonyms for POF include "Calcifying or ossifying fibroid epulis", "peripheral fibroma with calcification", "calcifying fibroblastic granuloma", "peripheral cementifying fibroma", or "mineralizing ossifying pyogenic granuloma" [5]. POF manifests itself clinically as a sessile or pedunculated nodular mass, generally red to pink in color and most frequently found in children and young adults with the predilection for the maxillary incisor and cuspid region [2].

2. CLINICAL CASE PRESENTATION

A 42 year old female patient reported to the department of Periodontics at Pacific Dental College and Hospital (PDCH) in Udaipur, Rajasthan with the chief complaint that her upper left front and back teeth had been loosening for the past month, and a lump-like mass in gums of the same area since previous seven months (Fig. 1). There was no relevant previous medical history, injuries, or ulceration history.

The oral cavity was clinically examined intraorally, and on the keratinised gingiva, a single, pedunculated nodular growth that expanded mesiodistally from the distal aspect of the canine (23) to the mesial aspect of the first molar (26) and covered up to more than two-third of the teeth was seen (Fig. 2). The lesion was well-defined, reddish, circular to oval-shaped, non-tender, solid in consistency, and

measured roughly 3 cm × 2.5 cm × 2 cm (Fig. 3). The lesion did not bleed when provoked and had pathological migration of 24 (Fig. 3) and mobility of grade III in 22, 23, 24, and 25. In addition, generalised Miller's Class II gingival recession was clearly evident.

Upon extraoral examination, facial asymmetry was seen on the left side from the philtrum to the angle of the mouth. After complete examination, Pyogenic granuloma and Peripheral ossifying fibroma were included in the differential diagnosis along with a provisional diagnosis of traumatic fibroma.

The IOPA revealed bone loss upto the middle of the root with diffuse ill-defined periapical radiolucency suggestive of periapical abscess (Fig. 12). CBCT revealed bone loss upto the apical third of the root along with an expansile lesion evident on the left side of the maxilla extending from the 24 – 26 tooth regions with small radio-opaque foci of calcification noted within the lesion along with the expansion of the buccal cortex (Fig. 13). Routine haematological investigations were normal.

3. CASE MANAGEMENT

Following thorough scaling and root planing, the patient was instructed to come back seven days later for an excisional biopsy under local anaesthesia. After appropriate antisepsis, local anaesthesia was administered, the lesion was excised (Fig. 4), and the accompanying grade III mobile teeth were extracted (Fig. 5). Curettage of the area was done and as bony spicules were present, bone file was used to smoothen the bone. L-PRF membrane was placed over the area as there was a tissue deficiency and for better healing [6] (Fig. 6). A periodontal dressing (COE -PAK™ AUTOMIX) was applied (Fig. 7), and the patient was summoned back for a check-up and the dressing was removed after 7 days [7].

On the 7th day, adequate healing was seen at the site and the patient was kept on follow-up for 2 months and no recurrence was observed (Figs. 9, 10).

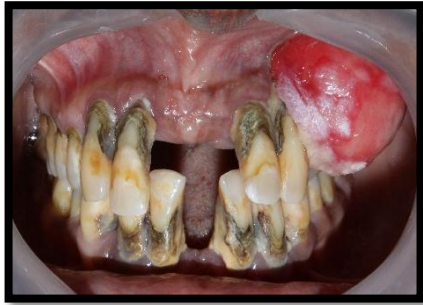

Fig. 1. Frontal View

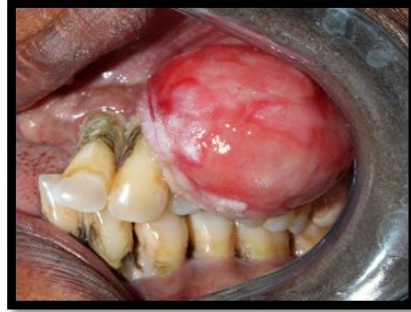

Fig. 2. Apico-coronal extension

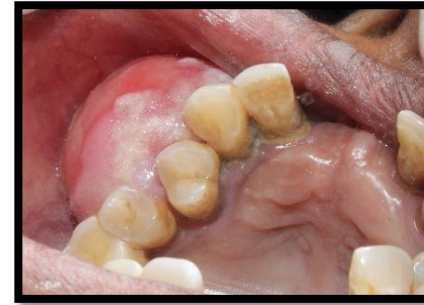

Fig. 3. Mesio-distal extension

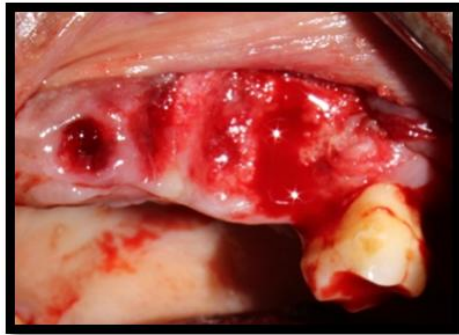


Fig. 4. Surgical Excision

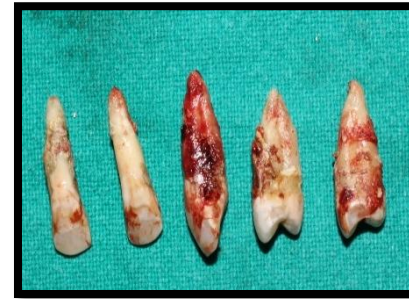

Fig. 5. Extraction of associated teeth

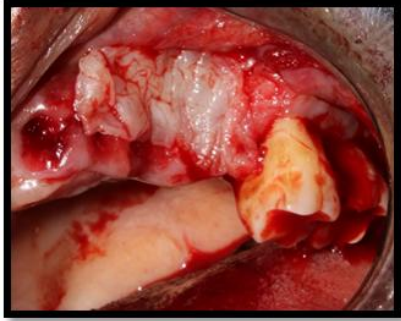


Fig. 6. L-PRF membrane placement

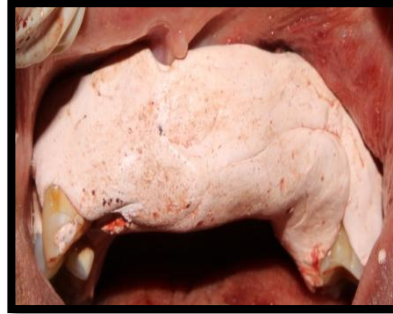

Fig. 7. Periodontal dressing placement

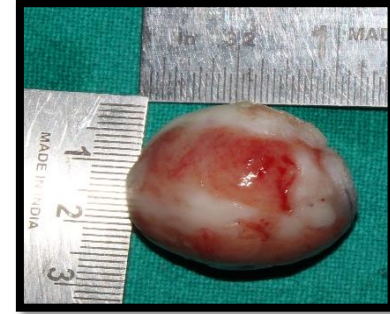

Fig. 8. Excised mass

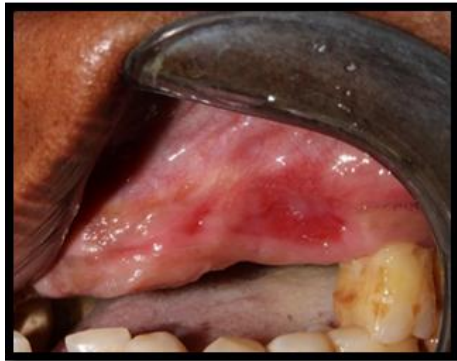

Fig. 9. 1 month re -evaluation

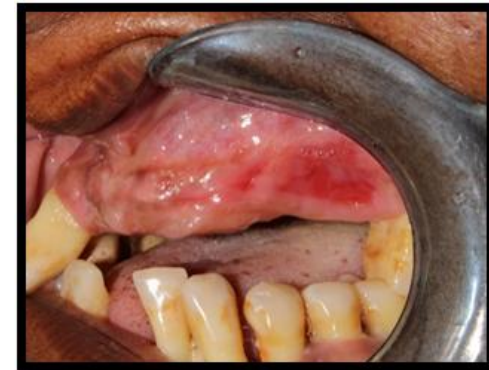

Fig. 10. 2 months re-evaluation

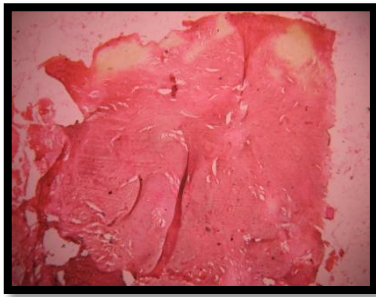

Fig. 11. Histopathological examination

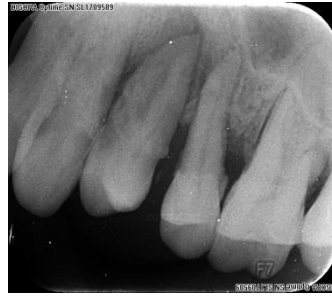

Fig. 12. IOPA

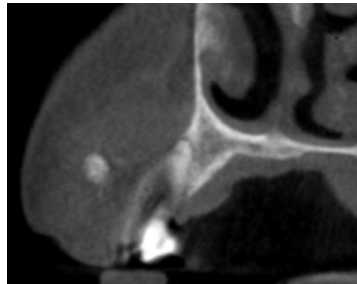


Fig. 13. CBCT

Pacific dental college and hospital
(A unit of pacific academy of higher education & research society)
 Airport road, Dahanu, Ulhaspur (raj.) 313024 Tel: 0229-2493530, 2493524, 2493582, Tdx Fax: 0229-2493508
DEPARTMENT OF ORAL AND MAXILLOFACIAL PATHOLOGY

Name-Bhagwani Bhai Lab no: HP 44/22
 Age/Sex: 45yrs/F Received date: 10/5/22
 Opd.no- 0205220155 Reporting date: 17/5/22
 Referred By- Dr.Rucha (Dept. Of Periodontics)

Provisional Diagnosis: Peripheral cement-ossifying fibroma irt 24-26 region

Gross pathology: Received 1 bit of tissue, firm in consistency, creamish brown in color with irregular margins and shape measuring 2.7 X 2 cm.

Histopathology

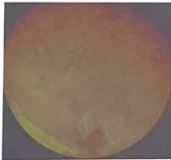
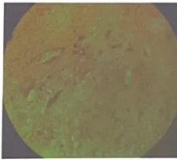




Fig 1 Fig 2

The given hematoxylin and eosin stained sections in:

- Scanner view reveal 1 bit of tissue with epithelium and connective tissue stroma.
- Low power view reveal connective tissue is composed of collagen fibers interspersed with fibro-cellular connective tissue interspersed with plump fibroblasts in between the collagen bundles, surfaced by parakeratinized stratified squamous epithelium. (Fig 1)
- Stroma showed trabeculae of lamellar bone and scattered basophilic, cementum like substances with chronic inflammatory cells.
- High power view confirms the above mentioned features. The chronic inflammatory infiltrate is chiefly composed of lymphocytes and plasma cells. (Fig 2)

Overall features are suggestive of
PERIPHERAL OSSIFYING FIBROMA.

A Clinicopathological correlation


 Signature

Note: This report is not valid for medico-legal purpose

Fig. 14. Histopathology report

3.1 Histopathological Report

Upon histopathological evaluation, it was discovered that the squamous epithelium was stratified and para keratinized and the connective tissue consisted of collagen fibers, fibro-cellular, and plump fibroblasts between collagen bundles. The stroma displayed lamellar bone trabeculae, erratic basophilic, cementum-like materials, and a persistent inflammatory infiltrate of lymphocytes and plasma cells [5] (Figs. 11,14).

4. DISCUSSION

With 2% prevalence across all oral biopsies, the peripheral ossifying fibroma is by far the most common lesion occurring in oral cavity. It is a clearly defined mass of tissue with a sessile or pedunculated base that is situated on the gingiva. POF typically measures less than 1.5 cm, but in some instances, sizes as large as 6 to 9 cm have also been documented.⁶ Although the etiopathogenesis of POF is still unresolved it is thought that periodontal ligament cells are the cause of the lesion in either case; some researchers believe that POF was a 'neoplastic process', while others thought it was a 'reactive process' [8]. POF is thought to originate from the PDL because POF exclusively occurs in the gingival; especially interdental papilla, the gingival area closer to the PDL, and some lesions have oxytalan fibres within the matrix that is mineralized [8]. Since many other conditions, such as pyogenic granuloma or peripheral giant cell granuloma, might display similar clinical manifestations and clinical courses, a conclusive diagnosis of POF cannot be established based solely on clinical findings. Therefore, a biopsy and histopathologic examination are necessary for the absolute diagnosis in order to be certain. Comprehensive overviews of the broad histologic spectrum of POF have been given by 'Buchner et al'. [9] All the fibromatous lesion will not show ossification or calcification [8]. Although POF does not always result in radiographic changes, occasionally a central point of radiopaque material may be visible, especially in more severe or mineralised lesions; which was present in our case [10,11] Surgical excision of POF is the absolute treatment after elimination of local etiological factors like dental plaque, calculus, ill-fitting dentures, and subpar restorations. In order to prevent recurrence, the periosteum and periodontal ligament beneath the lesion should be eliminated. Recurrence rates have been observed to range from 8% to 20% [9,10].

When 'Kennedy et al.' compared 'peripheral ossifying fibroma' and 'peripheral odontogenic fibroma', they discovered that factors like a high

female predilection and a peak incidence in the second decade of life suggest hormonal influences [3]. By analyzing biopsy tissues histopathologically, definitive diagnosis of POF can be made. When performing a microscopic assessment, the following characteristics are frequently seen: (1) Presence of connective tissue that is fibrous and benign, (2) irregular to frequent endothelial growth, (3) Mineralized substance that appears as mature, lamellar, or woven osteoid, cementum-like, or dystrophic calcified material. Inflammatory cells, either acute or chronic, can also be discovered in lesions [8]. In our case, most of the above histological features were present. In order to successfully treat POF, local surgical excision is advised. The management of a massive POF case was described by Gulati R et al. in which they have extracted the associated mobile teeth which was done in our case as well [12].

In this case, after surgical excision and extraction of teeth, we placed an L-PRF membrane over the exposed bone surface as described by *Friere A et al* in their case management of a giant POF with piezosurgery and PRF [13]. L-PRF is a simple to handle and a biomaterial that is created by centrifuging patient blood without the use of anticoagulants. It promotes faster healing and releases growth factors like 'platelet-derived growth factor', 'transforming growth factor beta 1', and 'vascular endothelial growth factor' for seven days. In conjunction with important coagulation and matrix proteins like thrombospondin-1, fibronectin, and vitronectin, the L-PRF membrane acts as an adjuvant for promoting and boosting up healing and/or tissue regeneration [6].

The case of gingival overgrowth that was described here has been identified histopathologically as Peripheral Ossifying Fibroma as no giant cells were found in the connective tissue stroma and the lesion had less vascularity, the possibility of peripheral giant cell granuloma and pyogenic granuloma was ruled out. In the case described here, all the clinical, radiographic and histological findings corroborates with the finding available in the literature.

The patient underwent a successful excision of POF, was kept on periodic maintenance therapy for two months to monitor for signs of recurrence.

5. CONCLUSION

POF is a chronic lesion that develops gradually into larger dimensions causing displacement of

teeth as well as functional and esthetic impairment. POF can be misdiagnosed with other reactive lesion, so a histopathological examination of the specimen is required for an accurate diagnosis. The lesion can be removed successfully with a surgical excision along with PRF placement for better soft tissue healing, as illustrated herein. The possibility of recurrence is significant in presence of local factors and incomplete surgical removal hence in order to prevent the recurrence, the lesion should be completely removed along with the periosteum and the nearby tissues.

CONSENT

As per international standard or university standard, patients' written consent has been collected and preserved by the author(s).

ETHICAL APPROVAL

As per international standard or university standard written ethical approval has been collected and preserved by the author(s).

COMPETING INTERESTS

Authors have declared that no competing interests exist.

REFERENCES

1. Farquhar T, MacLellan J, Dymont H, Anderson RD. Peripheral ossifying fibroma: a case report. *J Can Dent Assoc.* 2008;74(9):809-812.
2. Keluskar V, Byakodi R, Shah N. Peripheral ossifying fibroma. *Journal of Indian Academy of Oral Medicine and Radiology.* 2008;20(2):54.
3. Kenney JN, Kaugars GE, Abbey LM. Comparison between the peripheral ossifying fibroma and peripheral odontogenic fibroma. *Journal of Oral and Maxillofacial Surgery.* 1989;47(4):378-382.
4. Das UM, Azher U. Peripheral ossifying fibroma. *Journal of Indian Society of Pedodontics and Preventive Dentistry.* 2009;27(1):49.
5. Rajendran R, Sivapathasundharam B, Shafer WG. *Shafer's textbook of oral pathology* (6th ed ed.). New Delhi: Elsevier/Reed Elsevier; 2009.
6. Borie E, Oliví DG, Orsi IA, Garlet K, Weber B, Beltrán V, Fuentes R. Platelet-rich fibrin application in dentistry: a literature review. *Int J Clin Exp Med.* 2015;8(5):7922-7929.
7. Baghani Z, Kadkhodazadeh M. Periodontal dressing: a review article. *J Dent Res Dent Clin Dent Prospects.* 2013;7(4):183-191.
8. Kumar SK, Ram S, Jorgensen MG, Shuler CF, Sedghizadeh PP. Multicentric peripheral ossifying fibroma. *Journal of Oral Science.* 2006;48(4):239-243.
9. Buchner A, Hansen LS. The histomorphologic spectrum of peripheral ossifying fibroma. *Oral Surgery Oral Medicine Oral Pathology.* 1987;63(4):452-461.
10. Cuisia Z, Brannon R. Peripheral ossifying fibroma--a clinical evaluation of 134 pediatric cases. *Pediatric Dentistry.* 2001;23(3):245-248.
11. Flaitz C. Peripheral ossifying fibroma of the maxillary gingiva. *American Journal of Dentistry.* 2001;14(1):56.
12. Gulati R, Khetarpal S, Ratre MS, Solanki M. Management of massive peripheral ossifying fibroma using diode laser. *J Indian Soc Periodontol.* 2019;23(2):177-180. DOI:10.4103/jisp.jisp_431_18
13. Freire AEN, da Silva VSA, Pereira AAC, Ribeiro Junior NV, de Carli ML, Sperandio FF, Hanemann JAC. Giant Peripheral ossifying fibroma treated with piezosurgery and platelet-rich fibrin: a rare case report. *Clin Adv Periodontics.* 2019;9(1):15-19. DOI:10.1002/cap.10042