

# Original Research Article

## **EFFECTS OF 5-7, DIHYDROXY FLAVONE ON HIPPOCAMPUS OF WISTAR RATS WITH DOXORUBICIN INDUCED COGNITIVE IMPAIRMENT.**

### **ABSTRACT**

Concern is increasing regarding the effect of chemotherapy induced cognitive impairment on oncology patients. This sought to investigate the effect of 5-7, dihydroxyflavone on the hippocampus of wistar rats with Doxorubicin induced cognitive impairment. 30 male Wistar rats were procured and acclimatized for 14 days with feed and water, they were divided into six (6) experimental groups of five (5) animals each. Group 1 served as normal control. Group 2 was induced with 2mg/kg of DOX and was untreated. Group 3 received 50mg/kg of Chrysin. Groups 4, 5 and 6 were induced and treated with Chrysin at doses of 50mg/kg, 100mg/kg, and 150mg/kg respectively. The body weight of the animals were recorded three (3) times before and after induction and then recorded again at the end of the 21 days treatment. At the end of the experiment, there were significantly increase in body weight. The increase was more pronounce in group 1 and group 2. In the oxidative stress analysis and analysis on inflammatory cytokines 1 and 6 carried out, there was a significant increase in the levels compared to the control group 1. In the neurobehavioural test, group 6 had a high spontaneous alternation percentage compared to other groups. The treatment with Chrysin significantly had an ameliorative effect on the treated animal groups and in group 3. The result from this work suggest that Chrysin extract had an ameliorative effect on cognitive impairment of the hippocampus.

**Keywords:** Chrysin, Cognitive impairment, hippocampus, chemotherapy, oncology.

### **1. INTRODUCTION**

Doxorubicin (DOX) is an effective anticancer agent that revered extensive recognition in recent years for the management of several types of cancers. However, it's harmful perspective i.e., neurotoxicity, cardiotoxicity, hepatic damages, and nephrotoxicity have reticent its clinical practice [1]. DOX-impelled neurotoxicity may be an element of a multi-organ impairment facilitated primarily due to the free radicals' accumulation, ultimately inducing the membrane lipid peroxidation [2]. Doxorubicin may have cognitive deficits that manifest as impairments in learning, reasoning, attention, and memory. Then phenomenon of chemotherapy-related cognitive impairment (CRCI) or chemo-brain. Doxorubicin, a commonly used drug in adjuvant chemotherapy for patients with breast cancer, has been reported to induce chemo-brain through a variety of mechanisms including DNA damage, oxidative stress, inflammation, dysregulation of apoptosis and autophagy, changes in neurotransmitter levels, mitochondrial dysfunction, glial cell interactions, neurogenesis inhibition, and epigenetic factors. Doxorubicin belongs to the anthracycline class and is commonly used in the adjuvant chemotherapy

regimens for breast cancer [3]. Numerous studies have shown that tyrosine kinases, antimetabolites, microtubule inhibitors, and alkylating agents all can induce neurotoxicity [4]. Doxorubicin exerts its antitumor effects through DNA insertion and inhibition of topoisomerase II. In addition, Doxorubicin causes the production of invasive systemic reactive oxygen species (ROS) [5]. Notably, despite its limited passage through the blood-brain barrier (BBB), Doxorubicin can still cause severe neurotoxicity in the brain, and several clinical studies reported that patients of all ages treated with Doxorubicin exhibited impaired ability in cognitive assessments [6].

The Hippocampus is one of the structures closely associated with spatial processing and memory formation, and the integration of mature neurons in the circuit plays a key role in hippocampal neurogenesis [7].

Chrysin belongs to a class of chemicals called flavonoids. It occurs naturally in various plants and substances, such as the passionflower, silver linden, and some geranium species; and in honey and bee propolis (glue). Chrysin is a flavone under the category of flavonoids. It is widely distributed in plants and has been studied for antioxidant, antispasmodic, anxiolytic, and anti-inflammatory activities. The anti-inflammatory effect of Chrysin was found most likely by the inhibition of COX-2 expression and via IL-6 signaling.

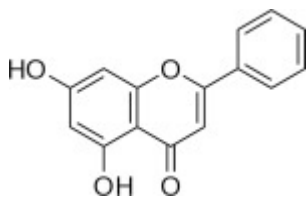


Fig.1.1. 5, 7-dihydroxy flavone (Chrysin), chemical structure. (Elsevier, 2022).

Structure-activity relationships have revealed that the chemical structure of Chrysin meets the key structural requirements of flavonoids for potent cytotoxicity in leukemia cells [8].

Doxorubicin is an anti-cancer drug, and when administered can cause multi-organ toxicities in various patients. Though a large number of plants worldwide show strong antioxidant and anti-inflammatory activities [9], Chrysin has been attributed with anti-inflammatory, anti-oxidative and anti-cancerous properties and so, it is to be used in this experiment as a possible protective agent, or as an ameliorative agent. The hippocampus of Alzheimer's disease brain has been shown to be highly oxidized compared to age-matched controls [10], and the hippocampus is a soft tissue and can easily be damaged. This present study has been designed to investigate the ameliorative effects (anti-inflammatory and anti-oxidative) of Chrysin on hippocampus of rats with Doxorubicin induced cognitive impairment.

## 2. MATERIALS AND METHODS

### 2.1. PROCUREMENT OF CHEMICAL

The 5, 7-dihydroxyflavone (Chrysin) was gotten from Sigma Aldrich Company, 3050 Spruce Street, St. Louis, USA. Doxorubicin was procured from Open haven Pharmaceutical Company, Enugu, Nigeria.

## 2.2. EXPERIMENTAL ANIMAL

A total of thirty male albino wistar rats weighing (150-200g) was used for this study. The animals were housed under normal conditions and were acclimatized for two weeks prior to the experiment. At the end of the acclimatization period, the animals were randomly divided into six groups of five rats each, labeled group 1 to 6. The body weights of the animals were measured and recorded using electric weighing scale; before administration, during administration and after administration.

## 2.3. EXPERIMENTAL DESIGN

**Table 1. The Experimental Design**

EXPERIMENTAL GROUP	NO OF RATS	ADMINISTRATION	TREATMENT
<b>Group 1</b> (Negative control)	5	CONTROL (Normal Saline)	Distilled water and food pellet only will be given for 21 days.
<b>Group 2</b> (Positive Control) (DXR only)	5	Doxorubicin (2mg/kg)	(2mg/kg) body weight of Doxorubicin given weekly without treatment.
<b>Group 3</b> (Chrysin only)	5	Chrysin (150mg/kg)	(150mg/kg) body Weight of Chrysin given without treatment.
<b>Group 4</b> (DXR-Low-dose)	5	Doxorubicin (2mg/kg) + Chrysin (50mg/kg)	Receives a weekly dose of 3mg/kg and treated with 50mg/kg Chrysin for 21 days.
<b>Group 5</b> (DXR-medium dose)	5	Doxorubicin (2mg/kg) + Chrysin 100mg/kg	Receives a weekly dose of 2mg/kg and treated with 100mg/kg Chrysin for 21 days.
<b>Group 6</b> ( DXR-high dose)	5	Doxorubicin (2mg/kg) + (150mg/kg)	Receives a weekly dose of 2mg/kg and treated with 150mg/kg of Chrysin for 21 days.

**DXR= Doxorubicin**

The dose of Doxorubicin was given according to the weight of animals in each group [11].

#### **2.4. ETHICAL APPROVAL**

The ethical approval was from Ethic and Research Committee of Faculty of Basic Medical Science, College of Medicine, Enugu State University of Science and Technology, ESUT.

#### **2.5. SACRIFICE OF EXPERIMENTAL ANIMAL**

Twenty-four hours after the last administration for various groups, the rats were weighed and sacrificed by cervical dislocation. A mild incision was made through the cranium. The hippocampus was isolated from the brain, weighed and then fixed for histological investigations. Blood was collected via retro-orbital sinus bleeding using capillary tube, and clotting was allowed for about 2 hours. Thereafter, the clotted blood was centrifuged for 10mins to recover serum from the cell of blood. Serum was separated from the clotted blood for biochemical analysis.

#### **2.6. BODY WEIGHT MEASUREMENT**

The body weight of all the rats was recorded three times, (weight before the induction, weight during the induction and weight after induction) using a digital electronic scale. The weights of the rats were recorded to the nearest gram.

#### **2.7. BIOCHEMICAL STUDY**

Blood samples were collected from all groups through retro-orbital sinus, using capillary tube. The blood samples were spun using an 800D centrifuge machine. After which the serum was separated from the plasma. The serum is then collected and taken to College Biochemistry Laboratory where the analysis was carried out.

#### **2.8. HISTOLOGICAL PROCEDURE**

The hippocampus was subjected to histological studies, hippocampal tissues from all groups was fixed in 10% formalin solution in phosphate buffer and tissue processed using paraffin wax embedding medium. Tissues blocks were microtome using rotator microtome and sections stained with routine H&E stain for histological examination.

#### **2.9. DETRMINATION OF ANTI-INFLAMATORY CYTOKINES**

- **IL-1 $\beta$**

In The BioVendor Human IL-1 Beta ELISA, samples and standards were incubated in a microplate wells pre-coated with monoclonal anti-human IL-1 Beta antibody. After 60 minutes' incubation and a washing, biotin –labelled monoclonal anti-human IL-1 Beta antibody is added and incubated with captured IL-1

Beta for 60 minutes. After another washing, the streptavidin-HRP conjugate is allowed to react with the substrate solution. The reaction is stopped by addition of acidic solution and absorbance of the resulting yellow product is measured. The absorbance is proportional to the concentration of IL-6 Beta. A standard curve is constructed by plotting absorbance values against concentrations of IL-6 Beta standards, and concentrations of unknown samples are determined using this standard curve.

- **1L-6**

An Elisa kit rat IL-6 platinum ELISA (Bender Medsystems, Vienna, Austria) as per the manufacturer's instructions. We washed all the wells with buffer solutions 1%. Then we added 100 cc assay buffer to the blank wells before putting them under room temperature (RT) for two hours. The next thing was to wash the wells using buffer solution 6 times and add 100 cc HRP and leave them for 1 hour RT. After washing, we added 100 cc TMB to the wells for 10 minutes RT. Then add 100 cc stop solution to them and read the strip using Elisa reading machine at wavelength of 450nm.

## **2.10. CASPASE-3**

The activity of caspase enzyme in the brain tissue homogenate is measured, according to the method of [12]. The cells that are suspected or have been induced to undergo apoptosis are first lysed to collect their intracellular contents. The cell lysate can then be tested for protease activity by the addition of a caspase-3 specific peptide that is conjugated to the color reporter molecule p-nitroaniline (pNA). The cleavage of the peptide by the caspase releases the chromophore pNA, which can be quantitated spectrophotometrically at a wavelength of 405 nm. The level of caspase enzymatic activity in the cell lysate is directly proportional to the color reaction.

## **2.11. STATISTICAL ANALYSIS**

Data that was collected from serum analysis will be analyzed using Statistical Package and Social Science (SPSS) version 23 and evaluated using ANOVA; followed by Post hoc test. The results will be expressed as mean  $\pm$  Standard Deviation (SD) and also presented in a graph.  $p < 0.05$  will be considered significant.

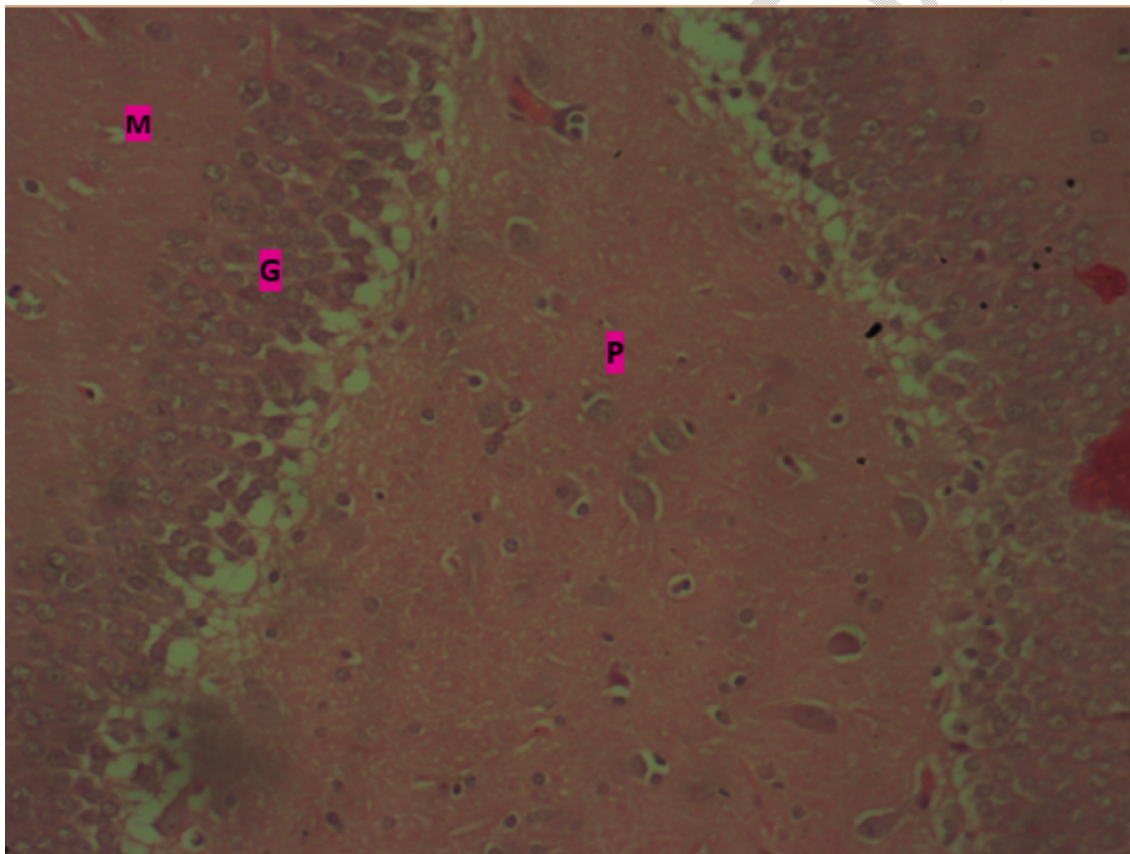
## **2.12. NEUROBEHAVIOURAL TEST**

The Y-maze and Object Recognition Task (ORT), was used to study the behaviors of the wistar rats as related to cognitive impairment. For Y-maze, testing occurs in a Y-shaped maze with three white, opaque plastic arms at a 120° angle from each other. After induction to the center of the maze, the

animal is allowed to freely explore the three arms. Over the course of multiple arm entries, the animal will show a tendency to enter a less recently visited arm. The entry is considered when all four limbs are within the arm. The alternation percentage is calculated by dividing the number of alternations by number of possible triads x 100. The ORT is fairly simple and can be completed over 3 days: habituation day, training day, and testing day. In habituation day, the animal is allowed to explore an empty field within the space where the objects will be placed. During training, the rat is allowed to explore two identical objects. On test day, one of the training objects is replaced with a novel object. ORT was originally described by Ennaceur and Delacour in 1988. The Statistics of the rat's memory performance was calculated using one-way ANOVA.

### 3. RESULTS

#### 3.1. HISTOLOGICAL ANALYSIS



**Plate 1 :**

Photomicrograph of the dentate gyrus of the hippocampus showing neuronal cells in the dentate polymorphic layer (p), dentate granular layer (g) and in the dentate molecular layer (m). General cyto-architecture appears normal. h & e. x200

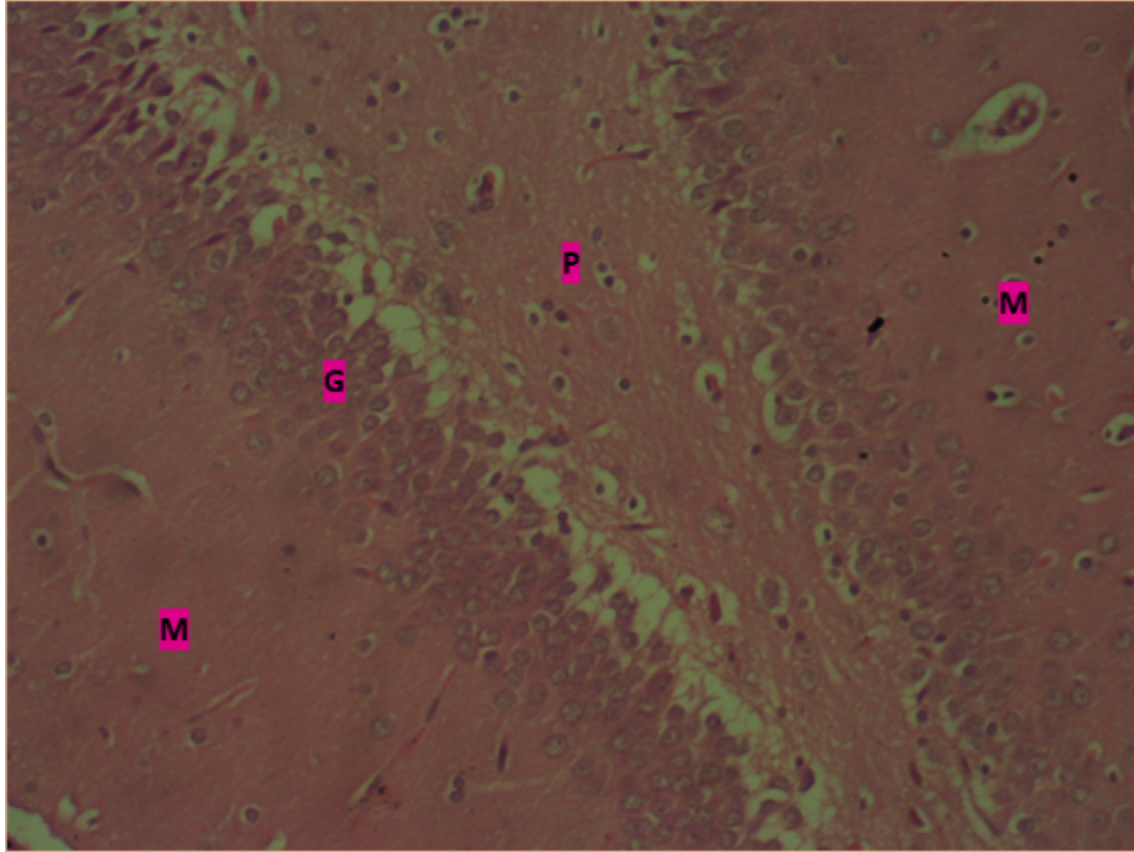
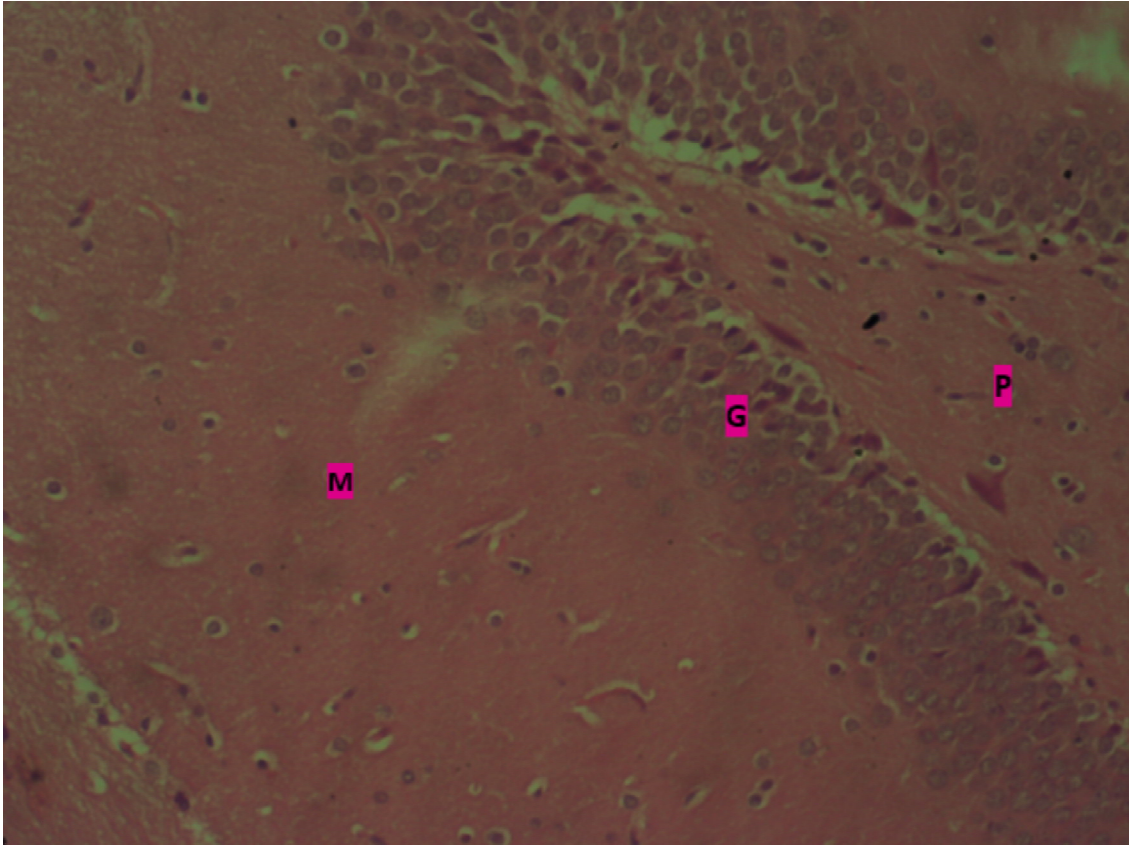


Plate 2:

Photomicrograph of the dentate gyrus of the hippocampus showing neuronal cells in the dentate polymorphic layer (p), dentate granular layer (g) and in the dentate molecular layer (m). General cyto-architecture shows slight shrunken, and degeneration of pyramidal neurons. h & e. x200



**Plate 3 :**

Photomicrograph of the dentate gyrus of the hippocampus showing neuronal cells in the dentate polymorphic layer (p), dentate granular layer (g) and in the dentate molecular layer (m). General cyto-architecture appears normal. h & e. x200

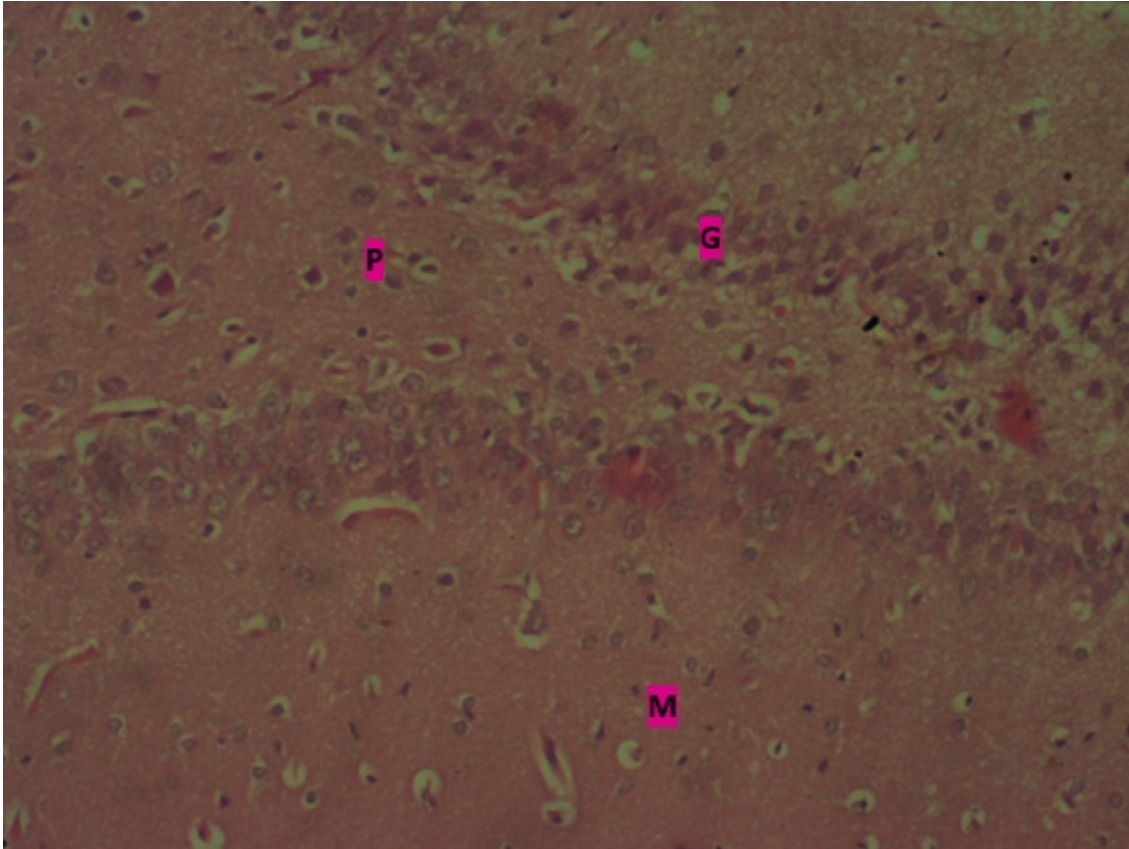


Plate 4

Photomicrograph of the dentate gyrus of the hippocampus showing neuronal cells in the dentate polymorphic layer (p), dentate granular layer (g) and in the dentate molecular layer (m). General cyto-architecture appears normal. h & e. x200

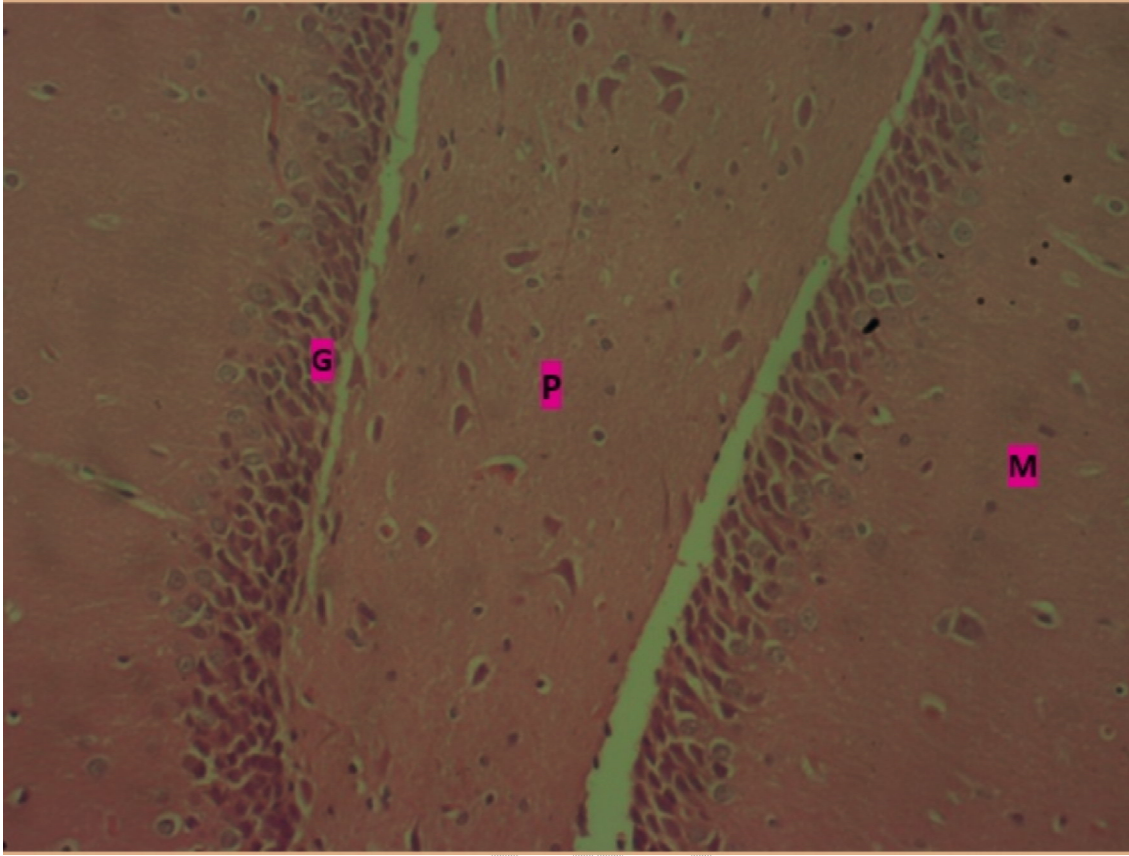


Plate 5

Photomicrograph of the dentate gyrus of the hippocampus showing neuronal cells in the dentate polymorphic layer (p), dentate granular layer (g) and in the dentate molecular layer (m). General cyto-architecture appears normal. h & e. x200

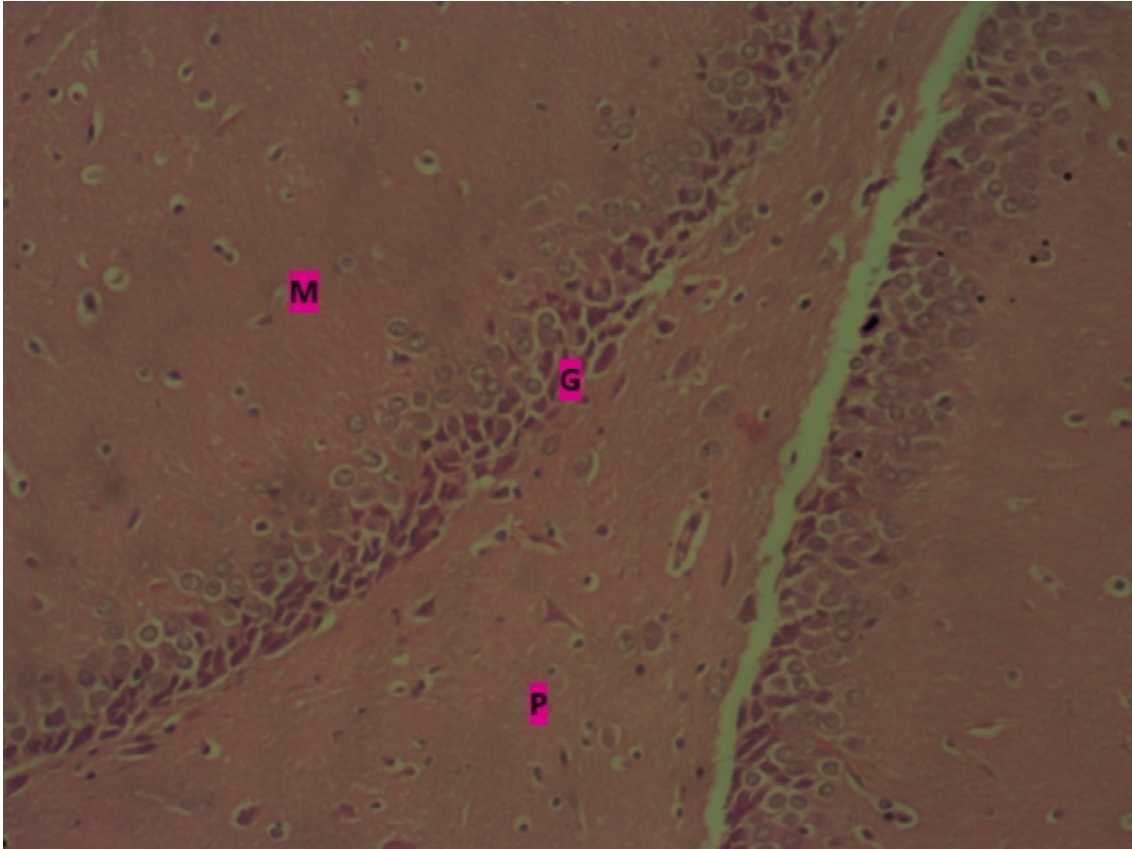


Plate 6

Photomicrograph of the dentate gyrus of the hippocampus showing neuronal cells in the dentate polymorphic layer (p), dentate granular layer (g) and in the dentate molecular layer (m). General cyto-architecture appears normal. h & e. x200

**TABLE 2: RESULT OF THE MEAN ± STANDARD DEVIATION OF THE HIPPOCAMPUS OXIDATIVE STRESS MARKERS ANALYSIS**

GROUPS	SUPEROXIDE DISMUTASE	CATALASE	MALONDIALDEHYDE	GLUTATHIONE
1	12.07±0.36	36.61±0.90	7.07±0.67	26.67±0.65
2	8.92±0.96	30.17±1.90	8.97±0.18	22.66±0.15
3	11.94±0.32*	34.42±1.10*	7.43±0.24*	25.43±0.41*
4	10.67±0.21*	32.93±1.80* <sup>β</sup>	8.44±0.13* <sup>β</sup>	24.84±0.75* <sup>β</sup>
5	10.10±0.48*	34.63±0.60*	7.82±0.13*	25.19±0.15
6	11.46±0.46*	33.91±0.30* <sup>β</sup>	8.08±0.11*	24.61±0.94* <sup>β</sup>
7	11.56±0.91*	32.71±0.80* <sup>β</sup>	7.91±0.29* <sup>β</sup>	24.61±0.51* <sup>β</sup>
<b>TOTAL (P)</b>	11.06±1.09	33.67±2.08	7.97±0.64	24.92±1.23

**P<0.05**

Values were expressed as Mean ± SD; \*P<0.05 showed a significant difference compared with the control group 1; <sup>β</sup>P<0.05 showed a significant difference with groups 4, 6 and 7, compared with group 2 respectively.

**TABLE 3: RESULT OF THE MEAN ± STANDARD DEVIATION OF THE HIPPOCAMPUS INFLAMMATORY CYTOKINES ANALYSIS**

GROUPS	IL-1	IL-6
1	131.1±9.27	204.4±5.36
2	182.6±9.27	238.5±5.96
3	138.6±6.62*	215.3±0.51
4	157.3±2.65* <sup>β</sup>	219.9±3.58* <sup>β</sup>
5	150.3±8.61*	222.9±4.17* <sup>β</sup>
6	148.9±5.21*	222.5±9.53* <sup>β</sup>
7	150.3±3.31*	213.2±3.58*
<b>TOTAL (P)</b>	151.3±16.46	219.5±10.9

**P<0.05**

Values were expressed as Mean ± SD; \*P<0.05 showed a significant difference compared with the control group 1; <sup>β</sup>P<0.05 showed a significant difference with group 4, compared with group 2 respectively.

**TABLE 4: RESULT OF THE MEAN ± STANDARD DEVIATION OF THE HIPPOCAMPUS CASPASE-3 ANALYSIS**

GROUPS	CASPASE-3
1	4.98±0.29
2	6.91±0.19
3	5.41±0.32*
4	5.52±0.16*
5	5.61±0.22
6	6.07±0.22 <sup>β</sup>

7

5.93±0.16

TOTAL (P)

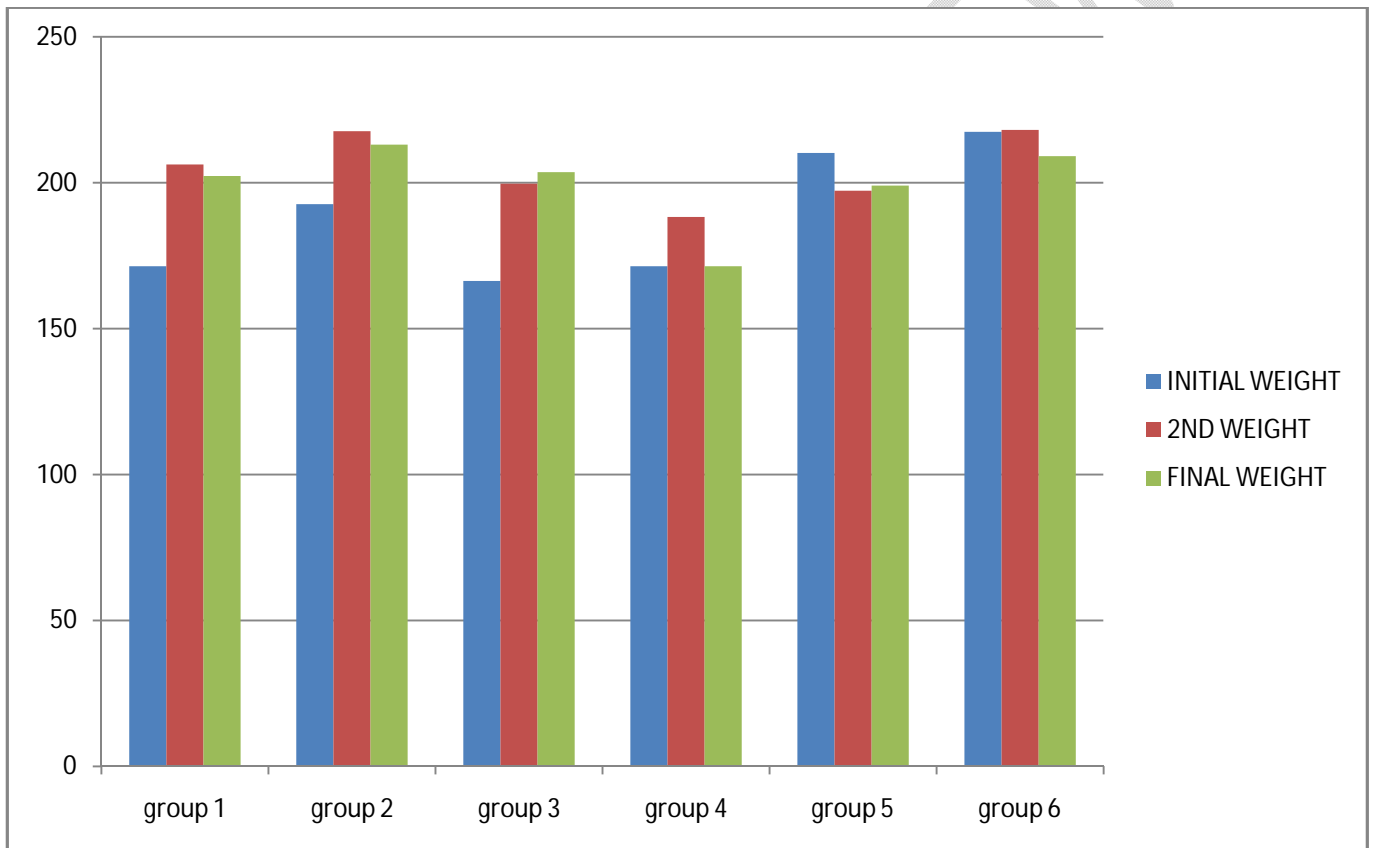
5.78±0.61

P<0.05

Values were expressed as Mean ± SD; \*P<0.05 showed a significant difference with groups 3 and 4, compared with the control group 1; <sup>β</sup>P<0.05 showed a significant difference with group 6, compared with group 2 respectively.

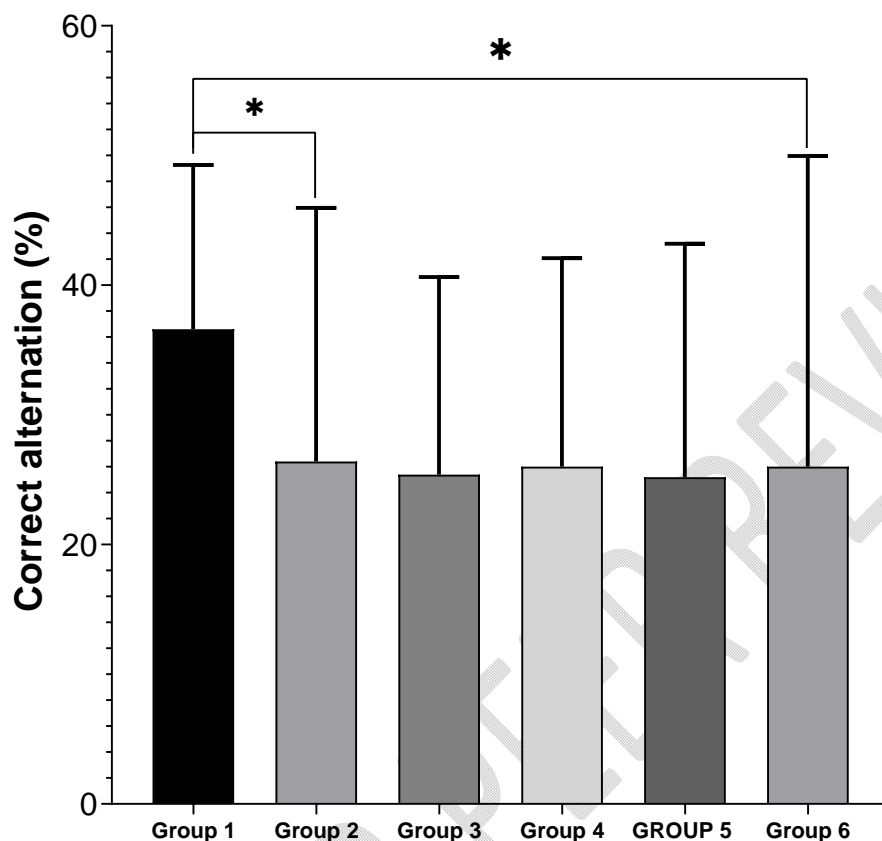
### 3.2. CHART FOR BODY WEIGHT MEASUREMENTS

Graph 1 : Bar graph showing body weight measurements



The above chart shows increase in body weight measurements in all the groups except for group 5, which received a medium dose of Chrysin, 100mg/kg. Weight increase was more in the control group and group 3 (Chrysin only).

### 3.3. RESULT FOR NEUROBEHAVIOURAL TEST



**Graph 2 : Bar graph showing Neurobehavioural Test result**

Percentage correct alternation in the Y-maze test. There was a significant decrease in percentage correct alternation in group 2 (DOX only) when compared with the group 1 (normal control) (\* $P < 0.05$ ). Also, group 6 (High dose Chrysin + DOX) had a significantly lower percentage correct alternation relative to the control (\* $P < 0.05$ ).

## 4. DISCUSSIONS

The aim of the present study is to determine the effect of 5, 7-dihydroxy flavone on the hippocampus of rats with Dox-induced cognitive impairment. Nowadays, medicine from plants sources play a vital role in healthcare management. Chrysin, a plant flavonoid, possesses a wide range of pharmacological activities. In Humans, Chrysin is used for bodybuilding; for treatment of anxiety, inflammation, gout, HIV/AIDS, erectile dysfunction, and baldness; and for preventing cancer. Chrysin seems to decrease the effects of estrogen in the female body, [13].

Athletes are interested in Chrysin for bodybuilding because laboratory research suggested that Chrysin might increase the male hormone called testosterone and improve bodybuilding results. But research in humans hasn't found any effect on testosterone levels. The amount of Chrysin that is absorbed from the intestine may be very small, which would make treatment effects unlikely [14].

Increased Hippocampal activity is observed in many conditions that increase the risk of Alzheimer's disease, but whether this activity is pathological or compensatory has been unclear. In a small study in patients with amnesic mild cognitive impairment, the antiepileptic drug levetiracetam reduce hippocampal activity and improved performance in a cognitive test compared with a placebo. Strategies to lower hippocampal activity, preserve cognitive function in prodromal Alzheimer's disease [15]. The hippocampus is one of the earliest affected brain regions in Alzheimer's disease and its dysfunction is believed to underlie the core feature of the disease-memory impairment. Alzheimer's disease is the most common type of dementia in people over the age of 65, with a lifetime risk of 10.5% [16].

The histopathological examination carried out on the hippocampal tissues of various groups. In Group 1, the dentate gyrus of the hippocampus shows neuronal cells in the dentate polymorphic layer, dentate granular layer and in the dentate molecular layer and the general cyto-architecture appears normal. The Group 2, Doxorubicin only, shows the dentate gyrus of the hippocampus having neuronal cells in the dentate polymorphic layer, dentate granular layer and in the dentate molecular layer and the general cyto-architecture shows slight shrunken, and degenerated pyramidal neurons. Group 3 was given Chrysin only. The dentate gyrus of the hippocampus shows neuronal cells in the dentate polymorphic layer, dentate granular layer and in the dentate molecular layer and the general cyto-architecture appears normal. This indicates that 150mg/kg body Weight of Chrysin given without treatment caused no histopathological changes in the hippocampal tissue. This agrees to a previous investigation by Rosen et al., [17], where 50mg/kg of Chrysin formed a protective cover to the hippocampus after the induction of D-galactose which causes brain aging. The ameliorative groups (4, 5, and 6) treated with increasing doses of Chrysin; low (50mg/kg), medium (100mg/kg) and high (150mg/kg) doses respectively, after induction of 2mg/kg of Doxorubicin show no significant therapeutic changes as the histomorphology of the hippocampus remains the same when compared to the normal control. This agrees with a previous study carried out by [18], where male Dawley rats were treated with Chrysin (50mg/kg, 4 times in a week) after induction of Doxorubicin (5mg/kg, once a week).

Although abnormalities in SOD1 and SOD3 have been variably implicated in neuromuscular and cardiovascular conditions [19, 20], manganese SOD (also referred to as SOD2) is likely most relevant to brain integrity due to localization within the mitochondria matrix [21]. Catalase is a critical antioxidant for monitoring hydrogen peroxide concentrations in the intracellular space by reducing peroxisomal hydrogen peroxide to oxygen and water [22]. Similarly, transgenic mice with overexpressed mitochondria catalase are associated with decreased oxidative damage, longer life span, and neuroprotection against cerebral ischemia [23, 24]. Melondialdehyde has been widely used for many years as a convenient biomarker for lipid peroxidation of omega-3 and omega-6 fatty acids because of its facile reaction with thiobarbituric acid (TBA) [25, 26]. Glutathione peroxidase, which is a selenium-dependent enzyme that detoxifies hydrogen peroxide in the cytosol and mitochondria and is responsible for recycling tripeptide glutathione [27]. The present study shows a significant increase in all the oxidative stress markers (table 4) when compared to the control group 1. Previous investigators have similarly demonstrated the antioxidant properties of Chrysin using SOD as an oxidative stress marker to assess tissues oxidative status in rats following dietary toxicity [28, 29].

IL-1 acts on the subsets of hippocampal neurons to influence cognitive and mood alternations with stress showed reduced social interactions with stress. Stress-induced monocyte trafficking to the brain was also blocked by IL-1 knockout [30]. Interleukin-6 are likely mediators of immune-to-brain communication, with peripheral immune activation being associated with behavioral, affective and cognitive disturbances, penetrating the blood brain barrier directly via active transport mechanism [31], or indirectly via activation of the afferent vagus nerve [32] to stimulate the production of central proinflammatory cytokines, including IL-6 in discrete brain regions [32]. The results of the present study show significant increase in the anti-inflammatory markers, which implies that Chrysin has an anti-inflammatory effect. This agrees to a study carried out by [33], where Chrysin treatment significantly inhibited the release of nitric oxide and proinflammatory cytokines such as IL-1 and TNF- $\alpha$  in lipopolysaccharides stimulated ganglia.

CASPASE-3 has been implicated in neurodegenerative processes, aging and Alzheimer's disease (AD). However, emerging evidence suggests that in addition to their classical role in cell death caspases have a key role in modulating synaptic function. The results of the present study show significant increase in the caspase-3, which implies that Chrysin administration has an anticancer efficacy. Previous studies reported the pro apoptotic effect of Chrysin in breast cancer, cervical cancer, leukemia, lung cancer and colon cancer in vitro [18]. A study by Zang *et al.* has demonstrated that Chrysin exhibited potential in anti-cancer effects in human cervical carcinoma cells [12].

Behavioral studies were conducted to determine the effect of doxorubicin, with Chrysin intervention. Wistar rats were subjected to Y maze and Novel Object Recognition to test for cognitive impairment in the hippocampus. The result shows a significant decrease in percentage correct alternation in rats in group 2 which received Doxorubicin only, when compared with the group 1 (normal control). Group 6 which received high dose of Chrysin + Doxorubicin, had a significantly lower percentage correct alternation relative to the control group.

Weight increase was more in the control group 1 and group 3 which received only Chrysin compared to the Dox-induced groups, and least was the group 5 which received medium dose of Chrysin (100mg/kg) + Doxorubicin (2mg/kg).

## **5. CONCLUSION**

This study shows that Chrysin was effective in treatment of Doxorubicin induced cognitive impairment in the hippocampus of Wistar rats.

## REFERENCES

1. Su, R., Murdock, C. D., and Rounds, J. Person-Environment fit. American Psychological Association handbook of Career Inventions 2015;81-98.
2. Steliana Ghibu, Stephanie Delemeasure, Carole Richard, Jean-Claude Guiland, Laurent Martin, Segolene Gambert, Luc Rochette, Cayherine Vergely. General oxidative stress during doxorubicin-induced cardiotoxicity in rats: absence of cardioprotein and low antioxidant efficiency of alpha-lipoic acid. *Biochimie* 2012; 94 (4), 932-939.
3. Laurent Chorro, Ayrelien Sarde, Mei Li, Kevin J Woollard, Pierre Chambon, Bernard Milissen, Adrien Kissenpfenning, Jean-Baptiste Barbaroux *et al.* langerhan cell (LC) proliferation mediates neonatal development homeostasis, and inflammation associated expansion of epidermal LC network. *Journal of Experimental Medicine* 2009; 206 (13), 3089-3100.
4. John V MccGowan, Robin Chung, Angshuman Maulik, Izabela Piotrowska, J Malcolm Walker, Derek M Yellon. Anthracycline chemotherapy and cardiotoxicity. *Cardiovascular drugs and therapy* 2017; 31 (1), 63-75.
5. Roland Vencovsky, Magno Anthonio Patto Ramalho, Fernando Henrique Ribeiro Barrozo Toledo. Contribution and perspectives of quantitative genetics to plant breeding in brazil. *Crop breeding and applied Biotechnology* 2012; 12, 07-14.
6. Wei Deng, James B Aimone, Fred H Gage. New neurons and new memories: how does adult hippocampal neurogenesis affect learning and memory? *Nature reviews neuroscience* 2010; 11 (5), 339-350.
7. Bernada Majc, Tilen Sever, Miki zaric, Barbara Breznik, Boris Turk, Tamara T Lah. Epithelial-to-mesenchymal transition as the driver of changing carcinoma and glioblastoma microenvironment. *Biochimica Et Biophysica Acta (BBA)-molecular Cell Research* 2020; 1867 (10), 118782.

8. Victor Udo Nna, Ainul Bahiyah AbuBakar, AZlina Ahmed, Chinedum Ogonnaya Eleazu, Mahaneem Mohamed. Oxidative stress, NF-kb-mediated inflammation and apoptosis in the testes of streptozocin-induced diabetic rats: combined protective effects of Malaysian propolis and metformin. *Antioxidants* 2019; 8 (10), 465.
9. Jennifer J Vasterling, Chris Brewin. *Neuropsychology of PTSD: Biological, cognitive, and clinical perspectives*. Guilford press 2005.
10. Atinke Adeyemi. *Journal of Educational and Social Research* 2013; 8 (3), 157.
11. George L Ellman, K Diane Courtney, Valentino Andres Jr, Robert M Featherstone. A new and rapid colorimetric determination of acetylcholinesterase activity. *Biochemical pharmacology* 1961; 7 (2). 88-95.
12. WebMD Scientific American. *Medicine and Health Science Books* 1996-2022.
13. International Health Organisations-WHO 2005; 91.
14. Arnold Bakker, Gregory L Krauss, Marilyn S Albert, Caroline L Speck, Lauren R Jones, Craig E Stark, Micheal A Yassa, Sussan S Bassett. Reduction of hippocampal hyperactivity improves cognition in amnesic mild cognitive impairment. *Neuron* 2012; 74 (3), 467-474.
15. Reisa A Sperling, Paul S Aisen, laurel A Beckett, David A Bennett, Suzanne Craft, Anne M Fagan, Christopher C Rowe. Toward defining the preclinical stages of Alzheimer's Association workgroups on diagnostic guidelines. *Alzheimer and Dementia* 2011; 7 (3), 280-292.
16. Yeon Hee Park, Samir Lal, Jeong Eon Lee, Yoon-la Choi, Ji wen, Sripad Ram, Ying Ding, Seo-Hyeon Lee, Eric Powell, Se kyung Lee, Jong Han Yu. Chemotherapy induces dynamic responses in breast cancers that impact treatment outcome. *Nature communications* 2020; 11 (1), 1-14.
17. Michael A Rosen, Deborah DiagzGrandos, Aaron S Dietz, Lauren E Benishek, David Thompson, Peter J Pronovost, Sallie J Weaver. Teamwork in healthcare: key discoveries enabling safer, high quality care. *American Psychologist* 2018; 73 (4), 433.

18. Tohru Fukai, Rodney J Folz, Ulf Landmesser, David G Harrison. Extracellular superoxide dismutase and cardiovascular disease. *Cardiovascular research* 2002; 55 (2), 239-249.
19. Kavitha Palaniappan, Richard A Holley. Use of natural antimicrobials to increase antibiotic susceptibility of drug resistant bacteria. *International journal of food microbiology* 2010; 140 (2-3), 164-168.
20. Oxidative changes and possible effect of polymorphism of antioxidant enzymes in neurodegenerative disease. *Neurodegenerative sciences* 2013.
21. Samuel E Schriener, Nancy J Linford, George M Martin, Piper Treuting, Charles E Ogburn, Mary Emond, Pinar E Coskun, Warren Ladiges, Norman Wolf. Extension of murine life span by overexpressing of catalase targeted to mitochondria. *Science* 2005; 308 (5730), 1909-1911.
22. Neuroprotective effect of hydrogen peroxide on an invitro model brain ischemia. *British journal of pharmacology* . 153(5):1022-9.
23. Marina R Barbosa. Hydrogen peroxide production regulates the mitochondrial function in insulin resistant muscle cells: effect of catalase overexpression. *Biopsychology Acta* 2013.
24. Regina Brigelius-Flohe, Maret G. Traber. Vitamin E: function and metabolism. *The FASEB journal* 1999;13(10):1145-1155.
25. T Walle, Y Otake, JA Brubaker, UK Walle, PV Halushka. Disposition and metabolism of the flavonoid chrysin in normal volunteers. *British journal of clinical pharmacology* 2001;51(2):143-146.
26. PA Tsuji, T walle. Cytotoxic effects of the dietary flavones chrysin and apigenin in a normal trout liver cell line. *Chemico-biological interactions* 2008;171(1):37-44.
27. Eric S Wohleb, Jenna M Patterson, Vikram Sharma, Ning Quan, Jonathan P Godbout, John F Shridan. Knockdown of interleukin-1 receptor type-1 on endothelial cells attenuated stress-induced neuroinflammation and prevented anxiety-like behavior. *Journal of Neuroscience* 2014;34(7):2583-2591.

28. Marcus Banks, David Zeitlyn. Visual methods in social research. Sage 2015.
29. Ulf Anderson, Kevin J Tracey. Neural reflexes in inflammation and immunity. *Journal of Experimental Medicine* 2012;209(6):1057-1068.
30. Hye-lin Ha, Hye-jun Shin, Mark A Feitelson, Dae-Yul Yu. Oxidative stress and antioxidants in hepatic pathogenesis. *World journal of gastroenterology:WJG* 2010;16(48):6035.
31. Gunter U Holinger, Gesine Respondek, Maria Stamelou, Carolin Kurz, Keith A Josephs. Clinical diagnosis of progressive supranuclear palsy: the movement disorder society criteria. *Movement disorders* 2017;32(6):853-864.
32. Gillian L Dalglish, Kyle Furge, Chris Greenman, Lina Chen, Graham Bignell. Systematic sequencing of renal carcinoma reveals inactivation of histone modifying genes. *Nature* 2010;463(7279):360-363.
33. Christos Profyris, Surinda S Cheema, Dawei Zang, Micheal F Azari, Kristy Boyle, Steven Petratos. Degenerative and regenerative mechanisms governing spinal cord injury. *Neurobiology of disease* 2004;15(3):415-436.