

## Case report

# Folliculotropic mycosis fungoides with alopecia and eruptive Comedones in an adolescent boy

---

### ABSTRACT

**Aims :** Folliculotropic mycosis fungoides (FMF) is an uncommon variant of mycosis fungoides, rarely described in children. This type of lymphoma is particularly unresponsive to treatment and has a poor prognosis. Paradoxically, it can be clinically confused with conditions as benign as acne or alopecia. Hence the interest of our case report.

**Case report :** A 15-year-old adolescent presented to our clinic with alopecia of the scalp associated with depilation of the axillae and pubic area. The clinical examination revealed infiltration of the scalp and axillae with fine scales and numerous open comedones, as well as non-pruritic erythematous patches on the hips and thighs. Anatomopathological and immunohistochemical examination confirmed the diagnosis of FMF without mucinosis. The patient was put on topical steroids, then on methotrexate without improvement.

**Discussion :** FMF is a rare form of primary cutaneous T-cell lymphoma. It is a well-defined variant of mycosis fungoides characterized by infiltration of the pilosebaceous follicles with atypical lymphocytes, with or without mucinosis. This may be clinically expressed by acne-like lesions, comedones or even depilation of the hairy areas. Different differential diagnoses exist. This condition is mostly seen in elderly subjects and much more rarely in children and adolescents.

**Conclusion :** Its resistance to usual treatments and its poor prognosis encourage practitioners to evoke this particular entity even in the pediatric population to ensure an early diagnosis and a better management.

*Keywords: Folliculotropic mycosis fungoides, primary cutaneous T-cell lymphoma, Teenager, Comedones, Alopecia.*

## 1. INTRODUCTION

Mycosis fungoides (MF) is the most common type of cutaneous t-cell lymphoma. Several clinical and histological forms have been described including folliculotropic mycosis fungoides, which is characterized by an infiltrate of atypical lymphocytes in the hair follicles [1]. It is a rare and aggressive form that is often unrecognized by dermatologists and pathologists, particularly in the early stages. It typically affects the cephalic region of elderly patients. Pediatric cases have been rarely described in the literature [2].

We report a case of a 15-year-old male patient with FMF marked by eruptive comedones and alopecia mimicking alopecia areata.

## 2. PRESENTATION OF THE CASE

A 15-year-old patient with no previous medical history presented with alopecia of the scalp associated with depilation of the axillae and pubic area, which had been evolving for about 4 years. The clinical examination revealed, in addition to the almost total alopecia of the scalp, a thickening of the scalp and axillary folds with fine whitish scales and several comedones (Figure 1,2). There were also bilateral, symmetrical, non-pruritic erythematous patches on the lateral sides of the hips and thighs (Figure 3).

Dermoscopy of the scalp showed in some areas scarring alopecia with fine whitish scales and open comedones, while in others yellow spots and fluffy hair are observed (Figure 4).

Pathological examination with immunohistochemical study of a scalp biopsy confirmed the diagnosis of folliculotropic mycosis fungoides without mucinosis (Figure 5).

The workup did not reveal any systemic involvement, thus classifying it as stage IA. Local treatment with very strong topical steroids was initiated under occlusion with improvement only of the erythematous plaques after 2 months. Weekly injections of 25mg of methotrexate with folic acid supplementation were prescribed without benefit after 18 months of treatment. The patient was subsequently lost to follow-up.

## 3. DISCUSSION

FMF, also known as pilotropic MF or follicular MF, is the most common variant of MF and accounts for approximately 4% of all cutaneous T-cell lymphomas [3]. It was categorized by the World Health Organization (WHO)-European Organization for Research and Treatment of Cancer (EORTC) as a separate entity given its particular clinicopathological characteristics, survival rate, and therapeutic responses compared to conventional MF [4].

There is a marked male predominance with a sex ratio of up to 5. In addition, FMF is believed to occur later in women than in men [5,6]. Only few cases have been reported in children in the literature [7]. But recently, a study has reported a 36 percent rate of occurrence of FMF in children. This high rate would be explained by a higher index of suspicion [8].

FMF commonly appear on skin areas with a high concentration of pilosebaceous units, such as the head, neck, and upper body. Its clinical features have long been known to be very variable. The most common clinical manifestations are erythematous, scaly and very itchy patches and plaques with follicular-based papules. Acneiform lesions with comedones occasionally associated with alopecia have also been described [9]. **Martínez-Escala**

FMF can actually mimic all conditions involving the pilosebaceous unit. These include acne conglobata, lichen spinulosus, keratosis pilaris, Favre-Racouchot syndrome, alopecia areata, lichen planopilaris, trichotillomania and folliculitis decalvans [9,10].

FMF is usually limited to skin with rare nodal and hematological involvement, at least in the early stages [5].

It is not surprising that FMF can manifest with an array of histologic characteristics given the wide range of clinical features. Five histologic patterns are reported: (1) typical folliculotropic infiltrate of atypical lymphocytes with or without mucinous deposits; (2) granulomatous reaction with destruction of the follicular unit; (3) eosinophilic folliculitis-like presentation with folliculotropism; (4) cystic and comedonal changes; and (5) basaloid folliculolymphoid hyperplasia with folliculotropism. The fourth histological pattern is clinically correlated with acneiform lesions, comedones or keratosis pilaris-like changes [9].

The treatment of FMF is to date challenging. Unlike classical MF, FMF is usually resistant to topical treatments, even in the early stages of the disease. This could possibly be explained by the depth of the atypical lymphocytic infiltrate that is difficult to reach by these topical therapies, thus requiring systemic treatment in most cases [11].

Treatment for early stages includes narrow-band ultraviolet B, local psoralen- Ultraviolet A therapy combined with interferon alpha or retinoids, local radiation therapy, local electron beam therapy, and topical nitrogen mustard. In advanced cases, chemotherapy (CHOP), alemtuzumab, irradiation and allogeneic bone marrow transplantation are used [2,12].

FMF is often considered an aggressive variant of MF, with an increased risk of progression. Significant discrepancies in prognosis are observed between FMF and classical MF, particularly in the early stages of disease ( $\leq$ IIA). The overall survival of patients at stage IIA or lower was 82% for FMF and 91% for MF at 10 years, decreasing to 41% for FMF while remaining stable (91%) at 15 years for classical MF. The prognosis of patients with advanced FMF ( $\geq$ IIB) is as poor as in advanced MF [13].

## 4. CONCLUSION

FMF is a rare and confusing variant of MF especially in adolescents. There is therefore often a delay in diagnosis. Its poor prognosis compared to classic MF justifies an early treatment.

We report these case to enlarge the clinical and histopathologic spectrum of FMF, which can look remarkably similar to acneiform disorders, and to emphasize the importance of reconsidering the diagnosis with histopathologic assessment.

## CONSENT

All authors declare that written informed consent was obtained from the patient (for publication of this case report and accompanying images). A copy of the written consent is available for review by the Editorial office/Chief Editor/Editorial Board members of this journal.

## ETHICAL APPROVAL

All authors hereby declare that all experiments have been examined and approved by the appropriate ethics committee and have therefore been performed in accordance with the ethical standards laid down in the 1964 Declaration of Helsinki.

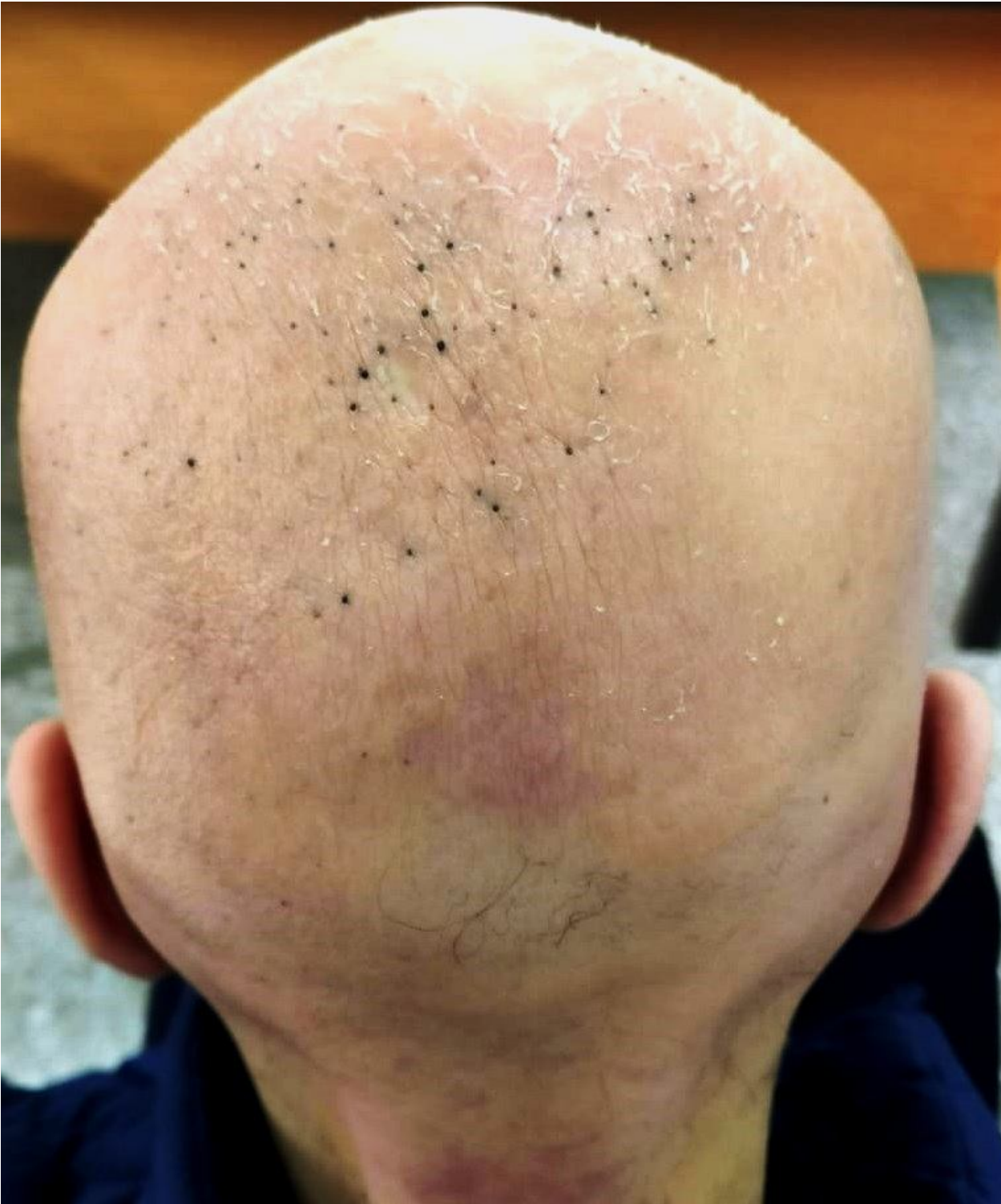## REFERENCES

1. Ben Samir, I. Damak, F.Z. Alaoui, A. Souissi, M.S. Boubaker, M. Mokni. Mycosis fongoïde ichtyosiforme et folliculotrope : une variante exceptionnelle de lymphome T cutané primitif. *Annales de Dermatologie et de Vénérologie - FMC*, 2022-11-01, Volume 2, Numéro 8, Pages A176-A176. French.
2. Mantri MD, Khadke MP, Ameet DL, Rachita DS. Folliculotropic Mycosis Fungoides in an Adolescent: A Rare Case. *Indian J Dermatol*. 2016 Jul-Aug;61(4):467. doi: 10.4103/0019-5154.185746.
3. Sebastian DeMarco. A case of folliculotropic mycosis fungoides. *Journal of the American Academy of Dermatology*, 2019-10-01, Volume 81, Numéro 4, Pages AB151-AB151.
4. Hodak E, Amitay-Laish I, Atzmony L, Prag-Naveh H, Yanichkin N, Barzilai A et al. New insights into folliculotropic mycosis fungoides (FMF): A single-center experience. *J Am Acad Dermatol*. 2016 Aug;75(2):347-55. doi: 10.1016/j.jaad.2016.03.009.
5. Lehman J.S., Cook-Norris R.H., Weed B.R. Folliculotropic mycosis fungoides: single-center study and systematic review. *Arch Dermatol* 2010; 146: pp. 607-613.
6. Shamim H, Riemer C, Weenig R, Sokumbi O, Sciallis G, McEvoy M et al. Acneiform Presentations of Folliculotropic Mycosis Fungoides. *Am J Dermatopathol*. 2021 Feb 1;43(2):85-92. doi: 10.1097/DAD.0000000000001698.
7. Alikhan A., Griffin J., Nguyen N. Pediatric follicular mucinosis: presentation, histopathology, molecular genetics, treatment, and outcomes over an 11-year period at the Mayo Clinic. *Pediatr Dermatol* 2013; 30: pp. 192-198.
8. Roca-Ginés J, Alfaro-Cervelló C, Sánchez-Arreaez J, Torres-Navarro I, Navarro-Mira MÁ, Monteagudo C et al. Folliculotropic Mycosis Fungoides With Flexural Eruptive Cysts and Comedones in a 14-Year-Old Boy. *Am J Dermatopathol*. 2021 Sep 1;43(9):656-658. doi: 10.1097/DAD.0000000000001958.
9. Martínez-Escala ME, González BR, Guitart J. Mycosis Fungoides Variants. *Surg Pathol Clin*. 2014 Jun;7(2):169-89. doi: 10.1016/j.path.2014.02.003. Epub 2014 Apr 13.
10. Van Doorn R., Scheffer E., Willemze R. Follicular mycosis fungoides, a distinct disease entity with or without associated follicular mucinosis: a clinicopathologic and follow-up study of 51 patients. *Arch Dermatol* 2002; 138: pp. 191-198.

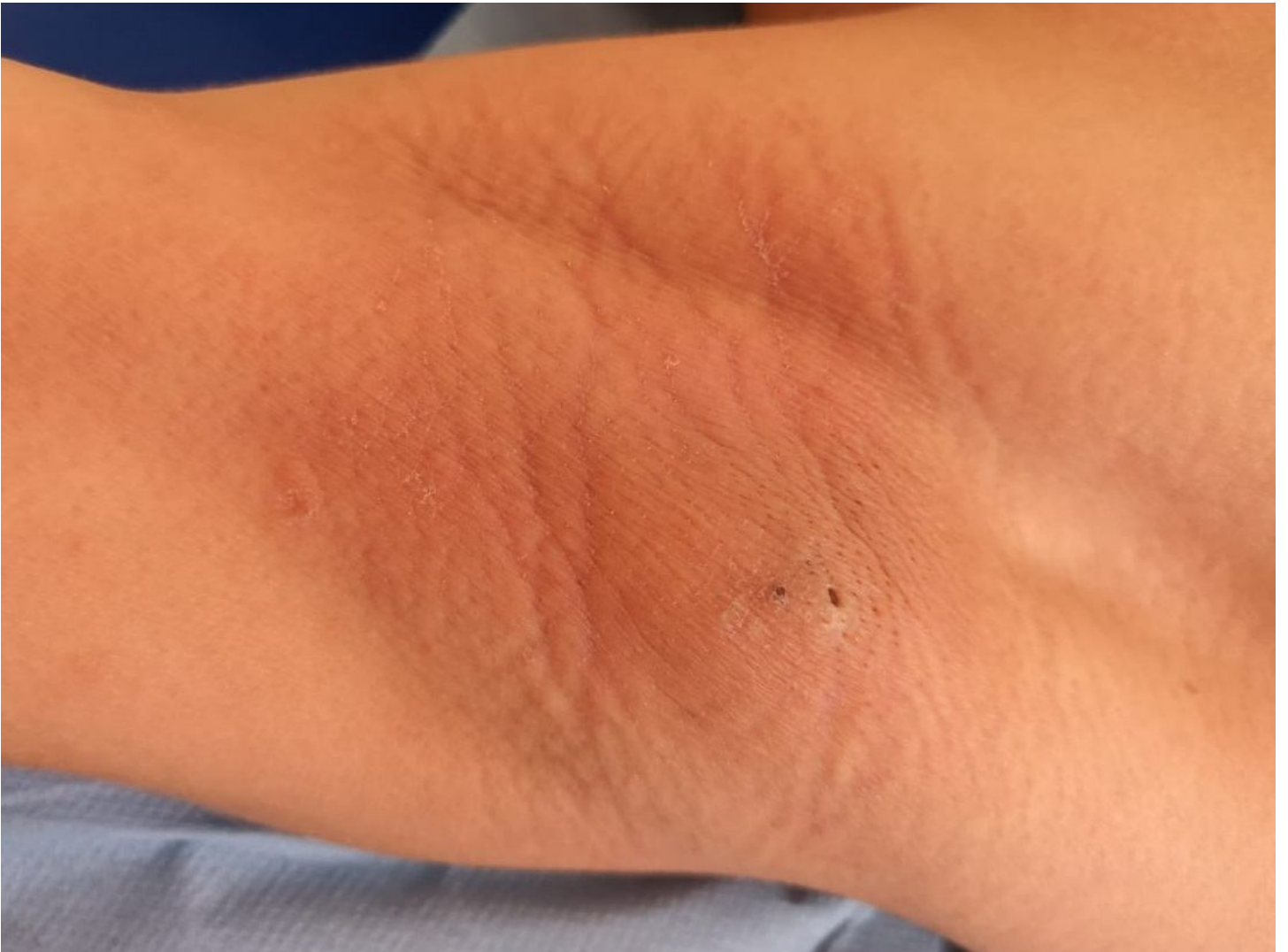11. Muniesa C., Estrach T., Pujol R.M. Folliculotropic mycosis fungoides: clinicopathological features and outcome in a series of 20 cases. *J Am Acad Dermatol* 2010; 62: pp. 418-426.
12. Boix-Vilanova J, Corral-Magaña O, Martín-Santiago A, Escalas J. Folliculotropic mycosis fungoides in a pediatric patient with response to psoralen-ultraviolet A phototherapy. *Photodermatol Photoimmunol Photomed*. 2019 Jan;35(1):54-56. doi: 10.1111/phpp.12414.
13. Gerami P., Rosen S., Kuzel T. Folliculotropic mycosis fungoides: an aggressive variant of cutaneous T-cell lymphoma. *Arch Dermatol* 2008; 144: pp. 738-746.

UNDER PEER REVIEW

**FIGURES**

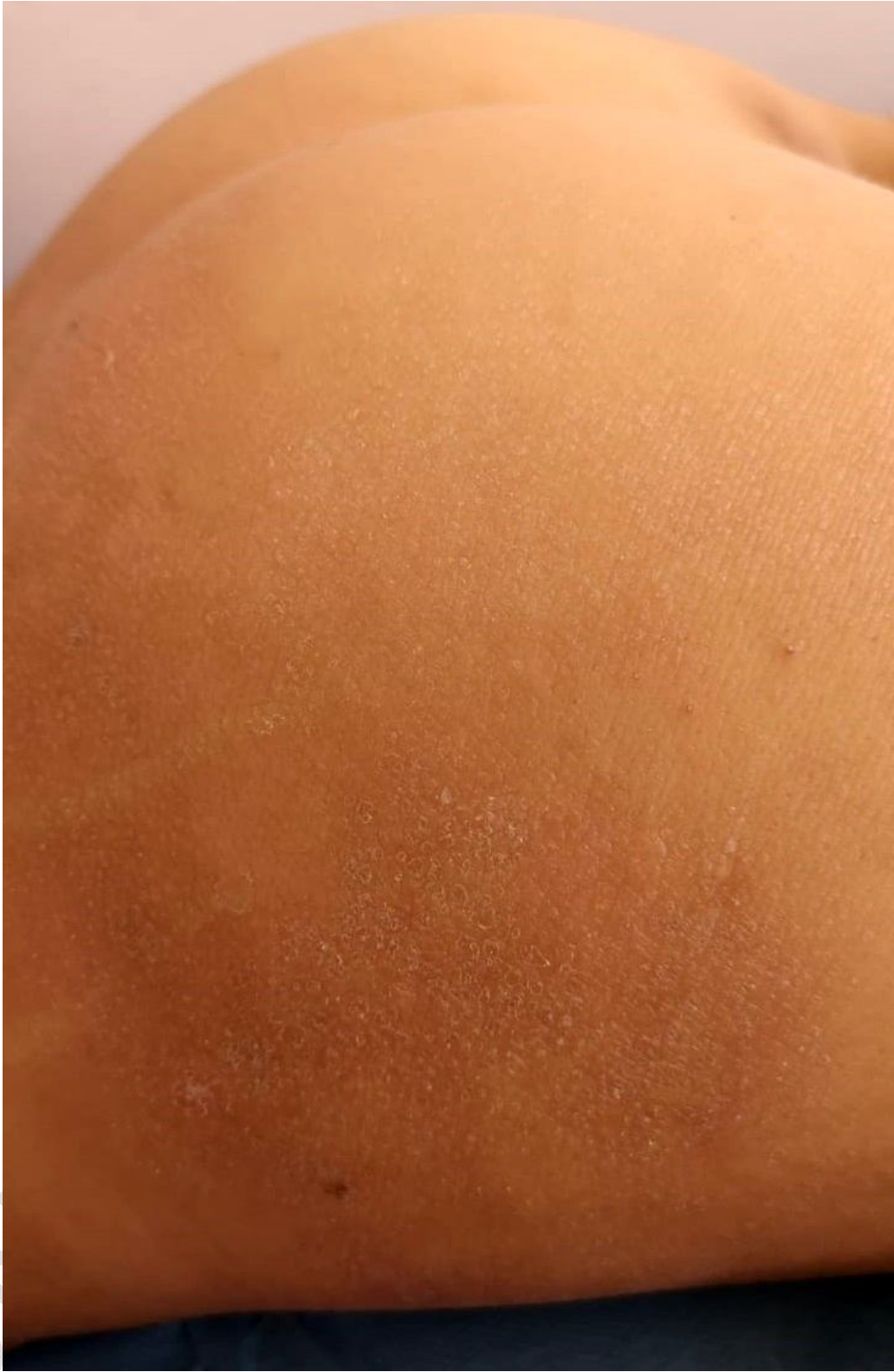

**Figure 1** : Almost total alopecia of an infiltrated scalp with numerous open comedones and fine scales

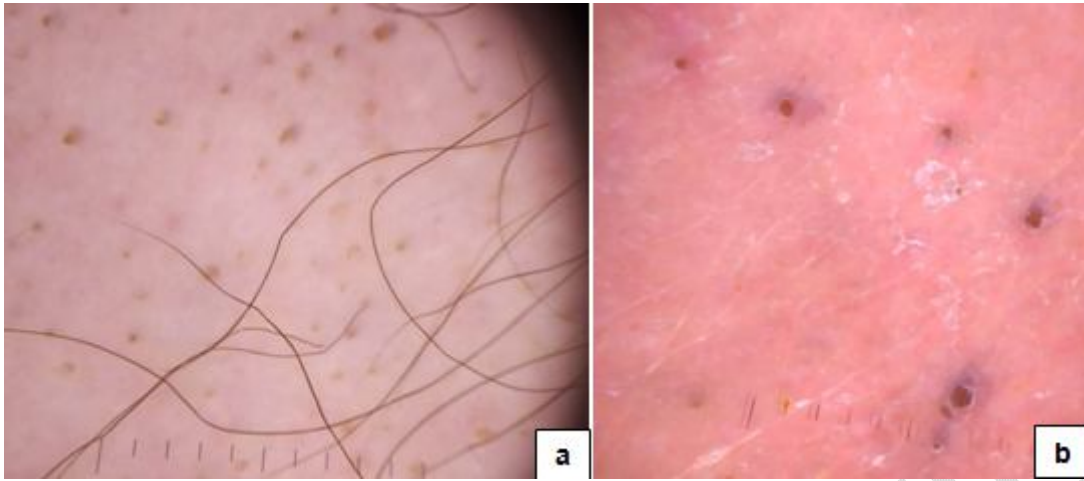


**Figure 2:** Thickened skin of the axillary fold with accentuated wrinkles, fine whitish scales and open comedones.

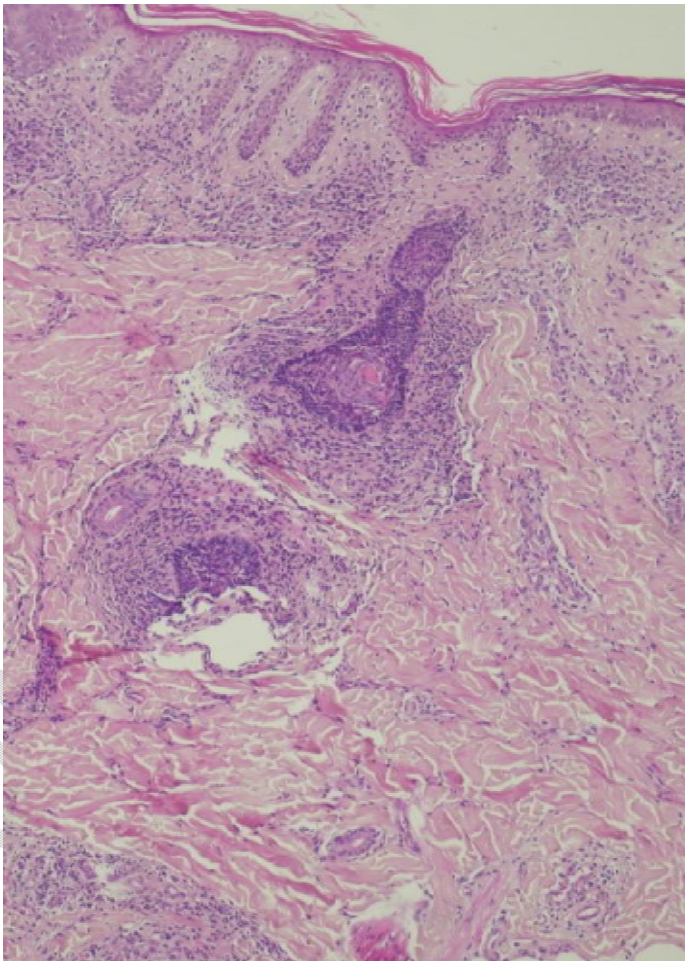
UNDER



**Figure 3 :** Thinly scaly erythematous patches on the buttocks.



**Figure 4:** Dermoscopic images of the scalp showing areas of non-scarring alopecia with numerous yellow dots and fluffy hair **(a)** and areas of scarring alopecia with keratotic plugs and fine whitish scales on an erythematous background **(b)**.



**Figure 5:** Histological section of a scalp biopsy showing orthokeratotic hyperkeratosis, clear epidermotropism and follicular involvement.

UNDER PEER REVIEW