

MOYNIHAN'S HUMP- DREADFUL HEPATIC ARTERY VARIATION IN LAPAROSCOPIC CHOLECYSTECTOMY

ABSTRACT

Aims- To highlight a case of hepatic artery anatomic variation during laparoscopic cholecystectomy.

Presentation of Case- During cholecystectomy a variation of hepatic artery anatomy called Moynihan's hump was noticed.

Discussion- Laparoscopic cholecystectomy is gold standard treatment for gallstones, The presence of Moynihan's hump can increase the risk of injury to the hepatic artery during surgery.

Conclusion- The presence of Moynihan's hump can increase the risk of complications during surgery, therefore sound knowledge of anatomy is important.

Keywords- Moynihan's hump, Hepatic Artery, Laparoscopic Cholecystectomy

1. INTRODUCTION

"The gallbladder diseases are the most common gastrointestinal pathology worldwide including in India. There are many different types of gallbladder disease like Gallstones, Cholecystitis, Choledocholithiasis, Acalculous gallbladder disease, Biliary dyskinesia, Sclerosing cholangitis, Gallbladder cancer, Gallbladder polyps. The commonest biliary pathology is gallstone disease which is a major cause of morbidity and mortality" [1]. "The increased incidence of cholecystitis and cholelithiasis in the past couple of decades is attributed to the increased intake of a fatty, high-calorie diet and increased consumption of alcohol" [1].

"The prevalence of gallstone disease varies with age, sex, ethnic group and geographical areas. The female prevalence of gall bladder disease in the American Indians and Pima Indians is as high as 60%-70%, in Chile 37% while in the UK and the USA, it is 6% to 12% and 11% respectively. China and Japan have a very low prevalence rate of 5%. The estimated prevalence of gallstone disease in India was 2-29% with marked differences in North and South India. It is seven times more common in North than in South India" [2].

"Cholelithiasis produces various changes in the gall bladder like acute cholecystitis, chronic cholecystitis, polyp, granulomatous cholecystitis, empyema, eosinophilic cholecystitis, metaplasia, hyperplasia, dysplasia to carcinoma. However, in 5 % to 10% of the cases, cholecystitis occurs without calculus" [1].

"Multiple signs and symptoms are associated with cholelithiasis like severe pain in Murphy's point in the right upper quadrant of the abdomen, bilious vomiting, mild to moderate increase in temperature, obstructive jaundice, loss of appetite and weight. The clinical spectrum of gallstone disease ranges from asymptomatic gallstones to biliary colic, acute calculus cholecystitis, gallstone pancreatitis, choledocholithiasis, acute cholangitis and carcinoma gallbladder" [1].

Chronic cholecystitis is a long-standing inflammation of the gallbladder, which can lead to the formation of stones, fibrosis, and thickening of the gallbladder wall. It is usually caused by repeated episodes of acute cholecystitis, and if left untreated, can lead to complications such as gallbladder rupture, biliary peritonitis, or gallbladder cancer [3].

"Laparoscopic cholecystectomy is the gold standard for treating benign gall bladder diseases and the commonest operation performed worldwide" [4]. However, there are many complications involved with this surgery that may be due to anatomical variations or surgeon error. One of them is the presence of an aberrant Right hepatic artery over the cystic

duct, that mimics the cystic artery, it is called Moynihan's hump. The wrong identification can lead to injury to the right hepatic artery, leading to many complications [5].

In this case report we discuss the variation in the right hepatic artery and the importance of sound knowledge of anatomy.

2. CASE REPORT

A 42-year-old female presented to the clinic with a history of pain in her right upper abdomen and dyspepsia for the past 1 year. The pain was sudden in onset, mild in intensity, colicky in nature, radiating to the back with no aggravating factors and was relieved on its own since then she had on and off mild pain. There was no history of fever, jaundice, vomiting, no alteration in bowel and bladder movements. Past surgical, medical and family history was insignificant. On examination, there was no pallor, icterus, clubbing, cyanosis, lymphadenopathy and pedal oedema. Her vitals were stable. The abdominal examination was normal. Baseline investigations viz. CBC, RFT, LFT and electrolytes were normal. In the Ultrasound abdomen, there was cholelithiasis with multiple calculi in GB largest measuring 2.1x1.3cm. the gold standard treatment of gallstones i.e. Laparoscopic cholecystectomy was done after explaining the risks and complications to the patient and taking due consent. It was done in General Anesthesia in endotracheal intubation. Operative findings included no adhesions between the omentum and gall bladder. The gall bladder was distended and contained multiple calculi. The right hepatic artery was noticed to be tortuous and very close to the cystic duct i.e. Moynihan's hump was present (Figure 1). The cystic artery and cystic duct were safely clipped and cut (Figure 2). Total cholecystectomy was done. The post-operative period was uneventful and the patient was discharged on the second post-operative day. The histopathology report of extracted gallbladder was consistent with chronic cholecystitis.

3. DISCUSSION

Cholecystitis is a common disorder characterized by inflammation of the gallbladder. It may occur due to a blockage in the cystic duct, which prevents bile from flowing out of the gallbladder. This may lead to the formation of gallstones, which can cause pain, inflammation, and infection [1].

"Laparoscopic cholecystectomy is the standard treatment for symptomatic cholelithiasis" [4]. In this case, the presence of multiple calculi in the gallbladder and a large stone size justified the need for surgery. The surgical procedure involved removing the entire gallbladder, as it is difficult to remove individual stones. During surgery, it was observed that the right hepatic artery was tortuous and very close to the cystic duct, a condition known as Moynihan's hump. The incidence of Moynihan's hump is 1-13%. The presence of Moynihan's hump can increase the risk of injury to the hepatic artery during surgery, which can lead to significant complications like ischemic necrosis of the right lobe of the liver, partial injury can subsequently lead to hepatic artery pseudoaneurysm and haemorrhage during surgery may obscure the surgeon's field of vision, causing injury and/or disruption to the bile duct. This is the most feared complication of laparoscopic cholecystectomy and also one of the most frequent causes of lawsuits against surgeons[5]. Therefore, safe dissection and sound knowledge of anatomy are important.

4. CONCLUSION

Laparoscopic cholecystectomy is a safe and effective treatment for symptomatic cholelithiasis, but the presence of Moynihan's hump can increase the risk of complications during surgery.

5. ETHICAL APPROVAL:

As per international standard or university standard written ethical approval has been collected and preserved by the author(s).

6. CONSENT:

As per international standard or university standard, patient(s) written consent has been collected and preserved by the author(s).

7. CONFLICT OF INTEREST:

NO conflict of interest

8. REFERENCES

1. Tazuma S. Gallstone disease: Epidemiology, pathogenesis, and classification of biliary stones (common bile duct and intrahepatic). *Best Pract Res Clin Gastroenterol.* 2006;20(6):1075-83.
2. Mohan H, Punia R, Dhawan S, Ahal S, Sekhon M. Morphological spectrum of gallstones disease in 1100 cholecystectomies in North India. *Ind J Surg.* 2005;67(3):140-2.
3. Yamashita Y, Takada T, Kawarada Y, et al. Surgical treatment of patients with acute cholecystitis: Tokyo Guidelines. *J Hepatobiliary Pancreat Surg.* 2007;14(1):91-97.
4. Chand P, Kundal S, Singh S, Papneja S, Singh J. Patterns of complications and outcome of laparoscopic cholecystectomy. *Int SurgJ* 2020;7:484-8.
5. Martín Pérez JA, Domínguez Rodríguez JA, De Alba Cruz I, Lara Valdés AJ, Sánchez Baltazar AL, Perna Lozada L. Moynihan's Lump as an unusual variant of right hepatic artery during a laparoscopic cholecystectomy approach. A case report. *Int J Surg Case Rep.* 2021 Aug;85:106221.

9. FIGURES

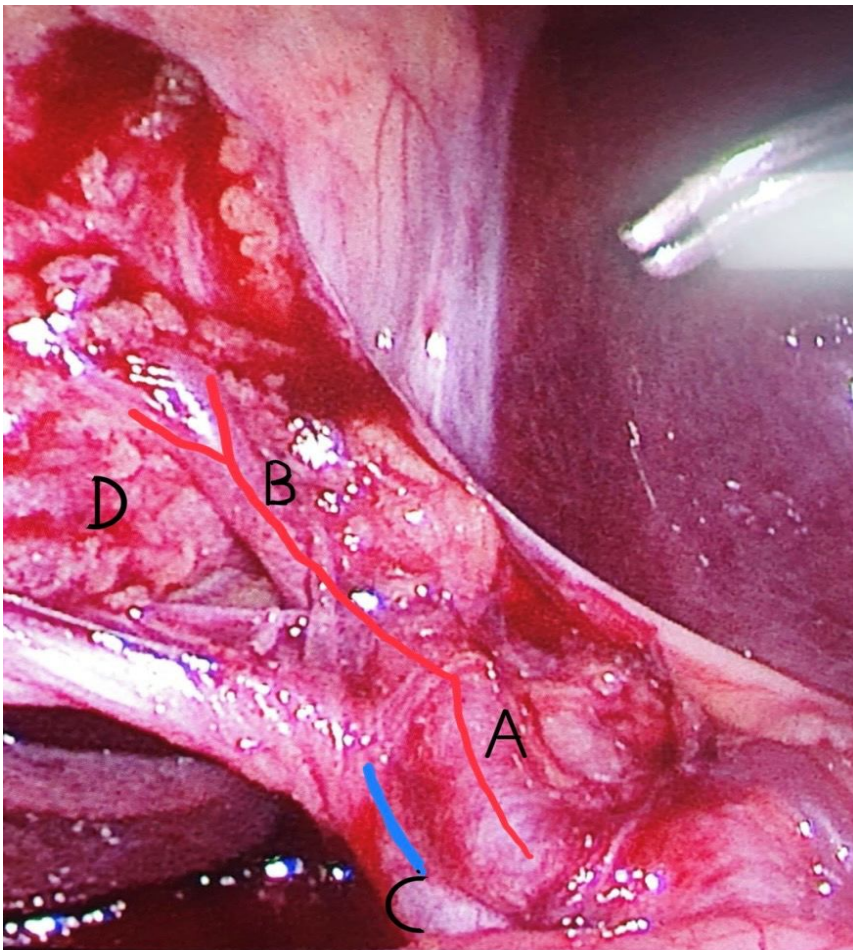


FIGURE1: Laparoscopic view of safety with Moynihan's Hump(A- Right Hepatic artery, B-Cystic Artery, C- Cystic Duct, D- GallBladder)

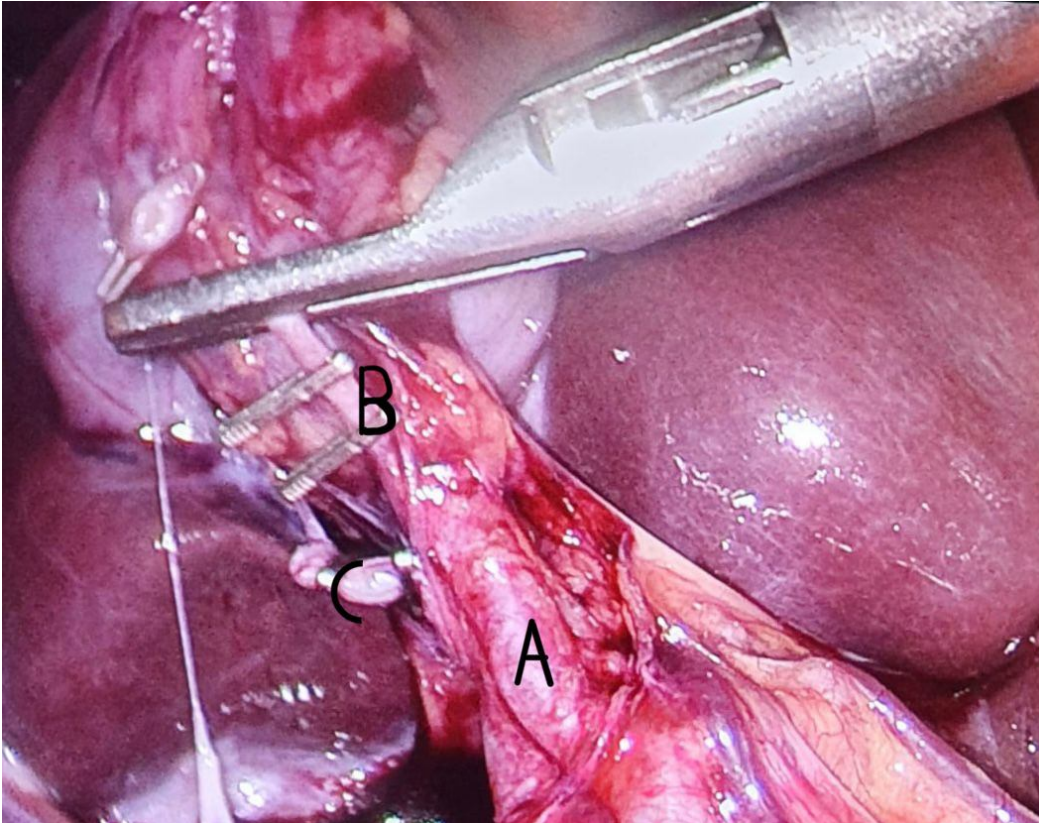


FIGURE 2: Cystic artery and cystic duct clamped