

Case Report

Toxic or septic myocarditis in a patient suffering from aplastic anemia

ABSTRACT

The present case report highlights about Toxic or septic myocarditis in a patient suffering from aplastic anemia. A 21 years old female patient, without any cardiovascular risk factor, suffering from Aplastic Anemia, admitted initially for feverish neutropenia for which she received adequate antibiotherapy followed by Thymoglobulin® (anti-thymocyte globulin (rabbit)), which is an immunosuppressive agent used in treatment of Aplastic Anemia. Adverse cardiovascular reactions that have been reported in association with ATG include myocarditis, "cardiac irregularity," chest pain, hypertension, hypotension, tachycardia, and bradycardia.

Keywords: Toxic Myocarditis, Septic myocarditis, Aplastic anemia, Myocarditis, Chest pain, Electrocardiogram, Cardiac enzymes, Cardiac magnetic resonance imaging, Drug reactions

BACKGROUND:

Myocarditis refers to the inflammation of the myocardium, resulting in tissue degeneration or necrosis. Previously known as inflammatory myocarditis, it typically affects younger people. Myocarditis is classified as acute, fulminant, chronic active, or chronic persistent. [1] Acute myocarditis constitutes most cases of myocarditis (65%) and is mostly caused by an infection.

The clinical presentation is variable and includes febrile illness, mild chest pain, arrhythmias, heart failure, cardiogenic shock, or death. The clinical diagnosis is often challenging, and the management is usually supportive.

CASE PRESENTATION:

A 21 years old female patient, without any cardiovascular risk factor, suffering from Aplastic Anemia, admitted initially for feverish neutropenia for which she received adequate

antibiotherapy followed by Thymoglobulin® (anti-thymocyte globulin (rabbit)), which is an immunosuppressive agent used in treatment of Aplastic Anemia. 3 days after its administration, the patient was complicated by septic shock. After 12 hours, she presented chest pain. Her pulse was 150 bpm, blood pressure 62/43, respiratory rate was 32c per minute, purulent sputum.

Physical examination found rhonchi and crackling sound when auscultating the lungs, there were signs of global heart failure such as: crackling sound when auscultating the lungs, oedema in legs, Jugular Vein Distention.

The electrocardiogram showed a sinus tachycardia of 150 bpm with negative T waves in inferior and anterior derivations (figure 1). A bedside echocardiography showed an impaired left and right ventricular function, LVFE was at 30%, slightly elevated left ventricular filling pressure, moderate mitral regurgitation (figure 2), mild tricuspid regurgitation.

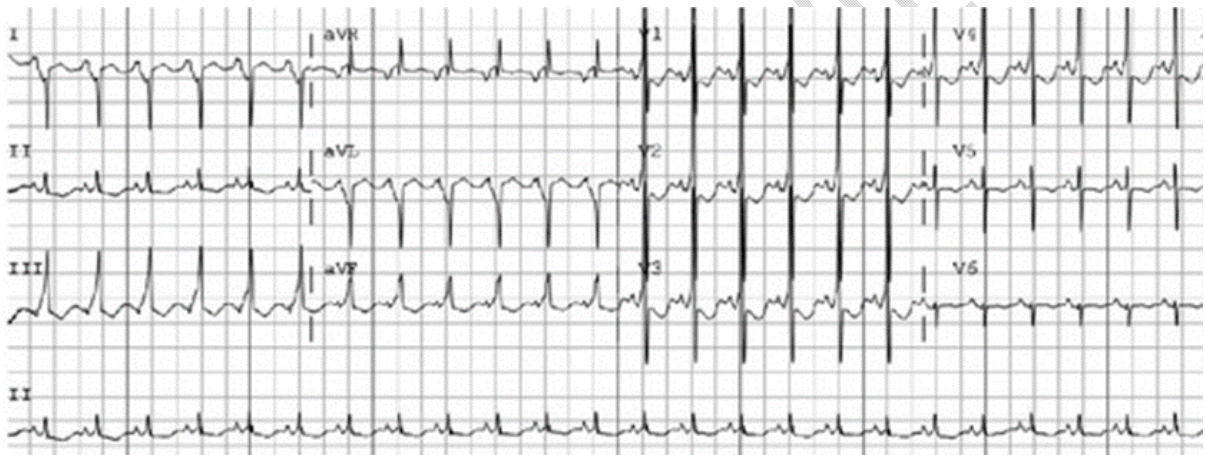

Figure 1: Patient ECG

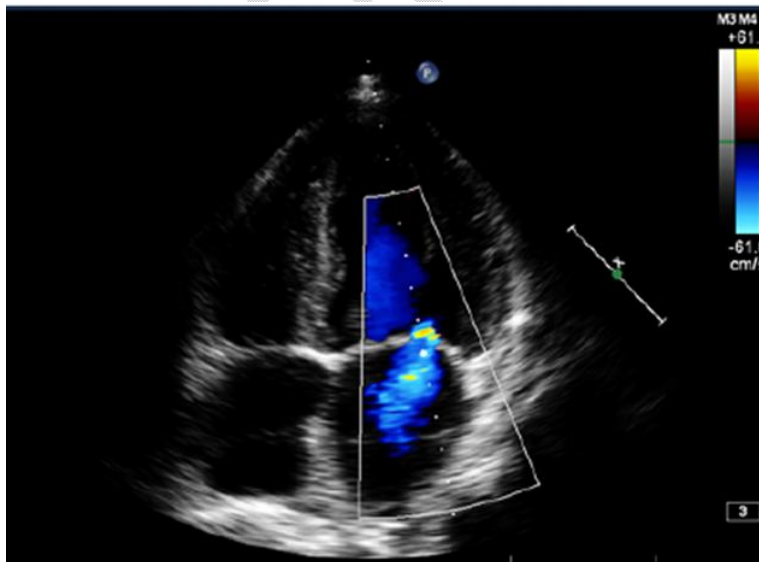


Figure 2: TTE of patient showing Moderate mitral regurgitation

On laboratory investigation, CRP was high 365, neutropenia at 50, Hb at 6.9, Platelets <10 000, at troponin at 648, normal renal function. The patient received 2mg of noradrenaline on continuous perfusion, triple antibiotherapy : vancomycin + Imipenem/cilastatin + amikacyn.

We suspected cardiotoxicity due to anti-thymocyte globulin (ATG) or a Myocarditis due to septic shock, so a cardiac MRI have been indicated.

The patient was transferred to intensive unit care in which she presented multivisceral failure even with the increased doses of noradrenaline and introduction of dobutamine. She passed away 7 days later.

DISCUSSION:

The diagnosis of myocarditis is challenging, due to the variability of symptoms that are often unspecific, ranging from asymptomatic to life-threatening.

ATG is a monomeric immunoglobulin G (IgG) obtained from the serum of horses or rabbits immunized with human thymus lymphocytes. It is a lymphocyte-selective immunosuppressant. [1] The most commonly reported side effects of treatment with ATG are fever, chills, leukopenia, thrombocytopenia, and dermatologic manifestations (rashes, urticaria, pruritis, wheal, and flare). [1] Adverse cardiovascular reactions that have been reported in association with ATG include myocarditis, "cardiac irregularity," chest pain, hypertension, hypotension, tachycardia, and bradycardia.

Sepsis, defined by consensus conference as "the systemic inflammatory response syndrome (SIRS) that occurs during infection," is generally viewed as a disease aggravated by the inappropriate immune response encountered in the affected individual [5]. Myocardial dysfunction affects approximately half of patients with sepsis admitted to intensive care units (ICUs) [2]. Cardiac abnormalities can involve both the left and right ventricles and may include both systolic and diastolic dysfunctions [3]. Studies have shown that plasma concentrations of troponin, as biomarker of myocardial injury, correlate well with functional abnormalities seen on echocardiography [4].

Infectious Myocarditis is more likely to be the cause given the context of lymphopenia, septic shock, the high serum levels of CRP, purulent sputum and leg ulceration.

CONCLUSION:

Myocarditis is a major complication of sepsis and has a negative impact on the survival of patients. Sepsis-induced myocarditis is present in half of all the patients with septic shock and is characterized by the significant impairment of the left ventricular (LV) systolic and diastolic function. Although there have been major advances in the understanding the pathophysiology and treatment of sepsis over the past 20 years, much of the associated mortality and morbidity remain High.

REFERENCES:

1. Pfizer Inc. Atgam (lymphocyte immune globulin, antithymocyte globulin [equine] sterile solution) 2011.
2. Zaky A, Deem S, Bendjelid K, Treggiari MM. Characterization of cardiac dysfunction in sepsis: an ongoing challenge. *Shock*. 2014; 41:12–24. doi: 10.1097/SHK.0000000000000065
3. Pulido JN, Afessa B, Masaki M, Yuasa T, Gillespie S, Herasevich V, Brown DR, Oh JK. Clinical spectrum, frequency, and significance of myocardial dysfunction in severe sepsis and septic shock. *Mayo Clin Proc*. 2012; 87:620–628. doi: 10.1016/j.mayocp.2012.01.018.
4. Landesberg G, Jaffe AS, Gilon D, Levin PD, Goodman S, Abu-Baih A, Beerli R, Weissman C, Sprung CL, Landesberg A. Troponin elevation in severe sepsis and septic shock: the role of left ventricular diastolic dysfunction and right ventricular dilatation*. *Crit Care Med*. 2014; 42:790–800. doi: 10.1097/CCM.0000000000000107.
5. Bone RC, Balk RA, Cerra FB, Dellinger RP, Fein AM, Knaus WA, Schein RMH, Sibbald WJ. Definitions for sepsis and organ failure and guidelines for the use of innovative therapies in sepsis. *Chest*. 1992; 101: 1644–1655.

UNDER PEER REVIEW