

Original Research Article

COMPARISON BETWEEN MODIFIED TRIANGULAR FLAP AND ENVELOP FLAP TECHNIQUES FOR SURGICAL REMOVAL OF IMPACTED THIRD MOLAR

Comment [J1]: Maxilla or mandibular

ABSTRACT

Objective: To compare postoperative outcomes in surgical extraction of mandibular third molar with envelop flap versus modified triangular flap.

Comment [J2]: Please adjust the procedure for writing an abstract consisting of an introduction, case report, discussion, and conclusion.

Setting: Oral & Maxillofacial Surgery Unit at Faculty of Dentistry, Liaquat University of Medical and Health Sciences Jamshoro

Duration: January 2021 to December 2021.

Comment [J3]: Is part of the case report, not a separate part

Subject and Methods: A set of 60 individuals were sequentially assigned 30 to the envelop flap and 30 to the modified triangular flap for surgical removal of the mandibular third molar tooth. The demographic and clinical parameters was identified and recorded in proforma. The discomfort, swelling, and restricted mouth opening linked with an impacted mandibular third tooth are all assessed prior to surgery. The flap pattern employed for the extraction of the impacted lower third molar tooth, pain, and mouth opening were all reported on the proforma at the end of the procedure. On the seventh postoperative day, each patient was evaluated again.

Comment [J4]: Proforma

Comment [J5]: how to evaluate it, please explain in the case report section

Results: - The average age of patients in group A was 29.77 ± 7.17 years and 28.20 ± 6.28 years in group B. Mean pain score was significantly low in group A as compare to group B [0.87 ± 0.86 vs. 2.93 ± 0.87 $p=0.0005$]. Mean mouth opening was significantly high in group A than group B [12.86 ± 3.59 vs. 6.12 ± 1.67 ; $p=0.0005$].

Conclusion: In comparison to the envelope flap, the modified triangular flap was more effective when considering the postoperative periodontal state of the surrounding third molar and the dehiscence after wound recovery.

Key Words: Mandibular third molar impaction, envelop flap, modified triangular flap, surgical extraction, mandibular premolar

Comment [J6]: Keywords:

INTRODUCTION

"A tooth that is stopped from emerging into place due of malposition, lack of space, or other obstructions," Mead defines an impaction. "An impacted tooth" is defined by Peterson as "teeth that fail to erupt into the dental arch within the predicted period." "An impacted tooth is a tooth that is inhibited from erupting owing to a physical obstacle inside the eruption route," Farman wrote previously. ^[1,2] The more prevalent impaction is mandibular third molar impaction, which is preceded by maxillary third molar, maxillary canine, and mandibular premolar impaction. ^[3]

Comment [J7]: Please use paragraphs, indented, and so on.

Comment [J8]: No need to always mention the name, just include the literature number.

Comment [J9]: No need to always mention the name, just include the literature number.

Comment [J10]: No need to always mention the name, just include the literature number.

Comment [J11]: Could you please add the percentage for each?

The orientation and depth of impaction, the proportion of accessible space for tooth eruption, and the amount of soft tissue and bone (or both) that

covers them (Pell and Gregory classification), as well as the angulation of the impacted third molar with regard to the long axis of the neighbouring second molar, are used to classify impacted wisdom teeth in the mandible. Practitioners can use the categorization framework to predict the likelihood of impaction, infection, and other problems related with wisdom tooth extraction. The presence or absence of symptoms and illness can also be used to classify wisdom teeth. [4,5]

The extraction of the lower wisdom tooth surgically is a frequent surgery that might result in discomfort, trismus, edoema, alveolar osteitis, and periodontal pocket development close to the second molar. Clinicians have examined the use of several flaps such as the Envelop flap, ward incision flap, kruger envelop flap, killy and kay incision, berwick tongue shape flap, nageshwar comma shaped flap, henry incision, triangle flap, and modified triangular flap to decrease these complications^[6]. The envelop flap provides for good visibility of the surgical site, and the incision can be expanded anteriorly if necessary. Blood supply is excellent because to the wide base, and the design allows for simple sealing and re-approximation.

Comment [J12]: Please pay attention to the use of capital letters

Comment [J13]: From which literature?

Since it prevents elevating soft tissues from the buccal face of the second molar, the modified triangular flap is considered more cautious due to a lower degree of tissue reflectance. It's easy to seal and provides a reasonably tension-free seal. Unlike the envelop flap, though, it cannot be easily stretched. [7,8].

When contrasted to the modified triangular flap, probable troubles with the envelop flap include enhanced osteoclastic action when elevating the mucoperiosteal flap with possible local bone setback, greater danger of wound dehiscence, which might result to a dry socket and an excruciating and uncomfortable postoperative era for the patient, and injury at the level of periodontal fibres to cervical insertion when the incision is conducted. Soft tissue strain, arising in postoperative hematoma and masticatory motions, promotes a greater frequency of wound dehiscence when the envelop flap is anchored anteriorly with intersulcular sutures. [6,9,10]

Comparing envelop flap with modified triangular flap, the triangular flap has disadvantage of limited mouth opening due to raising mucoperiosteal flap which induces inflammation to masticatory muscles causing trismus. [11]

Sandhu et al looked at the impact of modified triangular and envelope flap patterns on postoperative trismus and found no significant differences between the two designs. [12,13] In the study conducted by koyuncu BO et al found out the mean pain among modified triangular flap as 0.85 ± 1.15 at 7th day and mean mouth opening at 7th day as 4.03 ± 1.02 . [9] And the mean pain score for envelop flap as 2.16 ± 1.12 , and mouth opening as 12.25 ± 9.08 . [8].

Comment [J14]: trismus

Comment [J15]: 1 paragraph must consist of > 1 sentence

Comment [J16]: Inclusion of the name is enough on the literature number (Van Couver)

MATERIAL AND METHODS:

This is a non-probability **Consecutive** sampling research with a Randomized Control Trial. Sample size was calculated using **open epi**. Sample size calculate by taking statistics for pain in modified triangular flap technique as 0.85 ± 1.15^9 at 7th day and for envelope flap technique the mean as 2.16 ± 1.12 , power of test 90% and 95% CI. The calculated sample size came out as 30 in each group. 5 patients additional were enrolled for loss of follow up in each group. Total sample size was 60.

INCLUSION CRITERIA:

- **Either gender**
- **Age group from 18 to 40 years**
- **Mesioangular impaction**

Comment [J17]: Without :

Comment [J18]: consecutive

Comment [J19]: Is this the name of an app? OpenEpi? Please explain.

- Distoangular impaction
- Class II
- Class B

EXCLUSION CRITERIA:

- Immuno-compromised
- Pregnant patients
- Patient having systemic diseases like diabetes, cancer, hypertension or renal failure was assessed on medical record and history.
- Smokers
- Patients with bad habits (pan, guttka, betel nut chewers)

Comment [J20]: Made into a long sentences, not per point.

DATA COLLECTION PROCEDURE:

Comment [J21]: Without :

Individuals who met the eligibility conditions and were prepared to engage in the trial were enrolled. Before enrolling in the experiment, an informed and signed permission was obtained. Age, gender, pain, medical history, and tooth extraction process were among the demographics and clinical factors evaluated and documented in a proforma. The lead researcher or supervisor took the history, performed the clinical assessment, and took radiographs (OPG and periapical) and recorded them on a proforma. Complete preoperative assessment of patient and diagnosis of impaction pattern was done.

Comment [J22]: Proforma.

Preoperative evaluation of pain [on a scale of zero to ten (worst pain imaginable)], degree of swelling (by comparing the two sides of the patient's face), and restricted mouth opening [on a millimetre ruler] affiliated with impeded mandibular third molar

PROCEDURE:

By using a lottery system, all individuals were sorted into two identical portions, group A and group B. Group A was given to the modified triangular flap design, while Group B was given to the envelop flap type. Following patient stratification, routine preparation and draping were completed, and all procedures were executed under local anaesthetic with two 1.8mL of % xylocaine with 1:10000 epinephrine (Medicaine; Made in Korea) and all operations were undertaken under the observation of the supervisor. Using sterile carbon steel surgical blade #15 and a standard full thickness mucoperiosteal flap (MODIFIED TRIANGULAR FLAP), a standard full thickness mucoperiosteal flap (MODIFIED TRIANGULAR FLAP) was produced in group A. (Feather safety razor co. Ltd Japan).

A typical full thickness mucoperiosteal flap (ENVELOP FLAP) was developed in group B, accompanied with a sulcular cut from the first to second mandibular molar and a distal relieving incision along the external oblique ridge to the ramus. To prevent lingual nerve injury, a lingual flap was softly lifted distal to the second molar.

Comment [J23]: Without :

Comment [J24]: No need to write all capital letters

Comment [J25]: No need to write all capital letters

Comment [J26]: no need to repeat words

Comment [J27]: No need to write all capital letters

Comment [J28]: madibular

The crown, which was partially covered, was uncovered from the occlusal down to the equator using a rose head round bur in a slow speed turbine with continual irrigation of 0.9 % normal saline after deploying the mucoperiosteal flap and revealing the surgery location (Searle Ltd. Pakistan). After exposing the impacted tooth, tooth was sectioned with slow speed turbine with a straight fissure bur with copious irrigation Normal Saline 0.9%. The tooth was partitioned and elevated with the couplain straight elevator, following which any jagged bone was smoothed with a curving bone filer and the incision was secured with 3-0 Vicryl suture (Johnson & Johnson; made in USA). For 30 minutes, a sterile wrapped gauze (2 x 2) was placed over the surgical site to provide pressure and hemostasis. For 5 days, I took standard antibiotics (amoxicillin 500mg every 8 hours) and pain relievers (diclofenac potassium 50mg every 12 hours). The flap design employed for the extraction of the impacted lower third molar tooth, discomfort, and mouth opening was all reported on the proforma at the end of the procedure. On the seventh postoperative day, each individual was evaluated again.

Comment [J29]: 0.9%

Comment [J30]: normal saline 0.9%

DATA ANALYSIS PROCEDURE:

The data was examined using SPSS version 20.0, a statistical software application. For quantitative factors including age, pain score, and mouth opening, mean and standard deviation were determined. For qualitative

factors such as gender, edoema, trimus, wound dehiscence, and impaction kinds, frequencies and percentages were computed (mesioangular, distoangular, class II, class B). For quantitative factors like pain and mouth opening, the T test was used to compare the two groups. For quantitative factors like pain, the T test was used. Significant was defined as a P value less than or equal to 0.05.

Comment [J31]: t-test

Comment [J32]: t-test

Comment [J33]: justify please

Comment [J34]: remove

RESULTS

A total of 60 patients for surgical extraction of mandibular third molar randomly allocated 30 by envelop flap and 30 by modified triangular flap. The average age of patients in group A was 29.77 ± 7.17 years and 28.20 ± 6.28 years in group B as shown in Table 1. There were 50% male and 50% female. Gender distribution according to groups is also presented in figure 1.

Comment [J35]: Figure 1.

Out of 60 cases, swelling was observed in 53.3% in group A and 56.7% in group B, similarly rate of trismus was 50% in group A and 36.7% in group B, wound dehiscence was 43.3% in group A and 33.3% in group B as reported in Table 2. Regarding impaction types, mesioangular was the commonest impaction as presented in figure 2.

Comment [J36]: Figure 2.

Mean pain score was significantly low in group A as compare to group B [0.87 ± 0.86 vs. 2.93 ± 0.87 $p=0.0005$] as presented in figure 3. Mean mouth opening was significantly high in group A than group B [12.86 ± 3.59 vs. 6.12 ± 1.67 ; $p=0.0005$] as shown in figure 4.

TABLE 1

DESCRIPTIVE STATISTICS OF AGE ACCORDING TO GROUPS

Descriptive Statistics		Group A n=30	Group B n=30
Mean		29.77	28.20
Std. Deviation		7.17	6.28
95% Confidence Interval for Mean	Lower Bound	27.09	25.85

Comment [J37]: remove

Comment [J38]: Pay attention to the writing for the table.

	Upper Bound	32.44	30.55
--	-------------	-------	-------

UNDER PEER REVIEW

Comment [J39]: remove

FIGURE 1
GENDER DISTRIBUTION OF THE PATIENTS
ACCORDING TO GROUPS
n=60

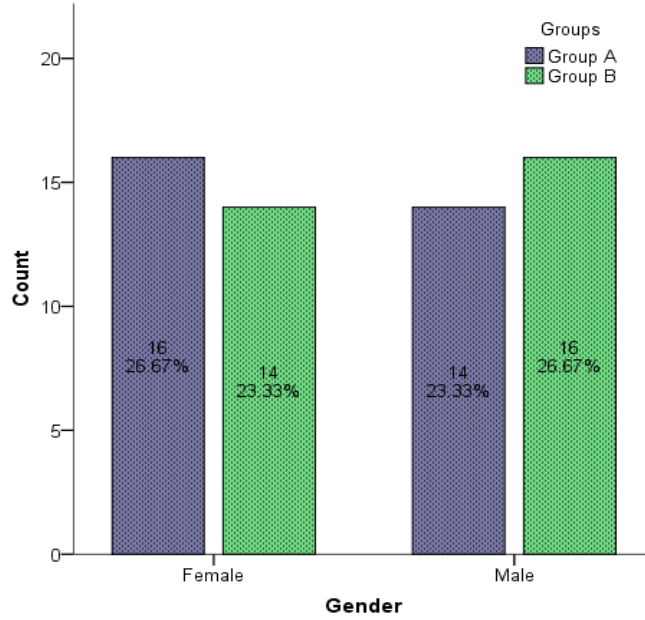


TABLE 2

RATE OF SWELLING, TRIMS AND WOUND DEHISCENCE BETWEEN GROUPS

Variables	Group A	Group B	Total

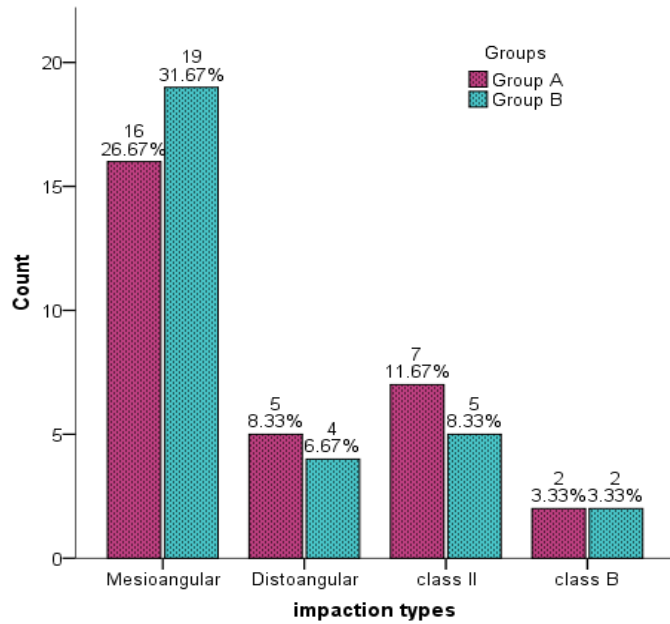
Swelling	16(53.3%)	17(56.7%)	33(55%)
Trimus	15(50%)	11(36.7%)	26(43.3%)
Wound Dehiscence	13(43.3%)	10(33.3%)	23(38.3%)

Comment [J40]: 55.0%

Comment [J41]: 50.0%

UNDER PEER REVIEW

FIGURE 2
 IMPACTION TYPE OF THE PATIENTS
 ACCORDING TO GROUPS
 n=60

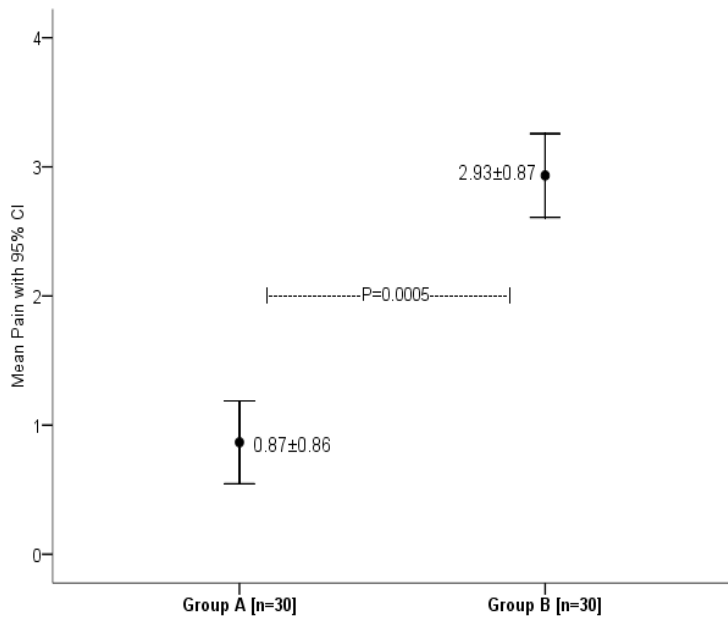


UNDER PEER

FIGURE 3

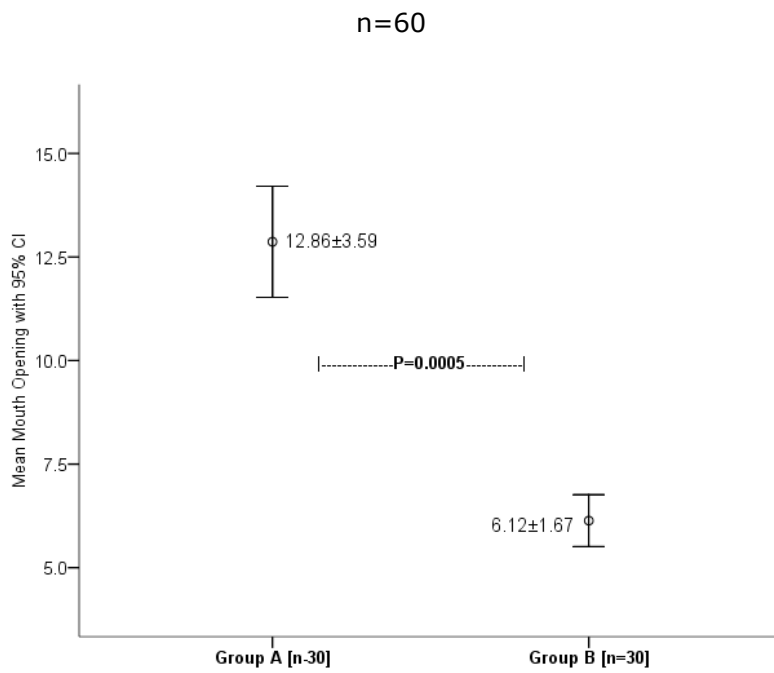
COMPARISON OF MEAN PAIN SCORE BETWEEN GROUPS

n=60



UNDER PEE

FIGURE 4
COMPARISON OF MEAN MOUTH OPENING BETWEEN GROUPS



UNDER PEE

DISCUSSION

Comment [J42]: Please add a more complete discussion section. For example: possible side effects such as dry sockets and their handling. Please explain the other types of flaps, the reasons for choosing these two flaps in this case report..

Based on the surgeon's view, two types of flaps, envelope or modified triangular, can be employed in lower-impacted wisdom teeth procedures. The concern is whether the use of each of those flaps has a distinct effect on the occurrence of dry sockets.^[14,15] Dry socket was detected in 2 out of 32 patients after employing triangle flap and 7 out of 32 instances after utilising envelop flap (EF), according to a research conducted by Kirk et al^[16]. In a separate paper by Nusair and Younis^[17], they reported a 4.8 percent prevalence of dry socket occurrence, with 3.2 % in non-surgical tooth extraction and 20 % in impacted third molar removal procedures.

Comment [J43]: 3.2%

The mean age of the individuals in this research was 29.77 ± 7.17 years in group A and 28.20 ± 6.28 years in group B. Males made up half of the group, while females made up the other half. Patients in the Koyuncu et al^[9] research ranged in age from 18 to 40 years old, with an average age of 23.30 years. There were 29 women and 7 men among the patients.

In present study out of 60 cases, swelling was observed in 53.3% in group A and 56.7% in group B similarly rate of trismus was 50% in group A and 36.7% in group B. wound dehiscence was 43.3% in group A and 33.3% in group B as reported. Furthermore, according to a research done by Dolanmaz, there was no substantial variation in postoperative edoema following impacted third molar surgery among the envelope and modified triangular flaps.^[18]

Comment [J44]: Oedema/edema

Minimal incisions with little mucoperiosteum reflectivity are related with decreased postoperative discomfort and edoema, according to research.^[19]

Comment [J45]: Oedema/edema

The observations of the current investigation demonstrated that the differences in mean pain intensity between the envelope and the modified triangular flap were significant statistically. In comparison to group B, group A's mean pain score was considerably lower [$p=0.0005$]. In a research done by Sandhu et al^[20] and AliasghariAbandansari S and Foroughi R^[21], greater pain ratings were seen with the envelope flap layout, which is comparable to the results of our investigation.

Kirk et al found no statistically meaningful differences in pain between the envelope and triangle flap styles, which is consistent with our observations.^[16] Sandhu et al investigated the effects of modified triangular and envelope flap layouts on postoperative trismus and reported no differences in either type.^[13,20] The average discomfort among modified triangular flap patients was 0.85 ± 1.15 on the seventh day, and the mean mouth opening was 4.03 ± 1.02 on the seventh day, according to a research done by Koyuncu BO et al. The mean pain score for the envelop flap was 2.16 ± 1.12 , while the mean rating for mouth opening was 12.25 ± 9.08 .^[9]

Comment [J46]: Give the space

Comment [J47]: Give the space

Since the envelope flap does not necessitate the relieving cut and is highly prudent, it was believed that the envelope flap would show a reduced constraint in mouth opening throughout the postoperative phase. According to Kim et al^[22] and Oliveira et al^[23], the degree of mouth opening reduction

is related to the complexity of the technique, the extent of tooth involvement, and the surgical time, with the more complex the method and the higher the requirement for an osteotomy and tooth segmentation, the higher the risk of postoperative side effect. In this trial, group A had a considerably higher mean mouth opening than group B [$p=0.0005$]. Conard et al^[24] discovered acute trismus on the first postoperative day after third molar operation in a clinical investigation. Azaz^[25] found sluggish trismus recovery in 13% of instances of mild-moderate trismus 10 days after surgery in another clinical investigation. Trismus was highest at 24 hours and was remained evident 15 days after third molar surgery, according to Cerqueira.^[26] The kind of incision had no effect on trismus, according to Van Gool^[27] and Suarez-Cunheiro.^[28] Sandhu^[20] investigated the impact of modified triangle and envelope flap layouts on postoperative trismus and observed no substantial differences in either category. Likewise, Kirk et al^[16] looked at the effects of envelope and modified triangular flap patterns on postoperative trismus and found that the flap patterns they utilised had no negative effects on participant's postoperative trismus.

According to Garcia^[29], the degree of discomfort after third molar surgery decreased between days 1 and 5. Erdogan^[11] investigated the impact of triangular and envelope flaps on discomfort following mandibular third molar removal and discovered that envelope flaps result in lower VAS ratings than triangle flaps.

The envelop flap allows the surgeon easier access to the operation site. In this flap, the clinician can also deepen the sulcular incision from the anterior region while maintaining a wide base. In this instance, circulation would be greater and sewing would be faster. Different publications look into the potential drawbacks of envelop flap, such as the damage of periodontal ligament during sulcular incisions across the teeth, a boost in osteoclastic action during the lifting of the mucoperiosteal flap, which leads to more bone loss, and a higher risk of wound rupture during the postsurgical era.^[8,30]

The modified triangular flap is a more conservative flap than the others, resulting in minimal tissue response. The soft tissue on the buccal of the second molar is elevated as a result of this. This state allows for quick wound sealing and tension-free sutures, but unlike the EF, it is not extensible.^[14]

COMPETING INTERESTS DISCLAIMER:

Authors have declared that no competing interests exist. The products used for this research are commonly and predominantly use products in our area of research and country. There is absolutely no conflict of interest between the authors and producers of the products because we do not intend to use these products as an avenue for any litigation but for the advancement of knowledge. Also, the research was not funded by the producing company rather it was funded by personal efforts of the authors.

Comment [J48]: Put at the end, after the conclusion

CONCLUSION

Within the report's constraints, it can be inferred that the triangle flap layout was superior to the envelope flap in terms of discomfort and mouth opening. In contrast to the envelope flap, the triangular flap was more effective in terms of postoperative periodontal condition of the neighboring third molar and wound healing dehiscence.

REFERENCES

1. Juodzbaly G, Daugela P. Mandibular Third Molar Impaction: Review of Literature and a Proposal of a Classification. *J Oral Maxillofac Res.* 2013;4:1-12
2. Agarwal KN, Gupta R, Faridi MM, Kalra N. Permanent dentition in Delhi boys of age 5-14 years. *Indian Pediatr.* 2004;41:1031-5.
3. Peterson LJ, Ellis E, Hupp JR, Tucker MR, editors. Contemporary oral and maxillofacial surgery. St.louis, MO: Mosby; 1988.
4. Divya T, Themozhi MS. Third molar impaction- a review. *J Pharm Sci Res* 2014;6:363-67.
5. Dodson TB. The management of the asymptomatic, disease-free wisdom tooth: removal versus retention. (review). *Atlas Oral Maxillofac Surg.* 2012;20;(2):169-76.
6. Bodh R, Jain A. The flap design of third molar surgery: an overview. *Int J Med Health Res.* 2015;1(3):32-35

Comment [J49]: References are not updated, in fact there is a literature with the year 1988. Please update.

7. Kumar A, Memon A, Panjabi SK, Shams S. Flap design: Comparison of ward's flap versus modified ward's flap in surgical extraction of impacted mandibular third molar. *Professional Med J* 2019; 26(8):1323-1327.
8. Baqain ZH, Shaffi AA, Hamdan AA. Flap design and mandibular third molar surgery: a split mouth randomized clinical study. *Int J Oral Maxillofac Surg.* 2012;41:1020-24.
9. Koyuncu BO, Zeytinoglu M, Cetingul E. Comparison of 2 different flap techniques in the surgical removal of bilateral impacted mandibular third molars: *Turk J Med Sci.*2013;43:891-98.
10. Blanco G, Lora D, MarzolaC. The different types of flaps in the surgical relations of the third impacted molars-literature review . *Dentistry.*2016;7(4):1-10
11. Erdogan O, That U, Ustun Y, Damlar I, Influence of two different flap designs on the sequelae of mandibular third molar surgery. *Oral Maxillofac Surg.*2011;15:147-52
12. Adarsh D, Rushit P, Kiran D, et al. Comparison of two incision designs for surgical removal of impacted mandibular third molar: A randomized comparative clinical study. *Contemp Clin Dent* 2014; 5:170-4.
13. Shahzad A, Munir F, Chatha R, Sohail A, The effect of two triangular flap designs for removal of impacted third molar on maximal mouth opening. *Pak Oral Dent J.* 2015;35:190-93.

14. Koyuncu BÖ, Çetingül E. Short-term clinical outcomes of two different flap techniques in impacted mandibular third molar surgery. *Oral Med Oral Pathol Oral Radiol Endod* 2013;116(3):e179-e184.
15. Elo JA, Sun H-H, Dong F, Tandon R, Singh HM. Novel incision design and primary flap closure reduces the incidence of alveolar osteitis and infection in impacted mandibular third molar surgery. *Oral Surg Oral Med Oral Pathol Oral Radiol*. 2016;122(2):124-133.
16. Kirk DG, Liston PN, Tong DC, Love RM. Influence of two different flap designs on incidence of pain, swelling, trismus, and alveolar osteitis in the week following third molar surgery. *Oral Surg Oral Med Oral Pathol Oral Radiol Endod* 2007;104(1):e1-e6.
17. Nusair YM, Younis MH. Prevalence, clinical picture, and risk factors of dry socket in a Jordanian dental teaching center. *J Contemp Dent Pract* 2007;8(3):53-63.
18. Dolanmaz D, Esen A, Isik K, Candirli C. Effect of 2 flap designs on postoperative pain and swelling after impacted third molar surgery. *Oral Surg Oral Med Oral Pathol Oral Radiol*. 2013;116:e244-6.
19. Shevel E, Koepp WG, Bütow KW. A subjective assessment of pain and swelling following the surgical removal of impacted third molar teeth using different surgical techniques. *SADJ*. 2001;56:238-41.

20. Sandhu A, Sandhu S, Kaur T. Comparison of two different flap designs in the surgical removal of bilateral impacted mandibular third molars. *Int J Oral Maxillofac Surg*. 2010;39:1091–6.
21. AliasghariAbandansari S, Foroughi R. Effect of releasing incision on the post operative complications of third molar surgery. *International Journal of Advanced Biotechnology and Research*. 2016;7:1144–51.
22. Kim HR, Choi BH, Engelke W, Serrano D, Xuan F, Mo DY. A comparative study on the extractions of partially impacted mandibular third molars with or without a buccal flap: a prospective study. *J Oral Maxillofac Surg* 2011;69:966–70.
23. Oliveira Neto PJ, de Souza Maliska MC, Sawazaki R, Asprino L, de Moraes M, Moreira RWF. Temporal abscess after third molar extraction in the mandible. *Oral Maxillofac Surg* 2012;16:107–10
24. Conard SM, Blakey GH, Shugars DA, Marciani RD, Phillips C, White RP. Patients' perception of recovery after third molar surgery. *J Oral Maxillofac Surg*. 1999;57:1288–94.
25. Azaz B, Shteyer A, Piamenta M. Radiographic and clinical manifestations of the impacted mandibular third molar. *Int J Oral Surg*. 1976; 5:153–60.
26. Cerqueira PRF, Vasconcelos BCE, Bessa-Nogueira RV. Comparative study of the effect of a tube drain in impacted lower third molar surgery. *J Oral Maxillofac Surg*. 2004;62:57–61.

27. Van Gool AV, Ten Bosch JJ, Boering G. Clinical consequences of complaints and complications after removal of the mandibular third molar. *Int J Oral Surg.* 1977;6:29-37.
28. Suarez-Cunqueiro MM, Gutwald R, Reichman J, OteroCepeda XS, Schmelzeisen R, Compostela S. Marginal flap versus paramarginal flap in impacted third molar surgery: a prospective study. *Oral Surg Oral Med Oral Pathol Oral RadiolEndod.* 2003;95:403-8.
29. Garcia AG, Sampedro FG, Rey JG, Torreira MG. Trismus and pain after removal of impacted lower third molars. *J Oral MaxillofacSurg* 1997; 55: 1223-6
30. Yolcu U, Acar AH. Comparison of a new flap design with the routinely used triangular flap design in third molar surgery. *Int J Oral Maxillofac Surg* 2015 Nov;44(11):1390-1397.