

### **IMMUNOTHERAPY-INDUCED VOGT KOYANAGI HARADA SYNDROME/CASE REPORT**

#### **ABSTRACT**

This report describes a case of Vogt Koyanagi Harada Disease (VKH) in a 44-year-old male with metastatic gastric carcinoma who presented with sudden onset headache and decreased vision. The patient was treated with first-line standard therapy for stage IV HER2-positive gastric adenocarcinoma and was on maintenance trastuzumab and pembrolizumab for seven months before developing new symptoms. His VKH was diagnosed after multiple imaging and a comprehensive ophthalmologic examination. The patient's vision and headaches improved with the initiation of corticosteroid therapy. Although immunotherapy was discontinued, trastuzumab was continued with close ophthalmology follow-up. He remains in stable condition despite his cancer. It is critical to consider and recognize immunotherapy-related ophthalmologic complications immediately, even if they are rare, considering their implications. Corticosteroids remain the first-line organ-saving therapy.

**Keywords:** Blurring vision, Vogt Koyanagi Harada disease, Pembrolizumab, Herceptin

#### **INTRODUCTION**

Therapy for metastatic gastric carcinoma has undergone significant changes in recent years. Previously, 5-fluoropyrimidine-based cytotoxic chemotherapy was the mainstay of therapy. With the identification of Her2 as a predictive marker, anti-Her2 therapy has been incorporated into

the therapeutic regimen for metastatic gastric carcinoma, as well as gastroesophageal carcinoma.

(1) In the recent years of checkpoint inhibitors, both pembrolizumab and nivolumab have also shown survival benefits in metastatic gastric carcinoma. Cytotoxic chemotherapy, combined with trastuzumab and pembrolizumab, is now recommended as the standard of care for first-line therapy for metastatic gastric carcinoma. (2)

Vogt Koyanagi Harada syndrome is an autoimmune granulomatous disease that affects all the main 'pigmented' or melanocyte-rich structures, such as the eyes, ears, meninges, skin, and hair.

It is a rare disease that is related to and affects only the central nervous system (CNS). Vogt Koyanagi Harada syndrome has an acute onset and is said to occur due to TH1 lymphocyte-mediated aggression against melanocytes. It usually occurs after a viral attack on the body and in the presence of the HLA-DRB1 allele. (3)

This disease was first described by Alfred Vogt in Switzerland, in 1906, when he encountered a patient with the sudden and bilateral onset of iridocyclitis, associated with the premature whitening of the eyelashes. (4) While the declining sight and hearing of the affected person might be the only presenting symptoms, Vogt Koyanagi Harada Syndrome is a multi-system inflammatory disease that is characterized by panuveitis. This may also be associated with various other neurological and skin manifestations, such as headaches, vertigo, poliosis, generalized weakness of the body, and abdominal pain. (5)

This genetic influence seems to vary from ethnicity to ethnicity. Indeed, the DRB1-04\*01 allele was found to be prevalent in the East Asian populations, whereas the HLA-DRB1 and HLA-DRB4 alleles were found to be more prevalent in the affected populations as a whole. (6)

People of any age group can be affected. It has been found adult patients are usually affected in the third or fourth decade of their lives, whereas in pediatrics, children up to age three can also be affected. Furthermore, females are seen to be affected twice as often as males. (7)

Corticosteroid therapy is the only mode of treatment for Vogt Koyanagi Harada syndrome. The mode of administration varies from topical to oral drugs and usually depends on the severity and intensity of the symptoms.

However, the sole focus of the physician should always be to reduce the number of complications and ensure that no irreversible damage occurs to the patient's eyes or any other affected body part.

In this report, we describe a case of VKH syndrome associated with pembrolizumab therapy administered to a patient with metastatic gastric carcinoma. We will also review previous cases published to date. (8)

## **CASE DESCRIPTION**

This case revolves around a 44-year-old male patient diagnosed with metastatic gastric carcinoma. The patient had Stage IV Her2-positive gastric cancer. There were nodal metastases in the retroperitoneum, pelvis, and left supraclavicular region. This was confirmed by computerized tomography-guided lymph node biopsy [MSS, HER-2 IHC 3+, PD-L1 + (CPS=20)]. The patient completed nine cycles of first-line palliative FOLFOX chemotherapy. Upon completion, the oxaliplatin was removed (due to side effects), and the patient continued with 5FU, Trastuzumab and Pembrolizumab for one more cycle. The patient received ten cycles of chemotherapy in total and was then maintained on Trastuzumab and Pertuzumab alone. As a chronic Hepatitis B carrier, he was put on entecavir. He also developed autoimmune hypothyroidism, for which he was treated by levothyroxine oral replacement therapy.

### **First Scan - October 2021:**

- *Little change in the ulcerated lesser curvature gastric mass.*
- *Retroperitoneal and pelvic lymphadenopathy are predominantly not significantly changed.*
- *Some indeterminate thoracic lymph nodes show areas of stability and marginal increase.*

### **Second Scan - November 2021:**

- *Stable gastric wall thickening that reduces the curvature of the junction between the body and the antrum of the stomach. Favor a T3 type lesion.*
- *Stable abdominal and pelvic adenopathy.*
- *Smaller right hilar lymph node.*
- *Stable small left low anterior neck and multi-compartmental mediastinal lymph nodes.*

### **Third Scan - February 2022**

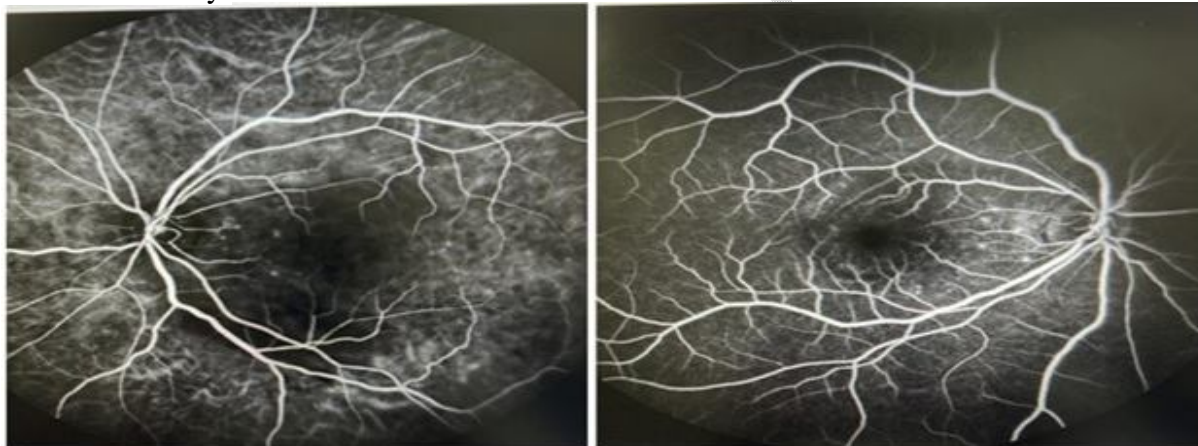
- *Asymmetric wall thickening in the gastric antrum.*
- *Stable lymphadenopathy in the chest, abdomen, and pelvis.*

The patient completed ten cycles of trastuzumab and pembrolizumab maintenance. A few days after cycle n°8, the patient developed sudden-onset headaches and decreased vision. He was evaluated in the emergency room and underwent a CT scan of the brain, which turned out normal. As his symptoms persisted, he sought care from an ophthalmologist.

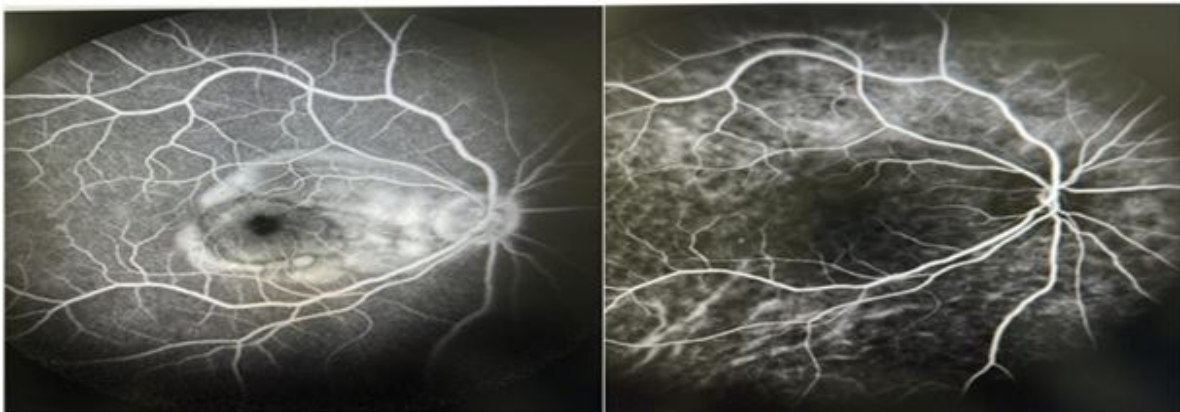
### **Imaging**

The patient's imaging details are as follows:

Fluorescein angiography showed multiple hyper-fluorescent spots that were increasing in size and intensity.



**Figure 1** Fluorescein angiography (1<sup>st</sup> Scan)



**Figure 2** Fluorescein angiography (2<sup>nd</sup> Scan)

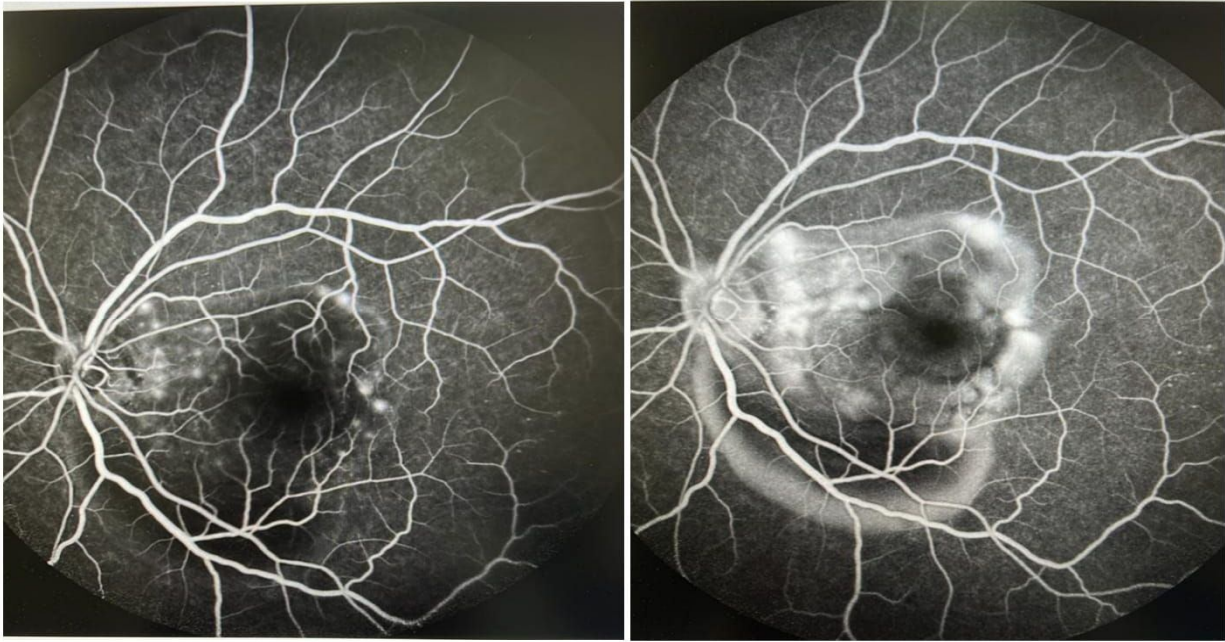


Figure 3: Fluorescein angiography (3<sup>rd</sup>Scan)

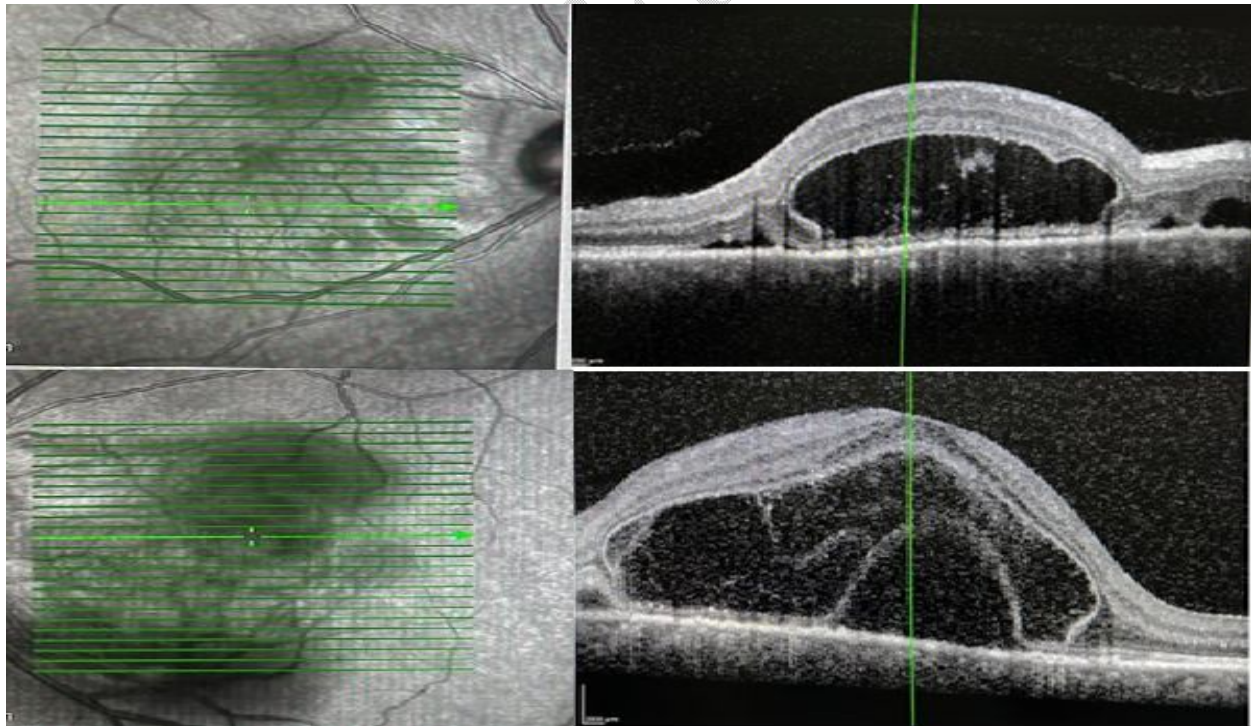


Figure 4: The optical coherence tomography (OCT) of the macula showed a loss of foveal contour and multiple pockets of submacular / subretinal fluids.

Slit lamp examination demonstrated that the anterior chamber was quiet and that there was a pinguecula in both eyes. The intra-ocular pressure was found to be 16 mm Hg in the right eye and 18 mm Hg in the left one. However, the optical coherence tomography (OCT) of the macula showed a loss of foveal contour and multiple pockets of sub-macular/sub-retinal fluids. Hyperreflective dots were also found in the subretinal fluids in both eyes, suggesting the presence of an underlying inflammatory pathology.

To elaborate on this pathology, an intravenous fluorescein angiogram (IVFA) and an indocyanine green angiogram (ICGA) were performed. The IVFA showed multiple hyper-fluorescent spots that were increasing in size and intensity, both of which indicated some sort of active leakage.

'Enhanced depth imaging optical coherence tomography' showed choroidal thickening. It was also confirmed by the ultrasound B-scan. The patient was diagnosed with Vogt Koyanagi Harada syndrome. For this, a course of methylprednisolone (1g/day for three days). He was also recommended oral prednisone (1-1.5mg/kg per day for at least 4 to 6 months). Pembrolizumab was discontinued, while Trastuzumab was continued as maintenance therapy.

## **DISCUSSION**

Vogt Koyanagi Harada syndrome is an uncommon or rare type of non-infectious uveitis that occurs in people with pigmented skin. For this reason, it is often found to affect Asians, Hispanics, Middle Easterns, and North Americans more than Africans. (9)

Since the disease is rare, its total prevalence worldwide is less than 10%. In the United States alone, Vogt Koyanagi Harada syndrome was found to occur in 1.5 to 6 patients per million, which is a significant gap. (10)

It was also found that females (78% approximately) are affected twice as often as males. Mostly middle-aged people are affected by this disease, ranging from the fourth to the sixth decade of life. Children and the elderly can also be affected by this condition. (11)

The actual cause of this disease remains unclear. Given its autoimmune and granulomatous etiology, it is obvious that some kind of ongoing insult within the immune system leads to the development of this disease.

The complications in both affected populations vary as well. Indeed, the pediatric population was found to be usually affected by subretinal fibrosis, while older people are affected by choroidal detachments and hyperemia of the optic disc. (12)

However, in the majority of the cases, it is the aggressive response of the TH-1 cells to melanocytes that leads to the development of this disorder. Usually, it is a viral trigger that triggers the stimulus for the aggressive response of TH-1 helper cells. (13)

Microscopically, there is a diffuse thickening of the uveal tract. This manifests in the acute stages as a granulomatous process. In the acute stages of the disease, we also notice the diffuse infiltration of lymphocytes, along with epithelioid cells and multinucleated giant cells taking up most of the space in the uveal tract. (14)

The American Uveitis Society (AUS) has adopted a particular criterion for the diagnosis of VKHD, as follows:

- No history of ocular trauma and/or surgery
- At least three of the following four signs:
  - a. Bilateral chronic iridocyclitis;
  - b. Posterior uveitis (multifocal exudative retinal or RPE detachments; disc hyperemia or edema; or 'sunset glow fundus', which is a yellow-orange appearance of the fundus due to depigmentation of the RPE and choroid);
  - c. Neurological signs (tinnitus, neck stiffness, symptoms of the cranial nerve or central nervous system, or cerebrospinal fluid pleocytosis);
  - d. Cutaneous findings (alopecia, poliosis, or vitiligo). (15)

Apart from the ocular manifestations, there are several extraocular manifestations as well. These include CNS symptoms (headaches, neck stiffness, confusion, and CSF pleocytosis), inner ear symptoms (tinnitus, hearing loss, and vertigo), and cutaneous findings (vitiligo, alopecia, and poliosis of the eyelashes, eyebrows, and hair). (16)

The treatment revolves around the patient receiving corticosteroids for their condition. The corticosteroids may be topical or oral, depending on the extent of the damage inflicted by the disease. The timing, dosing, and duration of corticosteroid therapy are important to prevent recurrence of the disease. (17)

## CONCLUSION

Vogt Koyanagi Harada syndrome is a rare disease. Since it is not usually encountered in hospital settings, it is obvious that dealing with it can be difficult. Diagnosis of the disease itself can be arduous, let alone starting treatment before symptoms turn worse.

However, it can be seen, in this case study, that the early diagnosis through imaging and findings could avoid complications.

Since the patient was already dealing with Stage IV metastatic cancer, it was feared that he might relapse or react to the treatment unfavorably. But the prognosis so far has been hopeful and in his favor, and is thought to remain that way in the days to come.

## REFERENCES

1. Ajani JA, Javle M, Eng C, Fogelman D, Smith J, & Anderson B, et al. Phase I study of DFP-11207, a novel oral fluoropyrimidine with reasonable AUC and low C<sub>max</sub> and improved tolerability, in patients with solid tumors. *Invest New Drugs*. 2020 Dec;38(6):1763-73.
2. Schlintl V, Huemer F, Rinnerthaler G, Melchardt T, Winder T, & Reimann P, et al. Checkpoint inhibitors in metastatic gastric and GEJ cancer: a multi-institutional retrospective analysis of real-world data in a Western cohort. *BMC Cancer*. 2022 Dec;22(1)

3. Herbort, C.P., &Mochizuki, M. "Vogt-Koyanagi-Harada disease: inquiry into the genesis of a disease name in the historical context of Switzerland and Japan." *Int Ophthalmol*. June 2007;27(2-3):67-79.
4. Kaza, H., Tyagi, M., Agarwal, K., Behera, S., Pappuru, R.R., &Mohan, S., et al. "Vogt Koyanagi Harada Disease In Paediatric Age Group: Clinical Characteristics, Remission, Recurrences and Complications in Asian Indian Population." *Semin Ophthalmol*. February 2022 17;37(2):187-92.
5. Shindo Y, Inoko H, Yamamoto T, &Ohno S. HLA-DRB1 typing of Vogt-Koyanagi-Harada's disease by PCR-RFLP and the strong association with DRB1\*0405 and DRB1\*0410. *Br J Ophthalmol*. 1994 Mar;78(3):223-6
7. Sugita, S., Takase, H., Kawaguchi, T., Taguchi, C.,&Mochizuki, M. "Cross-reaction between tyrosinase peptides and cytomegalovirus antigen by T cells from patients with Vogt-Koyanagi-Harada disease." *Int Ophthalmol*. 2007 June;27(2-3):87-95.
8. Rao NA, Gupta A, Dustin L, Chee SP, Okada AA, &Khairallah M, et al. Frequency of distinguishing clinical features in Vogt-Koyanagi-Harada disease. *Ophthalmology*. 2010 Mar;117(3):591-9, 599.e1.
9. Rubsamen, P.E., &Gass, J.D. "Vogt-Koyanagi-Harada syndrome. Clinical course, therapy, and long-term visual outcome." *Arch Ophthalmol*. May 1991;109(5): 682-7. 10.
10. Kiyomoto C, Imaizumi M, Kimoto K, Abe H, Nakano S, &Nakatsuka K. Vogt-Koyanagi-Harada disease in elderly Japanese patients. *Int Ophthalmol*. 2007 Jun;27(2-3):149-53.
11. Inomata H, &Rao NA. Depigmented atrophic lesions in sunset glow fundi of Vogt-Koyanagi-Harada disease. *Am J Ophthalmol*. 2001 May;131(5):607-14.
12. tern EM, Nataneli N. Vogt Koyanagi Harada Syndrome. [Updated 2022 May 15]. In: *StatPearls* [Internet]. Treasure Island (FL): StatPearls Publishing; 2022 Jan-. Available from: <https://www.ncbi.nlm.nih.gov/books/NBK574571/>
13. Bassili, S.S., Peyman, G.A., Gebhardt, B.M., Daun, M., Ganiban, G.J., &Rifai, A. "Detection of Epstein-Barr virus DNA by polymerase chain reaction in the vitreous from a patient with Vogt-Koyanagi-Harada syndrome." *Retina*. 1996;16(2):160-1.

14. Snyder DA, Tessler HH. Vogt–Koyanagi–Harada Syndrome. *American Journal of Ophthalmology*. 1980 Jul;90(1):69-75.

15. Fiore, T., Iaccheri, B., Androudi, S., Papadaki, T.G., Anzaar, F., &Brazitikos, P., et al. "Acute posterior multifocal placoid pigment epitheliopathy: outcome and visual prognosis." *Retina*. August 2009;29(7):994–1001.

16. Lavezzo MM, Sakata VM, Morita C, Rodriguez EE, Abdallah SF, &da Silva FT, et al. Vogt-Koyanagi-Harada disease: review of a rare autoimmune disease targeting antigens of melanocytes. *Orphanet J Rare Dis*. 2016 Mar 24;11:29.

**17.** Accorinti M, Saturno MC, Iannetti L, Manni P, Mastromarino D, &Pirraglia MP. Treatment and Prognosis of Vogt–Koyanagi–Harada Disease: Real-Life Experience in Long-Term Follow-Up. *JCM*. 2022 Jun 23;11(13):3632.

UNDER PEER REVIEW