

## Original Research Article

# Assessment of the Functional and Clinical Outcomes of Arthroscopic Release of Extensor Carpi Radialis Brevis in Management of Chronic Lateral Epicondylitis

### ABSTRACT

**Background:** Lateral epicondylitis commonly known as tennis elbow, is one of the commonest causes of elbow pain and dysfunction. It is due to excessive use of the muscles of the back of the forearm. Histological findings include granulation tissue and micro-rupture, degenerative changes with no traditional inflammation. Nowadays, management of tennis elbow is achieved through arthroscopy for release of extensor carpi radialis brevis (ECRB) tendon. **Aim:** To improve the quality of life of chronic lateral epicondylitis patients. **Subjects and Methods:** This study was Quasi experimental study where Twenty-five patients with chronic lateral epicondylitis were enrolled in the study and were subjected to history taking, physical examination, and then they underwent arthroscopic release of (ECRB) tendon for management of chronic lateral epicondylitis. Outcomes were assessed by Nirschl tennis elbow score and DASH scoring system. **Results:** A total of 25 patients with mean age of  $43.5 \pm 6.6$  years and 44% were males. Sixty-eight percent of them had no comorbidities. Ninety-six percent of the participants had history of previous steroid injections with the mean of  $1.8 \pm 0.8$ . There was statistically decrease in DASH score among patients after 6 and 12 weeks of operation than preoperative ( $p < 0.001$ ). Also, there was statistically significant improvement in the NIRSCHL score among patients after 6 and 12 weeks compared to preoperative score ( $P < 0.001$ ). Postoperative complications were reported among only 2 patients. **Conclusion:** we suggested that arthroscopic release of extensor carpi radialis brevis is effective in management of chronic lateral epicondylitis as it is improving function and decreasing impairment. So, we consider extensor carpi radialis brevis tendon release is a good option for treatment of lateral epicondylitis with minimal complications.

*Keywords: Tennis Elbow, Elbow Arthroscopy, Lateral Epicondylitis, Arthroscopic Release.*

### 1. INTRODUCTION

Tennis elbow, also known as lateral epicondylitis, is a condition in which the outer part of the elbow becomes painful and tender. The pain may also extend into the back of the forearm and grip strength may be weak. Onset of symptoms is generally gradual. It is due to excessive use of the muscles of the back of the forearm.<sup>(1)</sup>

In TE, the extensor carpi radialis brevis (ECRB) tendon is involved in more than 95% of all cases. Sometimes, the extensor digitorum, extensor digiti minimi, and extensor carpi ulnaris are also involved<sup>(2)</sup>

Histological findings include granulation tissue, and micro-rupture, degenerative changes with no traditional inflammation. Longitudinal sonogram of the lateral elbow displays thickening and heterogeneity of the common extensor tendon that is

consistent with tendinosis, as the ultrasound reveals calcifications, intra-substance tears, and marked irregularity of the lateral epicondyle. Although the term “epicondylitis” is frequently used to describe this disorder, most histopathologic findings of studies have displayed no evidence of an acute, or chronic, inflammatory process. Histologic studies have demonstrated that this condition is the result of tendon degeneration, which replaces normal tissue with a disorganized arrangement of collagen. Therefore, the disorder is more appropriately referred to as tendinosis or tendinopathy rather than tendinitis. <sup>(3)</sup>

Multiple modalities for management of lateral epicondylitis are available. Physical therapy including stretches and progressive strengthening exercises to prevent re-irritation of the tendon. Bracing which is a device externally used on the limb to improve the function or reduce the pain, anti-inflammatories are commonly prescribed for treatment of tennis elbow. Corticosteroid injections may be effective in short term, however they are of little benefit after a year, compared to a wait-and-see approach. <sup>(4)</sup>

There are a lot of surgical procedures that have been reported in the literature including, open, mini-open, percutaneous, and arthroscopic release. Arthroscopic tennis elbow release gained popularity in the last few years with promising results. <sup>(5)</sup>

The arthroscopic approach to lateral epicondylitis varies by surgeon. Some prefer to debride the lateral capsule and in folded tissue that may impinge within the radio-capitellar joint, while others focus debridement on the extensor origin. <sup>(1)</sup>

## **2. MATERIAL AND METHODS**

### **2.1 STUDY DESIGN**

This study was quasi experimental study following approval of our institutional research board. It was carried out at the department of Orthopedic Surgery and Trauma, Suez Canal University hospital (SCUH), Ismailia, Egypt. We included patients with lateral epicondylitis not responding to conservative treatment for more than 6 months with ages between 21 and 60. •Patients with history of trauma, internal fixation or previous open release were excluded from the study.

### **2.2 SAMPLING**

Convenience Sampling technique was used. The calculated sample size was 22 participants; however, after adding the expected (drop-out) rate (10%), the final sample size was 25 participants.

### **2.3 DATA COLLECTION TOOL**

Pre-operative assessment in form of history taking, physical examination, pre-operative Nirschl tennis elbow score and pre-operative DASH score. Post-operative assessment in form of Nirschl tennis elbow score and DASH score at 6- and 12- weeks post-operative. In DASH score the possible score ranges from 0 to 100 points. 0 points represent a complete, unrestricted function of the upper extremities, while 100 points represent the greatest possible functional impairment. In Nirschl tennis elbow score the possible score ranges from 0 to 80 points. 80 points represent a complete, unrestricted function of the upper extremities, while 0 points represent the greatest possible functional impairment

### **2.4 DATA Management**

The collected data was computerized and statistically analyzed using SPSS program (Statistical Package for Social Science) version 26. Data was tested for normal distribution using the Shapiro Walk test. Qualitative data was represented as frequencies and relative percentages. Quantitative data was expressed as mean and standard deviation. Paired t test was used to calculate difference between quantitative and qualitative variables in the same group for parametric and non-parametric variables. Level of P-value < 0.05 indicates significant while, P ≥ 0.05 indicates non-significant difference.

### 3. RESULTS

A total sample of 25 participants were included in this study with the mean age of  $43.5 \pm 6.6$  years ranging from 33 to 58 years. Forty-four percentage were males and 56% were females. Twenty-four percent of the participants were housewife, 40% were manual workers, 20% were employees. Only 8% were drivers and 8% were nurses.

Variable		n= 25
Age (years)	Mean $\pm$ SD	43.5 $\pm$ 6.6
	Median (Range)	43 (33- 58)
Gender	Male, n (%)	11 (44)
	Female, n (%)	14 (56)
Occupation	Housewife, n (%)	6 (24)
	Manual worker, n (%)	10 (40)
	Employee, n (%)	5 (20)
	Driver, n (%)	2 (8)
	Nurse, n (%)	2 (8)

Chart (1) Distribution of age, gender, and occupation among the studied cases.

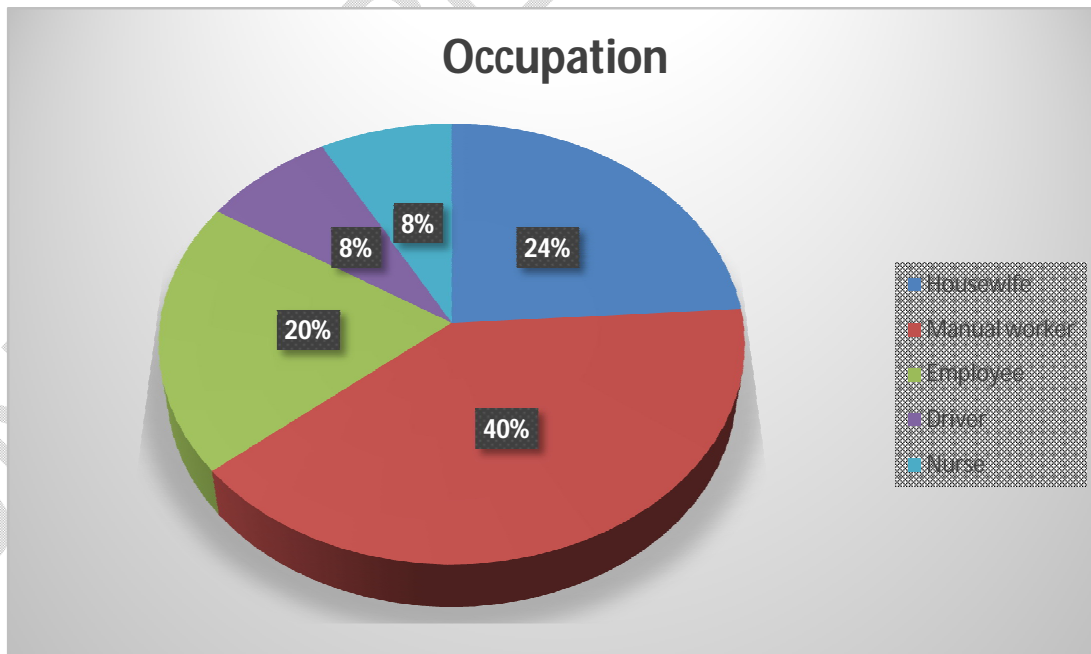
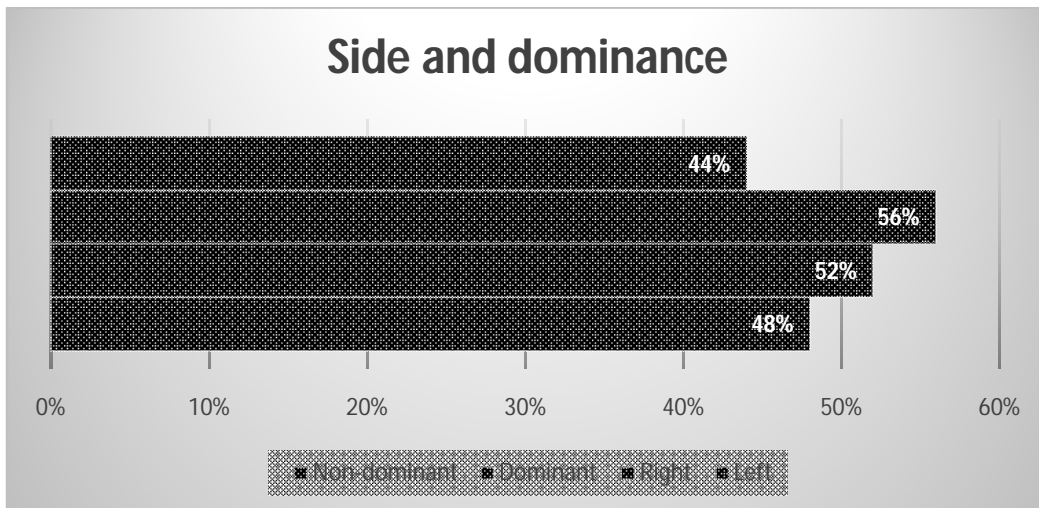


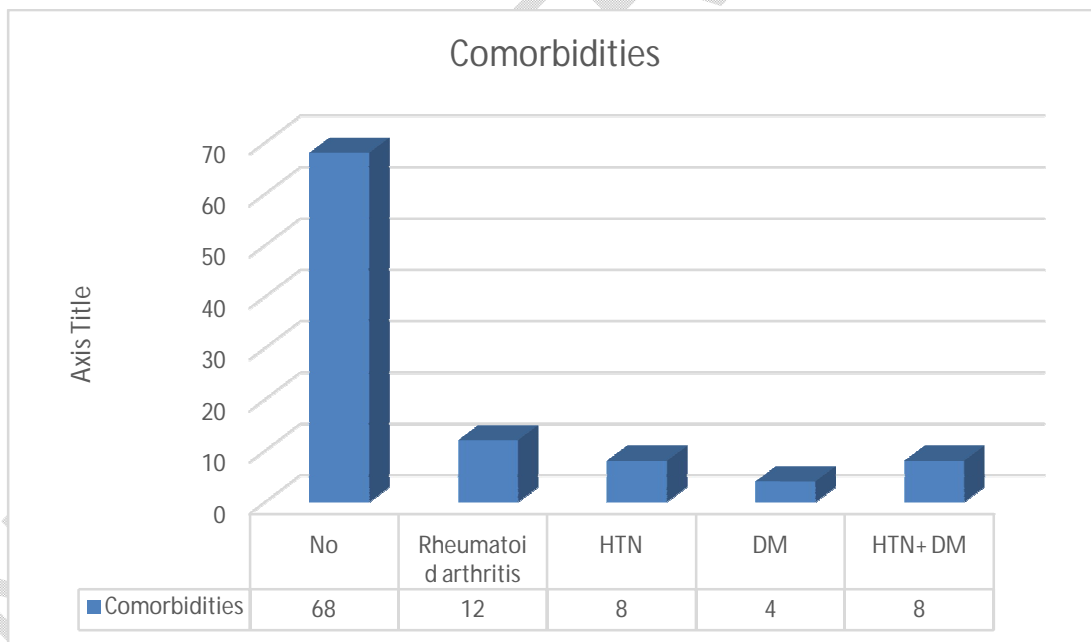
Chart (2) Distribution of occupation among the studied cases.

The affected side was right among 48% of the participants and 52% had left affected side. On the other hand, 56% had affected dominant side and 44% had non-dominant side.



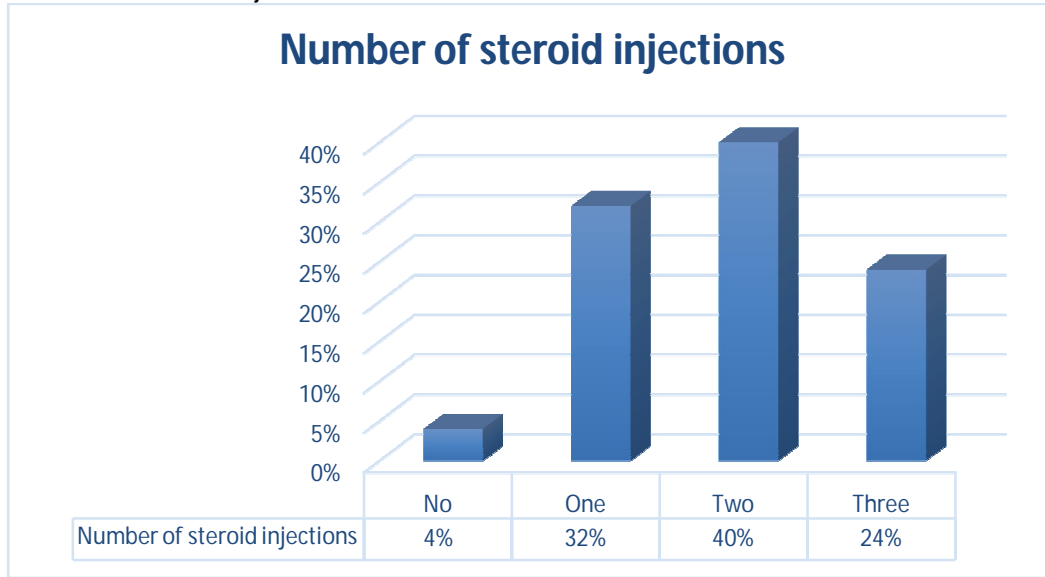
**Chart (3) Distribution of side and dominance among the studied cases**

Among the total participants, 68% had no comorbidities, while 12% had rheumatoid arthritis, 8% had hypertension, 4% had diabetes and 8% had both diabetes and hypertension.



**Chart (4) Distribution of comorbidities among the studied cases**

The participants reported symptoms of chronic lateral epicondylitis for mean duration of  $10.4 \pm 2.9$  months. Four percent of the participants had no history of steroid injection, 32% had one steroid injection, 40% tried two times of steroid injections and 24% had three times of steroid injections.

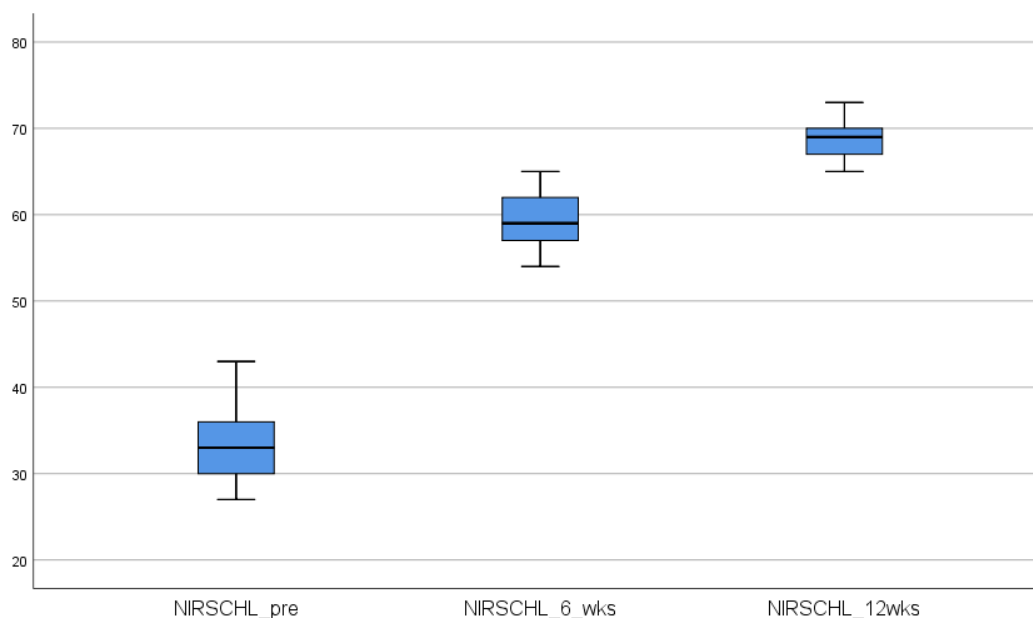


**Chart (5) Number of pre-operative injections per patient**

There was statistically decrease in DASH score among patients after 12 weeks of operation than preoperative ( $14.0 \pm 3.1$  vs.  $67.1 \pm 4.8$  respectively,  $p < 0.001$ ). Also, there was statistically significant improvement in the NIRSCHL score among patients after 12 weeks compared to preoperative score ( $68.9 \pm 2.4$  vs.  $33.4 \pm 4.3$ ,  $P < 0.001$ ).

Variable		Preoperative	Postoperative	P value
DASH	Mean $\pm$ SD	$67.1 \pm 4.8$	$21 \pm 2.5$	<b>&lt;0.001*</b>
	Median (Range)	68 (58, 75)	21 (17- 25)	
NIRSCHL	Mean $\pm$ SD	$33.4 \pm 4.3$	$59.4 \pm 2.9$	<b>&lt;0.001*</b>
	Median (Range)	33 (27, 43)	59 (54- 65)	

**Chart (6) Comparison between pre-operative and post-operative DASH and NIRSCHL scores.**



**Chart (7) Comparison between pre-operative and post-operative DASH and NIRSCHL scores.**

#### 4.DISCUSSION

Twenty-five patients with chronic lateral epicondylitis participated in this study. The mean age of  $43.5 \pm 6.6$  years and median of 43 years ranging from 33 to 58 years. While 44% were males and 56% were females. In Egypt, Zayed, (2020) studied 30 patients with lateral epicondylitis underwent arthroscopic ERCB release compared to open release with the mean age of 37.5 years among them 56.7% were males.<sup>(6)</sup> Similar to our results, Soeur et al., (2016) studied 42 patients with chronic lateral epicondylitis with the mean age  $48 \pm 8.4$  ranging from 31 to 76 years with 47.6% males.<sup>(7)</sup>

In the current study twenty-four percent of the participants were housewife, 40% were manual workers, 20% were employees. Only 8% were drivers and 8% were nurses. Based on Lattermann et al., (2010) results, lateral epicondylitis were reported with high percentage (66%) among manual workers and those whose work including repetitive movement (75%).<sup>(8)</sup>

In this study, 68% had no comorbidities, while 12% had rheumatoid arthritis, 8% had hypertension, 4% had diabetes and 8% had both diabetes and hypertension. Similarly, Yoon et al., (2015) assessed comorbidities among the lateral epicondylitis patients and found 8.9% had diabetes and 24.4% had hypertension.<sup>(9)</sup>

In the current study, the affected side was right among 48% of the participants and 52% had left affected side. On the other hand, 56% had affected dominant side and 44% had non-dominant side. Zayed, (2020) demonstrated that lateral epicondylitis was more common in right side than left side (70% vs 30% respectively). Also, dominant side was frequently reported than non-dominant (83.3% vs 16.7% respectively).<sup>(7)</sup> A study agreed with our results by Yoon et al., (2015), found the dominant side were more affected than non-dominant side among chronic lateral epicondylitis patients (64.4% vs 35.6%).<sup>(9)</sup>

Our results found symptoms of chronic lateral epicondylitis for mean duration of  $10.4 \pm 2.9$  months. Equally, Fahmy et al., (2022) examined patients with the mean duration of symptoms before operation of  $10.8 \pm 2.6$  months ranging from 6 to 15 months.<sup>(11)</sup> Another study supported our results by Zayed, (2020) who included patients who suffered from symptoms of lateral epicondylitis for a period of 11.4 months.<sup>(6)</sup>

In the current study, there was statistically decrease in DASH score among patients after 6 weeks of operation than preoperative ( $21 \pm 2.5$  vs.  $67.1 \pm 4.8$  respectively,  $p < 0.001$ ). Also, there was statistically decrease in DASH score among patients after 12 weeks of operation than preoperative ( $14.0 \pm 3.1$  vs.  $67.1 \pm 4.8$  respectively,  $p < 0.001$ ). This goes in line with Soeur et al., (2016) who found postoperative DASH score after arthroscopic and at last follow up visit was  $15.9 \pm 19.1$ .<sup>(7)</sup> Also, Mohamed et al., (2021) agreed the significant difference between Quick DASH score pre and post operative among lateral epicondylitis patients had arthroscopic release of ERCB.<sup>(12)</sup> In accordance with our results, Zayed, (2020)

found significant difference between DASH score preoperative and after 3 weeks postoperative ( $25.13 \pm 4.94$  vs.  $10.40 \pm 3.92$  respectively,  $p < 0.001$ ).<sup>(6)</sup>

In this study statistically significant improvement in the NIRSCHL score among patients after 6 weeks compared to preoperative score ( $59.4 \pm 2.9$  vs.  $33.4 \pm 4.3$ ,  $P < 0.001$ ) was reported. Also, there was statistically significant improvement in the NIRSCHL score among patients after 12 weeks compared to preoperative score ( $68.9 \pm 2.4$  vs.  $33.4 \pm 4.3$ ,  $P < 0.001$ ). In the same side, Egyptian study by Mohamed et al., (2021) found significant differences between NIRSCHL score preoperative and postoperative ( $p < 0.001$ ).<sup>(12)</sup> Comparable with our results, Colombi et al., (2019) found postoperative NIRSCHL score was  $67.5 \pm 9.8$  among patients had arthroscopic release of ERCB.<sup>(12)</sup>

Postoperative complications were reported among only 2 patients (8%). One of them had recurrence and treated with steroid injection while the other one had superficial infection of portal wound managed with antibiotics. Four percent of the participants had synovitis and 4% had radio capitellar plica associated with chronic lateral epicondylitis. In the same side, Fahmy et al., (2022) reported one patient with postoperative tourniquet neuropraxia and this problem resolved 3 weeks later. But no patient had elbow instability nor recurrence.<sup>(11)</sup> Also, Zayed, (2020) said that only one participant underwent arthroscopic release of ERCB reported transient ulnar nerve palsy which was improved completely.<sup>(7)</sup>

## 5. LIMITATIONS

This study had limitations. The first one is the absence of a control group for comparison to increase the evidence of our results. The second one is the short follow up duration which does not give a result about long term outcomes. While the strength of this study was the use of standardized tools to assess the clinical and functional outcomes after arthroscopic release of ERCB.

## 6. CONCLUSION

In conclusion our study suggested that Arthroscopic Release of Extensor Carpi Radialis Brevis is effective in Management of Chronic Lateral Epicondylitis as it is improving function and decreasing impairment as reported by DASH and NIRSCHL scores. So, we consider extensor carpi radialis brevis tendon release to be a good option for treatment of lateral epicondylitis with minimal complications.

## CONSENT

Participants had the right to refuse to participate in the study. Participants had the right to withdraw from the study at any time without giving any reason. Participants' data was kept confidential, and any data manipulation or transfer was done using codes. All authors declare that written informed consent was obtained from all participants.

## ETHICAL APPROVAL

All procedures of the study were approved by the department of Orthopedics surgery, Suez Canal University. The study protocol was approved by the faculty of medicine ethics committee.

## REFERENCES

1. Hubbard MJ, Hildebrand BA, Battafarano MM, Battafarano DF. Common Soft Tissue Musculoskeletal Pain Disorders. *Prim Care*. 2018 Jun;45(2):289-303. doi: 10.1016/j.pop.2018.02.006. PMID: 29759125.
2. Descatha A, Albo F, Leclerc A, Carton M, Godeau D, Roquelaure Y, Petit A, Aublet-Cuvelier A. Lateral Epicondylitis and Physical Exposure at Work? A Review of Prospective Studies and Meta-Analysis. *Arthritis Care Res (Hoboken)*. 2016 Nov;68(11):1681-1687. doi: 10.1002/acr.22874. PMID: 26946473.
3. McShane JM, Shah VN, Nazarian LN. Sonographically guided percutaneous needle tenotomy for treatment of common extensor tendinosis in the elbow: is a corticosteroid necessary? *J Ultrasound Med*. 2008 Aug;27(8):1137-44. doi: 10.7863/jum.2008.27.8.1137. PMID: 18645071.
4. Krogh TP, Bartels EM, Ellingsen T, Stengaard-Pedersen K, Buchbinder R, Fredberg U, Bliddal H, Christensen R. Comparative effectiveness of injection therapies in lateral epicondylitis: a systematic review and network

meta-analysis of randomized controlled trials. *Am J Sports Med.* 2013 Jun;41(6):1435-46. doi: 10.1177/0363546512458237. Epub 2012 Sep 12. PMID: 22972856.

5. Szabo SJ, Savoie FH 3rd, Field LD, Ramsey JR, Hosemann CD. Tendinosis of the extensor carpi radialis brevis: an evaluation of three methods of operative treatment. *J Shoulder Elbow Surg.* 2006 Nov-Dec;15(6):721-7. doi: 10.1016/j.jse.2006.01.017. Epub 2006 Sep 11. PMID: 16963287.
6. Zayed F. Comparative Study: Arthroscopic Versus Open Tennis Elbow Release. *Al-Azhar International Medical Journal.* 2020 Sep 18;0(0).
7. Soeur L, Desmoineaux P, Devillier A, Pujol N, Beaufile P. Outcomes of arthroscopic lateral epicondylitis release: Should we treat earlier? *OrthopTraumatol Surg Res.* 2016 Oct;102(6):775-80. doi: 10.1016/j.otsr.2016.05.017. Epub 2016 Aug 31. PMID: 27591940.
8. Lattermann C, Romeo AA, Anbari A, Meininger AK, McCarty LP, Cole BJ, Cohen MS. Arthroscopic debridement of the extensor carpi radialis brevis for recalcitrant lateral epicondylitis. *J Shoulder Elbow Surg.* 2010 Jul;19(5):651-6. doi: 10.1016/j.jse.2010.02.008. PMID: 20541097.
9. Lee SY, Kim W, Lim C, Chung SG. Treatment of Lateral Epicondylitis by Using Allogeneic Adipose-Derived Mesenchymal Stem Cells: A Pilot Study. *Stem Cells.* 2015 Oct;33(10):2995-3005. doi: 10.1002/stem.2110. Epub 2015 Aug 6. PMID: 26202898.
10. Fahmy FS, ElAttar M, Salem HF. Hand-Grip Strength and Return to Heavy Manual Work at a Mean 5-Year Follow-up After Arthroscopic Release of Recalcitrant Lateral Epicondylitis. *Orthopaedic Journal of Sports Medicine.* 2022;10(2). doi:10.1177/23259671221078586.
11. Mohamed, M., Zaghlool, A., Addosooki, A., Khalifa, A. FUNCTIONAL OUTCOME OF ARTHROSCOPIC RELEASE OF EXTENSOR CARPI RADIALIS BREVIS MUSCLE IN TREATMENT OF CHRONIC LATERAL EPICONDYLITIS (TENNIS ELBOW). *Egyptian Journal of Orthopedic Research,* 2021; 2(1): 39-46. doi: 10.21608/ejor.2021.175573.
12. Colombi R, Bevand A, Devillier A, Baulot E, Ezzahoui A, Martz P. Exclusive Posterolateral Arthroscopic and Endoscopic Approaches Used in the Treatment of Lateral Epicondylitis. *Orthopedics.* 2019 Nov 1;42(6):e521-e527. doi: 10.3928/01477447-20191001-03. Epub 2019 Oct 7. PMID: 31587076.