

Case study

Fahr's Syndrome Secondary to Hypoparathyroidism Presenting with Paralysis and Recurrent Seizures: A Case Report.

ABSTRACT

Aim: To describe a rare case of Fahr's syndrome (FS) associated with chronic post-surgical hypoparathyroidism and hypocalcemia.

Case presentation: A 63-year-old female with a previous history of total thyroidectomy and **hemiplegia** presented to our hospital with altered mentation and recurrent generalized tonic-clonic seizures. Laboratory evaluation revealed hypoparathyroidism, hypocalcemia, and hypokalemia. Head computed tomography (CT) scan was consistent with FS, **demonstrating extensive, bilateral, and symmetrical calcified deposits in the brain, predominantly in basal ganglia, corona radiata, and cerebellar hemispheres.** The association with post-surgical hypoparathyroidism and relevant biochemical indices determined the suspected etiology of the pathologic process of ectopic calcification.

Discussion: FS is a rare, neurodegenerative disorder characterized by abnormal bilateral ectopic calcified deposits in the basal ganglia and other brain structures. FS presents with a wide variety of neurological and psychiatric manifestations. The diagnosis is confirmed by neuroimaging studies such as a head CT scan or magnetic resonance imaging, which displays the calcification of BG and other structures in a bilateral and symmetrical pattern. **Biochemical analysis may adjunctively identify the underlying risk factor of the disease.**

Conclusion: Our case represents a long-term severe consequence of untreated post-surgical hypoparathyroidism, which has consequently led to irreversible secondary FS. **Maintenance of eucalcemic and euphosphatemic states is essential to prevent the progression of ectopic cerebral calcification.**

Keywords: Fahr's syndrome, Fahr's disease, hypoparathyroidism, basal ganglia calcifications.

1. INTRODUCTION

Fahr's syndrome (FS) is a rare, neurodegenerative, metabolic disorder characterized by symmetrically- and bilaterally-distributed calcified deposits in the brain parenchyma. Its primary form, Fahr's disease (FD), is distinguished from FS by the absence of identifiable secondary etiologies. **It has been genetically attributed to an autosomal dominant pattern** (1). The calcification is predominantly deposited in the basal ganglia (BG), dentate nuclei, cerebellum, and subcortical white matter (2). Its prevalence is estimated to be 1/1,000,000 (1–3). FS is also commonly referred to in the literature as bilateral basal ganglia calcification (BBGC), bilateral striopallidodentate calcification, and calcinosis nucleorum (1–3).

BBGC manifests in a wide variety of clinical manifestations, which include, but are not limited to, seizures, memory impairment, neuropsychiatric symptoms, motor dysfunction, and speech problems. Other features also include headache, orthostatic hypotension, vertigo, and papilledema secondary to raised intracranial pressure (ICP) (4).

2. PRESENTATION OF CASE

A 63-year-old female was brought to the emergency department on March 22, 2022, with altered mental status and worsening bilateral extremity weakness for 2 days. She was a known case of a prior cerebrovascular accident and uncontrolled hypertension. She also exhibited recurrent generalized tonic-clonic seizures. The relatives denied the presence of subjective fever, difficulty breathing, vomiting, and change in urine color and frequency.

Her past medical history was notable for hospital admission 1 month ago due to right-sided weakness. The admission was also complicated with urinary retention and episodes of urinary tract infections. Furthermore, the patient underwent a total thyroidectomy 30 years ago complicated by hypocalcemia. Subsequent laboratory investigations revealed the diagnosis of post-surgical hypoparathyroidism. Her routine medications include levothyroxine 100 µg/day and supplemental calcium; her compliance with medication cannot be elucidated. Family history was irrelevant.

On physical examination, the patient appeared obtunded; her Glasgow Coma Scale was E1V2M4. Vital signs showed blood pressure (BP) of 120/50 mmHg, heart rate (HR) of 90 beats/min, respiratory rate (RR) of 24/min, temperature of 36.6°C, and oxygen saturation (SpO₂) of 97% on room air. Neurological examination displayed spastic paralysis more pronounced in the right extremities and bilateral hyperreflexia. Sensory functions were difficult to assess. Furthermore, biochemical evaluations were notable for K⁺ of 2.6 mg/dL (N: 3.5 – 5.1 mg/dL) and Ca²⁺ of 8.0 mg/dL (N: 8.5 – 10.5 mg/dL). Her serum vitamin D concentration was normal, while the parathyroid hormone (PTH) was 5.5 pg/mL (N: 8.7 – 79.6 pg/mL). Other values including leukocyte counts, thrombocyte counts, and thyroid function tests were within normal range.

An anteroposterior chest radiograph was notable for cardiomegaly. Notwithstanding, a non-contrast computed tomography (CT) scan (figure 1) demonstrated hyperintense foci distributed bilaterally on the BG, corona radiata, and cerebellar hemispheres, indicating a possible calcification process. Mild bilateral ventricular enlargement was also illustrated. Correspondingly, the patient is diagnosed with FS secondary to chronic inadequately-treated post-surgical hypoparathyroidism.

Upon arrival and initial assessment, the patient was positioned 30° head-up with a sniffing position. The airway patency was secured by the nasopharyngeal airway with 4 liters per minute of oxygen. A nasogastric tube, peripheral intravenous (IV) cannula, and urinary catheter were inserted. Pharmacological management included IV mannitol 100 mL 6 hourly, IV dexamethasone 10 mg 8-hourly, IV phenytoin 150 mg 8-hourly, IV paracetamol 1 g 8-hourly, and correction of serum electrolytes.

Routine monitoring of hemodynamic status, electrolyte concentrations, and frequency of seizures was carried out intensively and treated accordingly. On the 6th day of admission, the frequency of seizures had significantly decreased. However, the patient was noted to experience shortness of breath, appeared distressed, and febrile. Vital signs showed HR of 107/min, RR of 30/min, temperature of 38°C, SpO₂: 97%, and BP of 114/64 mmHg. Routine blood tests showed leukocytosis with predominant neutrophilia. The patient was diagnosed with hospital-acquired pneumonia (HAP) and was given ciprofloxacin 200 mg IV 12-hourly and ceftazidime 1 g 8-hourly IV.

Alas, on the 8th day of treatment, the patient experienced apnea, the carotid pulse was not palpable, pupils were fixed and dilated, and the electrocardiogram showed no electrical activity. After resuscitative attempts, the patient was subsequently declared dead secondary to HAP.

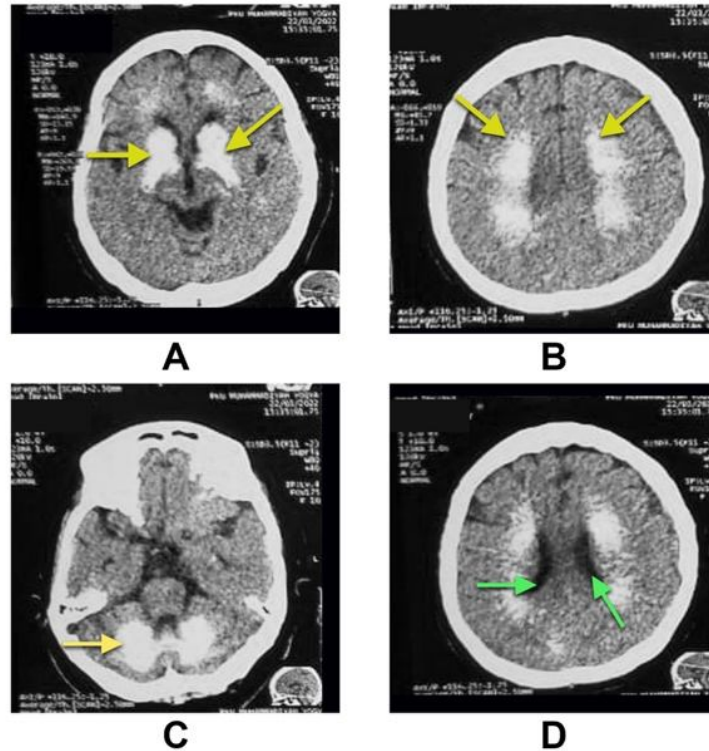


Figure 1: Head CT scan of the patient showing bilateral and symmetrical calcification of the BG (A), corona radiata (B), and cerebellar hemispheres (C). There is a mild bilateral dilatation of lateral ventricles (D).

3. DISCUSSION

The term BBGC was first described by Delacour, et al. in 1850 to illustrate a postmortem brain biopsy illustrating bilateral calcification in the BG and its vasculatures in a patient presenting with lower limb paralysis (5). However, the condition is now more eponymously known as FS, which refers to Theodor Fahr, a German pathologist who reported similar pathological findings in 1930 in an 81-year-old patient presenting with dementia and paralysis (6). The association of FS with hypoparathyroidism was first described by Eaton, et al. in 1939 (7).

In contrast to the described pathogenesis of ectopic mineralization in FD that occurs mainly due to dystrophic calcification, the mineralization FS, such as in the setting of hypoparathyroidism, is thought to be triggered via metastatic calcification as a consequence of systemic mineral imbalance (4,8). Albeit the pathogenesis of cerebral calcification in a hypocalcemic milieu is not yet completely understood, some authors proposed the hypothesis of decreased calcium/phosphate ratio and elevated serum calcium-phosphate products resulting in ectopic calcium deposition (9). Meanwhile,

others suggested an increased expression of osteogenic molecules in cases of hypoparathyroidism, such as osteonectin and osteopontin, predominantly in caudate nuclei (10).

Our patient presented with right hemiparesis, spasticity, and generalized tonic-clonic seizures. Kalampokini, et al. (11) reviewed 233 case reports of hypoparathyroid FS and demonstrated that the common clinical presentations include tetany (51.4%), motor disturbance (48.4%), seizures (46.5%), and neuropsychiatric manifestations. Parkinsonism contributed to the majority of the motor abnormalities. Overlaps of symptoms were observed, such as the mixed presentation of hypokinesia, cognitive deficits, and cerebellar defects (3,11). Diagnostic criteria have been proposed by Perugula et al. (1) and Saleem et al. (2) (table 1), incorporating neurological manifestations, associated comorbidities, and imaging findings on the CT scan or magnetic resonance imaging. In addition, single proton emission computed tomography may also show significantly reduced perfusion to the calcified brain areas.

Table 1: Diagnostic Criteria of Fahr’s Syndrome (FS) and Fahr’s Disease (FD) (1–3)

Consider the diagnosis of FS or FD in the presence of some or all of the following presentations:		
	Basal ganglia (BG) movement disorder (extrapyramidal). Cognitive disturbance. Cerebellar disorder. Psychiatric presentation.	Pyramidal signs. Gait abnormalities. Speech dysfunction. Sensory changes.
Consider the diagnosis of FD if:	Consider the diagnosis of FS if:	
Age	40-60 years	30-40 years
Associated conditions	Positive family history Associated autosomal dominant or recessive pattern of inheritance	Any of the following endocrinopathies: idiopathic or secondary hypoparathyroidism, pseudohypoparathyroidism, pseudopseudohypoparathyroidism, hyperparathyroidism and One of the following conditions: - Congenital brucellosis - Neuroferritinopathy - Tuberous sclerosis - Mitochondrial myopathy - <i>Lipoid proteinosis</i>
Pattern of calcification	Coarse, progressive, symmetrical, and bilateral calcification of BG.	Symmetrical and bilateral intracranial calcification
Management	Symptomatically-directed treatment No definitive therapy.	The treatment is aimed at the underlying pathology Symptomatic therapy adjunctively

Heretofore, there is no known definitive therapy for FS and FD. The management is generally aimed at alleviating the presenting symptoms. Nevertheless, in cases of FS with an identified secondary etiology, more attention needs to be paid in treating the underlying primary pathology, with adjunctive therapy for alleviating the presenting symptoms. Therefore, early diagnosis of secondary FS is essential to prevent further

progression of FS and potentially reverse the pathology of intracranial calcifications. Goswami et al. (9) reported in patients with idiopathic hypoparathyroidism, that the evidence of BG calcification identified on radiological imaging is approximately 73.8%. The finding is also correlated with the duration of hypocalcemia and the value of the calcium/phosphate ratio. Accordingly, improvement of serum calcium as well as calcium/phosphorus ratio needs to be done as early as possible to prevent or reverse the development of secondary FS. There is evidence showing that for every 1% increase in the calcium/phosphate ratio during follow-up, the probability of developing BG calcification decreased by 5% (9).

The conventional cornerstone therapy for hypoparathyroidism involves calcium and vitamin D supplementation (**table 2**) (12,13). The European Society of Endocrinology (ESE) and the American Association of Clinical Endocrinologists guidelines recommended maintaining serum calcium in hypoparathyroidism at the lower normal range, i.e. 8–9 mg/dL, as long as the patient is free of symptoms of hypocalcemia (12–14). Calcium carbonate is generally preferred to calcium citrate because it has more elemental calcium by molecular weight (40% vs 21%). However, calcium citrate is preferred in the elderly population, especially those taking antacids, proton pump inhibitors, or those with low gastric acidity, as gastric acidity is not essential for the absorption of calcium citrate. The general dose of calcium carbonate is 1 to 2 g given in divided doses of 500 mg each time, although some cases require up to 9 g per day (13). High doses of calcium should be avoided because it can increase the risk of long-term complications such as impaired renal function and ectopic calcifications (13,14). The 24-hour urinary calcium and creatinine should be monitored every 6 months to once a year to monitor for hypercalciuria.

Table 2. Recommended therapy in hypoparathyroidism

Drug	Dose	Comments
Calcium supplementation		
Calcium carbonate	1 – 9 g/day in 2 – 4 divided doses	Necessitates a high stomach acidity for absorption Requires to take with a meal for optimal absorption
Calcium citrate		Doesn't require a high stomach acidity and prior meal for its absorption
Vitamin D supplementation		
Ergocalciferol (D2) or Cholecalciferol (D3)	400-800 IU/day	
Calcitriol	0.25–2.0 µg/day	
Alfacalcidol	0.5–4.0 µg/day	
Adjuvant therapy		
Hydrochlorothiazide	12.5-100 mg/day	Consider as adjuvant therapy for hypocalcemia; act mainly reduce the urinary calcium excretion in the evidence of hypercalciuria.
Chlorthalidone	25-100 mg/day	
Indapamide	1.25-5 mg/day	
Amiloride	5 mg/day	

Furthermore, the ESE recommended calcitriol as a vitamin D supplement because the conversion of vitamin D to its active form via the kidneys might be impaired in hypoparathyroidism (14,15). However, calciferol, especially cholecalciferol, can be used if calcitriol is not available. There is also some evidence to support the use of calciferol in

conjunction with calcitriol due to the association of low vitamin D levels with negative effects on bone and extraskeletal health (16). Therefore, ESE also recommended vitamin D supplementation at a dose of 400-800 IU/day.

A promising treatment for hypoparathyroidism is the use of PTH analogs, including teriparatide (PTH 1-34) and recombinant human PTH 1-84 (rhPTH 1-84). Both PTH (1-34) and PTH (1-84) have been shown to reduce the need for vitamin D supplementation and increased markers of bone turnover (17). Importantly, teriparatide administration has been evaluated for the treatment of hypoparathyroidism in both the adult and pediatric populations and appears to be safe and efficacious in improving urinary calcium concentrations, serum calcium levels, and quality of life (18-19). Meanwhile, rhPTH 1-84 was approved by the FDA in 2015 as an adjunctive therapy for hypoparathyroidism in individuals who are not adequately controlled with conventional therapy. The REPLACE study, a randomized, double-blind, placebo-controlled clinical trial conducted in 134 adults with hypoparathyroidism showed that 53% of subjects treated with rhPTH 1-84 reduced supplemental calcium and active vitamin D by >50%, with 43% of subjects able to completely discontinue all vitamin D supplements and reduce her calcium dose to <500 mg/d and maintain normal serum calcium (20). Indications for the use of the proposed PTH analogs are listed in **Table 3**.

Table 3. Indication to consider the administration of rhPTH 1-84 in hypoparathyroidism (17)

1. Poor control of serum calcium (corrected serum calcium: <7.5 mg/dL) or clinical symptoms.
2. Oral calcium supplementation > 2.5 g/day or 1,25-(OH)D > 1.5 mcg/day or 1-alpha vitamin D > 3.0 mcg/day.
3. Hypercalciuria, nephrolithiasis, nephrocalcinosis, reduced creatinine clearance or eGFR (<60 mL/min), or increased risk of stones by biochemical analysis of urine.
4. Hyperphosphatemia or calcium-phosphate products >55 mg/dL (4.4 mmol/L)
5. Gastrointestinal dysfunction due to intrinsic disease or after bariatric surgery
6. Reduced quality of life

4. CONCLUSION

Hypoparathyroidism is one of the most important reversible risk factors for secondary FS. The progression of ectopic calcification is preventable and potentially reversible if hypocalcemia is properly corrected and maintained. Duration of hypocalcemia and low calcium/phosphate ratio in FS are considered to be the best predictors of the development of BG calcification in cases of hypoparathyroidism. Management with calcium, vitamin D supplementation, and adjunctive therapy is needed to prevent acute symptoms and long-term complications. PTH analogs may be considered in recalcitrant cases. **The case study we provided is aimed at increasing awareness of one of the most dreaded long-term complications of hypoparathyroidism and highlights the importance of maintenance of serum calcium and phosphate.**

ACKNOWLEDGEMENT

Not applicable.

COMPETING INTERESTS

The authors declare that they have no competing interests.

AUTHORS' CONTRIBUTIONS

EK experienced the case. EK and MJ gathered the available data. MJ wrote the first draft of the manuscript. EK supervised the report and writing of the manuscript. All authors read, reviewed, and approved the final manuscript.

CONSENT

Written informed consent was obtained from the patient's relative for the publication of this case report and accompanying images.

ETHICAL APPROVAL

As per international standards or university standards, written ethical approval has been collected and preserved by the authors.

REFERENCES

1. Perugula ML, Lippmann S. Fahr's disease or Fahr's syndrome? *Innov Clin Neurosci.* 2016;13(7–8):45.
2. Saleem S, Aslam HM, Anwar M, Anwar S, Saleem M, Saleem A, Rehmani MA. Fahr's syndrome: literature review of current evidence. *Orphanet J Rare Dis.* 2013; doi: 10.1186/1750-1172-8-156.
3. Donzuso G, Mostile G, Nicoletti A, Zappia M. Basal ganglia calcifications (Fahr's syndrome): related conditions and clinical features. *Neurol Sci.* 2019; doi: 10.1007/s10072-019-03998-x.
4. De Vilder EY, Vanakker OM. From variome to phenome: Pathogenesis, diagnosis and management of ectopic mineralization disorders. *World J Clin Cases.* 2015; doi: 10.12998/wjcc.v3.i7.556.
5. Ghormode D, Maheshwari U, Kate N, Grover S. Fahr's disease and psychiatric syndromes: A case series. *Ind Psychiatry J.* 2011; doi: 10.4103/0972-6748.102527.
6. de Oliveira JRM, Oliveira MF, Lemos RR, et al The current status of "Fahr's disease" nosology. *Practical Neurology.* 2009; doi: 10.1136/jnnp.2009.182923
7. Jihwaprani MC, Kumara EG. Fahr's syndrome secondary to hypoparathyroidism presenting with paralysis and recurrent seizures: a case report. *Research Square.* 2023; doi: 10.21203/rs.3.rs-2766767/v1.

8. Snijders BMG, Peters MJL, Koek HL. Ectopic Calcification: What Do We Know and What Is the Way Forward? *J Clin Med*. 2023; doi: 10.3390/jcm12113687.
9. Goswami R, Sharma R, Sreenivas V, Gupta N, Ganapathy A, Das S. Prevalence and progression of basal ganglia calcification and its pathogenic mechanism in patients with idiopathic hypoparathyroidism. *Clin Endocrinol (Oxf)*. 2012; doi: 10.1111/j.1365-2265.2012.04353.x.
10. Goswami R, Millo T, Mishra S, Das M, Kapoor M, Tomar N, Saha S, Roy TS, Sreenivas V. Expression of osteogenic molecules in the caudate nucleus and gray matter and their potential relevance for Basal Ganglia calcification in hypoparathyroidism. *J Clin Endocrinol Metab*. 2014; doi: 10.1210/jc.2013-3863.
11. Kalampokini S, Georgouli D, Dadouli K, Ntellas P, Ralli S, Valotassiou V, Georgoulas P, Hadjigeorgiou GM, Dardiotis E, Xiromerisiou G. Fahr's syndrome due to hypoparathyroidism revisited: A case of parkinsonism and a review of all published cases. *Clin Neurol Neurosurg*. 2021; doi: 10.1016/j.clineuro.2021.106514.
12. Abate EG, Clarke BL. Review of Hypoparathyroidism. *Front Endocrinol (Lausanne)*. 2017; doi: 10.3389/fendo.2016.00172.
13. Bilezikian JP. Hypoparathyroidism. *J Clin Endocrinol Metab*. 2020; doi: 10.1210/clinem/dgaa113.
14. Bollerslev J, Rejnmark L, Marcocci C, Shoback DM, Sitges-Serra A, van Biesen W, Dekkers OM; European Society of Endocrinology. European Society of Endocrinology Clinical Guideline: Treatment of chronic hypoparathyroidism in adults. *Eur J Endocrinol*. 2015; doi: 10.1530/EJE-15-0628.
15. Brandi ML, Bilezikian JP, Shoback D, Bouillon R, Clarke BL, Thakker RV, Khan AA, Potts JT Jr. Management of Hypoparathyroidism: Summary Statement and Guidelines. *J Clin Endocrinol Metab*. 2016; doi: 10.1210/jc.2015-3907.
16. Di Maio S, Soliman AT, De Sanctis V, Kattamis CC. Current treatment of hypoparathyroidism: Theory versus reality waiting guidelines for children and adolescents. *Acta Biomed*. 2018; doi: 10.23750/abm.v89i1.7118.
17. Cusano NE, Rubin MR, Sliney J Jr, Bilezikian JP. Mini-review: new therapeutic options in hypoparathyroidism. *Endocrine*. 2012; doi: 10.1007/s12020-012-9618-y.
18. Gafni RI, Brahim JS, Andreopoulou P, Bhattacharyya N, Kelly MH, Brillante BA, Reynolds JC, Zhou H, Dempster DW, Collins MT. Daily parathyroid hormone 1-34 replacement therapy for hypoparathyroidism induces marked changes in bone turnover and structure. *J Bone Miner Res*. 2012; doi: 10.1002/jbmr.1627.
19. Winer KK, Zhang B, Shrader JA, Peterson D, Smith M, Albert PS, Cutler GB Jr. Synthetic human parathyroid hormone 1-34 replacement therapy: a randomized crossover trial comparing pump versus injections in the treatment of chronic hypoparathyroidism. *J Clin Endocrinol Metab*. 2012; doi: 10.1210/jc.2011-1908.
20. Clarke BL, Vokes TJ, Bilezikian JP, Shoback DM, Lagast H, Mannstadt M. Effects of parathyroid hormone rhPTH(1-84) on phosphate homeostasis and vitamin D metabolism in hypoparathyroidism: REPLACE phase 3 study. *Endocrine*. 2017; doi: 10.1007/s12020-016-1141-0.