

## **Case study**

### **ACUTE MYOCARDIAL INFARCTION REVEALING A POLYCYTHEMIA VERA: A CASE REPORT**

#### **ABSTRACT :**

Acute myocardial infarction is usually seen in the setting of atherosclerosis and its associated risk factors. One of the rare causes of AMI in young patients is polycythemia vera.

We report the case of 38-year-old male with a history of tobacco use, who presented with constrictive chest pain and ST segment elevation in leads V1 through V6, DI and AvL. His blood investigation report showed higher levels of hemoglobin and hematocrit. The search for the JAK2V617F mutation in the blood came back positive. The patient was diagnosed with polycythemia vera.

This case illustrates the importance of considering PV a cardiovascular risk factor, making early diagnosis crucial for early initiation of preventive treatment.

**Keywords:** Polycythemia vera, Myocardial infarction, JAK2 mutation.

#### **INTRODUCTION:**

Acute myocardial infarction (AMI) is usually seen in the setting of atherosclerosis and its associated risk factors. Myocardial infarction in the young poses a particular challenge, as other non-atherosclerotic causes have to be explored. One of the rare causes of AMI in young patients is polycythemia vera (PV)<sup>1</sup>, previously known as Vaquez disease. PV is a myeloproliferative disorder characterized by an increase in the red blood cell line. The morbidity and mortality of patients is mainly due to thrombotic and, to a lesser extent, hemorrhagic events<sup>2</sup>. The

predictive factors of these thrombotic events as well as their pathophysiology still need to be clarified despite recent progress in this field.

### **CASE PRESENTATION:**

We report the case of 38 year old male with a history of tobacco use, who presented to the emergency department for sudden onset of at rest of constrictive chest pain radiating to the shoulders evolving for eight hours

He was a lifetime non smoker with no history of hypertension, diabetes mellitus or hyperlipidemia.

On examination, the patient had good general status overall. He had angina at rest. The Blood pressure was 120/70 mmHg, Heart rate 120 beats per minute (bpm) and respiratory rate 16 breaths per minute. He had no signs of heart failure, with a normal central venous pressure and clear lungs on auscultation. Cardiac auscultation didn't find any murmurs.

The ECG showed: sinus tachycardia at 120 bpm, ST segment elevation in leads V1 through V6, DI and AvL (antero-lateral leads), and Q waves in leads V1 through V6. Reciprocal ST segment depression was noted in the inferior leads (Figure 1).

A diagnosis of antero-lateral STEMI with late presentation was made, and the patient was taken to the cath Lab.

On coronary angiography, the patient had acute total occlusion of the mid left anterior descending artery (LAD). The RCA and the circonflexe arteries didn't have significant disease. A PCI of the mid LAD was performed with a drug eluting stent (DES) (Figure 2).

On echocardiography, the left ventricle (LV) was not dilated. There was severe hypokinesis of the apex extending to the apical and medial segments of the antero-septal, anterior, antero-lateral and inferior walls. The LV ejection fraction was reduced at 35% and the LV filling pressures were high. There was no right heart dysfunction, nor mitral regurgitation or ventricular septal defect.

On routine laboratory testing, the high sensitivity troponins Ic level was 39581ng per liter; the creatinine level was 8,4 mg/l. The hemoglobin level

was high at 21,6 g/ dl, the hematocrit was high at 60,2%. White Blood Cell (WBC) count was 24230/ microL, and the polymorphonuclear neutrophils (PMN) were 17400/ microliter.

The Lipid panel was normal: Total Cholesterol at 1,2g/L, Low density lipoprotein-Cholesterol (LDL-C) at 1,49 g/L, High Density Lipoprotein-Cholesterol (HDL-C) at 0,55 g/L and Triglycerides at 0,85 g/L

Given the relatively young age of the patient, the high hemoglobin and hematocrit levels, a type 2 myocardial infarction in the context of Polycythemia Vera (PV) was suspected, and we performed screening of the JAK2 mutation as well as osteo medullar biopsy.

the search for the JAK2V617F mutation in the blood came back positive, and the osteo-medullar biopsy revealed the presence of erythroid and megakaryocytic precursors, several megakaryocytes with dysplastic nucleus indicating a chronic myeloproliferative syndrome.

Our final diagnosis was STEMI due to Polycythemia Vera

For further management the patient received dual antiplatelet therapy, guideline directed heart failure therapy and PV disease specific therapy which included planned phlebotomy and hydroxyurea.

## **DISCUSSION:**

Cardiovascular disease remains the leading cause of adverse outcomes among young people worldwide, in stark contrast to the decline in other age groups. This group is understudied and has a unique risk profile, with fewer traditional cardiovascular risk factors compared with older populations. Plaque rupture remains the most common cause of myocardial infarction, but other nonatherosclerotic causes account for a greater proportion in this age group, including spontaneous coronary artery dissection, coronary artery spasm, microvascular dysfunction, and prothrombotic states such as polycythemia vera<sup>3,4</sup>.

Polycythemia vera (PV) is a primary disorder of bone marrow stem cells resulting in overproduction of red cells and, to a lesser extent, neutrophils and platelets. Academically, Polycythemia Vera (PV) is defined as an acquired increase in hemoglobin/ hematocrit level above 16.5 gm/dL/49% in men and 16 g/dL/48% in women, in the context of a JAK2 mutation and characteristic bone marrow morphology<sup>2</sup>. The 2017 WHO classification of tumors of hematopoietic and lymphoid tissues lists

3 major criteria (1- HB/HCT level above 16.5 g/dL/49% in men and 16 g/dL/48% in women or red cell mass >25% above mean normal predicted value; 2- Typical bone marrow morphology; 3- The presence of a JAK2V617F (exon 14) or exon 12 mutation) and 1 minor criterion (subnormal serum erythropoietin level) for the formal diagnosis of PV. The diagnosis is then made in the presence of 3 major criteria or 2 major criteria and one minor criterion.<sup>5</sup>

Vascular thrombosis is the most common cause of mortality and morbidity in patients with PV, but bleeding complications have also been described. Thrombosis can be venous or arterial. The incidence of thrombotic events in patients with PV is high, estimated at 40-60% over a 10 year period<sup>6</sup>. The most common thrombotic event is ischemic stroke, followed by myocardial infarction and less frequently, acute limb ischemia<sup>7</sup>. The 10-year incidence of MI in PV is 11,4% according to a study by Rossi and Al<sup>8</sup>. In some cases, MI can reveal PV<sup>1</sup>, which was the case for our patient.

The predictive factors for thrombotic events identified in PV are few and controversial. The two most recognized predisposing factors are : age greater than 60 years and a personal history of thrombotic events, consequently, a patient is considered high risk if one of the two latter conditions is present, and low risk if both are absent<sup>2</sup>. This treatment-relevant risk stratification is designed to estimate the likelihood of thrombotic complications. Counter-intuitively, Platelet count and hematocrit do not appear to be reliable predictors.

Recently, it has been shown that leukocyte load may be a factor in thrombotic events<sup>9</sup>. Another study by Malak et al<sup>8</sup> identified that the presence of the JAK2V617F mutation in the population correlated with an increased frequency of thrombotic events<sup>10</sup>. However, there is currently no sufficient and reproducible evidence formalizing WBC count or JAK2V617F allele load as independent risk factors for thrombosis in PV<sup>2</sup>.

To this day, the pathophysiology of MI in patients with PV is not well understood. However, the available data points towards a mechanism different from atherosclerosis.

Several elements seem to be involved in the occurrence of thrombotic events in PV, including an increase in blood viscosity secondary to the increase in hematocrit and a stimulation of platelet aggregation and thrombogenesis<sup>1</sup>. Leukocyte load may also play a role in the pathophysiology of PV and not only as a predictive factor. Indeed, in vivo polynuclear activation in PV has shown evidence of activation of the endothelium and coagulation system. An increase in platelet and leukocyte aggregation has also been demonstrated in patients with PV, which could promote prothrombotic phenomenas<sup>9</sup>. Other suggested cases include, Oxidative stress<sup>6</sup> and Intimal proliferation<sup>11</sup>

The cornerstones of PV treatment include planned phlebotomy with a hematocrit (Hct) target < 45% and daily low-dose aspirin therapy in all patients, regardless of risk category<sup>12,13</sup>. In high risk patients, such as the case for our patient, there is a broad consensus regarding the need for cytoreductive therapy<sup>14</sup>. Hydroxyurea is recommended as first-line therapy in patients > 60 years. Unfortunately, a quarter of patients become resistant to it over time, pegylated interperion alpha is a reasonable alternative in younger patients<sup>15</sup>. Other therapies can be discussed, mainly ruxolitinib (JAK2 inhibitor) and busulfan<sup>16,17</sup>. Our patient received hydroxyurea albeit his young age due to the unavailability of pegylated interperion in our structure.

Regarding acute coronary syndrome, there are no specific guidelines for myocardial revascularization in patients with polycythemia vera ; Consequently, we performed urgent coronary angiography and primary percutaneous coronary intervention (PCI) of the Culprit artery for our STEMI patient following the 2017 ESC guidelines for STEMI<sup>18</sup>. It should be noted that patients with PV are at higher risk of stent thrombosis<sup>19</sup> and therefore, optimal MI and PV treatment adherence is mandatory.

## CONCLUSION

In conclusion, MI is relatively common in PV patients and is responsible for significant morbidity and mortality in these patients. Therefore, PV can be considered a cardiovascular risk factor, making early diagnosis crucial for early initiation of preventive treatment. In some cases, MI can reveal PV. Physicians should be highly suspicious of PV,

especially when young patients without atherosclerotic risk factors present with MI, because starting early treatment can alter patient outcomes.

**Ethical Approval:**

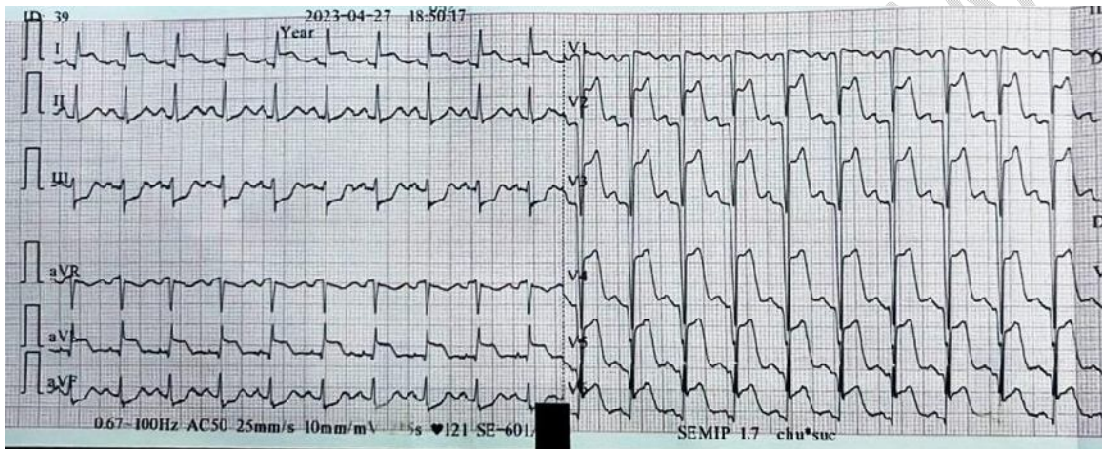
As per international standard or university standard written ethical approval has been collected and preserved by the author(s).

**Consent**

As per international standard or university standard, patient(s) written consent has been collected and preserved by the author(s).

UNDER PEER REVIEW

FIGURE 1 : 12 leads admission ECG showing antero-lateral STEMI



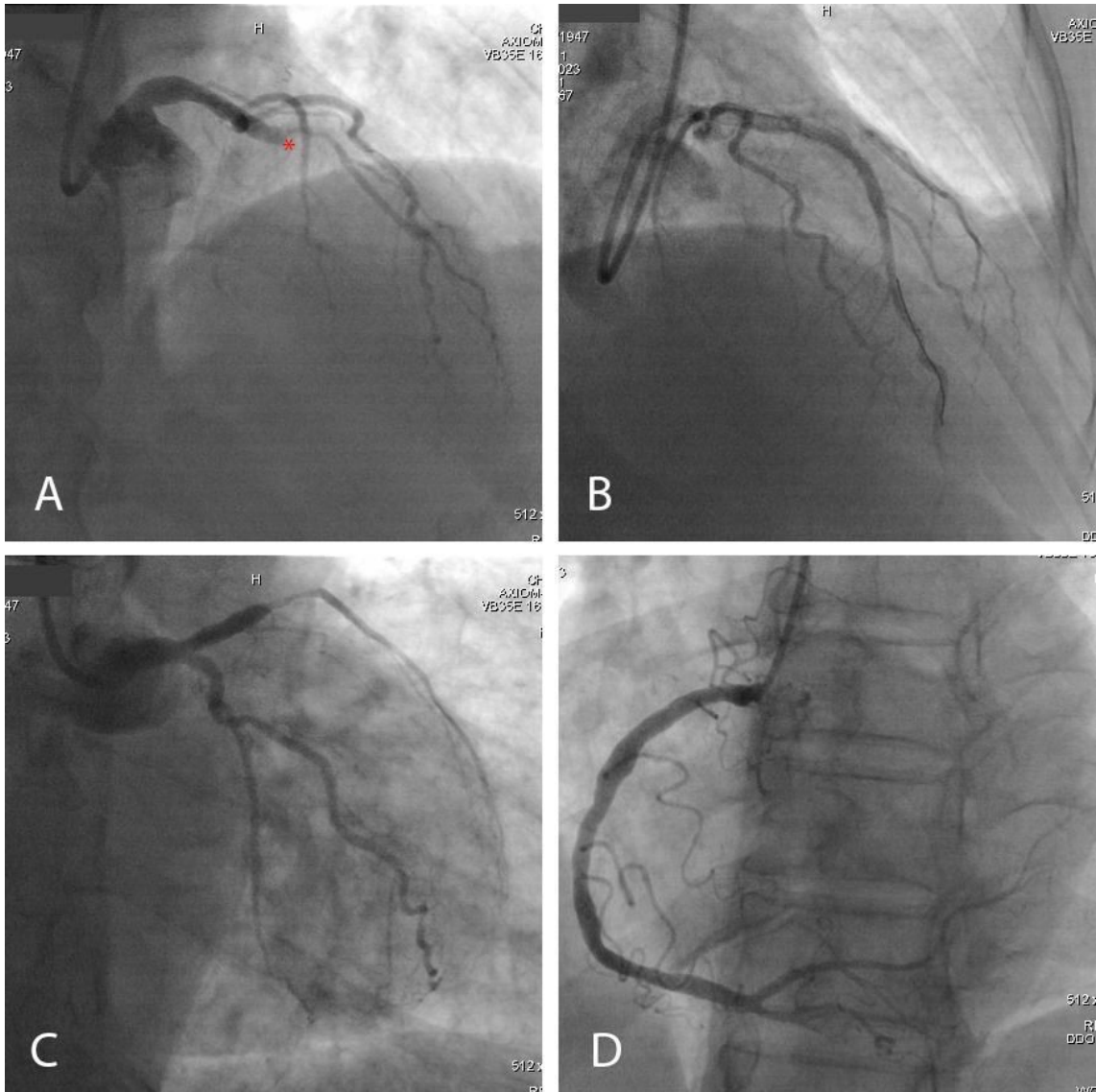


FIGURE 2 : coronary angiography and PCI of the LAD. Panel A : Acute thrombotic occlusion of the mid-LAD (\*), TIMI 0 flow ; Panel B : TIMI 3 flow after PCI of the mid LAD, Panel C and D : No significant stenosis in the right coronary and circumflex arteries.

## References

1. Bahbahani, H., Aljenaee, K. & Bella, A. Polycythemia vera presenting as acute myocardial infarction: An unusual presentation. *J. Saudi Heart Assoc.* **27**, 57–60 (2015).
2. Tefferi, A., Vannucchi, A. M. & Barbui, T. Polycythemia vera: historical oversights, diagnostic details, and therapeutic views. *Leukemia* **35**, 3339–3351 (2021).
3. Gulati, R. *et al.* Acute Myocardial Infarction in Young Individuals. *Mayo Clin. Proc.* **95**, 136–156 (2020).
4. Bădulescu, O. V., Ciocoiu, M., Bararu, I., Mocanu, M. & Bădescu, M. Polycythemia vera syndrome--as a prothrombotic state. *Rev. Med. Chir. Soc. Med. Nat. Iasi* **118**, 432–438 (2014).
5. WHO Classification of Tumours of Haematopoietic and Lymphoid Tissues – IARC. <https://www.iarc.who.int/news-events/who-classification-of-tumours-of-haematopoietic-and-lymphoid-tissues-2/>.
6. Durmus, A. *et al.* The thrombotic events in polycythemia vera patients may be related to increased oxidative stress. *Med. Princ. Pract. Int. J. Kuwait Univ. Health Sci. Cent.* **23**, 253–258 (2014).
7. Elliott, M. A. & Tefferi, A. Thrombosis and haemorrhage in polycythaemia vera and essential thrombocythaemia. *Br. J. Haematol.* **128**, 275–290 (2005).
8. Rossi, C., Randi, M. L., Zerbinati, P., Rinaldi, V. & Girolami, A. Acute coronary disease in essential thrombocythemia and polycythemia vera. *J. Intern. Med.* **244**, 49–53 (1998).
9. Lim, Y. *et al.* Prediction of thrombotic and hemorrhagic events during polycythemia vera or essential thrombocythemia based on leukocyte burden. *Thromb. Res.* **135**, 846–851 (2015).
10. Malak, S. *et al.* Long term follow up of 93 families with myeloproliferative neoplasms: life expectancy and implications of JAK2V617F in the occurrence of complications. *Blood Cells. Mol. Dis.* **49**, 170–176 (2012).
11. Hermanns, B., Handt, S., Kindler, J. & Füzesi, L. Coronary vasculopathy in polycythemia vera. *Pathol. Oncol. Res. POR* **4**, 37–39 (1998).
12. Wasserman, L. R. *et al.* Influence of therapy on causes of death in polycythemia vera. *Trans. Assoc. Am. Physicians* **94**, 30–38 (1981).
13. Landolfi, R. *et al.* Efficacy and safety of low-dose aspirin in polycythemia vera. *N. Engl. J. Med.* **350**, 114–124 (2004).
14. Barosi, G. *et al.* Clinical end points for drug treatment trials in BCR-ABL1-negative classic myeloproliferative neoplasms: consensus statements from European LeukemiaNET (ELN) and International Working Group-Myeloproliferative Neoplasms Research and Treatment (IWG-MRT). *Leukemia* **29**, 20–26 (2015).
15. Forsyth, C. J. *et al.* Recommendations for the use of pegylated interferon- $\alpha$  in the treatment of classical myeloproliferative neoplasms. *Intern. Med. J.* **49**, 948–954 (2019).
16. Passamonti, F. How I treat polycythemia vera. *Blood* **120**, 275–284 (2012).
17. Gerds, A. T. & Dao, K.-H. Polycythemia Vera Management and Challenges in the Community Health Setting. *Oncology* **92**, 179–189 (2017).
18. Ibanez, B. *et al.* 2017 ESC Guidelines for the management of acute myocardial infarction in patients presenting with ST-segment elevation: The Task Force for the management of acute

myocardial infarction in patients presenting with ST-segment elevation of the European Society of Cardiology (ESC). *Eur. Heart J.* **39**, 119–177 (2018).

19. Okabe, H. *et al.* Acute myocardial infarction following sequential multi-vessel occlusion in a case of polycythemia vera. *J. Cardiol. Cases* **20**, 111–114 (2019).

UNDER PEER REVIEW