

## Case study

### **A Rare case of Phytobezoar Impaction in a Giant Meckel's Diverticulum Causing Small bowel obstruction**

#### **Abstract**

Meckel's Diverticulum is the most common anomaly of the gastrointestinal tract, found in almost 2% of the population, it rarely gives rise to symptoms and its discover usually incidental. Meckel's Diverticulum size more than 5 cm are classified as Giant Meckel's Diverticulum, are relatively rare and may be prone to complications especially for obstruction in adults. Phytobezoar is concretion of poorly digested fruits and vegetable fibres that is found in the Giant Meckel's diverticulum can be the cause of small bowel intestinal obstruction.

Herein we report a rare case of 16 years' adolescent boy was having Giant Meckel's Diverticulum containing Phytobezoar causing intestinal obstruction. We did explorative laparotomy and resection of the involved segment along with Giant Meckel's Diverticulum with ileo-ileal anastomosis was done.

#### **Key words**

Giant Meckel's Diverticulum, Phytobezoar, Small bowel obstruction

#### **Introduction**

Meckel's Diverticulum is an embryological disorder resulting from an incomplete obliteration of vitelline duct during 5-7<sup>th</sup> week of gestation. The most common complication of Meckel's Diverticulum in adults is intestinal obstruction. It can result from several mechanism such as, volvulus of the intestine around the fibrous band attached to the umbilicus, intussusception due to inverted Meckel's Diverticulum, entrapment of intestine by Mesodiverticular band or secondary to chronic diverticulitis.

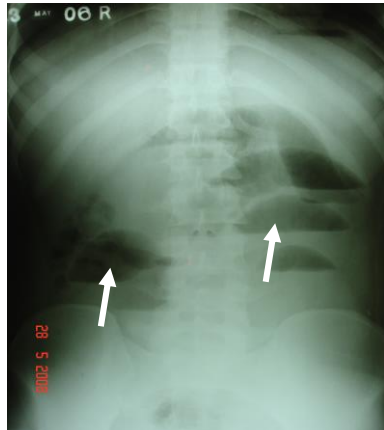
Phytobezoar is a vegetable ball defined as a concretion of poorly digested vegetables and fruit fibres that is impacted inside the Giant Meckel's Diverticulum. A Phytobezoar accounts for 4% causes of small bowel obstruction within the Giant Meckel's Diverticulum is extremely rare. The occurrence of small bowel obstruction due to a Phytobezoar within Meckel's Diverticulum is very uncommon and rarely reported. Only 7-10 cases have been reported in the literature. [1,2,3]

#### **Case Reports**

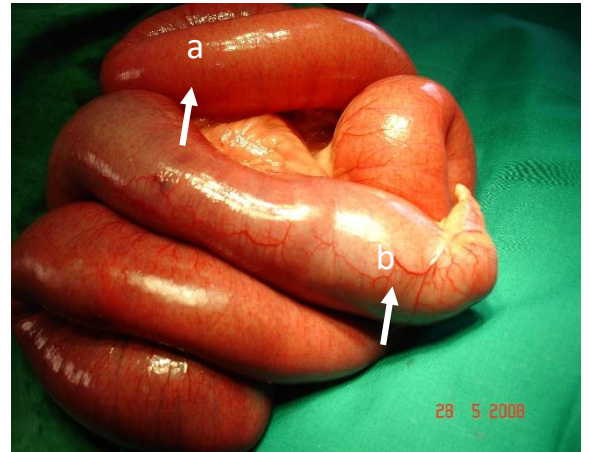
A 16 years' adolescent boy was admitted in our centre, on 28<sup>th</sup> may 2008 with complaints of pain in abdomen, distension of abdomen & constipation since last 3 days. On clinical examination abdomen was distended and bowel sounds were exaggerated. He was hemodynamically stable. X-ray KUB abdomen showed features of small bowel obstruction. Ultrasound abdomen showed distended bowel loops and minimal free in the abdomen. A diagnosis of small bowel obstruction was confirmed. The patient was taken for emergency laparotomy.

Intraoperatively dilated small bowel loops with a large Meckel's Diverticulum and the distal intestinal loops were collapsed. A Giant Meckel's Diverticulum of size 12x4 cm wide, and a hard mass was palpated at the region of Giant Meckel's Diverticulum causing obstruction of small bowel.

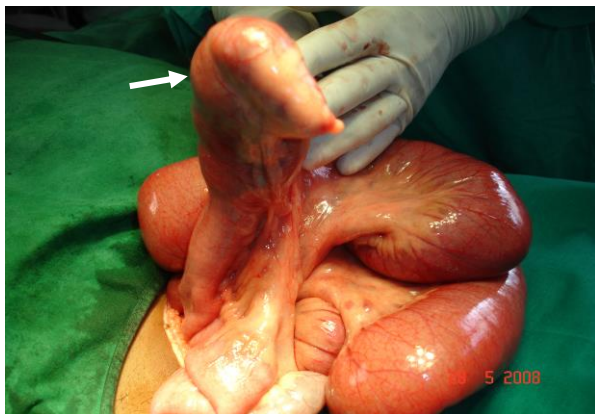
A resection and anastomosis was done and after cutting the layers of Giant Meckel's Diverticulum, we found a big concretion of Phytobezoar with undigested vegetable material seen. Large size and length of Giant Meckel's Diverticulum predisposed to concretion or a ball of vegetable Phytobezoar forms, a volvulus s around the axis of small bowel and followed by obstruction. Patient recovery was uneventful and discharge on 7<sup>th</sup> post-operative day. (Figure 1,2,3,4)



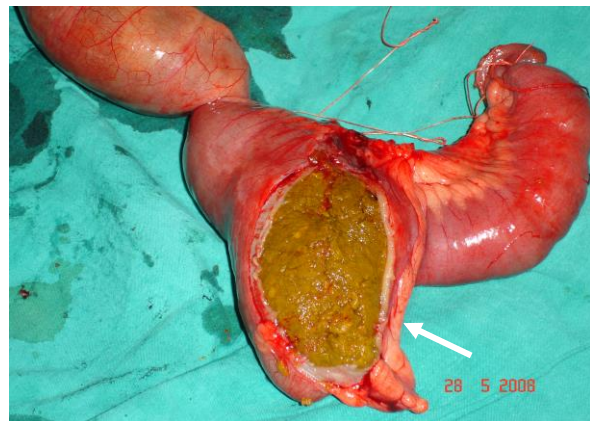
**Fig -1** Abdominal X-ray showing multiple air fluid levels



**Fig-2** Intra operative photographs  
a-Showing small bowel obstruction with b- Giant MD



**Fig-3** Intra operative photographs  
Showing Giant MD of size 12x4 cm



**Fig-4** Meckel's Diverticulum after cutting showing the Phytobezoar

## Discussion

The lifetime risk of complication in adult patients with Meckel's Diverticulum is usually 4-16%. Complication differs according to age of the patient. In paediatric age lower GI bleeding is more common and in adult patients, Intestinal obstruction is the most complication (40%). Bowel obstruction from Meckel's Diverticulum most commonly occur due to volvulus, intussusception, diverticulitis or incarceration of the Meckel's Diverticulum with in a littré's hernia. [2,3]

The term Bezoar comes from the Arabic "Badzehir" means counter poison or antidote. Excessive intake of fruits and vegetable fibres, can predispose to Phytobezoar formation. Bezoars have been reported between the age 1 and 56 years. Most common presentation age of 15-20 years and more common in 90% females due to psychiatric abnormalities or mental retardation. [4,5]

It is mandatory to arrange several radiological investigations. About 50-70 % of small bowel obstructions are diagnosed by abdominal radiography, showing dilated bowel loops and air-fluid levels. On ultrasonography examination bezoars appear as an intraluminal mass with a hyperechoic arc-like surface and marked posterior acoustic shadows. CT scan demonstrates dilated small bowel loops and well-defined round, intraluminal masses. CT scan is useful to localize the bezoars, perforation and obstruction. [1,2]

Phytobezoar impaction in a Meckel's Diverticulum is very rare and should be treated by open explorative laparotomy for surgical treatment of small bowel resection along with Meckel's Diverticulum containing Phytobezoar and ileo-ileal anastomosis. This patient was an operative surprise. [2]

### Conclusion

Phytobezoar impaction in a Meckel's Diverticulum. A rare cause of small obstruction in adults. Most of the cases reported in the literature were treated through explorative laparotomy. Laparoscopic approach could be a good option with better outcome for treatment of this condition.

### References

1. Bini R, Quiriconi F, Tello A, Fusca M, Loddo F, Leli R, Addeo A. Phytobezoar in Meckel's diverticulum: A rare cause of small bowel obstruction. *Int J Surg Case Rep.* 2012;3(5):161-3. doi: 10.1016/j.ijscr.2012.01.006. Epub 2012 Feb 3. PMID: 22382033; PMCID: PMC3316763.
2. Hussein BA, Khammas A, Al-Ozaibi L, Abdallah A, Busharar H, Al-Mazrouei A, Badri F. *Int J Surg* Phytobezoar impaction in a Meckel's diverticulum; a rare cause of bowel obstruction: Case report and review of literature. *Int J Surg Case Rep.* 2017;30:165-168. doi: 10.1016/j.ijscr.2016.10.070. Epub 2016 Nov 3. PMID: 2801233
3. Zello, A., Kirschner, D. Diagnosis of a rare pediatric case of small-bowel obstruction secondary to a phytobezoar in a Meckel's diverticulum aided by point-of-care ultrasound. *Can J Emerg Med* **25**, 244–247 (2023). <https://doi.org/10.1007/s43678-023-00463-9>
4. Bini, Roberto & Quiriconi, Fabrizio & Tello, Aurelio & Fusca, Marcella & Loddo, Franca & Leli, Renzo & Addeo, Alfredo. (2012). Phytobezoar in Meckel's diverticulum: A rare cause of small bowel obstruction. *International journal of surgery case reports.* 3. 161-3. 10.1016/j.ijscr.2012.01.006.
5. Ballapalli HP, Telsang MV, Arumalla A. Phytobezoar at the Meckel's diverticulum presenting as small bowel obstruction: A rare case. *J NTR Univ Health Sci [serial online]* 2013 [cited 2023 May 24];2:285-7. Available from: <https://www.jdntruhs.org/text.asp?2013/2/4/285/122173>
6. Xiang M, Mazer LM, Gupta A and Odom SR. Phytobezoar in a Meckel's Diverticulum Associated with Recent Adoption of a Paleolithic Diet. *Austin J Surg.* 2014;1(4): 1018.
7. 11. Plath F, Brock P, Hasse N, Liebe S, Arendt T. Vegetable stalk as a nidus for gallstone formation in a patient with a juxtapapillary duodenal diverticulum. *Gastrointest Endosc.* 2002; 56: 944-946. 12. Engin O, Yildirim M, Yakan S, Coskun GA. Can fruit seeds and undigested plant residuals cause acute appendicitis. *Asian Pac J Trop Biomed.* 2011; 1: 99-101. 13. Bingham JR, Causey MW, Haque MI. Phytobezoar within Meckel's diverticulum: an unusual cause of intestinal obstruction. *Am Surg.* 2014; 80: E94-96

8. Fagenholz PJ, de Moya MA. Laparoscopic treatment of bowel obstruction due to a bezoar in a Meckel's diverticulum. *JSLs*. 2011 Oct-Dec;15(4):562-4. doi: 10.4293/108680811X13176785204607. PMID: 22643518; PMCID: PMC3340972.