

## THE ANTI-OXIDANT EFFECTS OF VITAMINS ON LEAD-INDUCED REPRODUCTIVE TOXICITY IN MALE WISTAR RATS

### Abstract

#### Aim

The current study investigated the anti-oxidant effects of vitamins on lead-induced reproductive toxicity in male wistar rats.

#### Study Design

A total of 48 male Wistar rats divided into 6 groups of 8 rats per group were used in this study. Group 1 served as the positive control and was given normal animal feed and water ad libitum. Group 2 was the negative control and was administered 10mg/kg body weight of lead acetate (Pb) only, Group 3 was administered with 200mg/kg body weight of vitamin C only, Group 4 was given 1000IU/kg body weight of vitamin E only, Group 5 was given 10mg/kg body weight of lead and 200mg/kg body weight of vitamin C while Group 6 was given 10mg/kg body weight of lead and 1000IU/kg body weight of vitamin E. The administration of the test substances lasted for 4 weeks after which the animals were sacrificed. Blood samples were collected and assayed for reproductive hormones. Semen was also extracted from the testis for the assay of sperm parameters while the testis and epididymis were harvested for histological analyses.

#### Place and Duration of Study

The study was carried out in the Department of Human Physiology of University of Port Harcourt and it lasted for a period of 6 months

#### Results.

The results showed that lead significantly decreases the concentration of the reproductive hormones, decreases the sperm parameters and destroys the histological architecture of the testis and epididymis. The antioxidants were found to ameliorate the damages done by lead on the reproduction hormones, sperm parameters and the histology of the testis and epididymis.

#### Conclusion

It was therefore concluded that the anti-oxidants may be used as suitable substitutes to chelating agents in ameliorating lead-induced toxicity on the reproductive function of male wistar rats.

**Keywords: Antioxidants, Hepato-destructive, Liver, Toxicity, Testes and Vitamins.**

## **INTRODUCTION**

Lead is the most important environmental toxicant. Globally it is an abundantly distributed, important yet dangerous environmental chemical. Its important properties like softness, malleability, ductility, poor conductivity and resistance to corrosion seem to make it difficult to give up its use. Due to its non-biodegradable nature and continuous use, its concentration accumulates in the environment with increasing hazards.

Lead exposure has been reported to be responsible for several adverse effects on health such as developmental neurotoxicity, toxicity to the blood, kidneys and endocrine systems. <sup>[1]</sup> Lead has also been found in various other studies to cause deleterious effects on the entire reproductive function. For instance, lead was found to cause a decline in the activities of testicular key steroidogenic enzymes with a significant depletion in cholesterol, ascorbic acid and reduced glutathione contents in lead-treated animals. <sup>[2]</sup> It has also been established to cause an undesirable alteration in sperm motility and viability, acrosome reaction, chemotaxis, Semen quality and structural abnormality in rats. <sup>[3]</sup> Going forward, lead has further been found to cause a significant decrease in the testicular level of Glutathione peroxidase (GPx), Catalase (CAT), and Superoxide dismutase (SOD) and a corresponding elevation of the level of malondialdehyde (MDA) in both the plasma and tissue in lead treated animals. <sup>[1]</sup>

Antioxidants has been said to have regenerative and remediating effects on the tissues of the body and hence this study sets to investigate the extent to which the deterioration of the reproductive organs of wister rats exposed to lead can be ameliorated when administered with antioxidants like vitamins C and E.

Comment [A1]: Add space

## **MATERIALS AND METHODS**

This is an experimental study designed to evaluate the possibility or otherwise of anti-oxidants (Vitamins C and E) to ameliorate the damages caused by lead on the reproductive system. Forty-eight (48) male rats weighing between 137g-200g, acquired from the animal house of the Department of Human Physiology of the Faculty of Basic Medical Sciences, University of Port Harcourt were used for the study. The procured rats were housed in a cage of six compartments one for each group under standard laboratory conditions. Animals were treated in accordance with Institute for Laboratory and Animal Research, Guide for use of laboratory animals (1996). The rats were given access to pellet and tap water ad libitum and were acclimatized for two weeks then grouped for the study as shown in the table below:

Comment [A2]: Add space

Table 1 : Group wise distribution of Daily treatment

<b>GROUP</b>	<b>DESCRIPTION</b>	<b>DAILY TREATMENT FOR 28 DAYS</b>
1 (n=8)	Control	Distilled water + normal rat feed only
2 (n=8)	Lead group	10mg/kg body weight of lead only
3 (n=8)	Vitamin C group	200mg/kg body weight of vitamin C
4 (n=8)	Vitamin E group	1000IU/kg body weight of vitamin E
5 (n=8)	Lead + vitamin C group	10mg/kg body weight of lead + 200mg/kg body weight of vitamin C
6 (n=8)	Lead + Vitamin E group	10mg/kg body weight of lead acetate+ 1000IU/kg body weight of vitamin E

The administration of the antioxidants lasted for a period of four (4) weeks after which five (5) animals from each group were sacrificed under chloroform anaesthesia. After the sacrifice, blood samples were collected using a 5ml syringe through cardiac puncture and deposited in EDTA (ethylenediaminetetraacetic acid) bottles for hormonal analyses. Semen was also obtained from

Comment [A3]: Where is protocol for hormonal analysis

the testes for the analysis of sperm parameters while the testes and epididymis were harvested for histological analysis.

**Comment [A4]:** Complete methods for histological analysis are required

Obtained data were analysed using SPSS version 20.0. Analysed values were presented in tables. Mean comparison (Descriptive analysis) was done with One Way ANOVA at a confidence limit of 95%. Groups differences were considered significant at  $p < 0.05$ . Results were shown as mean  $\pm$  standard error of mean.

## RESULTS

**TABLE 2: Effects of anti-oxidants on reproductive hormones, following lead-induced toxicity**

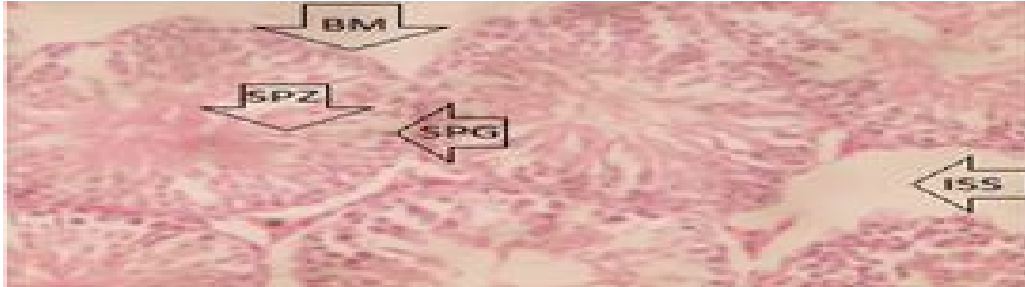
Groups	FSH (miu/ml)	LH (miu/ml)	TET (miu/ml)
Control	0.26 $\pm$ 0.08	0.73 $\pm$ 0.27	1.51 $\pm$ 0.19
Lead	0.21 $\pm$ 0.04 <sup>a</sup>	0.67 $\pm$ 0.23 <sup>a</sup>	1.34 $\pm$ 0.02 <sup>a</sup>
Vitamin C	0.45 $\pm$ 0.10 <sup>a</sup>	1.53 $\pm$ 0.39 <sup>a</sup>	1.49 $\pm$ 0.06
Vitamin E	0.41 $\pm$ 0.09 <sup>a</sup>	0.90 $\pm$ 0.20 <sup>a</sup>	1.47 $\pm$ 0.04
Lead + Vitamin C	0.40 $\pm$ 0.03 <sup>b</sup>	1.36 $\pm$ 1.10 <sup>b</sup>	1.35 $\pm$ 0.03
Lead + Vitamin E	0.38 $\pm$ 0.09 <sup>b</sup>	0.68 $\pm$ 0.64	1.32 $\pm$ 0.02

Data are expressed as Mean  $\pm$  SEM of 5 rats, a,b are mean significant differences relative to the control and lead groups respectively, at  $p < 0.05$ .

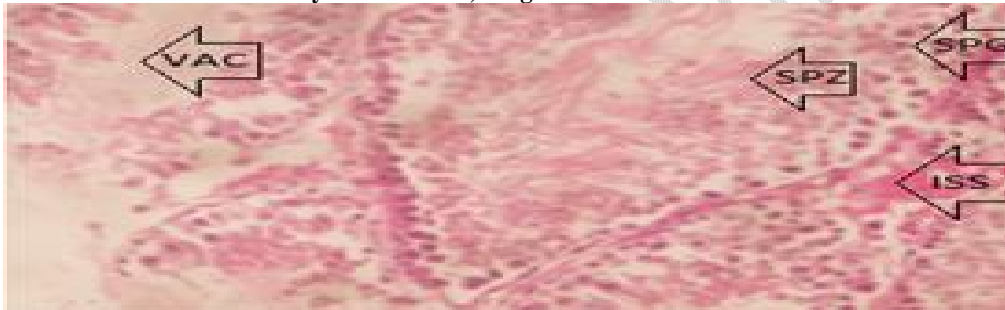**Table 3: Effects of anti-oxidants on sperm parameters, following lead-induced toxicity**

<b>Groups</b>	<b>Viability (%)</b>	<b>Normal Morphology (%)</b>	<b>Active sperm (%)</b>	<b>Count (Million/ml)</b>
<b>Control</b>	<b>70.0±2.17</b>	<b>71.0±2.45</b>	<b>66.0±2.00</b>	<b>530.0±26.95</b>
<b>Lead</b>	<b>62.0±2.10<sup>a</sup></b>	<b>59.0±1.32<sup>a</sup></b>	<b>54.0±1.80<sup>a</sup></b>	<b>230.0±13.59<sup>a</sup></b>
<b>Vitamin C</b>	<b>75.0±2.41</b>	<b>75.0±2.90</b>	<b>74.0±3.05<sup>a</sup></b>	<b>520.0±23.49</b>
<b>Vitamin E</b>	<b>79.0±3.48<sup>a</sup></b>	<b>77.0±3.25</b>	<b>66.0±2.02</b>	<b>580.0±35.09<sup>a</sup></b>
<b>Lead + Vitamin C</b>	<b>72.0±2.40<sup>b</sup></b>	<b>68.0±2.03<sup>b</sup></b>	<b>62.0±2.00<sup>b</sup></b>	<b>380.0±15.02<sup>b</sup></b>
<b>Lead + Vitamin E</b>	<b>80.0±3.58<sup>b</sup></b>	<b>61.0±2.10</b>	<b>58.0±2.10</b>	<b>320.0±14.76<sup>b</sup></b>

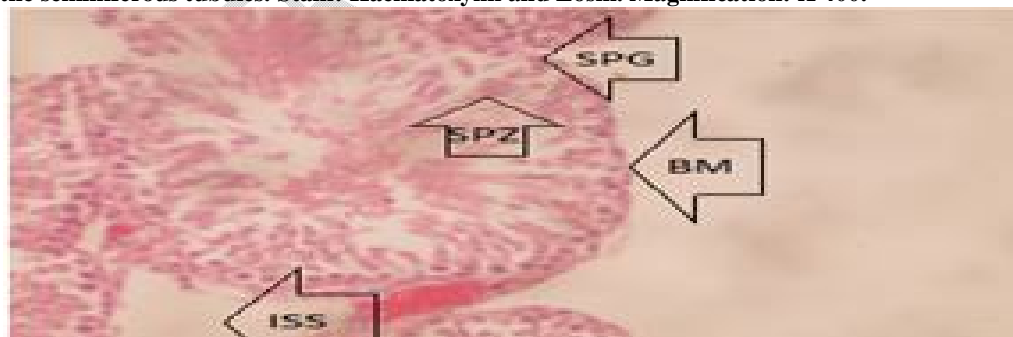Data are expressed as Mean ± SEM of 5 rats, <sup>a, b</sup> are Mean significant difference relative to control and Lead groups respectively at p<0.05



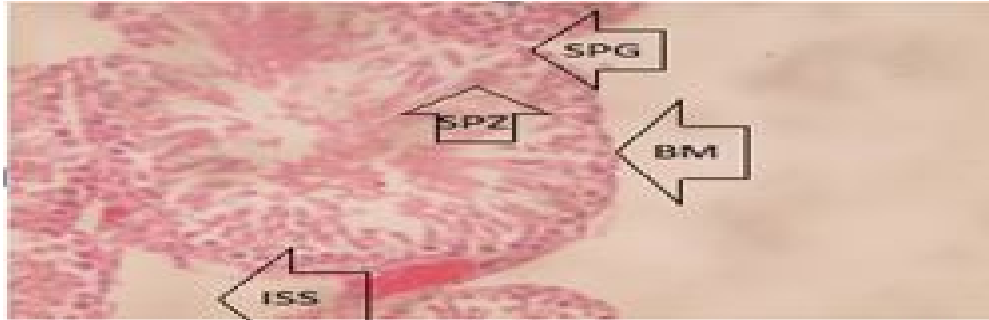
**Plate 1:** Photomicrograph of a section of the Testes of rat (control group) after 30 days period. It reveals a histologically normal testis, with seminiferous tubules containing spermatogenic cells (spermatogonia, spermatocytes or spermatids) and Sertoli cells. It also reveals interstitial spaces containing interstitial cells of Leydig and intact basement membrane. Stain: Haematoxylin and Eosin; Magnification: X 400.



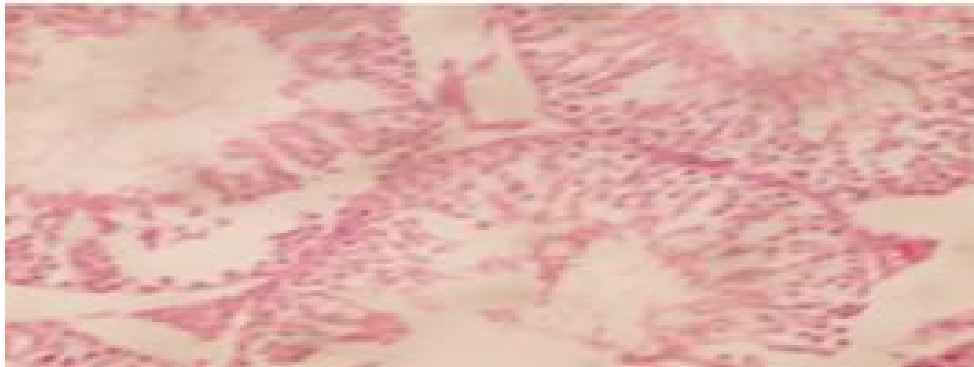**Plate 2:** Photomicrograph of a section of the Testes of rat (Lead group) after 30 days period. It reveals a histologically distorted testis, showing vacuole (VAC) in the centre of the seminiferous tubules. Stain: Haematoxylin and Eosin. Magnification: X 400.



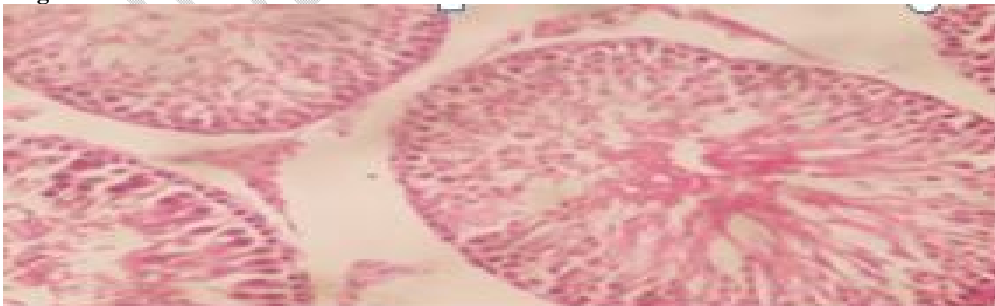
**Plate 3:** Photomicrograph of a section of the Testes of rat (Lead + Vitamin C group) after 30 days period. It reveals a histologically normal testis, with seminiferous tubules containing spermatogenic cells (spermatogonia, spermatocytes or spermatids) and Sertoli cells. It also reveals interstitial spaces containing interstitial cells of Leydig and intact basement membrane. Stain: Haematoxylin and Eosin. Magnification: X 400.



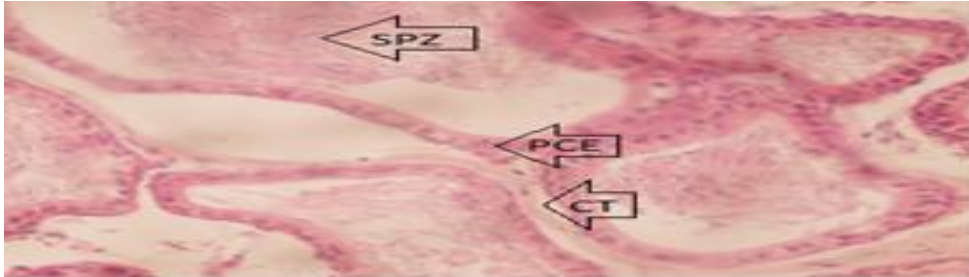
**Plate 4:** Photomicrograph of a section of the Testes of rat (Lead + Vitamin E group) after 30 days period. It reveals a histologically normal testis, showing seminiferous tubules containing spermatogenic cells (spermatogonia, spermatocytes or spermatids) and Sertoli cells. It also reveals interstitial spaces containing interstitial cells of Leydig intact basement membrane. Stain: Haematoxylin and Eosin. Magnification: X 400.



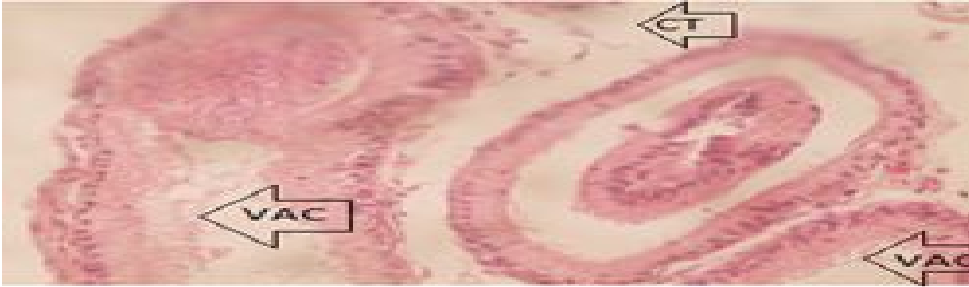**Plate 5:** Photomicrograph of a section of the Testes of rat (Vitamin C group) after 30 days period. It reveals a histologically normal testis. Stain: Haematoxylin and Eosin. Magnification: X 400.



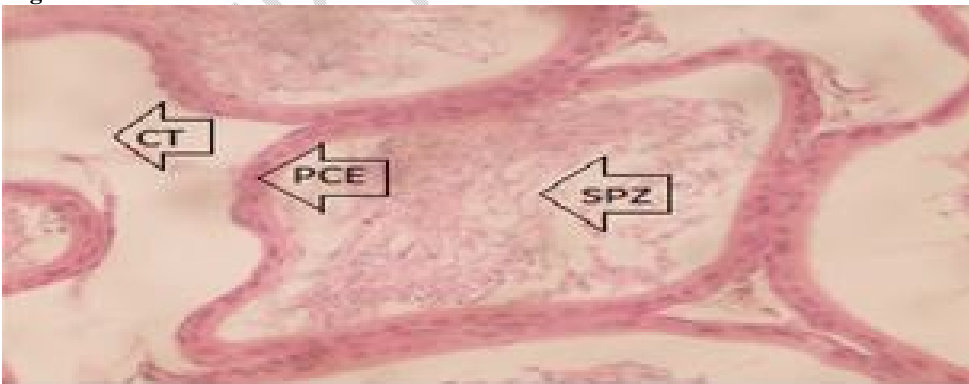
**Plate 6:** Photomicrograph of a section of the Testes of rat (Vitamin E group) after 30 days period. It reveals a histologically normal testis. Stain: haematoxylin and eosin; Magnification: x 400.



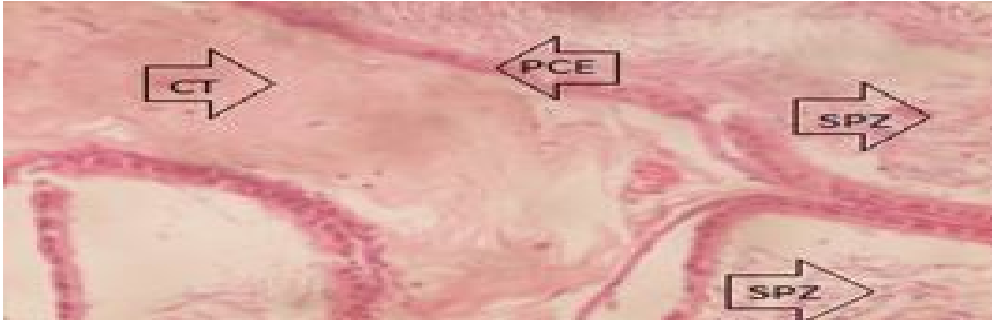**Plate 7:** Photomicrograph of a section of the Epididymis of rat (Control group) after 30 days period. It reveals a histologically normal epididymis, showing spermatozoa (sp), and pseudo stratified columnar epithelium. It also shows smooth muscles and connective tissues. Stain: haematoxylin and eosin; Magnification: x 400.



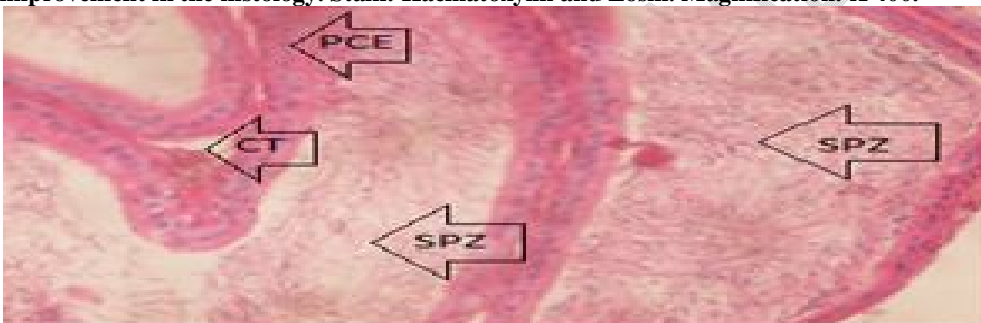
**Plate 8:** Photomicrograph of a section of the Epididymis of rat (Lead group) after 30 days period. It reveals a histologically distorted epididymis, showing scanty spermatozoa in the lumen and vacuoles replacing matured spermatozoa. Stain: Haematoxylin and Eosin. Magnification: X 400.



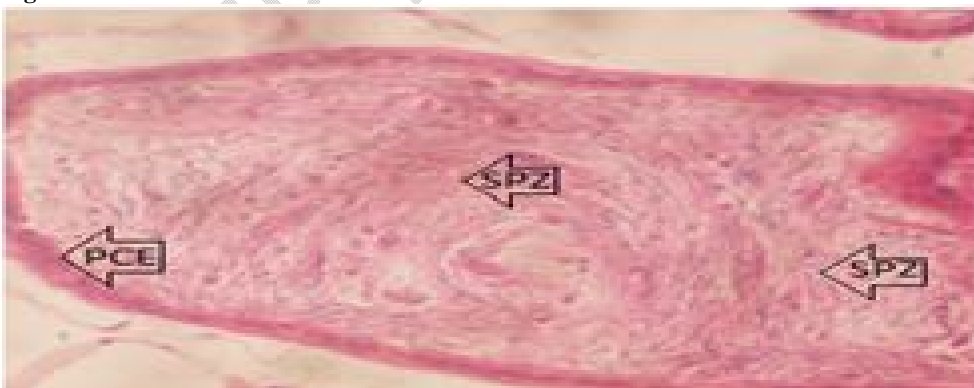**Plate 9:** Photomicrograph of a section of the Epididymis of rat (Lead +Vitamin C group) after 30 days period. It reveals a histologically normal epididymis, showing presence of pseudo-stratified columnar epithelium (PCE). Also, the seminiferous tubules containing matured spermatozoa (SPZ). Stain: Haematoxylin and Eosin. Magnification: X 400.



**Plate 10:** Photomicrograph of a section of the Epididymis of rat (Lead +Vitamin E group) after 30 days period. It reveals a histologically normal epididymis, showing a remarkable improvement in the histology. Stain: Haematoxylin and Eosin. Magnification: X 400.



**Plate 11:** Photomicrograph of a section of the Epididymis of rat (Vitamin C group) after 30 days period. It reveals a histologically normal epididymis. Stain: Haematoxylin and Eosin. Magnification: X 400.



**Plate 12:** Photomicrograph of a section of the Epididymis of rat (Vitamin E group) after 30 days period. It reveals a histologically normal epididymis. Stain: Haematoxylin and Eosin. Magnification: X 400.

## **DISCUSSION**

### **EFFECT OF VITAMINS C AND E ON THE CONCENTRATION OF REPRODUCTIVE HORMONES, FOLLOWING LEAD-INDUCED TOXICITY**

The results showing the effect of 30 days of administration of Lead on reproductive hormones with respect to the control shows a statistically significant decrease in the concentrations of FSH and Testosterone, with respect to the control. Also, the results showing the effect of 30 days of administration of Vitamins C and E on reproductive hormones with respect to the control reveals that both groups show a statistically significant increase in the concentrations of FSH and LH while there was a non-statistically significant increase in the concentration of Testosterone, with respect to the control. Finally, the results showing the effect of 30 days of administration of Vitamins C and E on the concentration of reproductive hormones following lead-induced toxicity reveals that in Vitamin C group, there was a statistically significant increase in the concentrations of FSH and LH while there was a non-significant increase in the concentration of TET with respect to the lead group (lead toxicity). The Vitamin E group on the other hand shows a statistically significant increase in the concentration of FSH and a non-statistically significant increase in the concentration of LH and a non-statistically significant decrease in the concentration of TET, with respect to the lead group. This means that to a very large extent, the vitamins have the capability of ameliorating the damage caused by lead on the reproductive hormones.

Lead (Pb) is a well-known reproductive system toxicant. <sup>[5]</sup> A study aimed at elucidating the mechanism of lead toxicity on reproductive hormone in rats showed a decrease in plasma Luteinizing hormone (LH) and follicle stimulating hormone (FSH) concentrations. <sup>[6]</sup> However, in another study on the effect of lead on the concentration of reproductive hormones in rats, the

level of testosterone in serum was reduced without any significant change in LH levels.<sup>[7]</sup> This result was supported by another study which reveals that there was no significant change in serum LH values in lead treatment animals.<sup>[8]</sup> In a further research by another group of researchers in lead-exposed rats, the plasma and testicular testosterone dropped by about 80%, but plasma LH dropped only by 32%. When luteinizing hormone releasing hormone (LHRH) stimulated the pituitary, the plasma LH level reached to normal range, but plasma testosterone remained significantly reduced by 37%.<sup>[9]</sup> This sharp decrease in the testosterone (TET): LH ratio in lead-exposed rats, combined with the significant reduction of intertubular tissue volume in the testes, were indications of the impairment of Leydig cell function.<sup>[9]</sup>

The pathological changes in Leydig cells brought the observed decline in the androgen level<sup>[10]</sup> and it has been reported to alter the metabolic function of Sertoli cells.<sup>[11]</sup>

The gonadotropin releasing hormone (GnRH) secreted by the hypothalamus regulates the release and secretion of gonadotropins (luteinizing hormone and follicle-stimulating hormone) from anterior pituitary, which in turn regulate testicular functions.

These gonadal steroids as well as the pituitary gonadotropins, via feedback regulatory mechanisms, further establish physiological homeostasis and maintain normal reproductive functions. The receptors of FSH are located on the membrane of Sertoli cells, while those of LH are on the Leydig cells. The luteinizing hormone coordinates the synthesis of testosterone, maintenance of normal spermatogenesis, sperm health and density. The level of androgens level of androgens in serum therefore serves as an important indicator for reproductive hormone.

Vitamin C (L-ascorbic acid) is an essential nutrient for humans and other mammalian species made internally by almost all organisms.<sup>[12]</sup> It is an antioxidant, which decreases oxygen, nitrogen, and sulfur centered radicals and might therefore protect the body from some oxidative

stresses.<sup>[13]</sup> It has been found to be a cofactor in several vital enzymatic reactions.<sup>[14]</sup> The main source of vitamin C is fruits and vegetables, therefore the plasma vitamin C concentration is a marker of fruits and vegetables intake.

The ability of Vitamin C to ameliorate the damage caused by lead on male reproduction observed from the study may therefore be attributable to its antioxidant property. The administration of 500 mg/day of vitamin C for one month in battery manufacturing workers has shown to reduce malondialdehyde concentration and nitrite levels, improving antioxidant status including erythrocyte osmotic fragility and activities of endogenous antioxidant enzymes by scavenging the ROS generated due to high blood lead levels.<sup>[15]</sup> Vitamin E in this study was found to have a limited ability to reverse the damage caused by lead on the reproductive hormones. Studies have demonstrated that vitamin E may help to reduce lead-induced hepatotoxicity of lead exposed rats and ameliorate the oxidative stress status in the brain of rats.<sup>[16]</sup> Vitamin E scavenges ROS by readily donating electrons to ROS in the body during oxidative reactions, and become oxidized in the process. The scavenging of ROS consequently causes the reduction of lipid peroxidation and oxidative stress that may cause tissue injury. Vitamin E has therefore been found to be effective in the treatment of lead-induced toxicity, while a combination of vitamins E and C has been found to produce synergistic and additive effects.<sup>[16]</sup>

#### **EFFECT OF VITAMINS C AND E ON SPERM PARAMETERS, FOLLOWING LEAD-INDUCED TOXICITY**

The results showing the effects of 30 days of administration of Lead on sperm parameters with respect to the control shows a statistically significant decrease in the percentage viability, percentage of sperm cells with normal morphology, percentage of active sperm cells and sperm count. Also, the results showing the effect of 30 days of administration of Vitamins C and E on

sperm parameters with respect to the control reveal that the Vitamin C group shows a statistically significant increase in the percentage of active sperm cells and a statistically insignificant increase in sperm viability and percentage normal morphology while the Vitamin E group on the other hand shows a statistically significant increase in the percentage of viable sperm cells and sperm count with respect to the control. Finally, the results showing the effect of 30 days of administration of Vitamins C and E on the sperm parameters following lead-induced toxicity reveals that Vitamin C show a statistically significant increase in the percentage of active sperm cells and an insignificant increase in the percentage of viable sperm cells and percentage of sperms cells with respect to the lead group (lead toxicity). Both vitamins were also able to cause a statistically significant increase in the percentage viability and sperm count. Finally, while vitamin C was able to significantly increase in the sperm parameters under consideration, vitamin E only showed a significant increase in sperm viability and count. This could mean that to a very large extent, the Vitamins have the capability of repairing the damage caused by lead on sperm parameters, with vitamin C exerting a greater capacity.

Studies have establish that lead toxicity causes a reduction in semen volume and density, sperm count (oligozoospermia), motility (asthenozoospermia), and deterioration in sperm chromatin structure as well as increased morphological abnormalities of spermatozoa in both humans<sup>[17]</sup> and experimental animals.<sup>[18]</sup> Even though elevated lead levels have been reported to be spermatotoxic in both animals and man<sup>[19]</sup>, prior attempts to correlate lead levels in seminal plasma with human male sub fertility produced equivocal results.<sup>[20]</sup> For instance, in the study conducted by administration of lead acetate in rats, resulted in an obvious decline in sperm density, significantly reducing sperm counts, sperm motility, and increasing the amount of anomalous spermatozoa.<sup>[21]</sup> Again, similar attempts in occupationally exposed cohorts have also

been inconclusive.<sup>[20]</sup> In fact, some investigators are not convinced that human lead exposure does affect semen parameters.<sup>[22]</sup> However, a recent study contains compelling evidence that even moderate exposure to lead has a negative impact on human semen quality.<sup>[23]</sup> This study is supported by a preliminary data, which suggest that a significant fraction of male partners from couples with 'unexplained' infertility exhibit high levels of lead in seminal plasma and may in fact represent cases of 'environmental' infertility.<sup>[20]</sup> Other studies indicate that workers exposed to lead had lower sperm count and higher teratozoospermia count.<sup>[24]</sup> A negative correlation between blood lead concentrations and poor semen quality has been shown.<sup>[25]</sup> A work done by on the effect of lead toxicity on male albino rats reproduction with amelioration by vitamin E and pumpkin seeds oil showed significant decrease in number of live sperm and increase in number of dead sperm in the lead acetate group compared with control group.

One mechanism by which lead causes the destruction of the sperm parameters is via the increase in oxidative stress. This is because oxidative stress (OS) has been found to be associated with sperm function impairment and plays a major role in the etiology of defective sperm function.<sup>[26]</sup> Lead's direct toxicity on testicular histology or its action on the hypothalamic-pituitary axis or a combined defect involving the gonad and hypothalamic-pituitary sites could inhibit spermatogenesis.<sup>[9]</sup>

The work done by on the effect of vitamin C and/or vitamin E treatment on Lead intoxicated animals showed a significant increase in reproductive hormones and an ameliorative effect on the semen quality assessed.<sup>[27]</sup> Vitamin C treatment showed a higher ameliorative effect on testosterone, follicle stimulating hormone levels, and sperm motility and morphology when compared to vitamin E treatment. Vitamin C has also been reported to protect the cells and sperm from oxidative stress and loss of motility, respectively. Vitamin C has also been found to

inhibit lipid peroxidation, regenerate spent Vitamin E and protect against hydrogen peroxide induced DNA damage. [28] Treatment of lead exposed animals with vitamin C and/or vitamin E showed an increase in luminal spermatozoa and seminiferous epithelium, with Vitamin C treatment potentiating better effects

Vitamin E has been considered as an anti-sterility vitamin and it is associated with normal function of the male reproductive system. [29] Vitamin E supplementation has been found to have the capacity of attenuating the adverse effects of stress on testicular physiology and endocrinology. [30] Vitamin E ameliorates oxidative stress in spermatozoa helping to maintain optimum fertilizing ability. [31] It enhances spermatogenesis (total sperm count, quality, concentration), sperm membrane fluidity and lowers the incidence of abnormal sperm production by inhibition of lipid peroxidation. [31] It also protects the spermatozoa from oxidative damage, as well as loss of motility, and increase sperm function. [32]

The observable difference in the ameliorative effect of Vitamin C and Vitamin E on the lead-exposed animals found in the study could be related to the ability of vitamin C to chelate lead, thereby reducing leads capacity to substitute zinc in zinc mediated processes, recycling vitamin E and also directly participating in antioxidant activity by helping to replenish glutathione.

#### **EFFECT OF VITAMINS C AND E ON THE HISTOLOGY OF THE TESTES AND EPIDIDYMIS FOLLOWING LEAD-INDUCED TOXICITY**

The results showing the effect of vitamins C and E on the histology of the testis and epididymis of the rats following 30 days of administration of Lead reveals a histologically normal testis and epididymis in the vitamins C and E groups with respect to the control, a histologically distorted testis and epididymis in the lead treated group with respect to the control and a histologically normal testis and epididymis in the groups treated with both lead and vitamins, with respect to

the lead group. This shows that the anti-oxidants have the capability of preserving the histological architecture of the testis and epididymis, when they are exposed to lead toxicity.

In a study carried out on the effect of lead on the testis of rat, it was found that the testicular weight and seminiferous tubular diameter significantly decreased following 3 days of lead chloride treatment. Also, following 60 days of exposure to 0.1% lead in drinking water, the histopathological results revealed a degeneration of germinal epithelium of the testis, with sloughing of germ cells into the lumen of seminiferous tubules.<sup>[33]</sup> It has also been reported that lead effects are manifested in the reduction of the thickness of epithelium and of seminiferous tubule diameter (STD) as a consequence of the reduction in numbers of prospermatogonia and spermatocytes.<sup>[34]</sup> Many previous studies have also shown that reduction of germinal epithelium seems to be due to damage of germinal cells.<sup>[35]</sup> A work done to establish the possibility or otherwise of vitamin E to repair the testicular damage done by lead, it was found that the testes in lead + vitamin E group showed a normal histological structure of seminiferous tubules with complete spermatogenic series compared with the lead group.<sup>[36]</sup> This result agreed with that obtained by other researchers.<sup>[37]</sup>

The work done on the histopathological examination of the epididymis of the rats exposed to lead toxicity revealed that the lead group showed focal degeneration with loss of spermatogenic series in the same seminiferous tubules.<sup>[38]</sup> These results agreed with that of other researchers.<sup>[39]</sup> The ability of the vitamins to preserve the histological architecture of the testis and epididymis may be due to their actions as antioxidant agents.<sup>[40]</sup>

## **CONCLUSIONS**

The present study provides scientific evidence that lead impairs male fertility by significantly reducing the concentration of gonadotropic hormones as well as adversely affecting the sperm

parameters and histology of the testis and epididymis. The overall resultant effect is a reduction in the fertility of male Wistar rats. However, vitamins C and E were found to have a great capability of reversing the damage caused by lead on the reproductive hormones, sperm parameters, histology of the testes and epididymis, with vitamin C exerting a greater capacity. The antioxidants may therefore be used as suitable substitutes to chelating agents in the amelioration of lead-induced toxicity on the reproductive function of male wistar rats.

#### **COMPETING INTERESTS DISCLAIMER:**

**Authors have declared that no competing interests exist. The products used for this research are commonly and predominantly use products in our area of research and country. There is absolutely no conflict of interest between the authors and producers of the products because we do not intend to use these products as an avenue for any litigation but for the advancement of knowledge. Also, the research was not funded by the producing company rather it was funded by personal efforts of the authors.**

#### **REFERENCES**

1. Sanborn MD, Abelsohn A, Campbell M, Weir E. Identifying and managing adverse environmental health effects: Lead exposure. *Can. Med. Assoc. J.* 2002;166: 1287–1292.
2. Pillai P, Pandya C, Bhatt N, Gupta SS. Biochemical and reproductive effects of gestational/lactational exposure to lead and cadmium with respect to testicular steroidogenesis, antioxidant system, endogenous sex steroid and cauda-epididymal functions. *Andrologia.* 2010, 44: 92–101.
3. Gautam AK, Agarwal K, Shah BA, Kumar S, Saiyed HN (2001). Lead induced spermatotoxicity in mouse and MPG treatment. *J. Environ. Biol.* 2001, 22: 287–291.
4. Dorostghoal M, Seyyednejad SM, Jabari A. Protective effects of *Fumaria parviflora* L. on lead-induced testicular toxicity in male rats. *Andrologia.* 2013;46: 437–446.
5. Landrigan PJ, Boffetta P, Apostoli. The reproductive toxicity and Carcinogenicity of lead: A critical review. *American Journal of Industrial Medicine.* 2000, 38; 231–43.
6. Batra N, Nehru B, Bansal MP. Influence of lead and zinc on rat malereproduction at biochemical and histopathological levels. *Journal of Applied Toxicology.* 2001, 21:507–512.
7. Riaz F, Khan UA, Ayub M, Shaukat S. Protective role of ginger on lead induced derangement in plasma testosterone and luteinizing hormone levels of male Sprague Dawley rats. *J. Ayub Med. Coll. Abbottabad.* 2011, 23; 24–7.
8. Sokol RZ, Madding CE, Swerdloff RS. Lead Toxicity and the Hypothalamic- Pituitary- Testicular Axis. *Biol. Reprod.* 1985.33:722–728.

9. Thoreux-Manlay A, de la Calle JFV, Olivier MF, Soufir JC, Masse R, Pinon-Lataillade G. Impairment of testicular endocrine function after lead intoxication in the adult rat. *Toxicology*. 1995;26:101–109.
10. Godowicz B, Galas J. Toxic effect of lead on fertility of inbred strain mice. *Folia Biol. (Praha)*. 1992, 40: 73–78.
11. Nathan E. Lead Acetate Does Not Impair Secretion of Sertoli Cell Function Marker Proteins in the Adult Sprague Dawley Rat. *Arch. Environ. Heal. An Int. J.* 1992, 47: 370–375.
12. Eteng MU, Ibeekwe HA, Amatey TE, Bassey BJ, Uboh FU. Effect of Vitamin on serum lipids and electrolyte profile of albino wistar rats. *Nigerian Journal of Physiological Sciences*. 2006, 21 (1-2); 15-9.
13. Niki E. Action of ascorbic acid as a scavenger of active and stable oxygen radicals. *Am J Clin Nutr*. 1991, 54: 1119-1124.
14. Padayatty S, Katz A, Wang Y, Eck P, Kwon O. Vitamin C as an antioxidant: Evaluation of its role in disease prevention. *J. Am. Coll. Nutr.* 2003, 22(1): 18-35.
15. Ganesh HG, Arun JP, Jyotsna AP, Mandakini SK, Ajit S. Biochemical effects of lead exposure on oxidative stress and antioxidant status of battery manufacturing workers of Western Maharashtra, India. *J Basic Clin Physiol Pharmacol*. 2016, 27: 141-146.
16. Ebuehi OA, Ogedegbe RA, Ebuehi OM. Oral administration of vitamin C and vitamin E Ameliorates lead induced hepatotoxicity and oxidative stress in the rat brain. *Nig Q J Hosp Med*. 2012, 22: 85-90.
17. Mahmoud A, Kiss P, Vanhoorne M, De Bacquer D, Comhaire F. Is Inhibin B Involved in the toxic effect of lead on male reproduction? *International Journal of Andrology*. 2005, 28:150–5.
18. Rubio J, Riqueros MI, Gasco M, Yucra S, Miranda S, Gonzales GF. Lepidium meyenii (Maca) reversed the lead acetate induced-damage on reproductive function in male rats. *Food and Chemical Toxicology*. 2006, 44: 1114–22.
19. Winder C. Reproductive and chromosomal effects of occupational exposure to lead in the male. *Reprod. Toxicol.* 1989, 3: 221-233.
20. Benoff S, Jacob A, Hurley IR. Environmental metals and male infertility. *Hum. Reprod.* 2000b, 6: 107-121.
21. Jensen TK, Bonde JP, Joffe M. The influence of occupational exposure on male Reproductive function. *Occup Med*. 2006, 56(8):544–553.
22. Hovatta O, Venalainen ER., Kuusimaki L, Heikkila J, Hirvi T, Reima I. (1998): Aluminum, lead and cadmium concentrations on seminal plasma and spermatozoa, and semen quality in Finnish men. *Hum. Reprod.* 1998, 13: 115-119.
23. Telisman S, Cvitkovic P, Juraasovic J, Pizent A, Gavella M, Rocic B. Semen quality and reproductive endocrine function in relation to biomarkers of lead, cadmium, zinc and copper in men. *Environ. Health Perspect.* 2000, 108: 45-53.
24. Robins TG, Bornman MS, Ehrlich RI, Cantrell AC, Pienaar E, Vallabh J, et al. Semen quality and fertility of men employed in a South African lead acid battery plant. *Am J Ind Med.* 1997, 32: 369–376.
25. Winder C. Lead, reproduction and development. *Neurotoxicology*. 1993, 14; 303-318.
26. El-Tohamy MM, El-Nattat WS. Effect of Antioxidant on Lead-Induced Oxidative Damage and Reproductive Dysfunction in Male Rabbits. *J Am Sci*. 2010, 6(11):613–622.

27. Ayinde O, Ogunnowo C, Ogedegbe RA. Influence of Vitamin C and Vitamin E on testicular zinc content and testicular toxicity in lead exposed albino rats. *BMC Pharmacol. Toxicol.* 2012,13; 17.
28. Adeniyi TT, Ajayi GO, Akinloye OA. Effect of Ascorbic acid and Allium sativum on Tissue lead level in female Rattus navigicus. *Niger J Health Biomed Sci.*2008, 7(2); 38–41.
29. Ashraf Abd EL-Hakem. Histological and Morphometric Study on the possible protective effect of Vitamin E on the Cadmium Intoxication of Adult Male Albino Rat Testis. *Med. J. Cairo Univ.*2014, 82 (2):321-330.
30. Saeed Al-Zahrani, Mohamed Mohany, Saleh Kandeal, Gamal Badr. Thymoquinone and Vitamin E supplementation improve the reproductive characteristics of heat stressed male mice. *Journal of Medicinal Plants Research.* 2012, 6(3):493-499
31. Amrit Kaur Bansal, Gurmail Singh Bilaspuri. Antioxidant effect of vitamin E on motility viability and lipid peroxidation of cattle spermatozoa under oxidative stress. *Animal Science Papers and Report.*2009, 27(1):5-14.
32. Motahareh Mortazavi, Iraj Salehi, Zohreh Alizadeh, Mehrangiz Vahabian, Amaneh Mohammadi Roushandeh. Protective Effects of Antioxidants on Sperm Parameters and Seminiferous Tubules Epithelium in High Fat-fed Rats. *J Reprod Infertil.* 2014, 15(1); 22-28.
33. Yasser Said El-Sayeda, Mahmoud Shaban El-Neweshy. Impact of lead toxicity on male rat reproduction at hormonal and histopathological levels. *Toxicological & Environmental Chemistry.* 2010, 92:765–774.
34. Corpas I, Castillo M, Marquina D, Benito MJ. Lead Intoxication in Gestational and Lactation Periods Alters the Development of Male Reproductive Organs. *Ecotoxicology and Environmental Safety.* 2001, 53:259-266.
35. Shan G, Tang T, Zhang X. The Protective Effect of Ascorbic Acid and Thiamine Supplementation against Damage Caused by Lead in the Testes of Mice. *J Huazhong Univ Sci Technol Med Sci.* 2009; 29:68-72
36. Adhikari N, Sinha N, Narayan R, Saxena DK. Lead- induced cell death in testes of young rats. *J. Applied Toxicol.* 2001, 21, 275-277
37. Amany R, Ragab ME, Elham AE. The effect of lead toxicity on male albino rats reproduction with ameliorate by vitamin E and pumpkin seeds oil. *Benha Veterinary Medical Journal.* 2019, 28(1).
38. Nadia A, Hamadouche N, Sadi O, Kharoub M, Sliman A, Aoues. The protective effect of vitamin E against genotoxicity of lead acetate intra peritoneal in male rat, *Arch. Biol. Sci., Belgrade.* 2013, 65(4): 1435-1445.
39. Madiha MM, Makhlof, Heba MS, Eldien, Dorreia AM, Zagloul, et al. The Effect of Lead Acetate on Testicular Structure and Protective Effect of Vitamin E in Adult Albino Rat. *Egypt. J. of Histol.* 2008, 31(2): 406 -418.
40. Wang BJ, Lien YH, Yu ZR. Supercritical fluid extractive fractionation: study of the antioxidant activities of propolis. *Food Chem.* 2004, 86: 237-243.