

Intra-osseous Schwannoma of Mandibular Symphysis: A rare case presentation

ABSTRACT:

Aim: To describe a rare presentation of intra-osseous schwannoma of mandible.

Presentation of Case: A rare representation of diffuse non-tender swelling at parasymphysis of mandible with bicortical expansion and negative aspiration on FNAC. A complete wide surgical enucleation of soft, doughy mass was done through intra-oral papilla preserving flap followed by suitable dissection preserving the vital nerves and vessels in the vicinity was done. Histopathologically the tissue tumor mass arranged in Antoni A pattern showing Verocay bodies formed by streaming fascicles of spindle shaped schwann cells forming palisade arrangement around central acellular, eosinophilic areas.

Discussion: Neurilemmomas is a typical histopathological finding with typical histological features includes Antoni A areas, Antoni B areas, or both. Antoni A regions have high cellularity and are composed of densely packed spindle cells arranged in palisades. On the other hand, Antoni B regions have more myxoid structures and two palisading rows of aligned nuclei in an eosinophil zone.

Conclusion: Intraosseous lesions located in the peripheral region with non-specific clinical and radiographic features often lead to diagnostic confusion. Most of the lesions located in the environs of the teeth are odontogenic in origin. Yet, other possibilities like intraosseous scwhannomas must be considered.

Keywords: Intra-osseous, Schwannoma, Mandible.

INTRODUCTION

“Schwannomas (neurilemmomas) are slow-growing, benign neoplasms derived from Schwann cells, the sheath cells that cover myelinated nerve fibers. These tumors most commonly arise in the soft tissues of the head and neck, as well as on the flexor surfaces of the upper and lower extremities. Intraoral lesions are uncommon, however, and intraosseous schwannomas, are even rarer”.¹ “The most common site of occurrence is the mandible, a characteristic traditionally attributed to the long intraosseous path of the inferior alveolar nerve”.² “Other sites reported include the sacrum, vertebra, skull, maxilla, clavicle, scapula, sternum, ribs, humerus, radius, ulna, ilium, pubic bone, femur, patella, fibula, tibia, and bones of the hands and feet”.³

CASE REPORT

A 32-year-old reported to the unit of Oral and Maxillofacial Surgery at IGIMS Patna with a slowly growing swelling on the left side of lower jaw since 6 months (Figure 1). On examination, a diffuse swelling was observed on the left side of chin, above the base of the mandible extending to the left submandibular region with normal overlying skin approx of 3*4 cm. The swelling was firm in consistency, non pulsatile, non - tender, non – fluctuant without any localized rise in temperature. Intraoral examination revealed bicortical expansion of the alveolar ridge in the same region with obvious vestibular obliteration. A panoramic radiograph revealed a well-circumscribed, unilocular radiolucent lesion. Nothing could be aspirated on FNAC trial.

A complete wide surgical enucleation of soft, doughy mass was done through intra-oral papilla preserving flap followed by suitable dissection preserving the vital nerves and vessels in the vicinity was done(Figure 2).The specimen was sent for histopathological examination(Figure 3).

Histopathologically the tissue tumor mass arranged in Antoni A pattern showing Verocay bodies formed by streaming fascicles of spindle shaped schwann cells forming palisaded arrangement around central acellular,eosinophilic areas. (Figure 4)

DISCUSSION

“In 1985, Erlandson classified schwannomas into several histological types”⁴. “Clinicopathological schwannoma variants, including common, plexiform, cellular, epithelioid, and ancient. Intraoral ancient schwannomas are rare (prevalence rate: 1%), with the majority of the tumours prevalent on the tongue, followed by other locations including the palate, buccal mucosa, lips, and gingival”⁵. “Typical histological features of schwannomas include Antoni A areas, Antoni B areas, or both. Antoni A regions have high cellularity and are composed of densely packed spindle cells arranged in palisades. On the other hand, as described by Salehinejad J , Antoni B regions have more myxoid structures and two palisading rows of aligned nuclei in an eosinophil zone as seen in our histopathological report too”⁶.

“Embryologically, Schwann cells arise during the fourth week of development from a specialized population of ectomesenchymal cells derived from neural crest. These cells serve as thin barrier around each extracranial nerve fiber of motor and sensory nerves and wrap larger fibers with myelin sheath to enhance nerve conductance”⁷. “Schwannomas commonly arise from spinal nerve roots and intracranial nerves of the face, neck, extremities, mediastinum, and pelvis”⁸. “Most commonly affected nerve is the VIII cranial nerve (acoustic neuromas). Additionally, as per reporting by Mohan A, we too experienced that hemorrhage from adjacent tissue, necrosis, hyalinization, and cystic degeneration may also occur in the tumor tissue”⁹. “The main clinical differential diagnoses consisting of other benign neoplasms at this site include neurofibroma, traumatic neuroma, nonossifying fibroma, lipoma, and leiomyoma”¹⁰. The schwannomas may be indistinguishable from other benign tumors, so biopsy and histological examination are essential.

CONCLUSION

Though schwannoma of the head and neck region is uncommon, it should be investigated as a differential diagnosis in an adult with a unilateral slow developing mass in the head and neck region. Intraosseous lesions in the periphery with non-specific clinical and radiographic characteristics frequently cause diagnostic confusion. The majority of lesions found around teeth are odontogenic in origin. Other alternatives, such as intraosseous schwannomas, must also be explored.

Ethical Approval:

As per international standard or university standard written ethical approval has been collected and preserved by the author(s).

Consent

As per international standard or university standard, patient(s) written consent has been collected and preserved by the author(s).

REFERENCES

1. Swami P, Raval R, Kumawat V, Nyklesh V. Maxillary schwannoma A case report of a rare tumor. *Natl J Maxillofac Surg*. 2019 Jul-Dec; 10(2):245-248
2. Yosuke Harazono, Kou Kayamori, Junichiro Sakamoto, et al. Retrospective analysis of schwannoma in the oral and maxillofacial reclinicopathological characteristics and specific pathology of ancient change, 2022;60(3) 326-331
3. Ahlawat S, Blakeley JO, Langmead S, Belzberg AJ, Fayad LM. Current status and recommendations for imaging in neurofibromatosis type 1, neurofibromatosis type 2, and schwannomatosis. *Skeletal Radiol*. 2020;49(2):199-219
4. Vera-Sirera B, Fernades-Ciacha L, Floria LM, Vera-Sempere F. Palatal ancient schwannoma: optical, immunohistochemical and ultrastructural study with literature review. *Eur Arch Otorhinolaryngol*. 2017;274(12):4195- 202
5. Butler RT, Patel RM, McHugh JB. Head and Neck Schwannomas: 20-Year Experience of a Single Institution Excluding Cutaneous and Acoustic Sites. *Head Neck Pathol*. 2016;10(3):286-91
6. Salehinejad J, Sahebhasagh Z, Saghafi S, Sahebhasagh Z, Amiri N. Intraoral ancient schwannoma: A systematic review of the case reports. *Dent Res J (Isfahan)*. 2017;14(2):87- 96.
7. Goldblum JR, Folpe AL, Weiss SW, Enzinger FM. *Enzinger & Weiss's soft tissue tumors*. 7th ed ed: Elsevier; 2020. ix, 1294 p. p.
8. Harhar M, Ramdani A, Bouhout T, Serji B, El Harroudi T. Retroperitoneal Schwannoma: Two Rare Case Reports. *Cureus*. 2021 Feb 20;13(2):e13456. doi: 10.7759/cureus.13456. PMID: 33777545
9. Mohan A, Kadani M, Nalamolu B, Srilatha T, Kakati I. Maxillary Schwannoma – A rare case report. *Oral Maxillofac Pathol J* 2022; 13(2): 179-182

10. Fechner RE, Mills SE. Miscellaneous mesenchymal lesions. In: Tumors of the bones and joints. Washington, DC: American Registry of Pathology; 2002. p. 206.

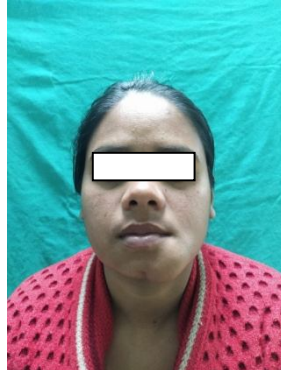

Figure 1: Diffuse swelling on the left side of chin, above the base of the mandible extending to the left submandibular region with normal overlying skin.

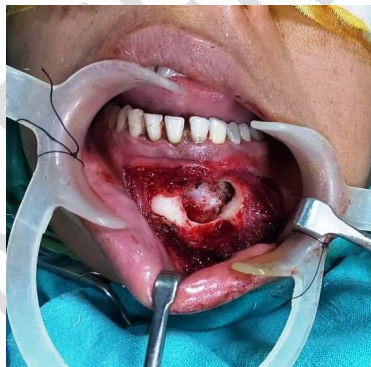

Figure 2: Wide surgical enucleation of soft, doughy mass was done through intra-oral papilla preserving flap followed by suitable dissection preserving the vital nerves and vessels in the vicinity

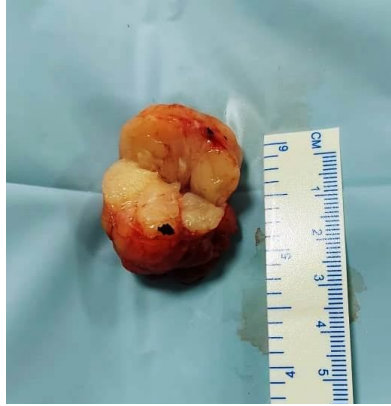

Figure 3: The specimen sent for histopathological examination

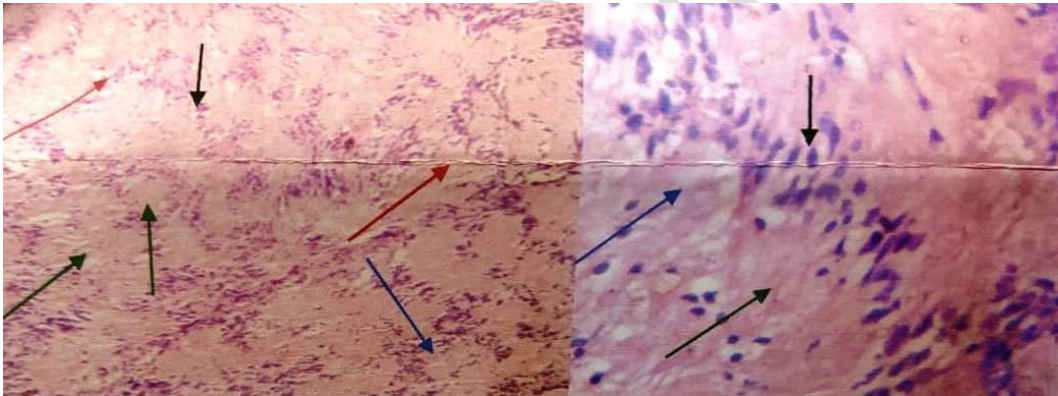


Figure 4 Antoni A pattern (RED), with Verocay Bodies(Green), Palisaded nuclei (Black)and Schwann cells(Blue)