

## Original Research Article

# Evaluation of Results of Separate Vertical Wirings for the Treatment of Extra-Articular Fractures of the Distal Pole of the Patella.

### Abstract

**Background:** Patella connects quadriceps ligament and tendon. Base peak. proximal non-articular distal patella. Common subcutaneous patella injurie. Patella focuses Quadriceps forces and facilitates arm extension. It rotates the knee extensor. At maximum extension, the patella raises the quadriceps moment arm by 30%. Patellar avulsion fractures are classified independently. 9.3% to 22.4% of patellar fractures are thus. AO 34-A1 extra-articular lower pole fractures. Men's risk is double women's. Rapid flexion against quadriceps contraction causes this fracture. After bone removal, the patellar tendon is frequently sutured transosseously. Long fixation and sluggish recovery cause quadriceps weakness. Two of 25 patients had problems with poor vertical wirings. We examined 2 vertical wiring procedures for extra-articular distal patella fractures. **Objective:** To look at how well separate vertical wirings work for treating fractures outside of the joint at the end of the patella. **Method:** Prospective, observational study. The study was done from July 2015 to June 2017 at NITOR's Department of Orthopedics. Patients with post-traumatic distal patella extra-articular fractures admitted to NITOR comprised the study population. From July 2015 to June 2017, NITOR took in 185 people with closed patella fractures. 52 patients had patellar fractures. At NITOR, 46 people with lower pole patella fractures were wired vertically with surgery. NITOR checked up on 40 people. After 18 weeks, the final functional result was looked at. Bostman knee score measured how the knee worked. **Results:** 40 patients with extra-articular distal patella fractures were studied to determine the effectiveness of 2 vertical wirings. 9 (22.5%) of 40 patients were 30 or younger, 10 (25%) were 31-40, and 8 (20%) were 41-50. 7% and 6% of patients were in their 5th and 6th decades. The youngest patient was 18 and the oldest was 70. Out of 40 cases, 31 (or 77.5%) were men and 9 (or 22.5%) were women. The number of men to women is 3.5:1. Most of the 30 broken bones (75%) healed between 6 and 10 weeks. The average time for a radiological union to happen was 82.4 weeks. **Conclusion:** According to the study's findings, extra-articular fractures of the distal pole of the patella commonly affect men in early middle age and farmers. Separate vertical wirings cure outside-the-joint distal patella fractures. Most patients can return to their pre-injury activities, but their knees are weaker.

**Keywords:** Patella, surgery, Orthopaedic, Separate Vertical Wirings, Extra-Articular Fractures

## **Introduction:**

Patella joins the quadriceps tendon and patellar ligament. Its base is higher than its summit. Distal patella is non-articular, proximal is articular. Subcutaneous patella is often injured [1]. Patella centralizes Quadriceps forces and increases extensor mechanism movement arm. It enhances knee extensor effectiveness by raising it away from the knee's axis of rotation [2]. Patella raises quadriceps moment arm by 30% at full extension, according to biomechanical studies [3]. Distal pole patella fractures are unusual non-articular avulsion injuries that damage the extensor mechanism. When the extensor retinaculum is damaged, the quadriceps muscle displaces the superior fragment proximally, making closed reduction of patella pieces impossible and requiring surgery [4]. Avulsion fractures of the inferior patellar pole are classified separately. 9.3% to 22.4% of surgically repaired patellar fractures are so [5] Extra-articular lower pole fractures are AO 34-A1. Men have double the risk as women. This fracture is caused by a rapid flexion against a quadriceps muscular contraction [2]. Displaced inferior pole pieces may be too tiny for anatomical reduction and internal fixation. Treatments vary Magnusson wiring, separate vertical wiring, cancellous screw fixation, tension band wiring, cerclage wiring, fixation of the lower pole augmented by a patellotibial SS wire loop, basket plate fixation, and excision of the lower pole of the patella each have their own advantages and disadvantages. Despite the many therapeutic choices, there is no consensus on how to treat these fractures [6]. After removing bone pieces, the patellar tendon is usually attached by transosseous pull-out suture. This surgery needs a long fixation period and slows recovery, resulting in quadriceps weakness. Yang and Byun devised vertical wire for distal patella fractures in 2003[7]. Lister invented intraosseous wire suture. He made oblique bone tunnels in each mid-patellar fracture fragment and wired them together. Our method modifies his. Because the shards are too small to construct bone tunnels, we wrap them with vertical wires. Tightening the wires aligns the anterior and posterior fragments. Biomechanically, this approach was stronger than tension band wiring. At 22-month follow-up, 25 patients had 100% union and no wire breakage. (2003) Two of 25 patients had difficulties due to the weak holding power of distinct vertical wirings, Song et al. (2014) stated [8]. In this study, we compared 2 vertical wiring techniques for treating extra-articular distal patella fractures.

## **Objective:**

- To analyze the outcome of separate vertical wirings in the treatment of extra-articular fractures of the distal pole of the patella.

## **Methods and Materials:**

The present study was a Prospective, Observational Study. The study was conducted in the Department of Orthopedics, National Institute of Traumatology and Orthopaedic Rehabilitation (NITOR) over a period of 2 years from July 2015 to June 2017. Patients with post traumatic extra-articular fractures of distal pole of the patella within three weeks of incidence were the

study population, those who are admitted in NITOR. A total of 40 patients met the following selection criteria were selected by convenient sampling from the study population.

**Inclusion criteria:**

- Adult patients with 18 years and above
- Both sexes
- Patients with closed extra-articular fractures of the distal pole of the patella
- Those presented within 3 weeks of injury.

**Exclusion criteria:**

- Less than 18 years
- Open fractures
- Pathological fractures other than osteoporotic fracture
- Unstable medical illness not permitting operative treatment
- Multiple injuries
- Late presentation after 3 weeks.

**Data Collection tools**

Data was collected with a pre-tested structured questionnaire included history, physical examination, radiological assessment; per-operative & post-operative follow up.

**Data Collection Procedure:**

From July 2015 to June 2017, 185 patients of closed fracture patella were admitted in NITOR. Among them, 52 patients were fracture lower pole of patella. Among 52 patients, 46 cases were closed fracture lower pole of patella & were treated surgically by separate vertical wiring at NITOR. Among them 40 patients were attended to regular follow up visit at NITOR. At least 18 weeks follow up was targeted to evaluate final functional outcome. The functional outcome was assessed by Bostman knee score. (Bostman et al., 1981)

**Data processing and statistical analysis:**

After data collection, the raw data was compiled and tabulated according to key variables. All statistical analysis of different variables was analyzed by using SPSS (Statistical Package for Social Science) and using appropriate formula. Results were presented by table and graphs.

**Results:**

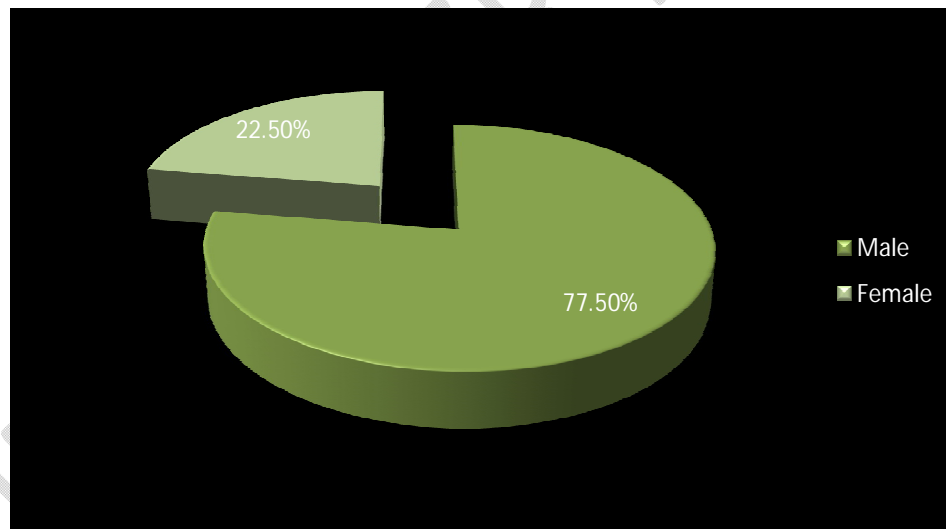
A total of 40 patients with extra-articular fractures of distal pole of the patella were included in the study to evaluate the outcome of fixation with 2 separate vertical wirings. Out of 40 patients, 9 (22.5%) were 30 or below 30 years old, 10 (25%) were 31-40 years and 8 (20%) were 41 - 50

years. The incidence of the patient in the 5th and 6th decade of life was rare (7% and 6% respectively). The mean age of the patients was  $43.30 \pm 15$  years and the youngest and oldest patients were 18 and 70 years old respectively.

**Table 1: Age distribution of the study patients (n =40)**

Age	Frequency	Percentage (%)
18-30	9	22.5
31-40	10	25
41-50	8	20
51 -60	7	17.5
>60	6	15
Total	40	100

Out of 40 cases 31(77.5%) patients were male and 9(22.5%) patients were female. The male: female ratio is 3.5:1



**Figure 1: Pie diagram showing the sex distribution of the patients (n=40)**

Table 2 shows occupational distribution of the patients, maximum 12 (30%) patients were Farmer. Then businessman, Housewife & students all were 17.5%, Service holders & laborers were 10% & 7.5% respectively.

**Table 2: Occupational distribution of the study patients (n =40)**

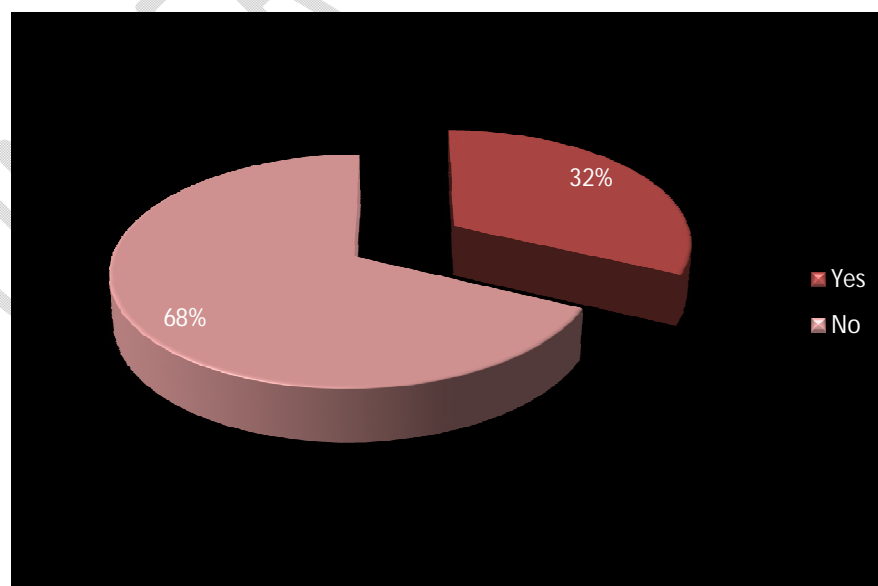
Occupation	Frequency	Percentage (%)
Farming	12	30
Business	7	17.5
Housewife	7	17.5
Student	7	17.5
Service	4	10
Laborer	3	7.5
<b>Total</b>	<b>40</b>	<b>100</b>

Below table 3 shows the mechanism of injury. Common cause of injury was RTA& fall on slippery ground both were 45%. The rest 10% were sports injury.

**Table 3: Mechanism of injury of the study population (n=40)**

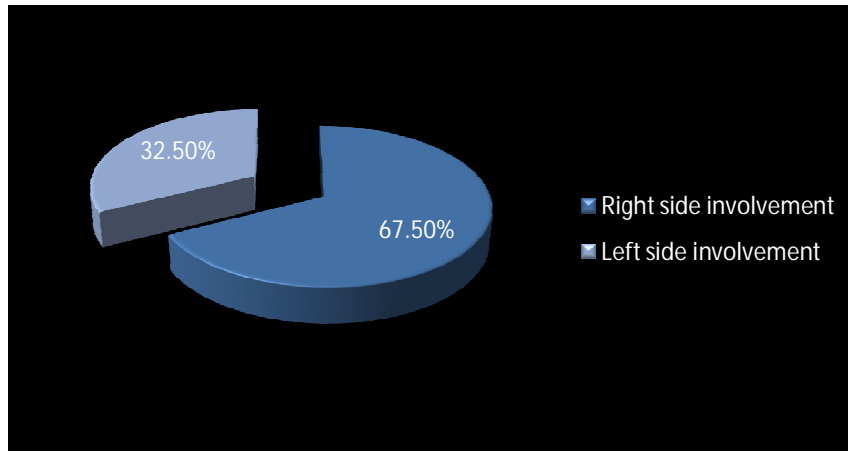
Mechanism of injury	Frequency	Percentage (%)
RTA	18	45%
Fall on slippery ground	18	45%
Sports injury	4	10%
<b>Total</b>	<b>100</b>	<b>100%</b>

Below figure shows 32% lower pole fractures were comminuted & the rest (68%) were non comminuted.



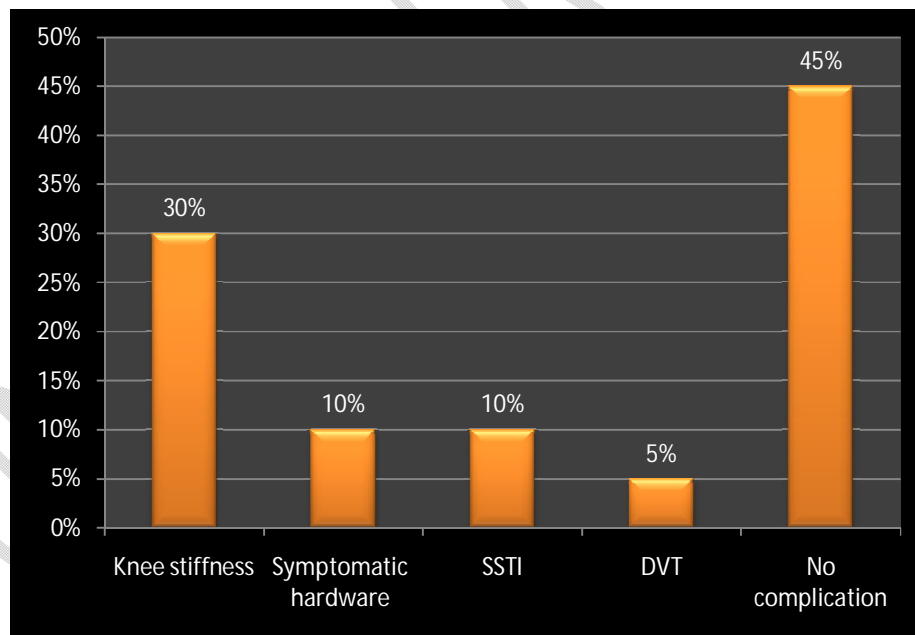
**Figure 2: Pie diagram showing the comminution of lower pole fragments.**

Below figure shows that 27(67.5%) patients had right side involvement and 13(32.5%) patients had left side involvement.



**Figure 3: Pie diagram showing the side distribution of injured limb (n=40)**

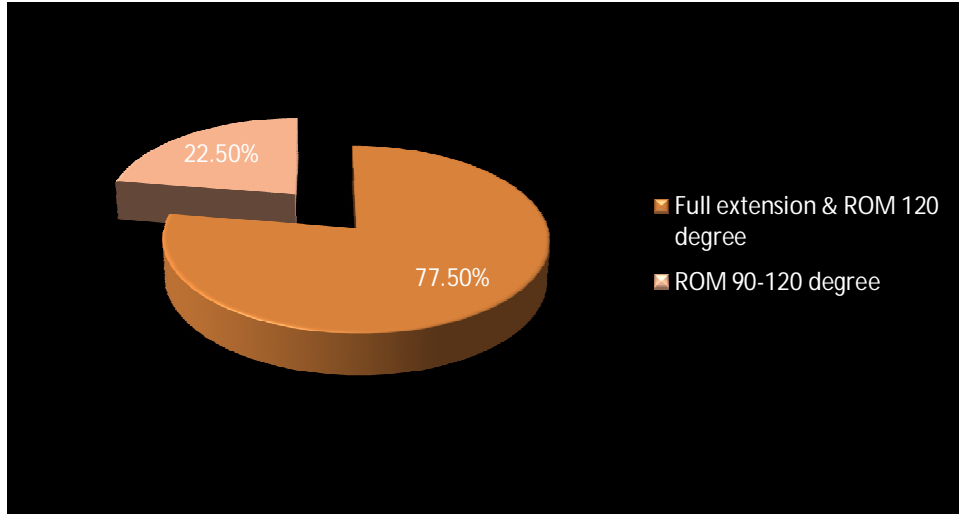
Patients had Knee stiffness, Symptomatic hardware & SSTI both were 10%, only 2 (5%) patient had DVT and rest of the patients 18 (45%) had no complications.



**Figure 4: Pie diagram showing the complications of the patients (n=40)**

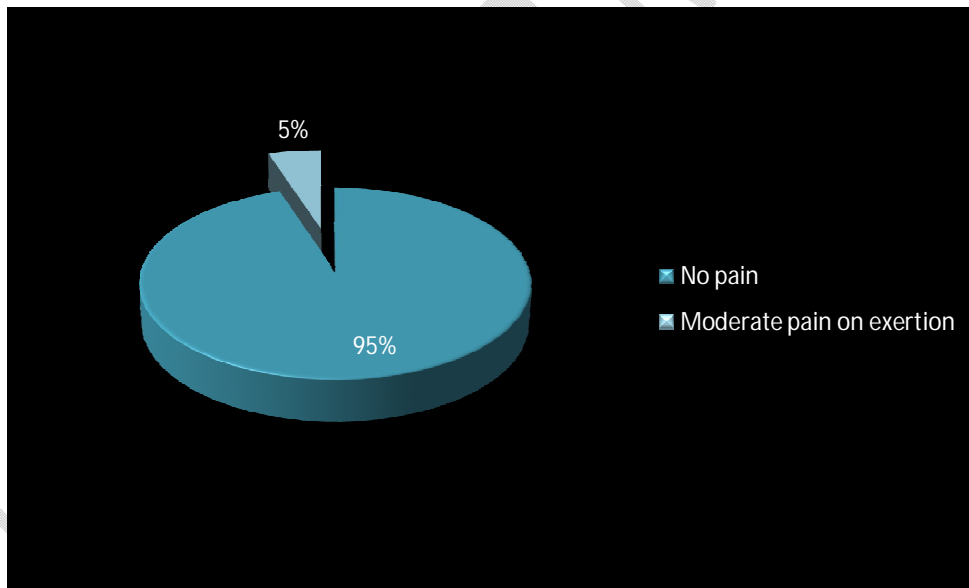
31(77.5%) patients had full extension & ROM 120 degree & 9(22.5%) patients had ROM 90-120 degree at final follow-up.

UNDER PEER REVIEW



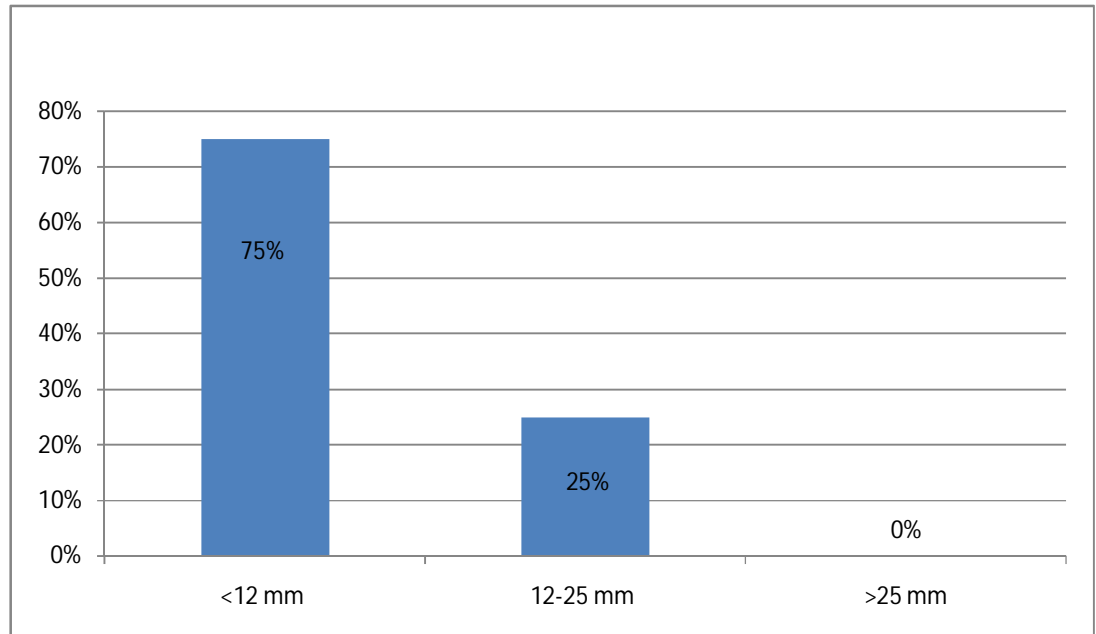
**Figure 5: Pie diagram showing the ROM of the knee**

38(95%) patients had no pain & only 2 (5%) patients had moderate pain on exertion at final follow-up.



**Figure 6: Pie diagram showing the pain status**

Pie diagram showing the atrophy of thigh muscles (10 cm proximal to patella), 30 (75%) patients had atrophy <12 mm & 10 (25%) patients 12-25 mm atrophy & none of them had atrophy of the thigh >25 mm.



**Figure 7: Pie diagram showing the atrophy of thigh muscles**

Most of the fractures 30 (75%) were united between 6-10 weeks. Mean duration of radiological union was  $8 \pm 2.4$  weeks.

**Table 3: Duration of radiological union (weeks) (n =40)**

Union (weeks)	No of patient	Percentage
<6weeks	0	0
6- 10 weeks	30	75
10- 12 weeks	8	20
12- 14 weeks	2	5
Delayed union	0	0
Non union	0	0
<b>Total</b>	<b>15</b>	<b>100</b>

Table showing functional results assessed, by Bostman Knee Scoring 24 (60%) patients had excellent outcome, 16 (40%) patients had good outcome and no patient had unsatisfactory result.

**Table 4: Functional result assessment by Bostman Knee Scoring (n=40)**

<b>Bostman Knee Score</b>	<b>No of Patients</b>	<b>Percentage</b>
Excellent(28 – 30)	24	60
Good(20 – 27)	16	40
Unsatisfactory(<20)	0	0
Total	40	100

Table 5 shows final outcome of the study. All of the patients 40(100%) were satisfactory (Excellent + Good) and no patients were unsatisfactory

**Table 5: Distribution of the results according to the final outcomes (n=40).**

<b>Result</b>	<b>No of Patient</b>	<b>Percentage</b>
Satisfactory (Excellent + Good)	40	100
Unsatisfactory	0	0
Total	40	100

## **Discussion:**

The patella is a sesamoid bone located in the tendon of the quadriceps femoris muscle. Extra-articular fractures of the distal pole of the patella account for only 9.2–2.4% of total patellar fractures [9].

The average age of patients in this study was 43.3 15 years, with the youngest patient being 18 years old and the oldest patient being 70 years old. Males made up the bulk of the patients (77.5%), and 32.5% of them farmed as their primary activity.

Fewer individuals are available for studies, and fewer reports are available. Distal pole patellar (patellar tendon attachment) extra-articular fractures are notoriously challenging to treat due to the small bone fragments and the knee's extension mechanism. Extra-articular distal-pole patellar fractures necessitate careful consideration of the surgical approach taken [10].

Anatomical reduction is challenging, and traditional wire or screw fixation is rarely successful for secure fixation due to combination.

The most common method for treating transverse patellar fractures, modified tension band wiring, is insufficient for achieving firm fixation of extra-articular fractures of the distal pole of the patella, especially comminuted ones, for the following reasons: tension band wires may become loose during joint exercises, loss of reduction may occur, joint movement may be restricted due to irritation of soft tissues caused by prominent k-wires, and complications including internal femoral oblique fracture may occur [11].

Anterior knee discomfort has been linked to the use of several wires for internal fixation in the transosseous pullout suture technique and wiring operations, such as cerclage wiring [10].

Recent years have seen a number of reports on research into alternative methodologies that aim to address limitations in the status quo [9].

Comminuted extra-articular distal pole patella fractures, as proposed by Yang and Byun (2003), should be wired separately vertically. According to a cadaveric biomechanical research, this technique is superior for treating comminuted fractures of the distal patella compared to the standard procedure, which involves shaping two wires into the shape of an 8 [10]. However, considering that in our investigation, union was achieved with bone fragments anteriorly displaced in 50% of the instances, separate transverse compression force alone may not be sufficient to induce anatomical reduction.

In patients with severe comminuted fractures of the distal pole of the patella, Matejic et al. (2008) found that basket plate osteosynthesis was more effective than partial patellectomy in terms of discomfort, mobility, joint movement, and muscular strength [9]. We don't have access to the basket plate here in the States.

In the patello-femoral joint, the distal pole of the patella is an extra-articular structure. Therefore, it was unnecessary to perform extensive treatment for an impossible-to-reduce distal patella. Instead, it is more crucial to restore the extension mechanism of the knee by maintaining the bone fragment of the distal patella.

Yang and Byun's (2003) separate vertical wiring technique prioritizes knee extension mechanism preservation above anatomical reduction [10]. Due to the tendency of the bone fragment to shift anteriorly during union, achieving anatomical reduction with separate vertical wiring is challenging. Anterior displacement of bone fragment, bone fragment length, and the presence of comminution were all thought to be related; however no such association was identified. They reasoned that the stress placed on the bone fragments during surgery, as well as the severity of the patient's osteoporosis, were responsible for the anterior displacement. They didn't check the patient's bone density, so they didn't know for sure what caused the wires to get taut during surgery.

Clinical research by Yang and Byun (2003) found that 29 patients treated for comminuted fractures of the distal pole of the patella with distinct vertical wiring had a mean Bostman score of 29.5 points at the last follow-up [10].

Following a minimum of 1 year of separate vertical wiring, the current study found that patients had attained firm fixation and normal joint movement, with a Bostman score of excellent (27.1 on a scale of 0–100) according to clinical and radiological examinations. Therefore, it is clear that while treating extra-articular distal pole patella fractures, preservation of the knee's extension mechanism is more important than restoration of anatomical reduction.

### **Conclusion:**

In the light of the findings of the study, it could be concluded that extra-articular fractures of the distal pole of the patella usually occur in early middle age with a male preponderance with most of patients being involved in farming. Separate vertical wirings are an effective method for the treatment of extra-articular fractures of the distal pole of the patella. Majority of the patients have returned to pre-injury activities with mild limitations in knee movements.

## References:

1. Iqbal, M.Z. et al., 2015. Comparison of outcome of fractures of inferior pole of patella. *Journal of Sheikh Zayed Medical College*, 7(1), pp.900-03.
2. Gupta, A.K., Agarwal, R., Singh, V. & Meena, R.L., 2016. Fixation of extra articular fracture of inferior pole of patella by on needle. *Scholars Journal of Applied Medical Sciences (SJAMS)*, 4(1C), pp.186-88.
3. Cramer, K. & Moed, B., 1997. Patellar Fractures: Contemporary approach to treatment. *The Journal of American Academy Orthopedic Surgeon*, 5(6), pp.323- 31.
4. Chang, S.-M. & Ji, X.-L., 2011. Open Reduction and Internal Fixation of Displaced Patella. *Journal of Orthopaedic Trauma*, 25, pp.366-70.
5. Kastelec, M. & Veselko, M., 2004. Inferior Patellar Pole Avulsion Fractures: Osteosynthesis Compared with Pole Resection. *The Journal of Bone and Joint Surgery*, 86-A(4), pp.696-701.
6. Veeranna, H.D., P.R, C. & R, S., 2014. Lower pole patella fracture: a combination of cancellous screw fixation and tension band wiring. *Journal of Evolution of Medical and Dental Sciences*, 3(31), pp.8575-78.
7. Kim, Y.M. et al., 2011. Separate Vertical Wirings for the Extra-articular Fractures of the Distal Pole of the Patella. *Knee Surgery & Related Research*, 23(4), pp.220-26.
8. Song, H.K., Yoo, J.H., Byun, Y.S., Yang, K.H., 2014. Separate vertical wirings for the fixation of comminuted fractures of the inferior pole of the patella. *Yonsei Med J*, 55(3), pp.785-91.
9. Matejcic, A. et al., 2008. Multifragment fracture of the patellar apex: basket plate osteosynthesis compared with partial patellectomy. *Arch Orthop Trauma Surg*, 128, pp.403-08.
10. Yang, K.H. & Byun, Y.S., 2003. Separate vertical wiring for the fixation of Comminuted fractures of the inferior pole of the patella. *The Journal of Bone & Joint Surgery*, 85-B, pp.1155-60.
11. Berg, E.E., 1997. Open Reduction Internal Fixation of Displaced Transverse Patella Fractures with Figure-Eight Wiring Through Parallel Cannulated Compression Screws. *Journal of Orthopaedic and Trauma*, 11(8), pp.573-76

UNDER PEER REVIEW