

# **Phototoxic maculopathy may recovery by antioxidant and vitamin supplements**

## **Abstract**

The aim of this study is to evaluate the efficacy of antioxidant and vitamin supplements for treatment of phototoxic maculopathy. The results of antioxidant and vitamin supplements treatment applied to a 51-year-old male patient due to phototoxic maculopathy in his right eye after uneventful phacoemulsification surgery was evaluated. Spectral domain optical coherence tomography image was showed the severe ellipsoid zone disruption. Oral antioxidant and vitamin supplements was started for the patient. At the end of one year, visual acuity was reached 1.0 and ellipsoid zone damage improved significantly. Antioxidant and vitamin supplements may be useful for recovery of phototoxic maculopathy.

**Keywords:** Antioxidant and vitamin supplements, phototoxic maculopathy

## **Introduction**

Iatrogenic retinal phototoxic damage due to operating microscope illumination is a serious problem causing visual loss and it may be seen after any kind of ocular surgery. Phototoxic retinopathy after cataract surgery can still be seen even though there is decreased exposure to operating microscope light energy due to reduced duration of the surgery with phacoemulsification method. Phototoxicity leads to mild yellow-white discoloration of the retina, mottled depigmentation of the retinal pigment epithelium (RPE), overlying retinal edema, and disruption of the photoreceptors inner segment/outer segment.<sup>1-2</sup>

Spectral domain optical coherence tomography (SD-OCT) that allows the retina to be examined at least as accurate as histology allows the clinicians for detect unnoticeable changes with normal fundusoscopic appearance.<sup>3</sup> In this report, we present SD-OCT findings in a patient with operating microscope-induced phototoxic maculopathy following uneventful phacoemulsification surgery, which was improved with antioxidant and vitamin supplements.

### **Case report**

A 51-year-old man was admitted to our clinic complaining of decreased visual acuity and distorted vision in the right eye with a history of uneventful phacoemulsification surgery. The patient had no known retinal disease and he was not using any systemic medication. The patient had a history of uneventful phacoemulsification surgery with retrobulbar block in a different center 2 weeks ago. The best corrected visual acuity of the right eye was 0.4 in Snellen chart. He had a transparent cornea and a centered posterior chamber intraocular lens. Dilated fundus examination in his right eye showed foveal pigment mottling approximately 500 micron diameter (fig. 1A) and fundus fluorescein angiography revealed foveal avascular zone irregularity and enlargement (fig. 1B).

The SD-OCT study demonstrated normal foveal contour with a reduced central foveal thickness and disruption of the photoreceptors' inner segment-outer segment (fig. 2A). Then, antioxidant and vitamin supplement was initiated because it might help the regeneration of photoreceptor cells. The patients was take perioral a drug including lutein 10 mg and zeaxanthin 2 mg, vitamin C 180 mg and vitamin E 30 mg, zinc 15 mg, and omega-3-fatty acids.

Six months after the application of antioxidants and vitamins, the visual acuity was measured as 0.7 and it was increased to 1.0 with Snellen chart in 12 months of treatment. SD-OCT

showed improvement of the outer retinal layers and ellipsoid zone lines, and the foveal thickness became stable from the 9th month onwards (Fig 2 B-D). The patient's complaints of distorted vision (metamorphopsia) were reduced significantly but not fully disappeared.

## **Discussion**

The prevalence of retinal phototoxicity after extracapsular cataract surgery was estimated a range of 7 to 28%. As the majority of ocular protective mechanisms including blinking, light aversion, and pupil response will be blocked in the operated patients, the eye becomes more susceptible to light damage. Immobilization of the eye by use of traction sutures over the superior rectus increases the risk of phototoxic maculopathy especially below the fovea. Surgical factors such as prolonged operation time, restriction of eye movements by retrobulbar anesthesia, increased light intensity of operating microscope, and drug use which increases the sensitivity to light increase the prevalence of phototoxic maculopathy.<sup>1</sup> It is less common when cataract is removed by phacoemulsification due to reasons such as not obstructing eye movements and short surgical duration.

The characteristic findings of phototoxic maculopathy are oval areas of mild yellow-white discoloration in the retina, mottled pigmentation of the retinal pigment epithelium, and macular edema. More detailed information can be obtained about the level and severity of retinal injury by the spectral domain OCT. Spectral domain OCT shows thinning of the retinal lesion with disruption of the inner/outer photoreceptor layer and retinal pigment epithelium, interruption of the cone outer segment tips, and cystoid macular edema.<sup>4-5</sup> Similar with these literature findings, we found in our patient that the retinal outer layers were impaired and foveal thickness decreased at the time of diagnosis.

There is no common decision on the treatment of phototoxic maculopathy. Yonekawa and al.<sup>6</sup> followed two cases diagnosed as phototoxic maculopathy after vitrectomy without treatment. The visual acuity of the cases was increased but the level of vision could not be removed completely. Some studies reports of oral or periocular steroid use in the treatment of phototoxic maculopathy.<sup>7-9</sup> Dogra et al.<sup>7</sup> gave oral steroids, but the visual acuity was continued to worsen. Menezo et al.<sup>8</sup> gave prednisone orally and triamcinolone acetonide was injected by the subtenon route. Patient visual acuity was reported to be increased minimally. Karp et al.<sup>10</sup> used oral steroid treatment and reported to final visual acuity was 20/20 but noted a persistent diminished paracentral scotoma.

## **Conclusion**

In our study, the patient took an oral drug containing lutein 10 mg, zeaxanthin 2 mg, vitamin C 180 mg, vitamin E 30 mg, zinc 15 mg, and omega-3-fatty acids. At the end of a year metamorphopsia continued but visual acuity was measured as 1.0. It is very likely that severity of the initial lesion and the time to start treatment affect the response to treatment

## **References**

1. Kweon EY, Ahn M, Lee DW, You IC, Kim MJ, Cho NC. Operating microscope light-induced phototoxic maculopathy after transscleral sutured posterior chamber intraocular lens implantation. *Retina* 2009; 29: 1491-1495.
2. Jabbarpoor Bonyadi MH. Bilateral Photic Maculopathy Following Pterygium Excision: Spectral Domain Optical Coherence Tomography Findings. *J. Ophthalmic. Vis. Res.* 2016; 11: 436-438.

3. Berger A, Cavallero S, Dominguez E, Barbe P, Simonutti P, Sahel JA. et al., Spectral-domain optical coherence tomography of the rodent eye: highlighting layers of the outer retina using signal averaging and comparison with histology. *PLoS One* 2014; 9:e96494.
4. Mansour AM, Yunis MH, Medawar WA. Ocular coherence tomography of symptomatic phototoxic retinopathy after cataract surgery: a case report. *J. Med. Case. Rep.* 2011; 5: 133.
5. Shukla D. Optical coherence tomography and autofluorescence findings in chronic phototoxic maculopathy secondary to snow-reflected solar radiation. *Indian J. Ophthalmol.* 2015; 63: 455-457.
6. Yonekawa Y, Abbey AM, Shah AR, Thomas BJ, Capone A Jr. Endoilluminator phototoxic maculopathy associated with combined ICG-assisted epiretinal membrane and internal limiting membrane peeling. *Clin. Ophthalmol.* 2014; 8: 2501-2506.
7. Dogra M, Singh SR, Dogra MR. Operating microscope and endoilluminator-induced retinal phototoxic maculopathy after trans-scleral sutured posterior chamber intraocular lens. *Indian J. Ophthalmol.* 2019; 67: 692.
8. Menezo JL, Peris-Martínez C, Taboada Esteve J. Macular phototrauma after cataract extraction and multifocal lens implantation: case report. *Eur. J. Ophthalmol.* 2002; 12: 247-249.
9. Zheng X, Xie P, Hu Z, Zhang W, Liang K, Wang X. et al., Phototoxic maculopathy induced by quartz infrared heat lamp: A clinical case report. *Medicine* 2017; 96: e5830.
10. Karp KO, Flood TP, Wilder AL, Epstein RJ. Photic maculopathy after pterygium excision. *Am. J. Ophthalmol.* 1999; 128: 248-250.

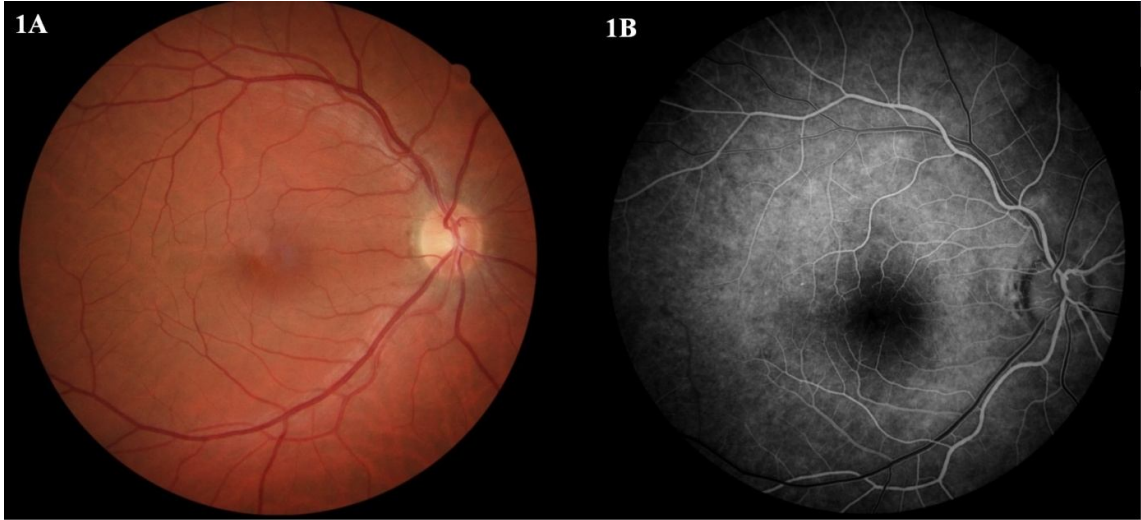


Fig 1 A. Dilated fundus examination in his right eye showed foveal pigment mottling approximately 500 micron diameter

Fig 1 B. Fundus fluorescein angiography revealed foveal avascular zone irregularity and enlargement

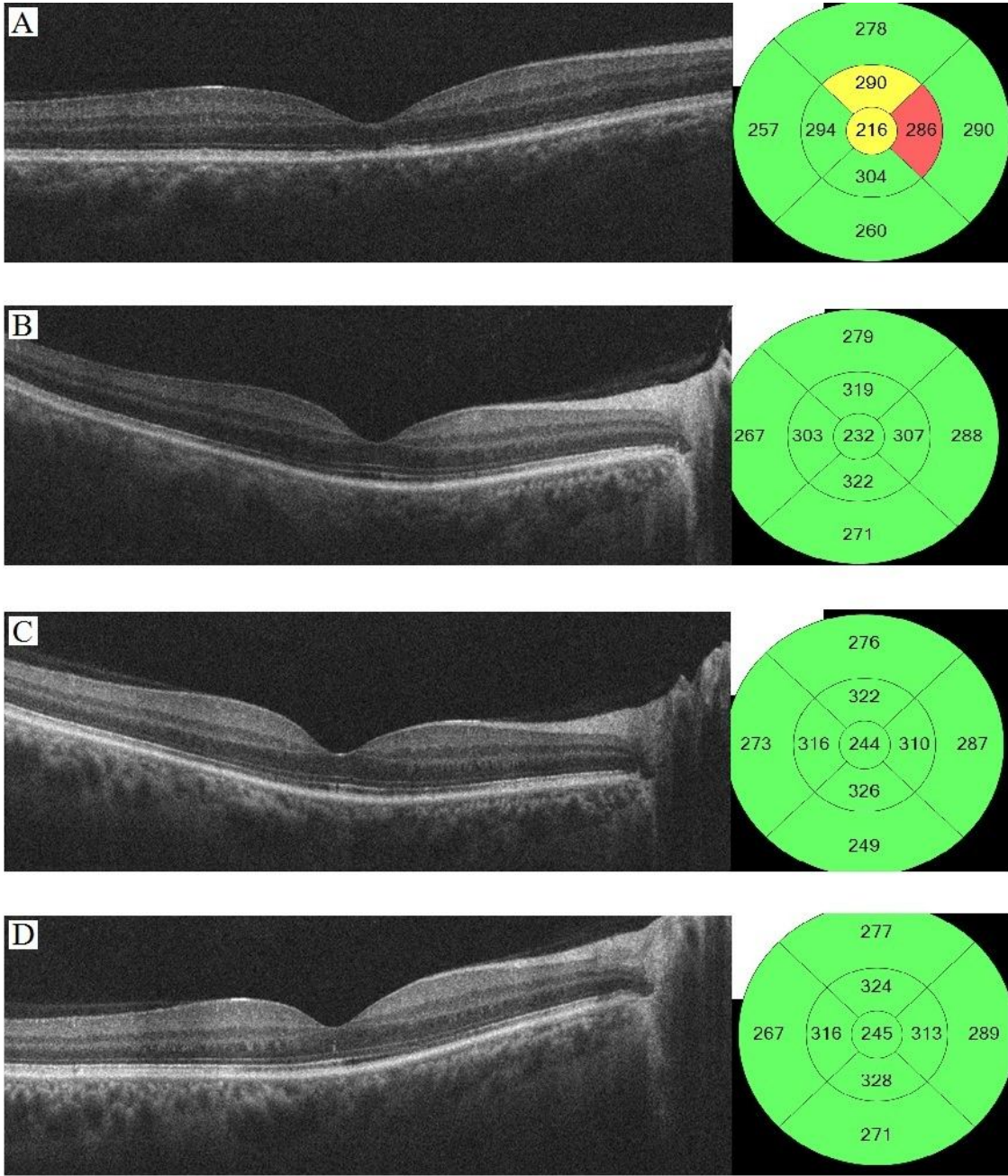


Fig.2 A-D Foveal thickness and disruption of the photoreceptors' inner segment-outer segment