

Case study

INFECTION, INFLAMMATION, VENOUS THROMBOEMBOLISM : A CO-EXISTENCE

ABSTRACT

Aims: Venous thromboembolism is a state of hypercoaguability occurring due to various risk factors causing a prothrombotic state. In this case series, 3 cases are discussed where patients presented as DVT revealing underlying infection later on during the progression of its course.

Place of Study: Department of Medicine, ABVIMS and Dr. RML Hospital, New Delhi and VMMC and Safdarjung Hospital.

Case Series : Case Series – In Case 1, a 25 year old male presented with DVT and was started on anticoagulants. While other risk factors were ruled out, further investigations then were suggestive of Pulmonary Tuberculosis. In Case 2, a 17 year old female with a lower limb swelling suggestive of DVT , with loose stools was found to be positive for Clostridium Difficile infection. In Case 3, a 14 year old boy presenting with a knee swelling with synovitis positive for Staphylococcus aureus also revealed popliteal vein thrombosis .

Discussion : Infections cause a systemic inflammatory response causing increased procoagulant factors, endothelial damage further causing Venous thrombosis.

Conclusion: In patients presenting with venous thromboembolism, infections, systemic or local should be ruled out along with all the known risk factors.

INTRODUCTION

Venous thromboembolism (VTE) encompasses deep venous thrombosis (DVT) and pulmonary embolism (PE). The estimated risk for first time VTE is 100 cases per 100,000 persons per year (annual incidence of 0.1%[1]) but remains a disease with high morbidity and mortality with case fatality rates reported to be 10.6% at 30 days and 23% at 1 year[2].

Deep vein thrombosis (DVT) is a condition that occurs when a blood clot forms in a deep vein. These clots usually develop in the lower leg, thigh, or pelvis, but they can also occur in the arm. A combination of reduced blood flow, increased tendency to clot, changes to blood vessel wall, and inflammation leads to the formation of thrombus. DVT is a multicausal disorder with a majority of the cases caused by prolonged immobilization owing to different reasons or underlying prothrombotic conditions including obesity, OCP use, genetic thrombophilia and autoimmune conditions[3]. While central venous catheters, malignancy, inflammatory disorders and even long-haul flights are other known reasons, clinicians often tend to miss out on a rarer cause for DVT – infections. More recently, inflammation has been identified as playing a clear causal role.[4] In presence of infection or a pathogen there is a stronger inflammation mediated component that triggers activation of platelets, which may accompany damage to the endothelium, resulting in fibrin deposition and thrombus formation.[5]

Infections such as sepsis, COVID-19, active Tuberculosis, HIV, with their varying presentations, have an uncommon association with increased risk for DVT[6]. This necessitates the need for an extensive investigation in cases of DVT with no apparent cause, to rule out any systemic infective etiology. In this case series, we present three such cases of primary DVT which revealed unexpected underlying infective diseases.

Case Presentation

CASE 1

A 25 years old male, with no known co-morbidity and no history of any addiction, was admitted to our department with the complaints of painful left lower limb swelling for 4 days and fever of 2 days' duration. The swelling was sudden in onset, progressively increasing from the thigh to involve the entire limb, associated with redness and gradually increasing pain on standing and walking. Fever was low grade with no specific diurnal variation or other associated symptoms. He did not have any breathlessness, cough or chest pain on admission. On examination, he had a pulse rate of 80 beats per minute, regular in rhythm and a blood pressure of 130/80 mm of Hg with a 97% saturation on room air. Left lower limb pitting edema was appreciable with calf tenderness and mild erythema and normal peripheral pulsations. Right lower limb and rest of general and systemic examinations were within normal limits. Wells score of the patient was 4. A lower limb Doppler was done suggestive of acute deep vein thrombosis with an echogenic thrombus and dilatation of the left posterior and anterior tibial, popliteal, superficial femoral, left common femoral and left external iliac veins. A CECT abdomen and 2D echo were done which were unremarkable. D-Dimer and homocysteine levels were raised but autoimmune profile, MTHFR mutation and thrombophilia profile including Protein C and S were negative. He was started on low molecular weight heparin but developed sudden onset chest pain with sudden breathlessness and hypotension with tachycardia after two days. Immediate CTPA was done (Fig.1) which suggested bilateral acute pulmonary artery thromboembolism. CECT chest also showed multiple enlarged homogeneously enhancing discrete and conglomerated lymph nodes with largest measuring 1.8cm. Patient underwent a systemic thrombolysis which relieved the chest pain and dyspnea. Pain in the lower limb however persisted and repeat venogram showed persistent total occlusion of the veins. He underwent a catheter directed local thrombolysis and was continued on oral anticoagulation thereafter. After 10 days of being discharged developed left sided pleural effusion (Fig. 2) for which a diagnostic tapping was done. Pleural fluid investigations revealed a raised ADA level of 69.4 U/L. He was started on Anti tubercular treatment (ATT) and continued on oral anticoagulant following which he improved clinically.

Fig. 1 CT Pulmonary Artery Angiogram showing multiple acute pulmonary thromboembolism and bilateral hilar lymphadenopathy.

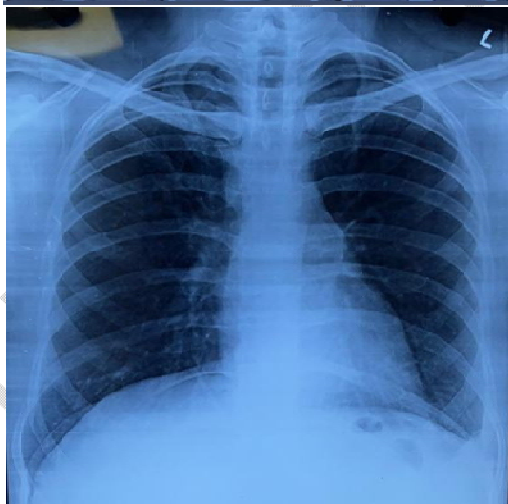
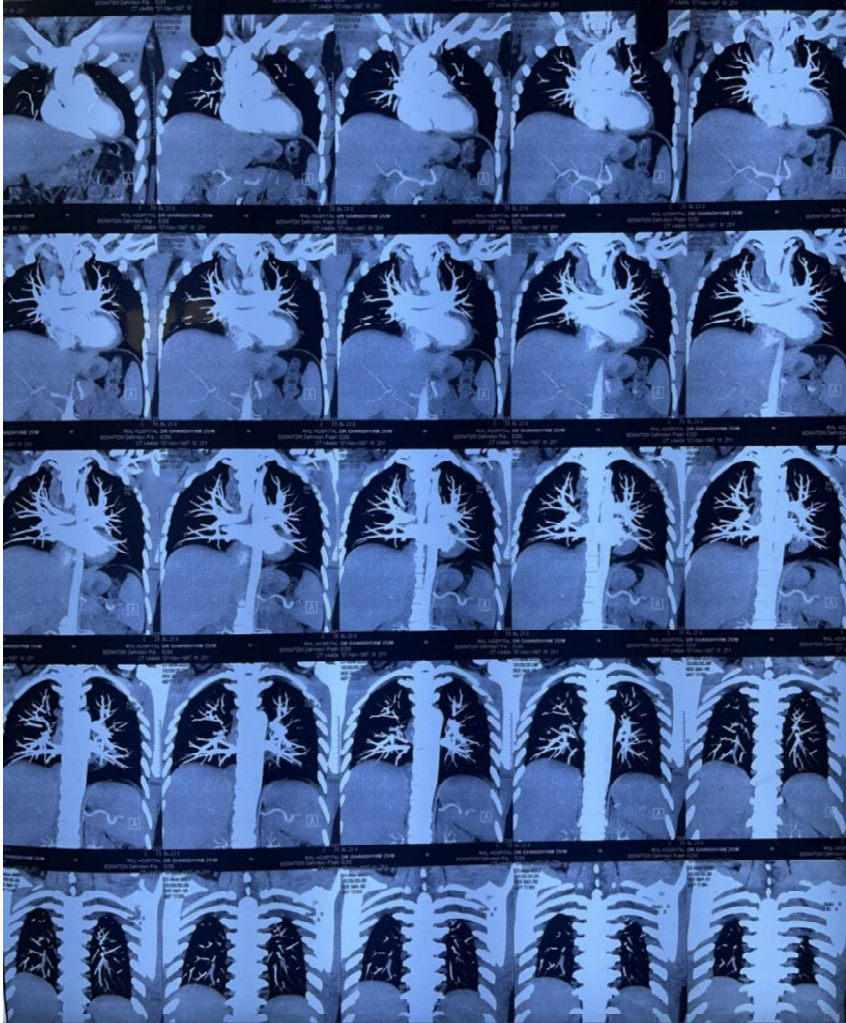


Fig. 2 : Chest Xray showing Left CP angle blunting suggestive of Left sided Pleural Effusion.

17 years old female , with no known co-morbidity , was admitted with complaints of high grade fever since 10 days, associated with vomiting , followed 3 days later by swelling in the right lower limb. The swelling started in the thigh and progressed to involve the entire limb, was associated with pain, initially on walking but progressed to be present at rest as well.

There was no complaint of breathlessness, chest pain or coughing, no history of any drug or OCP use or immobilisation prior to the symptoms. On examination, her pulse was 96 per minute, regular with a blood pressure of 100/70 mm of Hg and oxygen saturation of 96% on room air . The right lower limb was edematous with calf tenderness but no color change and normal peripheral pulsations . With a Wells score of 4, lower limb Doppler and a CT Venography were done suggestive of near complete thrombosis in anterior and posterior popliteal , popliteal, common femoral, internal and external iliac veins on the right side , bilateral common iliac veins and IVC. An IVC filter was inserted and she was worked up for the cause of thrombosis. APLA profile, factor V Leiden mutation , ANA by IFA and ENA profile were negative. DCT was positive while other blood investigations were normal. She was discharged on anticoagulation on symptomatic improvement.

However, she got re-admitted after 15 days with complaints of multiple episodes of loose stools, watery in consistency associated with fresh blood and mucus, high grade continuous type of fever and vomiting. Patient was febrile but vitally stable and general examination revealed pallor. On investigation, her Clostridium difficile Toxin A,B and GDH were positive. CECT abdomen was done suggestive of pancolitis with high possibility of Clostridium difficile. Biopsy taken (Fig. 3) showed crypt abscess with maintained architecture and chronic inflammation in lamina propria, suggestive of focal active colitis.

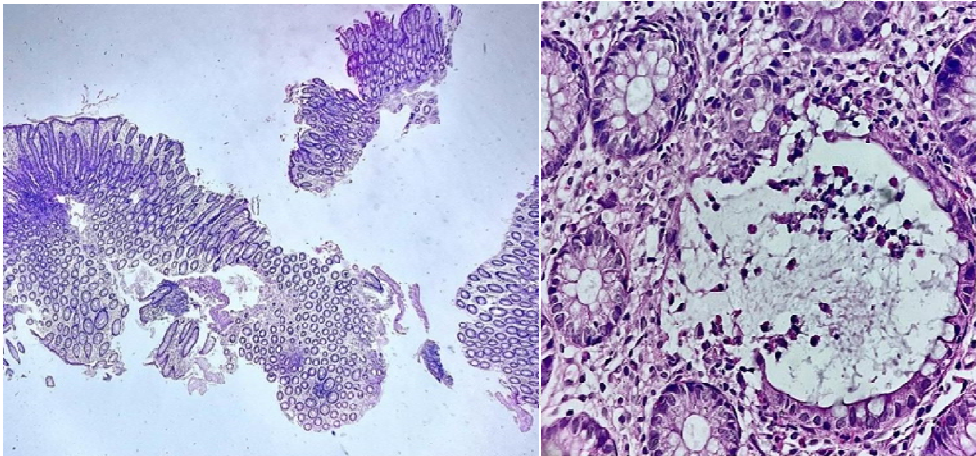


Fig. 3 Histopathological image showing Clostridium difficile associated pancolitis with crypt abscess.

CASE 3

A 14 year old boy presented to emergency with pain and swelling in left knee for 5 days along with pain in bilateral ankle for 3 days with no history of fever or other symptom. On examination, he was febrile with a temperature of 101 degree Fahrenheit with the skin overlying the knees being normal without any local rise of temperature. He, however, had pain on movement of the left knee. CBC was normal but ESR was raised to 58mm and CRP was positive. X-Ray revealed no obvious bony involvement. Ultrasound of the left knee revealed heterogenous , hypochoic collection suggestive of abscess but there was no collection in bilateral ankle joints. Synovial fluid aspiration was done and clear fluid aspirated. But the patient developed high grade fever with worsening total leucocyte counts and rising ESR and CRP. An urgent ultrasound of the knee revealed fluid collection along with a venous doppler suggestive of popliteal vein thrombosis . The patient was urgently taken for knee arthrotomy and the joint fluid was sent for pus culture/sensitivity, gram stain, AFB stain, Gene Xpert, cytology and microscopy. The patient was started on injection Vancomycin , injection Levofloxacin and injection Enoxaparin. The synovial fluid was turbid with analysis showing the WBC count of 30,000/ cumm and polymorphs 93% with culture revealing Staphylococcus aureus growth. Antibiotics were modified as per sensitivity reports and patient's clinical status gradually improved over a month. Blood culture report also suggested MRSA growth. Gene Xpert was negative and all other synovial fluid reports were inconclusive. Evaluation for JRA was done which was also negative. Patient improved gradually and on discharge, his joints movements were painless.

3. DISCUSSION

Systemic or localized infection are an independent risk factor for deep vein thrombosis, pulmonary thromboembolism and cardiovascular events which increase the risk by upto 2-20 percent.[7]

Acute infections have been reported to be associated with a higher risk for DVT in both hospitalized and non-hospitalized patients[8] [9]. A study by Schmidt et al[10] found infections to increase VTE risk by 4.2 times while Grimnes et al[11] concluded infections to be an important trigger for DVT with subsequent immobilization having a synergistic effect. Cohoon et al[12] in their case control study suggested infection and infection site were independently associated with VTE wherein the magnitude of risk was maximum with Intra abdominal infections followed by oral infection, systemic bloodstream infection, lower respiratory infection and systemic Urinary tract infection.

In Case 1, our patient had no overt symptom suggestive of TB. He was worked up for all possible prothrombotic states but it was the CT Chest findings and later pleural fluid analysis that pointed to the primary pathology of TB.

Tuberculosis (TB) remains commonly encountered in Indian hospital settings but it has a rare association with DVT[13] [14]. In a meta-analysis of 9 studies including over 16000 patients with active tuberculosis, the prevalence of VTE was found to be 3.5% and that of DVT 1.3%, both higher as compared to general population[15]. Rarer still is for DVT to be the primary presenting feature of tubercular infection [16] [17], as in our case.

Three elements of the Virchow's Triad represent the cornerstones of thrombosis and thrombo-embolism pathophysiology - stasis, endothelial lesions, and hypercoagulability[18]. Active TB has been thought to contribute to this pathophysiology via different mechanisms.

Tubercular enlargement of lymph nodes can lead to compression of venous system and stasis. TB induced chronic inflammation disturbs the coagulation cascade and may lead to endothelial lesions. In a prospective study by Kager et al[19] demonstrated that pulmonary Tuberculosis leads to a net procoagulant state with raised thrombin-antithrombin complexes, reduced activity of antithrombin and protein C . During pro inflammatory conditions endothelium becomes activated which results in attraction of leukocytes and thrombus formation. Von willebrand factor , secreted by endothelial cells is an acute phase protein that binds platelets and clotting factors.

A study by NW White[20] reveals Deep Vein Thrombosis has been associated with Tuberculosis in 1.5-3.4% of cases. Mean age of prevalence being 45 years. TB as in our case above, may therefore present as a thrombotic event even before any other systemic features appear. This important aspect must be borne in minds by clinicians and a workup for possible tubercular infection must be done in cases of unexplained DVT.

In Case 2 an uncommon presentation of a young female with an underlying undiagnosed C.difficile infection where the thrombotic manifestations preceded any gastrointestinal clinical feature. Our case above highlights that C. difficile infection may present primarily as an extensive thrombotic disease and this rare presentation must not be missed . A thorough investigation is imperative in such cases of of unprovoked DVT.

The incidence of Clostridium difficile is increasing. C. difficile has also been shown in studies to be associated with an increased rate of DVT[21]. A study by Barmparas et al[22] found more than 23% of C. difficile positive patients to have VTE, significantly higher compared with the 11% in those without the infection.

CDI related sepsis leads to the activation of inflammasome complex, role of which has been widely studied in "immune-thrombosis". This further leads to alteration in the balance between pro -thrombotic and anti-thrombotic factors , thus favouring thrombus formation, whereas thrombus can amplify the inflammatory response. [23]

In a pilot study by Mihaila RG et al[24] showed increased production of Thrombin generation in Clostridium difficile infections with high mean velocity index of production and peak thrombin levels. These factors may predispose a patient to a hypercoaguable state increasing the risk of VTE and complications.

Case 3 above reflects the unexpected finding of popliteal vein thrombosis in a child with staphylococcal septicaemia and arthritis. DVT following staphylococcal septicemia is rare in children and may be fatal. The process has been reported to usually begin in veins of calf around valve cusps or within soleal plexus, possibly due to release of various exotoxins and alpha-toxins that act on cell membranes and produce aggregation of platelets and spasm of smooth muscle. Though rare, there are case reports published with such presentations [25] [26].

Though sepsis overall has been shown to increase the risk[9], studies have found a more pronounced association of gram positive bacterial infections, including Staphylococcus, with DVT^[27]. Pediatric DVT associated with Staphylococcal infections have previously been reported. Staphylococcus aureus surface proteins and exotoxins can contribute to thrombus formation through effects on coagulation pathway and on anticoagulation factors. Exotoxins of Staph aureus like Pantone Valentine Toxin can cause leukocyte lysis and further endothelial injury and platelet aggregation. These events can cause microthrombus and deep vein thrombosis. [28]

4. CONCLUSION

Infections causing a systemic inflammatory response does play a causal role in formation of thrombus and it's associated further risk. The immune response to infection and coagulation system reciprocally regulate one another to formulate an effective response to injury and pathogen invasion but if unregulated it can lead to pathological thrombus and organ damage.

Infections leading to an overall prothrombotic state and predisposing to DVT and VTE increasing infection related morbidity and mortality.

In this case series special emphasis has been put on a relatively younger population presenting to the hospital setting with Primary provoked DVT with no evidence of a specific infection at the onset. Besides other risk factors both congenital and acquired, in a patient presenting as DVT possible infections as an etiological factor should be ruled out. Increased co-morbidities, increased predisposition to infections make it a valuable stressor for development of VTE.

CONSENT

All authors declare that 'written informed consent' was obtained from the patients for publication of this case series and accompanying images. A copy of the written consent is available for review by the Editorial office/Chief Editor/Editorial Board members of this journal.

REFERENCES

1. Olaf M, Cooney R. Deep venous thrombosis. *Emergency Medicine Clinics*. 2017 Nov 1;35(4):743-70.
2. Tagalakis V, Patenaude V, Kahn SR, Suissa S. Incidence of and mortality from venous thromboembolism in a real-world population: the Q-VTE Study Cohort. *The American journal of medicine*. 2013 Sep 1;126(9):832-e13.
3. Bevis PM, Smith FC. Deep vein thrombosis. *Surgery (Oxford)*. 2016 Apr 1;34(4):159-64.
4. Borgel D, Bianchini E, Lasne D, Pascreau T, Saller F (December 2019). "Inflammation in deep vein thrombosis: a therapeutic target?". *Hematology*.
5. Beristain-Covarrubias N, Perez-Toledo M, Thomas MR, Henderson IR, Watson SP, Cunningham AF. Understanding Infection-Induced Thrombosis: Lessons Learned From Animal Models. *Front Immunol*. 2019;10:2569. Published 2019 Nov 5.
6. Kaplan D, Casper TC, Elliott CG, Men S, Pendleton RC, Kraiss LW, Weyrich AS, Grissom CK, Zimmerman GA, Rondina MT. VTE Incidence and Risk Factors in Patients With Severe Sepsis and Septic Shock. *Chest*. 2015 Nov;148(5):1224-1230. doi: 10.1378/chest.15-0287. PMID: 26111103; PMCID: PMC4631038.
7. Smeeth L, Cook C, Thomas S, Hall AJ, Hubbard R, Vallance P. Risk of deep vein thrombosis and pulmonary embolism after acute infection in a community setting. *The Lancet*. 2006 Apr 1;367(9516):1075-9.
8. Tichelaar YV, Kluin-Nelemans HJ, Meijer K. Infections and inflammatory diseases as risk factors for venous thrombosis. *Thrombosis and haemostasis*. 2012;107(05):827-37.
9. Kaplan D, Casper TC, Elliott CG, Men S, Pendleton RC, Kraiss LW, Weyrich AS, Grissom CK, Zimmerman GA, Rondina MT. VTE incidence and risk factors in patients with severe sepsis and septic shock. *Chest*. 2015 Nov 1;148(5):1224-30.
10. Schmidt M, Horvath P, Puho E, Thomsen RW, Smeeth L, Sørensen HT. Acute infections and venous thromboembolism. *Journal of internal medicine*. 2012 Jun;271(6):608-18.
11. Grimnes G, Isaksen T, Tichelaar YV, Brækkan SK, Hansen JB. Acute infection as a trigger for incident venous thromboembolism: results from a population based case crossover study. *Research and practice in thrombosis and haemostasis*. 2018 Jan;2(1):85-92.
12. Cohoon KP, Ashrani AA, Crusan DJ, Petterson TM, Bailey KR, Heit JA. Is Infection an Independent Risk Factor for Venous Thromboembolism? A Population-Based, Case-Control Study. *Am J Med*. 2018;131(3):307-316.e2.
13. Muley P, Shah U, Shah V, Gandhi D. Deep vein thrombosis with tuberculosis: a rare presentation of common.
14. Hariz A, Guerhazi M, Hamdi MS, Boukhris I. Deep vein thrombosis of the left arm revealing an asymptomatic pulmonary tuberculosis. *BMJ Case Reports CP*. 2019 Jun 1;12(6):e229484.
15. Danwang C, Bigna JJ, Awana AP, Nzalio RN, Robert A. Global epidemiology of venous thromboembolism in people with active tuberculosis: A systematic review and meta-analysis. *Journal of thrombosis and thrombolysis*. 2021 Feb;51:502-12.

16. Robson SC, White NW, Aronson I, Woollgar R, Goodman H, Jacobs P. Acute phase response and the hypercoagulable state in pulmonary tuberculosis. *British journal of haematology*. 1996 Jun;93(4):943-9.
17. Kouismi H, Laine M, Bourkadi JE, Iraqi G. Association of deep venous thrombosis with pulmonary tuberculosis. *Egyptian Journal of Chest Diseases and Tuberculosis*. 2013 Jul 1;62(3):541-3.
18. Naithani R, Agrawal N, Choudhary VP. Deep venous thrombosis associated with tuberculosis. *Blood coagulation & fibrinolysis*. 2007 Jun 1;18(4):377-80.
19. Kager LM, Blok DC, Lede IO, Rahman W, Afroz R, Bresser P et al. : Pulmonary tuberculosis induces a systemic hypercoagulable state. *J Infect*. 2015 Apr;70(4):324-34.
20. White NW. Venous thrombosis and rifampicin. *Lancet*. 1989 Aug 19;2(8660):434-5. doi: 10.1016/s0140-6736(89)90603-x. PMID: 2569610.
21. Jhaveri K, Som A, Padala SA, Surani S. The Impact of Clostridium Difficile Infections on In-Hospital Outcomes of Venous Thromboembolism (Deep Vein Thrombosis or Pulmonary Embolism) Hospitalizations. *Cureus*. 2020 Jul 15;12(7).
22. Barmparas G, Fierro N, Lamb AW, Lee D, Nguyen B, Tran DH, Chung R, Ley EJ. Clostridium difficile increases the risk for venous thromboembolism. *The American journal of surgery*. 2014 Nov 1;208(5):703-9.
23. Mattana M, Tomasello R, Cammarata C, Di Carlo P, Fasciana T, Giordano G, et al. Clostridium difficile Induced Inflammation Activation and Coagulation Derangements. *Microorganisms [Internet]* 2022;10(8):1624.
24. Romeo G, Mihăilă, Crina Cătană, Ariela L. Olteanu, Victoria Bîrluțiu, Cosmin Sălcudean & Marius D. Mihăilă (2019) Thrombin generation is increased in patients with Clostridium difficile colitis – a pilot study, *Biomarkers*, 24:4, 389-393,
25. Prasad R, Mishra OP, Pant P. Deep vein thrombosis with Staphylococcus aureus septicemia. *Indian Pediatrics*. 2007 Jan 1;44(1):43.
26. Gorenstein A, Gross E, Houry S, Gewirts G, Katz S. The pivotal role of deep vein thrombophlebitis in the development of acute disseminated staphylococcal disease in children. *Pediatrics*. 2000 Dec 1;106(6):e87-.
27. Joshi MC, Baronia AK, Singh RK, Poddar B. Staphylococcal sepsis presenting as pulmonary embolism. *The Indian Journal of Pediatrics*. 2010 Jul;77:801-2.
27. Martin E, Cevik C, Nugent K. The role of hypervirulent Staphylococcus aureus infections in the development of deep vein thrombosis. *Thromb Res*. 2012 Sep;130(3):302-8.