

Case study

Fungal prosthetic valve endocarditis: case report

Abstract

Introduction:

Fungal prosthetic valve endocarditis is an extremely severe form of infective endocarditis, with poor prognosis and high mortality rate of about 50% [1]. To better characterize this syndrome, we present a case of fungal prosthetic valve endocarditis due to *Candida albicans* following aortic valve replacement.

Case presentation:

A 43-year-old male patient with history of aortic valve replacement, complicated with three thoracic empyema who have been drained, presented to emergency with high fever, cough, sputum and dyspnea. Transthoracic echocardiography evaluation demonstrated that the aortic prosthetic valve was dysfunctional and the leaflets were immobile with the existence of a very mobile and huge vegetation attached to this one measuring 22×12mm. The first blood cultures were all negative and the patient was treated initially for bacterial endocarditis with no noted clinical or biological improvement. Moreover, the patient presented several complications: left kidney infarction, impaired renal function and rhythmic complications (VT). On the 17th day of hospitalization, a fungal pathogen type *Candida Albicans* was isolated from a culture of the patient's blood. Fluconazole was given intravenously for about 2 weeks. Since fever continued, CRP remained elevated and no reduction in the size of vegetation was observed, a surgical intervention was planned. The vegetation was removed and replacement of the aortic valve by a new mechanical prosthetic valve was performed. 24 hours after the surgery, patient died of a sepsis.

Conclusion:

Fungal prosthetic valve endocarditis is rare, but fatal. The diagnosis and management are challenging. Any patient who fails to respond to antifungal agents should be referred to cardiac surgery. Some of these patients may require radical debridement and/or valve replacement. However, even with surgical treatment, survival rates are low.

Introduction:

Fungal infective endocarditis (IE) is a very rare disease, touching only 2% of IE cases and can be a source of high mortality rates up to 33%–47% [2,3]. The poor prognosis of fungal IE is associated with some specific situations: prosthetic valve implantation, cardiac implantation devices, and injection drug use (IDU).

Fungal prosthetic valve IE is an extremely severe form of infective endocarditis, with high mortality rate of about 50%. [1]

Establishment of the diagnosis is very challenging. The clinical features can be very similar to those of bacterial infections: prolonged fever, dyspnea, neurological symptoms, abdominal symptoms, cutaneous manifestations, signs of peripheral embolization [4]. However, the presence of prosthesis signs of mutilation with large vegetations and important regurgitation can lead to diagnosis of fungal endocarditis. In some extreme cases, the diagnosis can only be in postmortem findings in anatomical pathology autopsies [5].

The most common etiologic fungal agents are *Candida*, *Aspergillus* and *Histoplasma*, affecting particularly patients with suppressed immunity system disease [6]. And the probability of fungal infection touching prosthetic valves is higher than for native valves.

To better characterize this syndrome, we present a case of fungal prosthetic valve endocarditis due to *Candida albicans* following aortic valve replacement.

Case report:

A 43-year-old male patient with history of aortic valve replacement by mechanical prosthesis (bi-leaflets St. Jude mechanical valve) in February 2019 treated previously for rheumatic severe aortic regurgitation, complicated with three thoracic empyema who have been drained. After discharge, he took 2 mg per day of Acenocoumarol with INR target at 2.5 (2-3), Spironolactone 50 mg per day, Furosemide 40 mg per day. INR values were within the normal range in the 6 months previous to the admission. The patient had no history of IDU, not treated with immunosuppressive drugs or had a suppressed immunity system disease.

He presented to the hospital with high fever of 39°C, cough, sputum and dyspnea starting two weeks before the admission. After initial examinations, recurrence of thoracic empyema was the first diagnosis suspected, a chest CT (computed tomography) scan was done in the emergency room that showed no signs of empyema.

The patient was referred afterwards to the department of cardiology with a suspicion of IE. He presented respiratory symptoms including dyspnea, cough and mild abundance hemoptysis and other general symptoms as fatigue, night sweats and chills.

Physical examination found a febrile patient at 38.2°C, low systolic blood pressure at 95/60 mmHg, tachypnea at 26 cycles per minute. Changing heart murmur. Neurological and skin examination were normal. No portal of entry was identified in the ENT (ear, nose, throat), oral, abdominal, articular examination. No physical signs of heart failure were identified.

Complete blood count (CBC) showed hemoglobin level of 12.6 g/dL, WBC count of 17000 cells/L, C-reactive protein (CRP) of 135 mg/Dl, cytobacteriological examination of urine was negative. Renal function was initially normal with eGFR (estimated glomerular filtration rate) = 103 ml/mn/1.73m² using the MDRD (Modification of Diet in Renal Disease) formula. Serology for Hepatitis B and C, HIV (human immunodeficiency virus) and syphilis were negative.

Chest X ray showed a reticular shadowing of the lung peripheries prominent towards the lung right base suggesting a right basal fibrosis (pulmonary empyema sequel). (figure1)

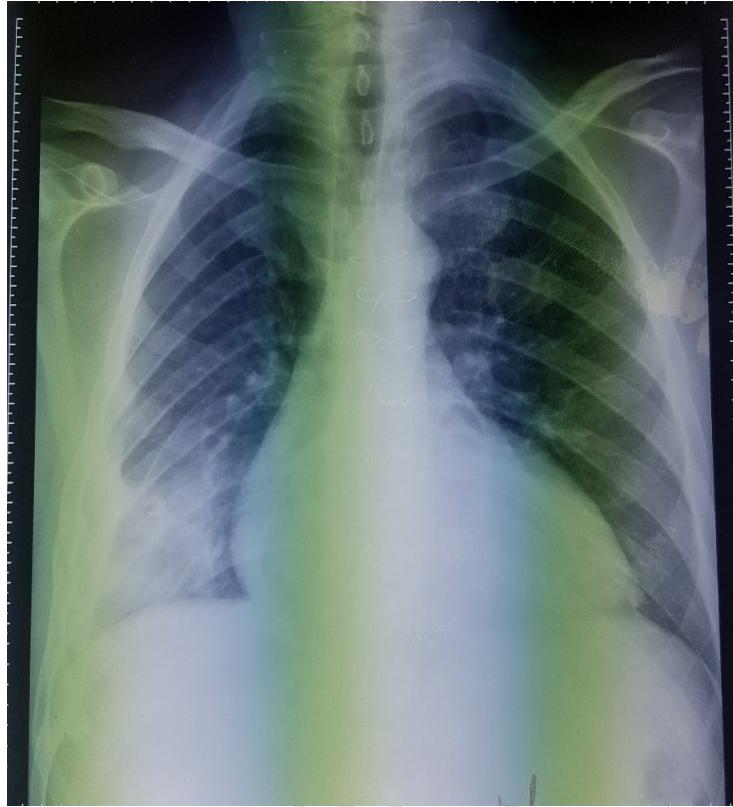


Figure 1: Chest X ray showing right basal fibrosis

Transthoracic echocardiography (TTE) evaluation revealed an aortic prosthetic valve dysfunction: With a pressure gradient of 23 mmHg through the aortic valve prosthesis, severe aortic regurgitation, left ventricular dilatation, and dysfunction with LVEF (left ventricle ejection fraction) of 35% (figure 2). In the TEE, both leaflets movement of the aortic prosthetic valve was restricted and stuck, with the existence of a very mobile vegetation attached to this one measuring 10×11mm between LV (left ventricle) and aorta. The right cavities were normal, and systolic pulmonary artery pressure was not elevated for the age of 29 mmHg.

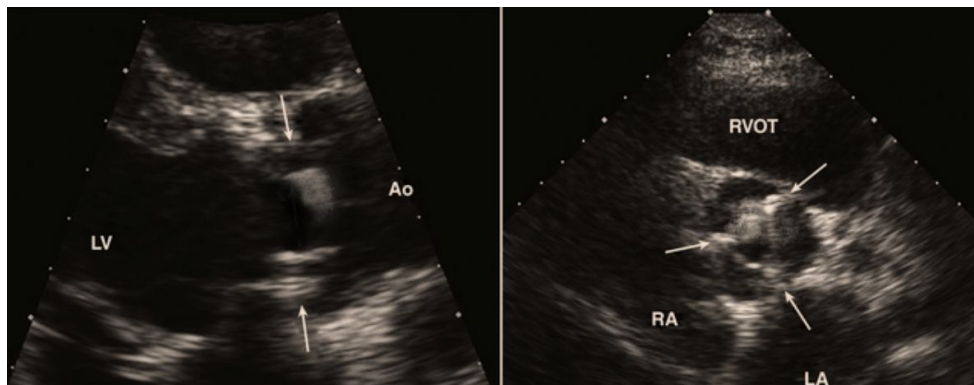


Figure 2: parasternal long and short axis showing the image of vegetation of the aortic mechanical valve

The first blood cultures were all negative and the patient was treated initially for bacterial endocarditis with IV third generation cephalosporin 2g/day for a total of 20 days + gentamicin 3 mg/kg/day for a total of 15 days. Acenocoumarol was not interrupted until surgery.

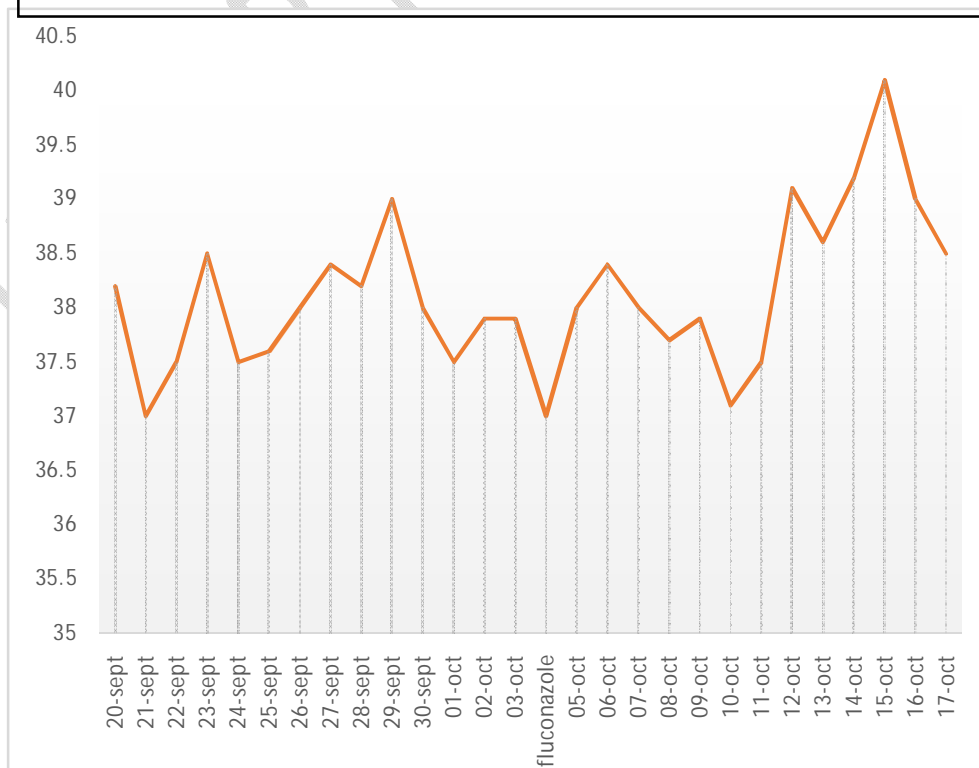
On the 5th day of hospitalization, the patient suffered from an acute abdominal pain radiating to the back, diarrhea, and vomiting. Physical examination revealed a diffuse abdominal tenderness, but no rebound tenderness or guarding. Urine analysis was unremarkable except for 1+ glucose. In the Abdominal CT, a 10 mm focal area of infarction was noted in the left kidney. No evidence of ischemic bowel or perforation was noted.

One week later, he presented palpitations and presyncope concomitant to a febrile peak of 41°C. He was found to be in sustained monomorphic VT at a rate of 200 beats per minutes and was hemodynamically compromised with hypotension. The VT was successfully treated with direct current cardioversion, with a return to normal sinus rhythm. Amiodarone was administrated 200mg, 2 times per day to maintain a sinus rhythm, but stopped 10 days later because of QT prolongation.

On the 17th day of hospitalization, a fungal pathogen type Candida Albicans was isolated from a culture of the patient's blood. Fluconazole 20 mg/kg was administrated intravenously for about 2 weeks.

Control TTE showed a volume increasing of the vegetation, measuring 22x12 mm very mobile with high embolic risk and increased transprosthetic aortic valve gradient of 25 mmHg. And Since fever continued (figure 3), CRP remained elevated (figure 4) and no reduction in the size of

Figure 3: Evolution of temperature during hospitalization



the vegetation was observed, an urgent surgical intervention was done. The vegetation was removed and replacement of the aortic valve by a new mechanical prosthetic valve was performed. During the postoperative period, the patient was hemodynamically unstable and couldn't be extubated. 24 hours

later, the patient died of a sepsis.

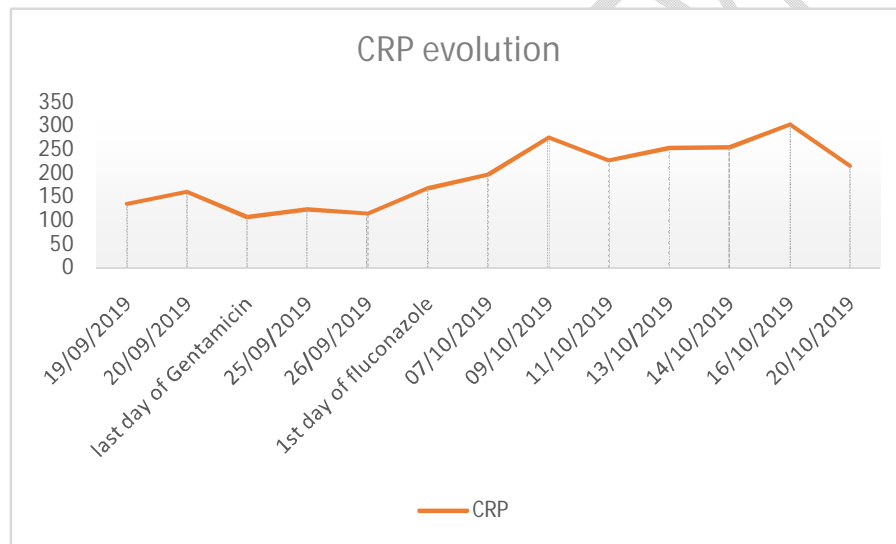


Figure 4: Evolution of C-reactive protein (CRP) during hospitalization

Discussion:

Fungal endocarditis (FE) is one of the less common forms of Infective endocarditis (IE) representing 1 to 10% of IE with increasing incidence each year [7]. It is indeed a rare affection, however it is the most severe form of IE, correlated with an extremely high mortality rate up to 50% [1].

The risk factors for fungal endocarditis include: Intravenous drug use, recent open heart surgery, prosthetic valves, Cardiac implantable electronic device, central venous catheter, history of congenital heart disease, immunosuppression, previous bacterial endocarditis [8].

Prosthetic valve is the most frequent risk factor for development of fungal endocarditis. That was the case of our immunocompetent patient who underwent an aortic valve replacement by mechanical bi-leaflets St. Jude prosthetic valve 7 months prior to the admission.

It is admitted that fungal endocarditis is an early complication of cardiac surgery, occurring within the first six months. However, it can take place at any time in patient with risk factors like for our case.

Candida albicans is the most frequent fungi, causing 24 to 46% of fungal endocarditis (FE) cases [4] and 3.4% of prosthetic valve endocarditis cases in particular, followed by *Aspergillus* species, representing approximately 25% of all cases of FE prosthesis [3]. *Candida Albicans* is commonly found in population using intravenous drugs [9]. In our case, *Candida Albicans* was isolated, even if the patient was not an intravenous drug abuser. Whereas *Aspergillus* species were mostly found in patients who had a history of recent heart surgery like valve replacement or congenital heart cure. For that reason, it can be considered as a nosocomial infection contracted during surgery [10].

The most common symptom associated with fungal endocarditis is prolonged fever (more than 2 weeks) associated with chills, night sweats and important fatigue. Respiratory symptoms as dyspnea can be explained by left heart failure or acute pulmonary embolism (PE) complicating a prosthetic fungal endocarditis. In our case, the patient presented with dyspnea with no other signs of heart failure or pulmonary embolism, it was probably associated with the severe aortic regurgitation. Furthermore, he presented also with mild abundance hemoptysis that can only be related to pulmonary fibrosis due to previous thoracic empyema, since there were no clinical or radiological evidence of pulmonary edema or PE. However, these clinical manifestations are not specific to fungal endocarditis and can be similar to bacterial endocarditis, which make the diagnosis extremely hard, leading to delayed or missed diagnosis and can impact directly a patient's chances of recovery.

Blood culture for *Candida Albicans* are positive only in 50% [1]. *Aspergillus* species are not usually detected by blood cultures [11]. Besides, blood cultures may take a lot of time (weeks or months sometimes) to identify the species, for that reason, new fast and uncomplicated methods are developed to detect fungemia: including Mannan antigen; is a component of the *Candida Albicans* cell wall that circulate during infection. They can detect a candidemia with sensitivity of 83% and specificity of 86%. [12,13] Another *Candida Albicans* cell wall polysaccharide, 1,3 b-D-glucan, has a sensitivity of 69.9% and specificity of 87.1%. [14] And finally detecting galactomannan, along with 1,3 b-D-glucan, can orient towards a FE due to *Aspergillus* species. [15] Still many review studies showed that the diagnosis in most cases was postmortem by autopsy (77%). In the described case, the processing of blood cultures took 17 days in total, causing a delay to start the appropriate treatment.

Transthoracic echocardiography (TTE) is one of the key diagnostic tools. It detects large left sided vegetations in most cases, and occasionally non-valvular one. it can also detect abscesses with a sensitivity of 77% for prosthetic valves [11]. However, trans-esophageal echocardiography (TOE) remain a better tool with high sensitivity and specificity for the diagnosis of endocarditis. A vegetation was detected by TTE on the aortic prosthetic valve in our case, but, it was hard to conclude to a fungal endocarditis only by TTE, and the patient was treated as a bacterial endocarditis. Blood culture and the increasing of the vegetation dimensions despite a bi-antibiotherapy for more than 2 weeks were the confirming tools to a fungal endocarditis.

Prognosis of fungal endocarditis is fatal compared to other types of endocarditis, and this is mainly due to lethal complications like embolic events. Peripheral embolization might occur in different sites such as cerebral, renal, pulmonary, splenic, lower extremities and gastrointestinal tract [16]. The aortic localization of vegetations can increase the risk of embolization, that was the case of our patient who presented an embolic event in the 5th day: left renal infarct with no indication of surgery.

Treatment strategies of fungal endocarditis are very blurry due to lack of randomized clinical trials evaluating the efficacy of antifungal therapy. Treatment requires a multidisciplinary team including: cardiologist, cardiothoracic surgeon, microbiologist and a pharmacist. It combines antifungal agents and surgical valve replacement. Antifungal therapy for *Candida* includes Amphotericin B (or other lipid or an echinocandin at high doses [17]). The treatment of choice of *Aspergillus* infective endocarditis is Voriconazole [16]. Once control blood cultures are negative, longterm therapies, sometimes for life, are based on oral azoles (fluconazole for *Candida* and oriconazole for *Aspergillus*). Antifungal therapy must be long enough and sufficient to eradicate microorganisms completely. Surgical replacement of the infected prosthetic valve should be a class IC by European society of cardiology (ESC) in patients with fungal endocarditis, concomitant to anti-fungal medication. Treatment should be started early and should be aggressive to avoid complications and therefore reduce the risk of mortality.

This case highlights the importance of early detection of fungemia in patients who underwent a valve replacement and keeping fungal endocarditis as a possible diagnosis for febrile patients presenting risk factors of FE. Antifungal therapy should start without delay in these patients to avoid complications as peripheral embolization of the lower extremities, brain, and intra-abdominal organs. Comorbidities prior to the diagnosis are often a cause of a worse prognosis.

Conclusion:

Fungal prosthetic valve endocarditis is rare, but fatal with very high mortality rate. The diagnosis and management are challenging because of the lack of prospective randomized trials. FE should be suspected when a patient present risk factors of fungemia such as history of open heart surgery, immunodepression and drug abuse. The treatment should be started without delay. Medical treatment includes antifungal agents such Amphotericin B, Voriconazole and fluconazole. Any patient who fails to respond to antifungal agents should be referred to cardiac surgery. Some of these patients may require radical debridement and/or valve replacement. However, even with surgical treatment, survival rates remain very low due to complications.

References:

1. Badiie P, Amirghofran AA, Ghazi Nour M, Shafa M, Nemati MH. Incidence and outcome of documented fungal endocarditis. *Int Cardiovasc Res J.* 2014;8(4):152–155.
2. Baddley JW, Benjamin DK Jr, Patel M, et al.; International Collaboration on Endocarditis-Prospective Cohort Study Group (ICE-PCS). *Candida* infective endocarditis. *Eur J Clin Microbiol Infect Dis* 2008; 27:519–29.
3. Falcone M, Barzaghi N, Carosi G, et al.; Italian Study on Endocarditis. *Candida* infective endocarditis: report of 15 cases from a prospective multicenter study. *Medicine (Baltimore)* 2009; 88:160–8.
4. Ellis M. Fungal endocarditis. *J Infect.* 1997 Sep;35(2):99-103.
5. Seelig MS, Speth CP, Kozinn PJ, Taschdjian CL, Toni EF, Goldberg P. Patterns of *Candida* endocarditis following cardiac surgery: Importance of early diagnosis and therapy (an analysis of 91 cases) *Prog Cardiovasc Dis.* 1974;17(2):125–160.
6. Muehrcke DD. Fungal prosthetic valve endocarditis. *Semin Thorac Cardiovasc Surg* 1995; 7: 20–4.
7. Gordon SM, Keys TF. Bloodstream infections in patients with implanted prosthetic cardiac valves. *Semin Thorac Cardiovasc Surg.* 1995;7(1):2-6.
8. Simon MS, Somersan S, Singh HK, Hartman B, Wickes BL, Jenkins SG, et al. Endocarditis caused by *Rhodotorula* infection. *J Clin Microbiol.* 2014;52(1):374–378.*
9. Kami M, Fukui T, Ogawa S, Kazuyama Y, Machida U, Tanaka Y, et al. Use of real-time PCR on blood samples for diagnosis of invasive aspergillosis. *Clin Infect Dis.* 2001;33(9):1504-12.
10. Gordon SM, Keys TF. Bloodstream infections in patients with implanted prosthetic cardiac valves. *Semin Thorac Cardiovasc Surg.* 1995;7(1):2-6.
11. Pierrotti LC, Baddour LM. Fungal endocarditis, 1995-2000. *Chest.* 2002 Jul;122(1):302-10.
12. Klis FM. Review: cell wall assembly in yeast. *Yeast.* 1994;10:851–869. doi: 10.1002/yea.320100702.
13. Mikulska M, Calandra T, Sanguinetti M, Poulain D, Viscoli C., Third European Conference on Infections in Leukemia Group. The use of mannan antigen and anti-mannan antibodies in the diagnosis of invasive candidiasis: recommendations from the Third European Conference on Infections in Leukemia. *Crit Care.* 2010;14(6):R222.
14. Varghese GM, Sobel JD. Fungal endocarditis. *Curr Infect Dis Rep.* 2008 Jul;10(4):275-9.
15. Maertens JA, Klont R, Masson C, Theunissen K, Meersseman W, Lagrou K, Heinen C, Crépin B, Van Eldere J, Tabouret M, Donnelly JP, Verweij PE. Optimization of the cutoff value for the *Aspergillus* double-sandwich enzyme immunoassay. *Clin Infect Dis.* 2007 May 15;44(10):1329-36.
16. Denning DW, Stevens DA. Antifungal and surgical treatment of invasive aspergillosis: review of 2,121 published cases. *Rev Infect Dis.* 1990;12(6):1147–1201.
17. Pappas PG, Kauffman CA, Andes DR, Clancy CJ, Marr KA, Ostrosky-Zeichner L, Reboli AC, Schuster MG, Vazquez JA, Walsh TJ, Zaoutis TE, Sobel JD. Clinical Practice Guideline for the Management of Candidiasis: 2016 Update by the Infectious Diseases Society of America. *Clin Infect Dis.* 2016 Feb 15;62(4):e1-50.