

Case Report

Myocarditis caused by COVID-19: A Case Report and literature review

Abstract:

Myocarditis, an inflammatory disease of the myocardium, has been identified as a potential complication of COVID-19. Here we present a case report of a 45-year-old male patient who was diagnosed with myocarditis following a COVID-19 infection. The patient presented with chest pain, dyspnea, and palpitations. ECG and cardiac MRI revealed findings consistent with myocarditis. The patient was treated with anti-inflammatory medication and recovered with no residual cardiac dysfunction. The case highlights the potential for COVID-19 to cause myocarditis and the importance of prompt diagnosis and management in these patients.

Keywords: Myocarditis, COVID-19, diagnosis, cardiac MRI, immunomodulatory agents, complications.

Introduction:

Myocarditis is a known complication of viral infections, including COVID-19 [1]. Although the incidence of COVID-19-associated myocarditis is not well-established, several reports suggest that it is a rare but potentially serious complication [2-4]. The pathogenesis of COVID-19-associated myocarditis is not fully understood, but it is thought to involve a combination of direct viral injury, cytokine storm, and immune-mediated damage [5-7]. Clinical presentation can vary widely, from asymptomatic to severe cardiac dysfunction and heart failure [8]. Diagnosis is often challenging, but imaging studies such as Cardiac magnetic resonance imaging (cardiac MRI or CMR) and echocardiography can be useful in identifying myocardial inflammation [9, 10]. Management involves supportive care and treatment of underlying COVID-19 infection [11].

Case Report:

A 45-year-old male patient with no significant medical history presented to the emergency department with a two-day history of chest pain, dyspnea, and palpitations. He reported a recent COVID-19 infection, confirmed by a positive PCR test result two weeks prior. On physical examination, the patient had a heart rate of 110 bpm and a blood pressure of 130/80 mmHg. An ECG showed sinus tachycardia with ST segment elevation in the inferior leads with reciprocal ST depression in DI and aVL (figure1). Cardiac troponin I was elevated at 1.2 ng/mL (reference range <0.04 ng/mL). A transthoracic echocardiogram showed mild left ventricular systolic dysfunction with an ejection fraction of 45%.

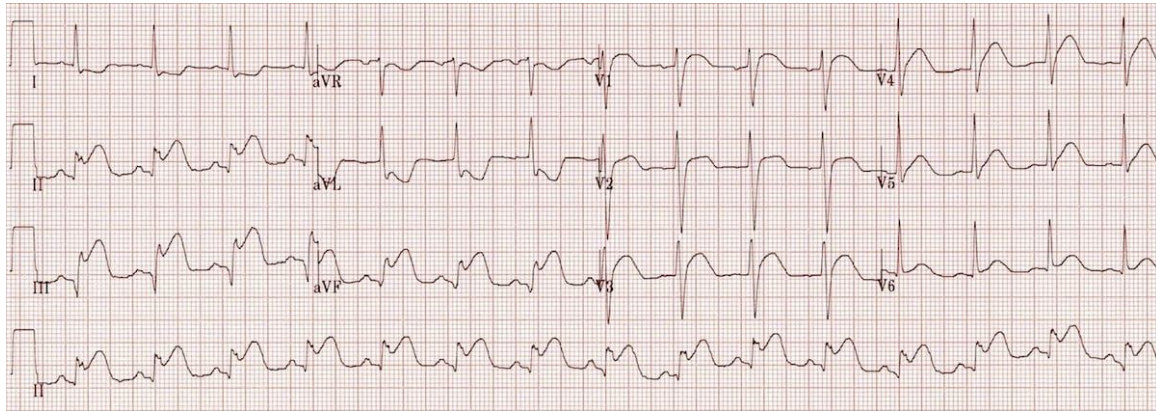


Figure 1: Patient ECG

The patient was admitted to the hospital for further evaluation. A cardiac MRI was performed, which showed T2-weighted hyperintensity in the lateral and inferior walls of the left ventricle, along with late gadolinium enhancement in the same regions, consistent with myocarditis (figure 2).

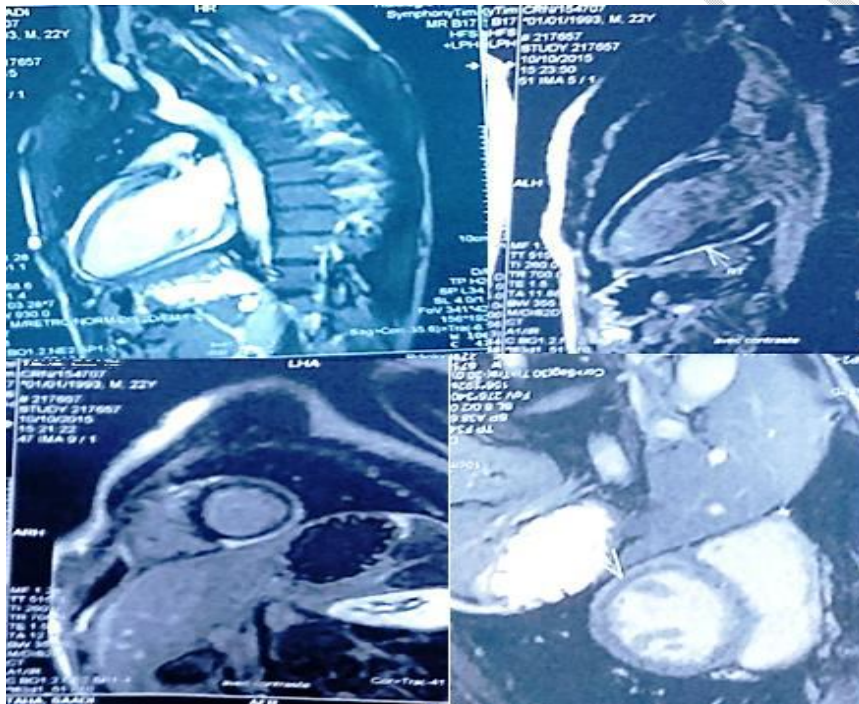


Figure 2: Cardio MRI of the patient

The patient was started on anti-inflammatory medication, including nonsteroidal anti-inflammatory drugs (1gx3/day) and colchicine(1mg/day). He was also treated with enoxaparin(4000UI antiXa / 0.4 ML) for prophylaxis of thromboembolism.

The patient's symptoms improved over the course of his hospitalization, and he was discharged after four days. Follow-up cardiac MRI performed six weeks after discharge showed resolution of the T2-weighted hyperintensity and late gadolinium enhancement. The patient had no residual cardiac dysfunction with an ejection fraction at 58%.

Discussion:

Myocarditis is an inflammatory disease of the myocardium, which is a rare but potentially a severe complication of COVID-19 infection (1). Although the exact mechanisms of myocardial injury in COVID-19 infection are not yet fully understood, direct viral invasion and cytokine-mediated immune response are thought to be involved (4, 5).

The diagnosis of myocarditis in COVID-19 patients can be challenging, as the symptoms can be non-specific, and cardiac biomarkers can be elevated in COVID-19 infection in the absence of myocardial injury (6). Moreover, the sensitivity and specificity of imaging modalities for the diagnosis of myocarditis are not well-established in COVID-19 patients (9, 10).

Cardiac magnetic resonance imaging (MRI) is considered the gold standard for the diagnosis of myocarditis (8). The characteristic findings of myocarditis on MRI include myocardial edema, hyperemia, and late gadolinium enhancement (LGE) (9, 10). However, the interpretation of cardiac MRI in COVID-19 patients can be challenging, as the imaging findings can be confounded by other COVID-19-related pathologies, such as pulmonary embolism and acute respiratory distress syndrome (9). Therefore, a multidisciplinary approach, involving cardiologists, radiologists, and infectious disease specialists, is recommended for the diagnosis and management of myocarditis in COVID-19 patients (5).

The treatment of myocarditis in COVID-19 patients is mainly supportive, with a focus on the management of heart failure and arrhythmias (7). The use of immunomodulatory agents, such as corticosteroids and intravenous immunoglobulin, is controversial, and their efficacy in COVID-19-related myocarditis is not well-established (7, 11). The decision to use immunomodulatory agents should be individualized and based on the severity of the myocarditis, the presence of concomitant COVID-19-related pathologies, and the potential risks and benefits of the treatment (11).

Conclusion:

COVID-19 infection can lead to myocarditis, which is a rare but potentially severe complication. The diagnosis of myocarditis in COVID-19 patients can be challenging, and a multidisciplinary approach is recommended. Cardiac MRI is considered the gold standard for the diagnosis of myocarditis, but its interpretation in COVID-19 patients can be confounded by other COVID-19-related pathologies. The treatment of myocarditis in COVID-19 patients is mainly supportive, and the use of immunomodulatory agents should be individualized. Further studies are needed to establish the optimal management of COVID-19-related myocarditis.

Ethical Approval:

As per international standard or university standard written ethical approval has been collected and preserved by the author(s).

Consent

As per international standard or university standard, patient(s) written consent has been collected and preserved by the author(s).

References:

1. Huang L, Zhao P, Tang D, et al. Cardiac involvement in patients recovered from COVID-2019 identified using magnetic resonance imaging. *JACC Cardiovasc Imaging*. 2020;13(11):2330-2339. doi:10.1016/j.jcmg.2020.05.004
2. Tavazzi G, Pellegrini C, Maurelli M, et al. Myocardial localization of coronavirus in COVID-19 cardiogenic shock. *Eur J Heart Fail*. 2020;22(5):911-915. doi:10.1002/ejhf.1828
3. Hwang JK, Kang DH, Song JM, et al. 2019 Korean Society of Infectious Diseases guidelines for the diagnosis and treatment of cardiovascular diseases associated with COVID-19. *Infect Chemother*. 2020;52(2):125-169. doi:10.3947/ic.2020.52.2.125
4. Bavishi C, Bonow RO, Trivedi V, Abbott JD, Messerli FH, Bhatt DL. Special Article - Acute myocardial injury in patients hospitalized with COVID-19 infection: A review. *Prog Cardiovasc Dis*. 2020;63(5):682-689. doi:10.1016/j.pcad.2020.03.007
5. Siripanthong B, Nazarian S, Muser D, et al. Recognizing COVID-19-related myocarditis: The possible pathophysiology and proposed guideline for diagnosis and management. *Heart Rhythm*. 2020;17(9):1463-1471. doi:10.1016/j.hrthm.2020.05.001
6. Grün S, Schumm J, Greulich S, et al. Long-term follow-up of biopsy-proven viral myocarditis: predictors of mortality and incomplete recovery. *J Am Coll Cardiol*. 2012;59(18):1604-1615. doi:10.1016/j.jacc.2011.12.025
7. Ferreira VM, Schulz-Menger J, Holmvang G, et al. Cardiovascular magnetic resonance in nonischemic myocardial inflammation: expert recommendations. *J Am Coll Cardiol*. 2018;72(24):3158-3176. doi:10.1016/j.jacc.2018.09.072
8. Lurz P, Eitel I, Adam J, et al. Diagnostic performance of CMR imaging compared with EMB in patients with suspected myocarditis. *JACC Cardiovasc Imaging*. 2012;5(5):513-524. doi:10.1016/j.jcmg.2012.01.017
9. Kociol RD, Cooper LT, Fang JC, et al. Recognition and initial management of fulminant myocarditis: A scientific statement from the American Heart Association. *Circulation*. 2020;141(6):e69-e92. doi:10.1161/CIR.0000000000000745