

EFFECT OF *Moringa oleifera* LEAF AQUEOUS EXTRACT ON HISTOLOGY OF LIVER AND ITS BIOCHEMICAL PARAMETERS IN HEIGHER FAT DIETS INDUCED OBESITY IN WISTAR RATS

ABSTRACT

Introduction: Obesity has emerged as a major health problem and risk factor for various disorders worldwide. Obesity has been defined as abnormal or excessive fat accumulation triggered by disproportion in energy intake than expenditure. Obesity is a non-communicable medical disorder that has largely been accepted as a reflection of healthy living and affluence among Nigerians. It is usually defined as body mass index (BMI) ≥ 30 kg/m².

Aim: The aim of this study was to determine the histopathological and biochemical effect of *Moringa olerifera* aqueous leaf extract on obesity induced albino rat.

Methodology: A total number of 25 healthy albino rats were used. The group 1 served as negative control group consisting of 5 rats including, they were given water *ad libitum* and were fed with standard rat chow for 12 weeks. The group 2 consist of 5 rats, received water *ad libitum* and were administered orally with high-fat diet in the dose of 1ml daily of mixture of melted pig fat and hydrogenated vegetable oil in 3:2 ratio respectively for 12weeks and also fed with a standard rat chow and served as obese positive control group. The group 3 also consist of 5 rats, served as standard control group in which they were fed orally with high fat diet in a dose of 1ml of mixture of melted pig fat and hydrogenated vegetable oil in 3:2 ratio for 6 weeks and were orally administered standard drug orlistat 12mg/kg body weight daily for another 6 weeks. While group 4 and group 5 have 5 rats each received water and were administered orally with melted pig fat and hydrogenated vegetable oil 1ml daily for 6 weeks and standard rat chow after 6 weeks of feeding, *moringa oleifera* aqueous leaf extract in a dose of 200mg/kgbw and 400mg/kgbw respectively, daily for another 6 weeks the dose of extract chosen were based on the result of acute toxicity (LD50) study conducted.

Result: The LD₅₀ of *M. oleifera* is more than 5000mg/kgbw as all doses below this incurred zero percentage of death among all groups of rats, shows no toxicity or mortality recorded after 24 hours all the animals in both Phase I and Phase II. The biochemical Parameters of Liver shows that there was no statistical significant difference in results of the parameters of all the groups when compared among the groups. Liver section shows hepatic fatty deposition when compared with control group. While A Group1 and B Group 4 Treated 200mg/kg shows no hepatic fatty deposition in hepatocytes and central vein. So also in A Group 1 and B Group 5 Treated 400mg/kg shows normal hepatocytes and central vein

Conclusion: This study shows that *Moringa oleifera* leaf extract possesses anti-hepatic fatty deposition properties like that of selected standard drugs. At higher acceptable dose of *Moringa oleifera* demonstrated better anti-obesity properties with the selected standard drugs. Hence, leaf extract of *Moringa. oleifera* is beneficial in the management of dietary obesity.

Key Words: *Moringa Oleifera*, Liver, Obesity and Wistar Rats

1.0 INTRODUCTION

Obesity has emerged as a major health problem and risk factor for various disorders worldwide [1]. Obesity has been defined as abnormal or excessive fat accumulation triggered by disproportion in energy intake than expenditure [2]. Obesity is a non-communicable medical disorder that has largely been accepted as a reflection of healthy living and affluence among Nigerians [3]. It is usually defined as body mass index (BMI) ≥ 30 kg/m² [3]. Obesity is a modifiable cardiovascular risk factor which predisposes to and occurs in combination with other non-communicable disease such as diabetes mellitus, hypertension, dyslipidaemia and metabolic syndrome [4]. An imbalance between energy intake and its expenditure is thought to principally lead to obesity [5]. Physical inactivity, excess caloric intake and genetic factors play significant role in aetiopathogenesis of obesity [5]. Body mass index (BMI), is the most commonly used marker for body-weight assessment and is highly correlated with body fat [6]. The medical risk of obesity is closely associated with the distribution of body fat, with abdominal fat considered at least as important a medical risk as the total amount of body fat [7]. The BMI serve as a veritable platform for evaluation of obese subjects, with predisposition to its deleterious effect increasing with its severity. Nigeria is currently witnessing both demographic and epidemiologic transitions which could be some of the possible reasons why the prevalence of non-communicable diseases is increasing. In a cross-sectional study carried out by [7]. A study conducted on 146 middle-aged Nigeria, shows that 21% and 28% males and females respectively were to be obese [9]. In Ghana and Republic of Benin, obesity was found among adults in 13.6% and 18% respectively [10, 11]. World Health Organization and other national organizations have devised strategies for chronic non-communicable disease prevention and control. The

inadequate facilities and measures to diagnose obesity and obesity-related morbidities by clinicians leads to missed opportunities to counsel these patients on lifestyle modification and screen them for obesity-related morbidities [11, 12]. *Moringa oleifera* is a fast-growing, drought-resistant tree of the family *Moringaceae*, native to tropical and subtropical regions of South Asia [13]. Common names include *moringa*, drumstick tree (from the long, slender, triangular seed-pods), horseradish tree (from the taste of the roots, which resembles horseradish), and ben oil tree or benzoil tree (from the oil which is derived from the seeds) [13].

3.0 MATERIALS AND METHOD

3.1 STUDY AREA

The study was carried out at Histopathology Laboratory of the School of Medical Laboratory Sciences, Usmanu Danfodiyo University Sokoto, Faculty of Pharmaceutical Science, Usmanu Danfodiyo University, Sokoto and Service Laboratory, Department of Histopathology of the Usmanu, Danfodiyo University, Teaching Hospital, Sokoto.

3.2 ETHICAL CONSIDERATION AND APPROVAL

The protocol of this study was approved by the Ethics and Research Committee on the use of animal for research of the Faculty of Pharmaceutical Sciences, Usmanu, Danfodiyo University Sokoto with reference number as PTAC/MO/OT/31-21.

3.3 PLANT IDENTIFICATION

The plant taxonomic identification and assigning of specimen Voucher Number was carried out at the Faculty of Pharmaceutical Sciences, Usmanu Danfodiyo University, Sokoto. The voucher specimen number was given as

PCG/UDUS/mori/0001 and deposited in the herbarium unit of the same department.

3.4 PLANT EXTRACTION

The Leaves of the *moringa oleifera* was collected at the herbarium unit of Faculty of Pharmaceutical Sciences Usmanu Danfodiyo University Sokoto, and was dried under the shade in the Histopathology Laboratory, School of Medical Laboratory Sciences to avoid heat destruction of the active component by the Sunlight. The dried material was grinded into powder using pestle and mortar. About 1000g of the grinded crude powder of *moringa* plant was weighed and dissolved in 3000ml of distilled water, the solution was stirred with the use of stirrer for two hours and left to stay over 24hours. This was filtered with fine cloth to remove large particles and debris then filtered with filter paper. The filtrate was evaporated to dryness at 40⁰C in water bath as it was done according to the method described by (Majekodunmi *et al.*, [14].

3.5 EXPERIMENTAL ANIMALS

A total of 25 healthy albino rats, weighing between 160-180g were purchased from animal house of the Faculty of Pharmaceutical Sciences, Ahmadu Bello University Zaria. They were allowed to acclimatize for a period of 14 days. They were maintained on high fat diet for induction of obesity and water added with vitamins in sufficient quantities throughout the experimental period; and kept in a metal cage in well ventilated environment at conducive temperature.

3.6 TOXICITY STUDIES (LETHAL DOSE)

The Lethal Dose (LD₅₀) was carried out using Lorke's method, in the Animal

House, Faculty of Pharmaceutical Sciences, Usmanu Danfodiyo University, Sokoto. The Lorke's method of LD₅₀ consists of two phases.

3.8 EXPERIMENTAL DESIGN AND INDUCTION OF OBESITY IN ALBINO RATS

A total number of 25 healthy albino rats were used. After the acclimatization period of two weeks, animals were divided into 5 groups with t3 rats and. The group 1 served as negative control group consisting of 5 rats, they were given water *ad libitum* and were fed with standard rat chow for 12 weeks of the experimental period. The group 2 consist of 5 rats, received water *ad libitum* and were administered orally with high-fat diet in the dose of 1ml daily of mixture of melted pig fat and hydrogenated vegetable oil in 3:2 ratio respectively for 12 weeks and also fed with a standard rat chow and served as obese positive control group [15, 16]. The group 3 also consist of 5 rats, served as standard control group in which they were fed orally with high fat diet in a dose of 1ml of mixture of melted pig fat and hydrogenated vegetable oil in 3;2 ratio for 6weeks and were orally administered standard drug orlistat 12mg/kg body weight daily [17]. for another six weeks . While group 4 and group 5 have 5 rats each including, received water and were administered orally with melted pig fat and hydrogenated vegetable oil 1ml daily for 6 weeks and standard rat chow after 6 weeks of feeding. *moringa oleifera* aqueous leaf extract in a dose of 200mg/kgbw and 400mg/kgbw respectively, daily for another 6 weeks the dose of extract chosen were based on the result of acute toxicity (LD₅₀) study conducted. The body weight and length, of the rats were recorded every week throughout the experimental period [18].

Table 1 Summary of Experimental Design and Induction of Obesity in Wistar rats

EXPERIMENTAL GROUPS	INTERVENTION GIVEN	TREATMENT GIVEN	DURATION OF TREATMENT/ INDUCTION
1(Negative control) (3 rats)	Distilled water	No treatment given	12 weeks
2 (Obese Positive control) 3 rats) and	Higher fat diet/ + normal diet	No treatment given	12 weeks
3 (standard control) (3 rats) and	Higher fat diet + normal diet	12 mg/kg of Orlistat Standard drugs for obesity for 6weeks	12 weeks
4 Test (3 rats)	Higher fat diet + normal diet	200mg/kg of <i>moringa</i> leaf extract for 6weeks	12 weeks
5 Test (3 rats)	Higher fat diet + normal diet	400mg/kg of <i>Moringa</i> leaf extract for 6weeks	12 weeks

3.9 SACRIFICE OF THE ANIMALS

After 6 weeks of the treatment period, the animals were anaesthetized using chloroform vapour in an enclosed transparent plastic jar. Blood samples were collected with aid of 5mls syringe and needle through the cardiac puncture into the plain containers for Liver biochemical analysis. The animals were then dissected by longitudinal abdominal incision with aid of surgical blade to carefully harvest the Liver washed with normal saline and then fixed immediately in 10% formal saline for histopathological investigations. The sections of the liver were stained with Haematoxylin and Eosin staining procedure.

3.10 LABORATORY ANALYSIS

The serum for Liver biochemical parameters was analyzed for the determination of Liver Enzymes: Aspartate aminotransferase (AST), alanine aminotransferase (ALT) and alkaline

phosphatase (ALP) were determined by method described by Reitman and Frankel, [19]. Determination of albumin (ALB) was carried out by the method described by Tietz, [20]. and Grant, [21]. Determination of total bilirubin and conjugated bilirubin were carried out by the method described by Aja *et al* [22]. Total protein concentration of the serum and homogenates was determined using Biuret method. Enzymes activities of serum alanine aminotransferase (ALT), aspartate aminotransferase (AST) was carried out using colorimetric method, alkaline phosphatase (ALP) was done using modified Bowers and Mc Comb Method [23]. Total protein was determined using the Biuret method of Henry *et al* [24]. The concentration of albumin was determined as described by Grant and Kacchman. [25].

Liver was processed using automatic tissue processor Machine (Leica TPO1020 Model), after which they are embedded

using Embedding Center (Leica EG1160 Model). Section of the embedded tissue blocks were cut at 3µm using Rotary Microtome (Leica RM2125RT) and then floated out on labelled glass slides, then stained with Hematoxylin and Eosin. Stained sections were examined microscopically using x10 and x40 objectives lenses. Photomicrograph of liver, sections were taken and presented alongside with control section. The photomicrographs of tissue section were taken using Light Microscope and Best Scope Camera and the results were presented alongside with control. Egbujo *et al* [26].

3.11 DATA ANALYSIS

The data analysis were performed using Graph pad prism 6.0 as mean±SD. Statistical comparison between and within the groups were made using one way analysis of variance (ANOVA) with post

hoc Bonferroni Multiple comparison Test to establish the differences in means where appropriate. P<0.05 was taken as statistically significant. The standard analysis were performed using SPSS Statistical software version 23

hoc Bonferroni Multiple comparison Test to establish the differences in means where appropriate. P<0.05 was taken as statistically significant. The standard analysis were performed using SPSS Statistical software version 23

4.0 RESULTS

Table 2: This is showing the physical properties of *moringa oleifera* leaf aqueous extract. The part of plant used was leaf, the colour of the extract was brown, texture was gummy and percentage yielded was 12.2% after extraction procedure.

The result showed that the LD₅₀ of *M oleifera* leaf aqueous extract is more than 5000mg/kgbw as all doses below this incurred zero percentage of death and no toxicity or mortality recorded after 24 hours among all groups of rats. in both Phase I and Phase II. This shows that LD₅₀ of the extract was above 5000 mg/kgbw.

showing no hepatic fatty deposition in hepatocytes (black arrow) and central vein (Green arrow). H &E x400

PLATE:3 Photomicrograph of Liver section showing regular hepatocytes (black arrow) and portatriad (Red arrow). A Group1 and B Group 4 Treated 200mg/kg showing no hepatic fatty deposition in hepatocytes (black arrow) and central vein (green arrow) H &E x400

PLATE :4 Photomicrograph of Liver section showing regular hepatocytes (black arrow) and portatriad (Red arrow). A Group 1 and B Group 5 Treated 400mg/kg showing regular hepatocytes (black arrow) and central vein (Green arrow) (H &E x400

Table 4This is showing the biochemical Parameters of Liver, shows that there was no statistical significant difference in results of the parameters of all the groups when compared within and among the groups.

PLATE 1: Photomicrograph of Liver section showing regular hepatocytes (black arrow) and portal triad (Red arrow) in A (Group 1) and B (Group 2). Showing Hepatocytes with micro and macro vesicular steatosis (White and red arrows) and central vein (Green arrow). H &E x400

Table 2: The result of physical properties of *moringa oleifera* leaf aqueous extract

Plant part	Type of extract	Colour	Texture	Percentage yield
------------	-----------------	--------	---------	------------------

Leaf	Aqueous extract	Red-brown	Gummy	12.2%
------	-----------------	-----------	-------	-------

Table 3 Showing the result LD₅₀ of the *moringa oleifera* leaf aqueous in albino rats

Dose (mg)	Observation	
	first phase	Second phase
10	0/3	-
100	0/3	-
1000	0/3	-
1600	-	0/1
2900	-	0/1
5000	-	0/1

Table 4: Biochemical Parameters of Liver Function Test

Experi- mental groups	1 control (distilled water)	2 positive control (no treatment)	3 standard control (12mg/kg olistart)	4 test (treated with 200mg/ kg of extract)	5 test (treated with 400mg/ kg of extract)
AST	5.93 ± 0.33	5.67 ± 0.88	6.33 ± 0.88	6.33 ± 1.20	6.67 ± 0.67
ALT	8.00 ± 0.58	8.33 ± 1.45	8.33 ± 0.33	8.67 ± 1.45	8.67 ± 0.67
ALP	57.00 ± 1.00	58.67 ± 2.73	61.00 ± 6.43	60.67 ± 7.31	57.33 ± 0.67
TP	59.33 ± 0.33	57.67 ± 1.85	61.00 ± 1.73	57.67 ± 2.96	63.33 ± 0.33
ALB	36.67 ± 0.67	36.67 ± 1.20	38.33 ± 1.20	37.67 ± 1.67	42.00 ± 1.53
TB	0.73 ± 0.03	0.63 ± 0.03	0.70 ± 0.06	0.73 ± 0.07	0.63 ± 0.03
DB	0.23 ± 0.03	0.17 ± 0.03	0.17 ± 0.03	0.23 ± 0.03	0.23 ± 0.03

Legend: **AST** =Aspartate aminotransferase **ALT** = Alanine aminotransferase **ALP** = Alkaline Phosphotase, **TP** = Total Proteins, **ALB** = Albumin, **TB** = Total Bilirubin and **DB** = Direct Bilirubin

No significant differences when compared across all the groups (P>0.05)

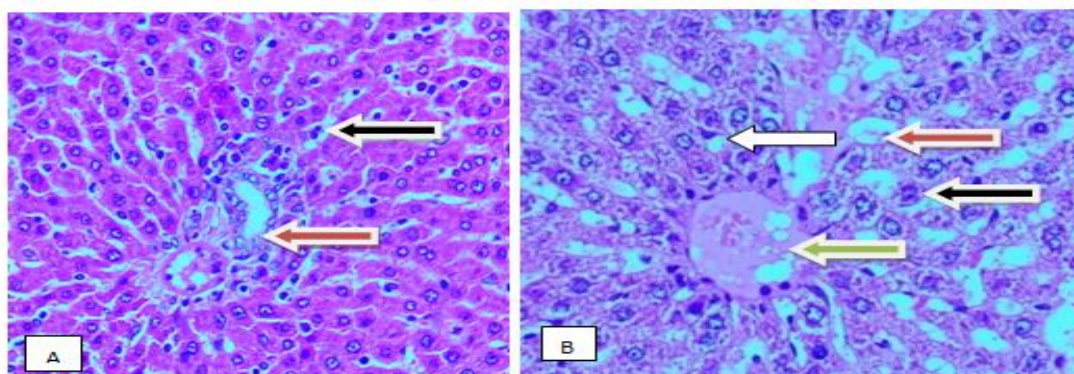


PLATE 1: Photomicrograph of Liver section showing normal hepatocytes (black arrow) and portal triad (Red arrow) in A control group (Group 1) and B positive control group (Group 2). Showing Hepatocytes with micro and macro vesicular steatosis (White and red arrows) and central vein (Green arrow). H &E x400

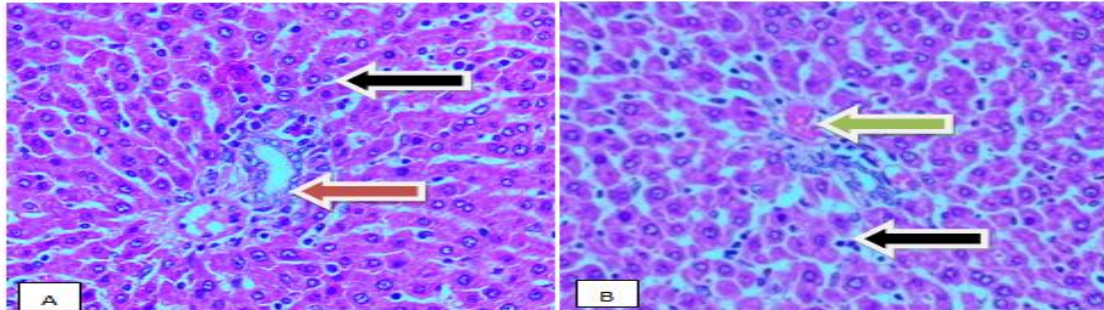


PLATE:2 Photomicrograph of Liver section showing normal hepatocytes (black arrow) and portatriad (Red arrow). Control group (A Group 1) and Stanadrd control group (B Group 3) treated with standard drug showing no hepatic fatty deposition in hepatocytes (black arrow) and central vein (Green arrow). H &E x400

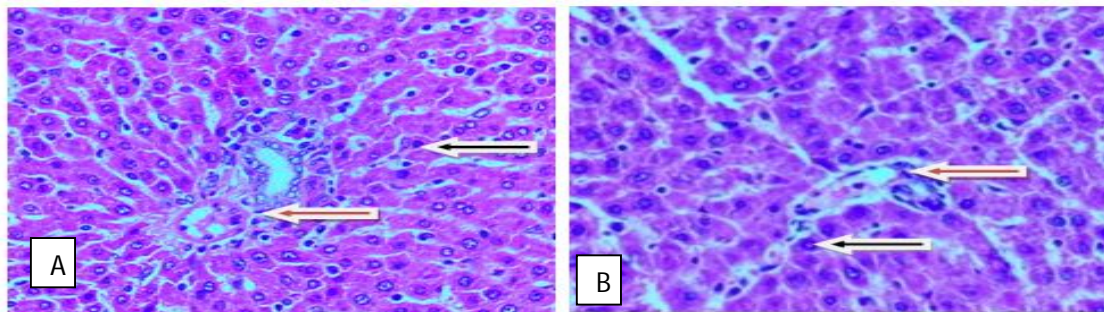


PLATE:3 Photomicrograph of Liver section showing normal hepatocytes (black arrow) and portatriad (Red arrow). Control group (A Group1) and test group (B Group 4), treated 200mg/kg showing no hepatic fatty deposition in hepatocytes (black arrow) and central vein (green arrow) H &E x400

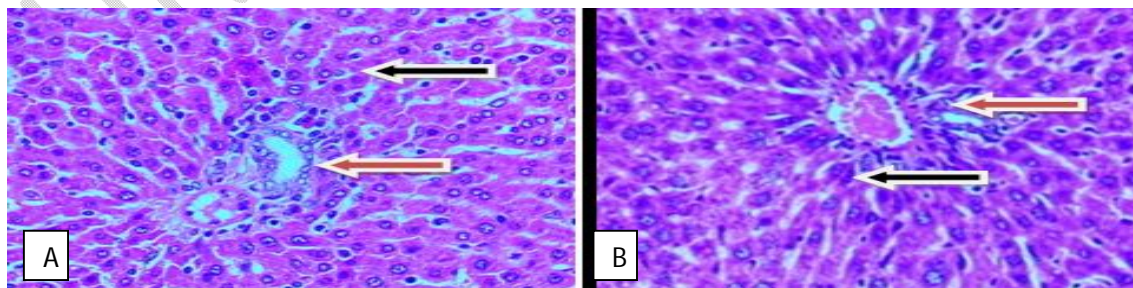


PLATE:4 Photomicrograph of Liver section showing regular normal (black arrow) and portatriad (Red arrow). Control group (A Group 1) and test group (B Group 5), treated

400mg/kg showing regular hepatocytes (black arrow) and central vein (Green arrow) (H &E x400)

5.0 DISCUSSION

Obesity epidemic continues to grow at an alarming rate. There are several promising medications currently in clinical trials that induce weight loss through several separate mechanisms. Ultimately obesity will most likely be treated with combinations of medications, similar to other chronic diseases such as heart disease, hypertension, and diabetes. A model of diet-induced obesity in rats is well controlled and shares many features with human obesity. Dietary fat is one of the most important environmental factors associated with the incidence of cardiovascular diseases; high cholesterol and saturated fat diets have been shown to promote atherosclerosis. A rodent model of obesity based on the intake of HFD is advantageous in studying obesity-related cardiovascular abnormalities. In the present study, body weight gain was higher in rats fed with HFD as compared to the normal healthy control rats.

The physical property of *moringa oleifera* leaf aqueous extract, the part of plant used was leaves, the colour of the extract was red-brown, texture was gummy and percentage yielded was 12.2% after extraction procedure. This finding agrees with research work conducted by Mehta *et al.*, [27]. This could be attributed to the fact that the same method of extraction procedure was used.

The Lorke's method of acute toxicity test (LD₅₀) procedure, after administration orally it was observed for 24hours no toxicity manifestations or mortality recorded in the rats of each group for the first phase of the procedure. Then after 24 hours the second phase of the procedure was administered orally it was observed for another 24hour no toxicity manifestations or mortality recorded in all the animals. This shows that LD₅₀ of the

extract was above 5000 mg/kgbw. The lethal dose is thought to be safe as suggested by Lorke's [28].

The biochemical Parameters of Liver, there was no statistical significant difference in results of the parameters of all the groups when compared with control group. This could be attributed to the fact that the *moringa oleifera* leaf aqueous extract does not have any effect on the liver biochemical. This finding disagree with the work reported by Bais *et al.* [29] who reported an improvement in liver function test parameters in *Moringa* treated groups. This could be attributed to the fact that the different method of estimation of liver parameters used in this research

The Liver section in group 1 which Normal control shows normal hepatocytes, arranged in tubules and normal portal tracts. The group 2 which was Positive control showed normal hepatocytes with micro and macro marked steatosis within the hepatocytes. The group 3 which served as standard control shows normal hepatocyte with no steatosis observed within the hepatocytes. The group 4 served as test group shows normal hepatocyte with no steatosis within the hepatocytes. The group 5 also served as test group shows normal hepatocyte with no steatosis within the hepatocytes.

The study demonstrated that *moringa oleifera* leaves extract and standard obesity drug may reverse the formation of hepatic steatosis in group 3, group 4 and 5. as supported by work done by Bais *et al.* [29] Thamer, [30], who independently reported amelioration of steatosis in Liver of obese rat treated with Orlistat and *Moringa oleifera*.

5.1 CONCLUSION

This study shows that *Moringa oleifera* leaf extract possesses clearing ability of fat deposited in the liver tissue and anti-obesity properties as like the selected standard drugs. At higher acceptable dose of *Moringa oleifera* leaf aqueous extract demonstrated better anti obesity properties like the selected standard drugs. Hence, leaf aqueous extract of *Moringa. oleifera* is beneficial in the management of dietary obesity.

COMPETING INTERESTS DISCLAIMER:

Authors have declared that no competing interests exist. The products used for this research are commonly and predominantly use products in our area of research and country. There is absolutely no conflict of interest between the authors and producers of the products because we do not intend to use these products as an avenue for any litigation but for the advancement of knowledge. Also, the research was not funded by the producing company rather it was funded by personal efforts of the authors.

REFERENCES

1. Rohan, C. U. J. "Screening of crude plant extracts with antiobesity activity," *International Journal of Molecular Sciences*, 2012. **13(2)**: 1710-1719.
2. Kopelman, P. G. "Obesity as a medical problem," *Nature*, 2000. **404(6778)**: 635-643. Adekunle, A. S., Adelus, T. I., Kamdem, J., Ishmael, A. and Akintade, B. B. Insulinomimetic, Antihyperlipidemic and Antioxidative Properties of *Moringa oleifera* , Possible Mechanism of Action. *British Journal of Medicine & Medical Research*, 2016. **17(5)**: 1-11.
3. Adeyemo, B. T., Omitoyin, B. O., Adeniji, A. A., Lawa, M. Potential of *Moringa oleifera* (Lam.) fresh root-bark extract as an organic pesticide in aquaculture pond management. *Egyptian Journal of Biology*, 2003. **13**: 8-13.
4. Musa, A., Spadano, J., Coakley, E. H., Field, A. E., Colditz, G. and Dietz, W. H. The disease burden associated with overweight and obesity. *Journal of the American Medical Association*, 1999. **282(16)**: 1523–1529.
5. Baron, R. B., Mcphee, S. J., Papadakis, M. A. and Tierney, L. M. Nutritional Disorders In human Editors. Current Medical Diagnosis and Treatment, 46th Edition New York: Lange Medical Books, 2007. **12(6)**: 1290-1296.
6. Siminnialayi, I. M., Emem-Chioma, P. C. and Dapper, D. V. The prevalence of obesity as indicated by BMI and waist circumference among Nigerian adult attending Family Medicine clinics as outpatients in Rivers state. *Nigerian Journal of Medicine*, 2007. **17**: 340-345.
7. Akinkugbe, O. O. Non-communicable diseases in Nigeria, The next epidemics: Nigeria preparedness. Third Biennial Abayomi Bamidele Memorial Lectures. *Nigerian Journal of Clinical Practice*, 2000. **3**: 37-42.
8. Ojofeitimi, O., Adeyeye, E. I. and Ojugba, S. Comparative study of proximate, amino acids and fatty acids of *Moringaoleifera* tree. *Elixir Applied Chemistry*, 2002. **54**: 12543-12554.
9. Chobanian, A. V., Bakris, G. L., Black, H. R., Cushman, W. C., Green, L. A., and Izzo, J. L. The seventh report of the Joint National Committee on Prevention, Detection, Evaluation and Treatment of high blood pressure: *Journal of the American Medical Association*, 2003. **289**: 2560-2572.
10. Amoah A. G. (2003). Obesity in adult residents of Accra, Ghana.

- Ethnopathology Diseases*, **13(22)**: 97–101.
11. Sodjinou, R., Agueh, V., Fayomi, B. and Delisle, H. Obesity and cardio-metabolic risk factors in urban adults of Benin: relationship with socio-economic status, urbanization and lifestyle patterns. *British Medical Center for Public Health*, 2008. **77(8)**: 84.
 12. World Health Organisation (WHO) Global strategy on diet, physical activity and health. *Bulletins of the World Health Organisation*, 2006. **5**: 16-8.
 13. Kalibbala, H. M., Wahlberg, O. and Hawumba, T. J."The impact of Moringa oleifera as a coagulant aid on the removal of trihalomethane (THM) precursors and iron from drinking water". *Water Science and Technology: Water Supply*, 2009. **9(6)**: 707-714.
 14. Majekodunmi, O. F., Zany K., Olanyaga I. E., Shi, L. E. and Melanhin, J. L. Selective Toxicity Diterpene from Euphorbia Poisonic, *Journal of Medicinal Chemistry*, 1996. **39**: 1005-1008.
 15. Oh, K., Hu, F. B., Manson, J. E., Stampfer, M. J. and Willett, W. C. Dietary fat intake and risk of coronary heart disease in women: 20 years of follow-up of the nurses' health study. *American Journal Epidemiology*, 2005. **161**: 672-679.
 16. Shyamala, M. P., Venukumar, M. R. and Latha, M. S. Antioxidant potential of the *Syzygium aromaticum* (Gaertn) Linn (Cloves) in rats fed with high fat diet. *Indian Journal of pharmacology*, 2003. **35**: 99-103.
 17. Calderon, G. D. (2011). Clinical guidance on the identification .Evaluation and treatment of overweight and obesity in adult, National institutes of health. *Obese*, **6**: 51 -209.
 18. Adekunle, A. S., Adelusi, T. I., Kamdem, J., Ishmael, A. and Akintade, B. B. Insulinomimetic, Antihyperlipidemic and Antioxidative Properties of *Moringa oleifera* , Possible Mechanism of Action. *British Journal of Medicine & Medical Research*, 2016. **17(5)**: 1-11.
 19. Reitman, S. and Frankel, L. Standard Method in Clinical Chemistry. *American Journal of Clinical Pathology*, 1957. **28**: 56-60.
 20. Tietz, N. W. Fundermental of Clinical Chemistry, W. B. Saunders Company, London, 2000. 1020-1038.
 21. Grant, G. H. and Kacchman, J. F. In: "Fundamental of Clinical Chemistry" (Tietz, N.W), 3rd edition. W. B. Sauders Company, Philadelphia, 1987. 298-320.
 22. Aja, P. M., Nwafor, E. J., Ibiama, A. U., Orji, O. U., Ezeani, N. and Nwali, B. U. Evaluation of Anti-diabetic and Liver Enzymes Activity of Aqueous Extracts of Moringa oleifera and Bridelia ferruginea Leaves in Alloxan Induced Diabetic Albino Rats. *International Journal of Biochemistry Research & Review*, 2015. **3(3)**: 248-258.
 23. Bowers, G. N. and McComb, R. B. A Continous Spectrophotometric Method for Measuring the Activity of Serum Alkaline Phosphate. *Journal of Clinical Chemistry*, 1996. **12**: 70-89.
 24. Henry, R. J., Cannon, D. C. and Winkelman, J. W. Clinical Chemistry, Principles and Techniques Harper and Row, 2nd edition, 1974. 309-320.
 25. Ochei, J. and Kolhacker, A. Textbook of Medical Laboratory Science: Theory and Practice. Tara Mecgraw- Hill Publishing Company Limited, New Delhi. 2005.
 26. Egbujo, E. C., Adisa, J. O. and Yahaya, A. B. A Study of the Staining Effect of Roselle (*Hibiscus sabdariffa*) on the Histologic Sections of the Testis. *International. Journal of Morphology.*, 2008. **26(4)**: 927-930.
 27. Mehta, K., Baraman, R., Amin, A. H., Bafina, P. A., and Gulatin, D. A. Effect

- of moringa oleifera on lipid profile and hypercholesterolaemic in rats. *Journal of Ethanopharmacology*, 2003. **86**: 191-195.
28. Lorke, D. A new approach to practical acute toxicity testing. *Archives of toxicology*, 1983. **53**: 275-287.
29. Bais, S. B., Guru, S. K. S. and Ramica, S. M. Antiobesity and thyrolipid activity of moringa oleifera leave against high fat diet induced obesity in rats. *Natural institute of pharmacology*, 2014. **9**: 10-14.
30. Themar, S. J. and Jammed, S. S. The effect of orlistat and metaformine treatment on body weight, liver steatosis, hepatin in obese rats fed HfD. *Journal of American science*, 2014. **10**: 4.

UNDER PEER REVIEW