

**PROTECTIVE EFFECT OF *COSCINIUM FENESTRATUM* BARK EXTRACT
ON LETROZOLE INDUCED POLYCYSTIC OVARY SYNDROME (PCOS) IN
SPRAGUE DAWLEY RATS**

ABSTRACT:

Aim:

Polycystic ovary syndrome (PCOS) is a common endocrine disorder. The aim of the present study is to evaluate the effects of the oral administration of *Coscinium fenestratum* bark extract in letrozole-induced PCOS in rats.

Methods

Thirty female Sprague-Dawley (SD) rats were randomly divided into five groups of 6 animals each. Letrozole (1 mg/kg) was administered orally for a period of 21 days to induce PCOS. Control rats received 1 mL/day of distilled water, and the three groups of PCOS rats were given 1mg/kg of clomiphene citrate, 250 mg/kg of *Coscinium fenestratum* extract and 500 mg/kg of *Coscinium fenestratum* extract by oral gavage for 15 days. Blood samples were collected and the ovary of rats was removed, weighed, and fixed in 10% buffered formalin to determine the hormonal and antioxidant parameters.

Results:

In rats treated with BECF, significant increase in Catalase, Superoxide Dismutase and Lipid peroxidation level was decreased when compared with letrozole group. Histopathology showed that the BECF treated rats had normal ovarian structure, which was seen distorted due to the PCOS condition in letrozole treated rats. The results show significant decrease in total testosterone level and LH and significant increase in FSH. Therefore, the extract of BECF show significant effect on PCOS rats. The significance p value is >0.001.

Conclusion:

Based on these result, the BECF extract and traditional wisdom of this plant when used regularly can be a good treatment a suitable treatment option for PCOS which can be regularly used

Keywords

Polycystic ovary syndrome, Coscinium fenestratum, clomiphene citrate, luteinizing hormone, follicle stimulating hormone.

Abbreviations

BECF – bark extract of Coscinium fenestratum

INTRODUCTION:

Polycystic ovary syndrome (PCOS) is referred as hyper-androgenic and common endocrine disorder in women reproductive age^[1]. The complex condition is characterized by elevated androgen levels^[2]. The manifestation of PCOS affects women of child bearing age (from 18-30) because the ovaries develop into numerous small collection follicles and failed to regulate the release of **dominant follicle (chronic anovulation)**. Prevalence of PCOS in India ranges from 3.7 to 22.5 % depending on the population studied and the criteria used for diagnosis^[3]. In PCOS, high level of LH secretion contributes to high level of androgen and low level FSH and it may lead to poor egg development, inability to ovulate and also lead to deficiency of progesterone production and often leads to absence of menstrual cycle period^(ref). The characteristics of PCOS is overweight^[4], insulin resistance^[5], anovulation, irregular periods, infertility, hypoandrogenemia and inflammation^[6]. The symptoms of PCOS are irregular periods, acne, hirsutism, weight gain, alopecia and heavy bleeding^[7]. The hormone is involved in PCOS is follicle stimulating hormone (FSH) and luteinizing hormone (LH) which is responsible for reproduction by testis in male and **ovarian** ovaries in female^(ref). FSH is released **by stimulation of GnRH secretion from the hypothalamic pituitary hormone** from the anterior pituitary following the stimulation by GnRH from hypothalamus (hypothalamic-pituitary –ovarian axis), it regulates **development, growth, pubertal maturation and reproduction.** pubertal maturation, and secondary sexual characteristics development. In female – FSH **also** initiates follicular growth, development of oocytes **and** , yolk deposition and increase the production of growth factors inside the ovary^[8]. LH is a hormone produced by gonadotropic cells from the anterior pituitary gland. In female LH is responsible for **ovulation and progesterone release after** ovulation from the corpus luteum^[9].

Obesity is the major key component for metabolic syndrome and associated with level of insulin which is increased in ovarian androgen production. The excessive adipose tissue is responsible for ovulatory dysfunction and menstrual abnormalities^[10]. Obesity and insulin resistance increase the risk of type 2 diabetes and cardiovascular disease^[11]. The decrease in HDL-C and increase in triglycerides and LDL can lead to PCOS^[12].

The phenotype limits of PCOS is defined by specific phenotype which determine the long term morbidity^[13]. The factors influencing the PCOS are genetic factors, environmental factors and endocrine factors.

The Rotterdam consensus include the diagnostic criteria national institute of Health (NH) proposed set any two from the three must present to diagnosis PCOS: hyperandrogenism, ovulatory dysfunction and polycystic ovaries by transvaginal ultrasound.^[14]

Tree turmeric is a beneficial plant in the world were its root and stem serve as excellent antibiotic and antiseptic properties, which belongs to menispermaceae family and botanically known as *Coscinium fenestratum*. Berberin is the active ingredient that gives the medicinal properties. The major alkaloids are yellow crystalline berberine, protoberberine and jatrorrhizine^[15]. The *Coscinium fenestratum* mainly from South Asia and parts of South-East Asia^[16].

The plant is used for treating inflammation, stimulate wounds and ulcers healing, jaundice, burns, skin disease, abdominal disorders and diabetes. The bark is used in gynaecological troubles^[17]. The *Coscinium fenestratum* have activities like anti-diabetic^[18], anti-gonococcal^[19], anti-oxidant and anti-microbial^[20], anti-hepatotoxic^[21], immunomodulatory^[22], anti-proliferative^[23], anti-acne^[24], hypotensive^[25], CNS depressant and analgesic activity^[26].

MATERIALS AND METHODS

The bark of *Coscinium fenestratum* were collected from local source, Tamil Nādu. The bark material was identified and authenticated by Dr. P Jayaraman, Plant Anatomy Research Centre, Tamil Nadu. Collected bark was ground into coarse powder. The powered bark was extracted with ethanol: water (3:1) in Soxhlet's apparatus. 630g powder of *Coscinium fenestratum* is extracted with 1500ml at 80°C for 72h. The extract is filtered and

vacuum dried. The dried residue of extract was cooled in desiccator for 30 min and then accurately weighed the % yield was 3.23^[27].

The female SD rats 3 weeks old was chosen which was procured from mass biotech. The animals were acclimated to laboratory conditions one week and provided with standard pellet chow and water ad libitum and maintained in animal house of C.L. Baid Metha College of Pharmacy. Ethical committee clearance was obtained from IAEC with IAEC REFERENCE NO: 02/321/PO/Re/S/01/CPSCEA – 17/11/2021

The animals were divided into 6 groups (n=6), Group I- control group, Group II – letrozole (1 mg/kg, P.O), Group III – Clomiphene citrate (1mg/kg, P.O.), Group IV – Low dose (250 mg/kg, P.O), Group V – High dose (500 mg/kg, P.O). The duration of study is for 36 days, letrozole was administered orally through oral gavage for 21 days induction PCOS, followed by oral administration of BECF for 15 days. For confirmation of PCOS formation the estrus cycle was done. On the 36 days, the animals are anaesthetized and decapitated, ovaries and serum were collected. Histopathology, anti-oxidant and hormonal assay was performed.

RESULTS AND DISCUSSION

FOLLICLE STIMULATING HORMONE

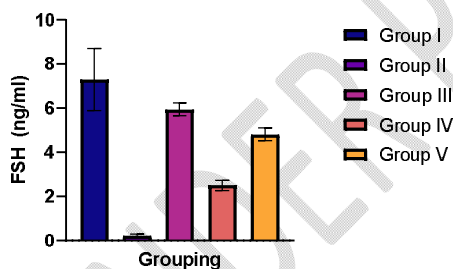


FIGURE 1

LUTENIZING HORMONE

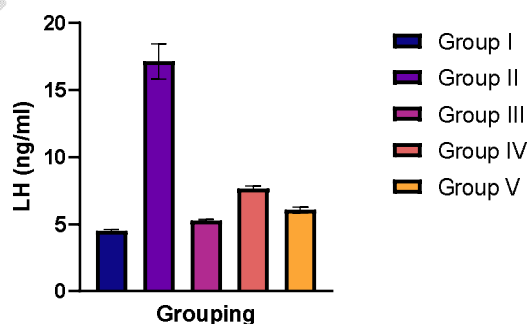


FIGURE 2

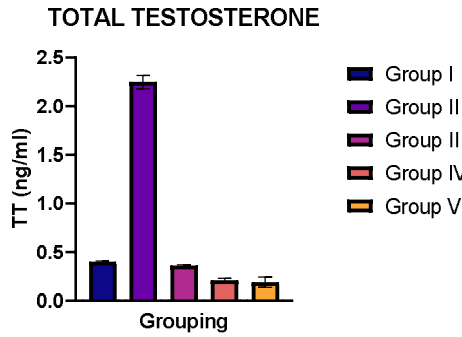


FIGURE 3

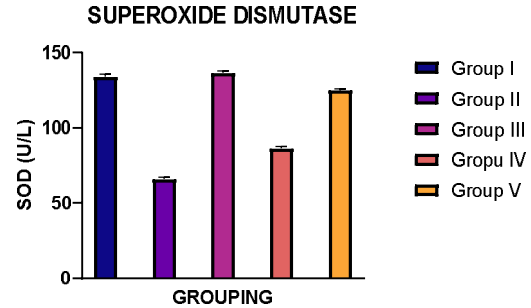


FIGURE 4

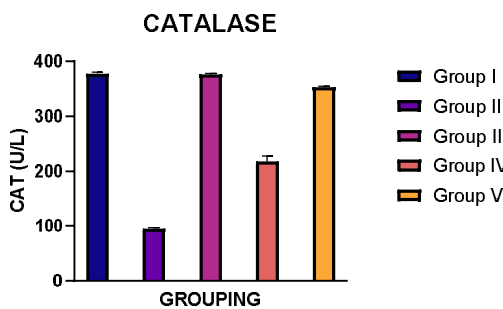


FIGURE 5

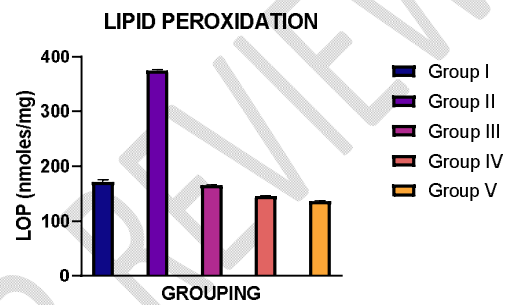


FIGURE 6

Hormonal analysis:

FSH, LH and Testosterone level was estimated using chemiluminescent method, the result shows the FSH level increased and Testosterone and LH level decreased when compared with group II as shown fig 1,2, 3

Anti-oxidant:

Superoxide dismutase, Catalase and Lipid peroxidation was estimated using specific kits, the result shows Superoxide dismutase and Catalase level increased and Lipid peroxidation level decreased when compared with group 4,5,6

Histopathology

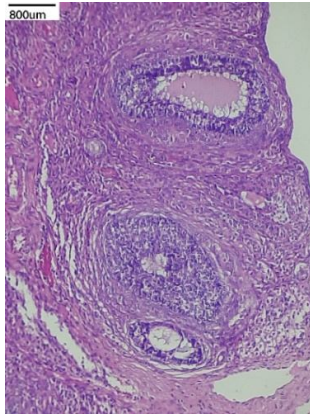
Group I - healthy growing follicles and a corpus_luteum is seen

Group II- several cyst-like follicles were formed

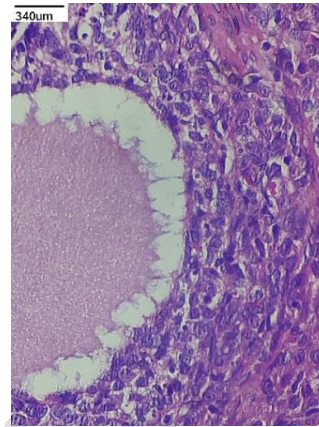
Group III – decrease in cyst size and generation of healthy follicles

Group IV – BECF (250mg/kg) show slight decreases in cysts size

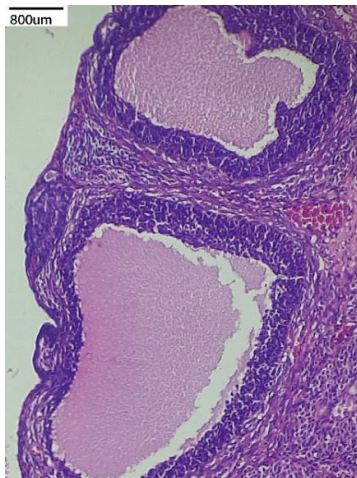
Group V – BECF (500 mg/kg) shows decrease cysts size and regeneration of healthy follicles



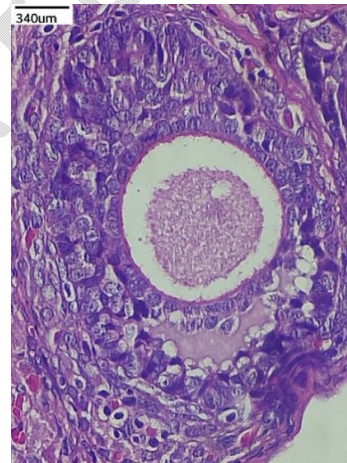
Group I



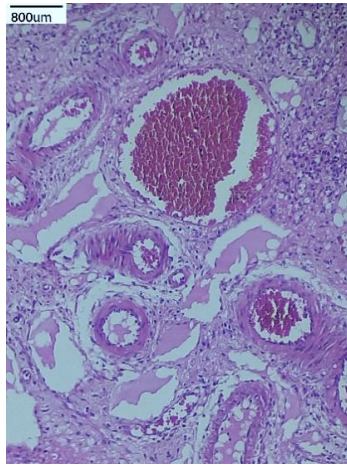
Group II



Group III



Group IV



Group V

STATISTICAL ANALYSIS:

The data was analysed in terms of mean \pm standard error of mean (SEM). For statistical analysis, multiple comparisons of data were made using Analysis of variance (ANOVA) followed by Dunnett's multiple comparison test. Software program GraphPad prism 9.3.1 was used for all data analysis.

CONCLUSION:

Animals who were treated by BECF extract exhibited a regular pattern estrus cycle. The BECF treated rats were showed a marked increase in FSH level, while both testosterone and LH levels were markedly decreased. BECF extract also had some anti-androgenic effects represented by degeneration of immature follicles and decrease in cysts; size. Thus, this plant can help in restoration of normal estrogenic state, inhibiting hyper androgenic state and treating PCOS.

The Estrus cycle has been restored to regular pattern in the animals treated with BECF. Hence is concluded that this extract has produced potential healing effect on PCOS rat model, restoring the reproductive cycle and other complications to normal. The BECF treated group causes an increase in FSH level and decrease in LH and Testosterone level and BECF shows a remarkable antiandrogenic effect by degenerating the immature follicular cysts and decreasing the cysts size which can help in regulating normal ovulation. So this plant helps in restoring the estrogenic conditions and inhibit aspects of hyperandrogenism.

Ethical Approval:

Animal Ethic committee approval has been collected and preserved by the author(s)

Disclaimer

This paper is an extended version of a repository document of the same author.

The repository document is available in this link: http://repository-tnmgrmu.ac.in/21007/1/261602721hari_priya.pdf

[As per journal policy, repository article can be published as a journal article, provided it is not published in any other journal]

REFERENCE

1. El Hayek et al. (2016). Poly cystic ovarian syndrome: an updated overview. *Frontiers in physiology*, 7, 124.
2. Bharathi R et al. (2017). An epidemiological survey: Effect of predisposing factors for PCOS in Indian urban and rural population. *Middle East Fertility Society Journal*, 22(4), 313-316.
3. Ganie et al. (2019). Epidemiology, pathogenesis, genetics & management of polycystic ovary syndrome in India. *The Indian journal of medical research*, 150(4), 333.
4. Ramanand et al. (2013). Clinical characteristics of polycystic ovary syndrome in Indian women. *Indian journal of endocrinology and metabolism*, 17(1), 138.
5. Marshall, J. C., & Dunaif, A. (2012). Should all women with PCOS be treated for insulin resistance? *Fertility and sterility*, 97(1), 18-22.
6. González (2012). Inflammation in polycystic ovary syndrome: underpinning of insulin resistance and ovarian dysfunction. *Steroids*, 77(4), 300-305.
7. Sidra et al. (2019). Evaluation of clinical manifestations, health risks, and quality of life among women with polycystic ovary syndrome. *PLoS One*, 14(10), e0223329.
8. Cahoreau et al. (2015). Structure–function relationships of glycoprotein hormones and their subunits' ancestors. *Frontiers in endocrinology*, 6, 26.

9. Schriefer, et al. (1982). Role of fetal oxytocin in parturition in the rat. *Biology of Reproduction*, 27(2), 362-368.
10. Cena et al. (2020). Obesity, polycystic ovary syndrome, and infertility: A new avenue for GLP-1 receptor agonists. *The Journal of Clinical Endocrinology & Metabolism*, 105(8), e2695-e2709.
11. Teede et al. (2010). Polycystic ovary syndrome: a complex condition with psychological, reproductive and metabolic manifestations that impacts on health across the lifespan. *BMC medicine*, 8(1), 1-10.
12. Kim, J. J., & Choi, Y. M. (2013). Dyslipidemia in women with polycystic ovary syndrome. *Obstetrics & gynecology science*, 56(3), 137-142.
13. Sachdeva et al. (2019). Comparison of the different PCOS phenotypes based on clinical metabolic, and hormonal profile, and their response to clomiphene. *Indian Journal of Endocrinology and Metabolism*, 23(3), 326.
14. Markle, M. E. (2001). Polycystic ovary syndrome: Implications for the advanced practice nurse in primary care. *Journal of the American Academy of Nurse Practitioners*, 13(4), 160-163.
15. Tushar et al. (2008). *Coscinium fenestratum* (Gaertn.) Colebr.-A review on this rare, critically endangered and highly-traded medicinal species. *Journal of Plant Sciences*, 3(2), 133-145.
16. Rai et al. (2013). Medicinal use of *Coscinium fenestratum* (Gaertn.) Colebr.: an short review. *Oriental Pharmacy and Experimental Medicine*, 13(1), 1-9.
17. Danapur et al. (2020). Endangered Medicinal Plant *Coscinium fenestratum* (Gaertn.) Colebr A Review. *Pharmacognosy Journal*, 12(5).
18. Shirwaikar et al. (2005). Antidiabetic activity of alcoholic stem extract of *Coscinium fenestratum* in streptozotocin-nicotinamide induced type 2 diabetic rats. *Journal of Ethnopharmacology*, 97(2), 369-374.
19. Chomnawang et al. (2009). In vitro antigonococcal activity of *Coscinium fenestratum* stem extract. *Journal of ethnopharmacology*, 122(3), 445-449.
20. Goveas, S. W., & Abraham, A. S. H. A. (2013). Evaluation of antimicrobial and antioxidant activity of stem and leaf extracts of *Coscinium fenestratum*. *Asian J Pharm Clin Res*, 6(3), 218-21.
21. Venukumar, M. R., & Latha, M. S. (2004). Effect of *Coscinium fenestratum* on hepatotoxicity in rats.

22. Kothalawala, et al. (2020). Immunomodulatory Activity of a Traditional Sri Lankan Concoction of *Coriandrum sativum* L. and *Coscinium fenestratum* G. *Evidence-Based Complementary and Alternative Medicine*, 2020.
23. Jacob et al. (2012). Synthesis of silver nanorods using *Coscinium fenestratum* extracts and its cytotoxic activity against Hep-2 cell line. *Colloids and Surfaces B: Biointerfaces*, 98, 7-11.
24. Kumar et al. (2007). Antimicrobial effects of Indian medicinal plants against acne-inducing bacteria. *Tropical journal of pharmaceutical research*, 6(2), 717-723.
25. Singh, et al. (1990). Hypotensive action of a *Coscinium fenestratum* stem extract. *Journal of Ethnopharmacology*, 30(2), 151-155.
26. Sudharshan, et al. (2009). Central Nervous System (CNS) depressant and analgesic activity of methanolic extract of *Drypetes roxburghii* wall in experimental animal model. *Research Journal of Pharmacy and Technology*, 2(4), 854-857.
27. Rojsanga, et al. (2006). Determination of berberine content in the stem extracts of *Coscinium fenestratum* by TLC densitometry. *Medical Principles and Practice*, 15(5), 373-378.