

Implant Supported Metal Reinforced Overdenture with Ball Attachments : A Case Report

ABSTRACT

Prosthetic management of mandibular edentulous arch has always been a challenge. Implant-supported overdentures have been a common treatment modality for edentulous patients and have shown good clinical results. Implant supported overdentures offer many advantages over conventional complete dentures. These include decreased bone resorption, reduced prosthesis movement, better esthetics, improved tooth position, better occlusion, increased occlusal function and maintenance of the occlusal vertical dimension. The present article illustrates design and fabrication technique of the implant-retained mandibular overdenture using ball attachments.

Keywords: implant retained overdenture, ball attachment

Introduction

Implant-supported overdenture is a treatment modality that is commonly used, cost effective, and possible treatment for the edentulous mandible to increase patient satisfaction.¹ Mandibular implant-supported overdenture is often indicated when there are problems found with mandibular dentures, such as lack of retention or stability, decrease in function, difficulty in speech, tissue sensitivity, and soft tissue abrasion.² However, acrylic resin denture base fracture can be a problem encountered with implant supported prosthesis. Occlusal disharmony, excessive occlusal forces, flexure and fatigue of the denture base as a result of alveolar resorption, thin spots in denture base, and impact as a result of dropping the denture can be the possible causes of fracture of denture.³ Metal reinforcement of the mandibular implant-supported overdenture has been suggested as a method that can increase resistance to fracture and improve the denture's dimensional stability. Many patients are satisfied with a stable implant-supported overdenture that requires limited clinical time and financial expense.⁴ The attachments used to retain implant overdenture include stud, bar, magnets, and telescopic attachments. Among these, bar attachment system has the greatest retention to provide better comfort and long term serviceability to the patient.⁵ The selection of the attachments for an implant retained overdenture depend on cost effectiveness, retention required, oral hygiene, amount of bone available, patient's economic status, patient's expectation, maxillomandibular relationship, inter implant distance, and status of the opposing jaw.⁶

The present article reports prosthodontics rehabilitation of edentulous mandibular arch with implant supported metal reinforced overdenture.

Case report

A male patient aged 60 years reported to department of Prosthodontics with chief complaint of broken mandibular denture. On intraoral examination, it was found that maxillary and mandibular arch were completely edentulous (figure 1) and a decision to place two implants with in mandibular arch was made. Surgery was performed under local anaesthesia and ball attachments were placed over the implants (figure 2). Patient was recalled after 2 months for definitive treatment. The following treatment was carried out:

1. Maxillary arch primary impression was made with impression compound and mandibular arch primary impression was made with alginate (figure 3). Casts were poured in dental plaster. Custom trays were fabricated with self cure acrylic resin (DPI, India). Border moulding was done with green stick compound followed by wash impression with zinc oxide eugenol impression paste (DPI, India) for maxillary arch and light body polyvinylsiloxane material (Coltene Affinis) for mandibular arch (figure 4). After beading and boxing of the impressions, definitive casts were poured with dental stone (figure 5).
2. Fabrication of the metal denture base was done prior to jaw relations, and it included relieving the master cast using a wax spacer following which the relieved master cast was duplicated using agar and poured with phosphate bonded investment material and refractory cast was prepared. After that die hardener was applied all over the refractory cast. Meshwork pattern wax was used for the design of the metal framework which was then sealed to the refractory cast. Sprues were also attached. Ring liner and casting ring was placed and then invested. The metal framework was then finished and polished (figure 6).
3. Customized record base and occlusal rim was then fabricated over the metal framework. Facebow record and jaw relation of the patient was made. Casts were articulated onto semi-adjustable articulator following teeth arrangement was done. Evaluation of esthetics and phonetics was done, and the patient's acceptance was obtained at the try in appointment (figure 7).
4. On the day of denture placement both the female and male attachments were replaced with the new one. An index was made using alginate for ball attachment locations on the intaglio surface of a denture, and a hollow was created in that area to receive female housings. A rubber dam was cut and placed around the ball attachment on the tissue to prevent tissue injury during acrylic polymerization.

5. Female housings were incorporated over male ball attachments, which were held parallel to each other in the parallel path of the axis. The self-cure acrylic resin was mixed and injected into the hollow space created on the tissue surface for both maxillary and mandibular dentures. Both dentures were positioned inside the patient's mouth, and the patient was asked to bite in centric occlusion. The material was allowed to be set for some time and was removed from the mouth. Excess materials were trimmed and finished before being reoriented in the same position intraorally (figure 8 and 9).

Discussion

The implant-supported overdenture allows the tongue and perioral musculature to resume a more normal function as they remain in place during mandibular movements.⁷ In the present article conventional complete denture prosthesis was converted into implant supported overdenture prosthesis at a comparatively low cost without compromising esthetic and function.

In the present case, ball attachment was used because, it has been documented in various studies that ball attachment are less costly, less technique sensitive and easier to clean than bars. **The minimum space required for ball attachments is 10-12mm. Attempts to fabricate prostheses with inadequate restorative space can result in physiologically inappropriate contours, structurally weak prostheses, compromised esthetics, encroachment into interocclusal rest space, and/or compromised retention and stability of the treated result.**^{8,9} The case in the present article had the space availability of 10mm. Also the implants were parallel to each other. Tokuhisa et al.¹⁰ stated that the use of the ball/O-ring attachment could be advantageous for implant-supported overdenture with regard to optimizing stress and minimizing denture movements. A photoelastic analysis done by Kenney and Richards indicated that less stress was transferred with the ball/O-ring attachment to the implants. It appears that the O-ring provide retention against dislodging forces toward occlusal surface, allowing the overdenture to rotate around the ball connected to the implant body. As rotation occurs, stress is transferred to the posterior edentulous area providing optimal broad stress distribution to the ridge and minimal stress to the implants.¹¹ A systematic review by Ikbalet al.¹² stated that the form of attachment of the cylinder locator is not easy to wash. Cleaning using a palatal, buccal, mesial and distal toothbrush, including areas close to the gingival margin, should be of concern for the patient to rotate the toothbrush section in such a way that the wall around the buffer is washed. A ball can be a simple attachment that is washed with horizontal brushing movements that are easy to abutment.

Retentive element and the denture connection can be achieved by two methods i.e. indirect or direct method. The indirect technique includes recording of denture's soft tissue support and implant position in relation to the denture, so that the connection of the matrix and the relining procedure can be completed in the laboratory. This method reduces chair time. Recording and transfer of implant positions with analogues may include errors. The direct technique includes locating a ball attachment intraorally. This technique was used in the article as this technique is simple, economic, quick, and allows the patient to retain the prosthesis.¹²

The technique presented describes the reinforcement of the denture base with a metal framework and also the inclusion of the metal housing in the framework design to prevent fractures that could occur at the sites close to the implant abutments. A follow up of 3 months was given to the patient and patient was highly satisfied and also on radiographic examination the marginal bone loss was also minimal.

Conclusion

Prosthetic rehabilitation of edentulous mandible with implant supported overdenture is one of the most beneficial treatment option that can be rendered to the patient. Despite being widely accepted as treatment, some controversies still exist with regard to the design of the overdenture, selection of the appropriate attachment system, and the optimal techniques for the overdenture fabrication. Clinicians and dental technicians have to adhere to sound design principles such as simplicity in fabrication, ease of maintenance and repair and cost control.

REFERENCES

1. Ozçelik TB, Yılmaz B, Akçimen Y. Metal reinforcement for implant-supported mandibular overdentures. *J Prosthet Dent* 2013;109(5):338–340.
2. Kadam KS, Dange SP, Mahale K, Khalikar SA, Khalikar A. Implant-supported Overdenture. *Int J Oral Implantol Clin Res* 2017;8(1):22-25..
3. Batenburg RH, Meijer HJ, Raghoobar GM, Vissink A. Treatment concept for mandibular overdentures supported by endosseous implants: a literature review. *Int J Oral Maxillofac Implants* 1998;13(4):539-545.
4. Rodrigues AHC. Metal reinforcement for implant-supported mandibular overdentures. *J Prosthet Dent* 2000;83(5):511–513.
5. Krishna S, Kumar R, Sailasri K. Implant-Supported Overdenture Using Ball Attachments in Maxilla and Mandible: A Case Report. *Cureus* 2022;14(3): e23264.
6. Nazir O, Pandey KK, Katiyar P, Tarranum F, Tiwari H, Farhaan M. Implant supported overdenture: a case report. *IP Annals of Prosthodontics and Restorative Dentistry* 2021;7(1):50–54.
7. Lambade D, Lambade P, Gundawar S. Implant supported mandibular overdenture: A viable treatment option for edentulous mandible. *J ClinDiagn Res* 2014;8(5):ZD04-ZD06.
8. Bansal S, Aras MA, Chitre V. Guidelines for treatment planning of mandibular implant overdentures. *J Dent Implant* 2014;4:86-90.
9. Ahuja S, Cagna D. Defining available restorative space for implant overdentures. *J Prosthet Dent* 2010;104(2):133–136.

10. Cakarer S, Can T, Yaltirik M, Keskin C. Complications associated with the ball, bar and locator attachments for implant-supported overdentures. *Med Oral Patol Oral Cir Bucal* 2011;16:e953-9.

11. Mhatre S, Ram SM, Mahadevan J, Karthik M. Rehabilitation of an Edentulous Patient with Implant Supported Overdenture. *J Contemp Dent* 2013;3(1):52-56.

12. Ikbal M, Mude HA, Dammar I, Launardo V, Sudarman IA. Locator or ball attachment systems for mandibular implant overdenture: a systematic review. *Sys Rev Pharm* 2020;11(9):15-19.

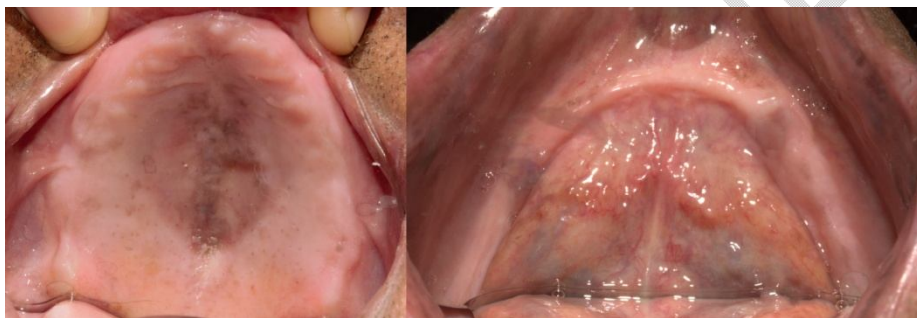

Figure 1: Intraoral view of maxillary and mandibular arch

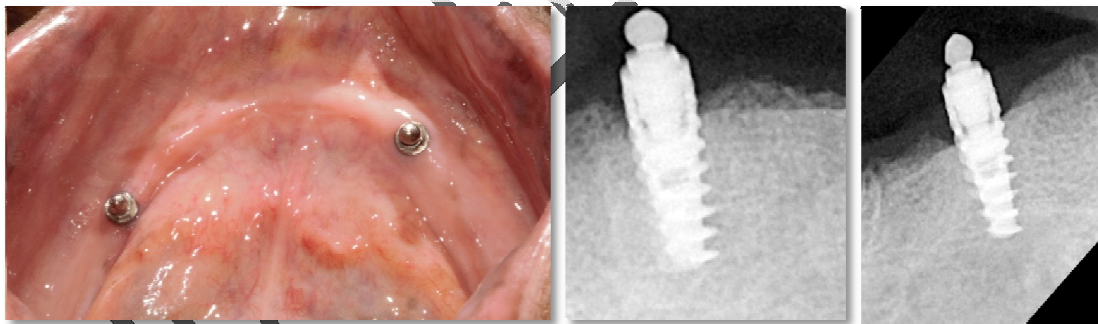


Figure 2: Intraoral and radiographic view of mandibular arch after implant placement

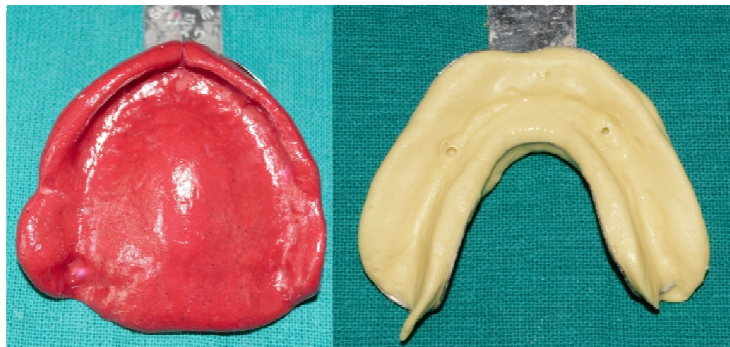

Figure 3: Primary Impression of Maxillary and mandibular arch

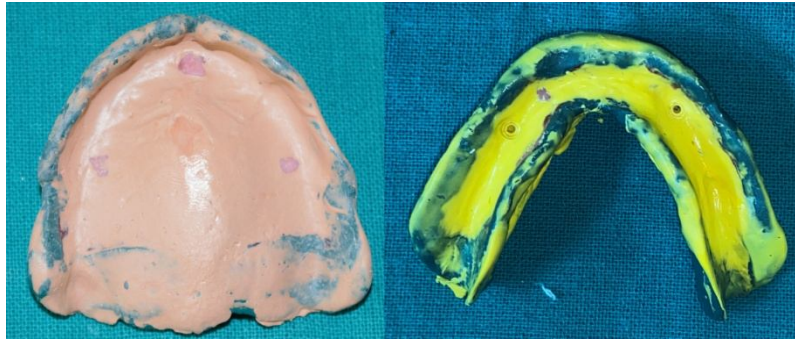


Figure 4: Final Impression of Maxillary and mandibular arch

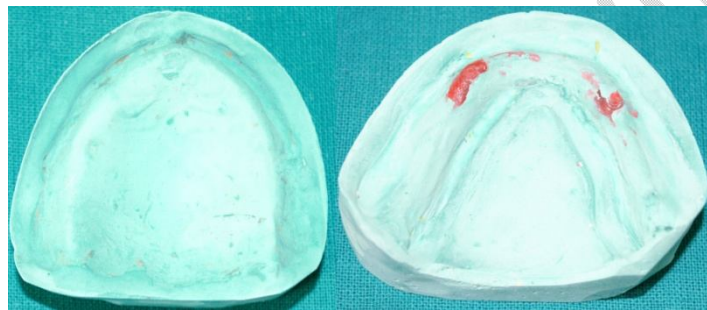

Figure 5: Master cast of Maxillary and mandibular arch



Figure 6: Refractory cast with wax pattern and sprue attachment and finished metal framework

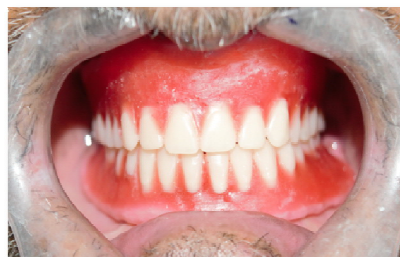

Figure 7: Denture trial

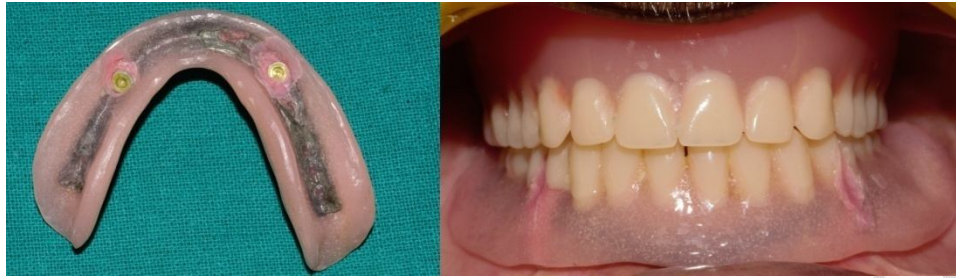

Figure 8: Intaglio surface of denture after pick up of female attachments and insertion of denture



Figure 9: Pre and Post operative view