

Case report

LIPOSARCOMA OF SPERMATIC CORD: A CASE REPORT ON A RARE RECURRENT PARATESTICULAR TUMOR

Abstract:

This is a case report of an elderly male patient who presented with recurrent scrotal liposarcoma on the contralateral side. A 76-year-old male patient presented with swelling in the left scrotum in 2018 which showed gradual increase in size for a period of 1 year. The patient underwent high inguinal orchidectomy. Histopathology report was given as Myxoid liposarcoma. Post-surgery the patient underwent chemotherapy for the same. The yearly follow-up visits were unremarkable. Liposarcoma of the cord should be differentiated from other para-testicular masses. It is rarely diagnosed preoperatively and is usually mistaken for inguinal hernia, hematocele and hydrocele.

Keywords: hematocele, Myxoid liposarcoma, inguinal hernia, hydrocele

INTRODUCTION

Liposarcoma is a rare malignant paratesticular tumour of the scrotum. It can arise from the epididymis, spermatic cord and fascia. Other malignant tumours include rhabdomyosarcoma, leiomyosarcoma, mesothelioma, and lymphoma.(1) Liposarcomas are difficult to diagnose as the imaging findings on MRI, CT, or Ultrasonography mimic that of inguinal hernia due to its fat content. (2) This is a case report of an elderly male patient who presented with a recurrent scrotal liposarcoma of the contralateral side.

Case report:

A 76-year-old male patient presented with swelling in the left scrotum in 2018 which showed gradual increase in size for a period of 1 year. There was no history of trauma, abdominal pain or prior surgery. On local examination the swelling was hard in consistency and all the borders were well felt. No previous imaging details were available. Due to clinical suspicion of scrotal malignancy and financial constraints, patient underwent contrast enhanced computed tomography (CECT) of abdomen and pelvis with limited sections of inguino-scrotal region in our institute for further evaluation of metastases. There was a 12.7 x 5.3cm (CC x TR) lesion in the left hemiscrotum which showed heterogenous enhancement with areas of fat density, interspersed fibrous septa, loculated fluid and intervening vessels with fat stranding (Figure 1). Left testes was not visualized. There was a hepatic haemangioma with classical CT features of peripheral nodular enhancement with delayed persistent enhancement and centripetal pattern of enhancement. Based on the CECT

features imaging diagnosis of liposarcoma with differentials of incarcerated inguinal hernia and dermoid were given. The patient underwent high inguinal orchidectomy. Histopathology report was given as Myxoid liposarcoma. Post-surgery the patient underwent 2 cycles of chemotherapy (Doxorubicin) for the same. The yearly follow-up visits up to 2020 were unremarkable.

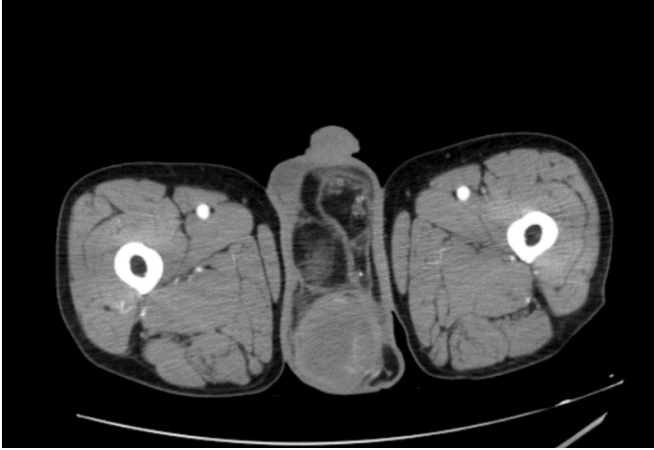


Figure (1): Axial CECT image taken in 2018 showing heterogenous areas of fat density with interspersed fibrous septa and loculated fluid pockets and intervening vessels with fat stranding in the left inguinoscrotal region.

In October 2022, the patient came with complaints of swelling in the right hemiscrotum. The swelling was insidious in onset and was hard in consistency, irreducible and non-compressible. The upper margin of swelling was palpable. The right testis was separately palpable from the swelling.

On ultrasound examination, a large well defined lobulated echogenic lesion with intervening hypoechoic septa measuring 9 x 7.9 x 5.7 cm (CC x AP x TR) was noted occupying the right scrotal sac causing inferior and posterior displacement of the right testis (Figure 2). Vascularity noted within the lesion on colour Doppler examination.

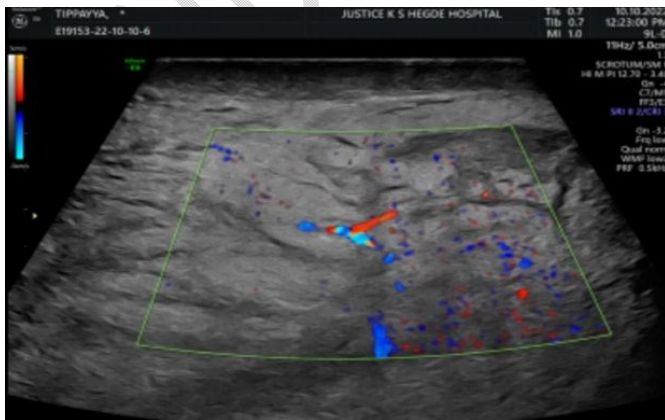


Figure (2): Longitudinal ultrasound view of the recurrent lesion (2022) in the right scrotum showing lobulated hyperechoic lesion with intervening hypoechoic septae with vascularity.

CECT of abdomen and pelvis including scrotal region revealed, a hypodense lesion with ill-defined margins in the scrotal sac predominantly in the dependent portion. The lesion shows predominantly fat density areas, enhancing vessels and mildly enhancing soft tissue component. Multiple enhancing vessels noted in the venous and delayed phase. No calcifications are noted. The lesion shows no definite capsule. There is mass effect on the right testis which is displaced **postero-superiorly**. (Figure 3a and 3b) No enlarged inguinal **lymph-nodes** were noted.

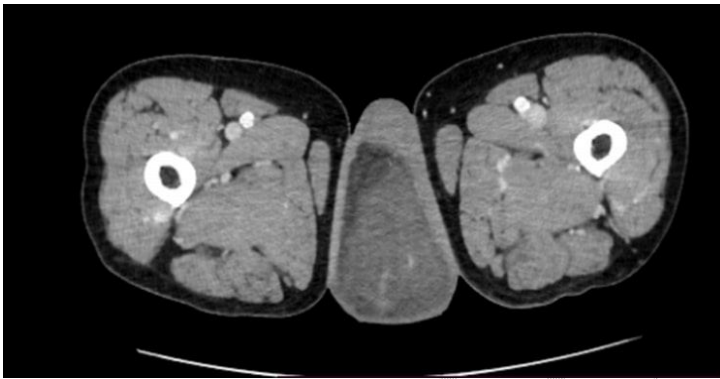

Figure 3a

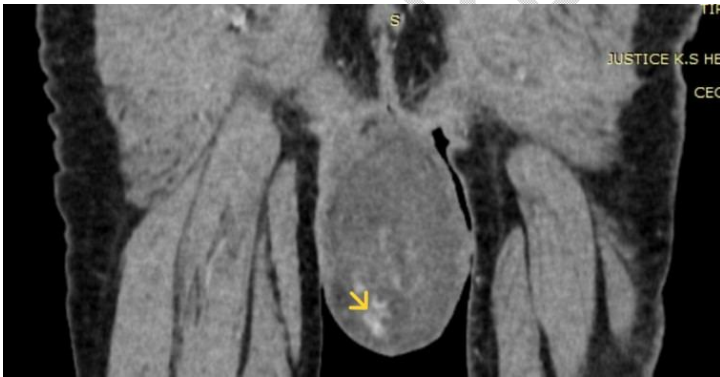

Figure 3b

Figure (3a) and (3b): Axial (a) and coronal (b) CECT image shows a heterogeneous lesion with few fat density areas, enhancing vessels and mildly enhancing soft tissue component in the right scrotum (Arrow).

Magnetic resonance imaging revealed a lesion appearing isointense to muscle on T1 weighted sequences which is hyperintense with hypointense strands on T2 weighted and Short Tau Inversion Recovery (STIR) sequences in the right

scrotal sac (Figures 4a, 4b). The lesion showed patchy areas of diffusion restriction on Diffusion weighted (DW) sequences. Based on the above imaging findings, recurrence of liposarcoma or differential diagnosis of fibrous tumour were given and histopathological correlation was advised. The patient then underwent surgical excision of the mass.

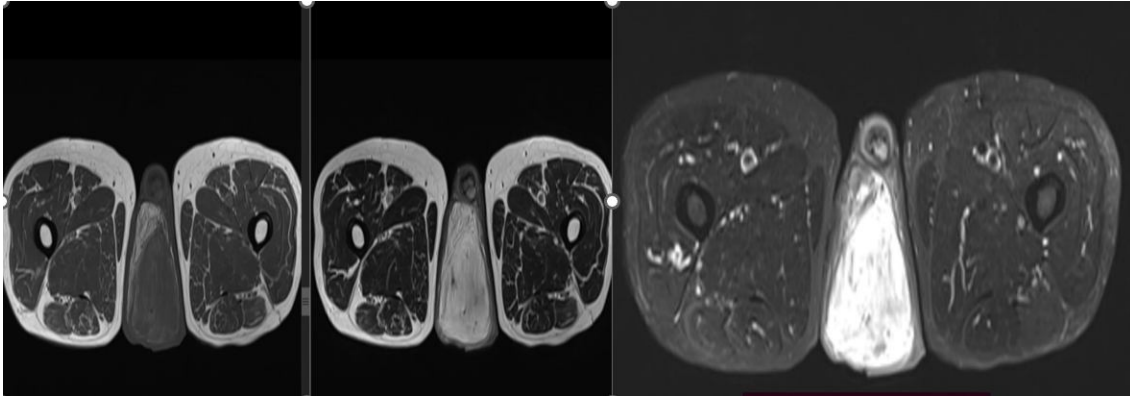


Figure 4a

Figure 4b

Figures (4a) and (4b): (4a) Axial T1 and T2 weighted sequences show a well-defined altered signal intensity lesion in the right scrotum appearing isointense to muscle on T1 and heterogeneously hyperintense on T2 sequences. (4b) On fat suppressed sequences, the lesion appears heterogeneously hyperintense with hypointense strands within

Histopathology came as dedifferentiated liposarcoma. The patient was advised chemotherapy and radiation for further management and was lost to follow up.

Discussion:

In our case, the patient presented with masses in scrotum bilaterally over the span of 4 years (Myxoid liposarcoma and Dedifferentiated liposarcoma). A possibility of loco regional recurrence with change in the histological type of liposarcoma secondary to degeneration of the primary tumor (Myxoid variety to dedifferentiated type) in the right scrotum was considered.

The sarcoma of the spermatic cord was first reported in the year of 1845 by Lesauvage.(3) Liposarcoma of the spermatic cord presents as a slow growing tumour and presents in patients between the ages of 50 and 60. Based on histological examination, liposarcoma consists of various subtypes. World Health Organisation (WHO) classification of liposarcoma is as follows- Well differentiated (Adipocytes, sclerosing and inflammatory types), Myxoid or round cell, Pleomorphic and De-differentiated types.(4,5) Dedifferentiation of

liposarcomas is usually seen with well differentiated liposarcoma and rarely with myxoid variety of liposarcoma.

Liposarcoma of the cord should be differentiated from other para-testicular masses. It is rarely diagnosed preoperatively and is usually mistaken for inguinal hernia, hematocele and hydrocele.

The ultrasound appearance can be variable and non-specific. It appears predominantly hyperechoic due to their predominate fat composition but have variable echogenicity because of variable amounts of internal soft-tissue septa and calcifications.^{6,7} CT features include mixed fat and soft tissue density areas with heterogenous contrast enhancement. MRI features of liposarcoma are macroscopic fat can be identified as regions of increased T1 and T2 signal intensity, with signal loss on fat-suppressed sequences.^{8,9} The tumour shows heterogeneous contrast enhancement.

The treatment of paratesticular liposarcoma is orchidectomy with excision of the mass.^{4,10} Later based on the grading of the tumour, though controversial, further management with radiation and chemotherapy is advised.¹¹ The local recurrence rate for high grade dedifferentiated tumours is about eighty percent.^{2,4} Follow up of these patients should be done for atleast 10 years.¹²

Conclusion:

Paratesticular liposarcoma is a rare tumor involving the spermatic cord. Diagnosis of the same is vital to the management and prognosis of the disease. Adequate surgical resection is required for improving prognosis of the patient. Recurrent tumor requires combination of surgery, chemotherapy and radiation for its management.

Ethical Approval:

As per international standard or university standard written ethical approval has been collected and preserved by the author(s).

Consent

As per international standard or university standard, patient(s) written consent has been collected and preserved by the author(s).

References:

1. Woodward PJ, Sohaey R, O'Donoghue MJ, Green DE. From the Archives of the AFIP: Tumors and Tumorlike Lesions of the Testis: Radiologic-Pathologic Correlation. *RadioGraphics*. 2002 Jan;22(1):189–216.
2. Londeree W, Kerns T. Liposarcoma of the Spermatic Cord Masquerading as an Inguinal Hernia. *Case Rep Med*. 2014;2014:735380.
3. Schwartz SL, Swierzewski SJ, Sondak VK, Grossman HBarton. Liposarcoma of the Spermatic Cord: Report of 6 Cases and Review of the Literature. *J Urol*. 1995 Jan;153(1):154–7.
4. Mokrani A, Guermazi F, Meddeb K, Hadj Kacem LB, Chakroun M, Yahyaoui Y, et al. Liposarcoma of the spermatic cord: A case report and review of literature. *Urol Case Rep*. 2018 Jul 12;21:19–20.
5. Ciongariu AM, Dumitru AV, Cîrstoiu C, Crețu B, Sajin M, Țăpoi DA, et al. The Conundrum of Dedifferentiation in a Liposarcoma at a Peculiar Location: A Case Report and Literature Review. *Medicina (Mex)*. 2023 May 17;59(5):967.
6. Cassidy FH, Ishioka KM, McMahon CJ, Chu P, Sakamoto K, Lee KS, et al. MR Imaging of Scrotal Tumors and Pseudotumors. *RadioGraphics*. 2010 May;30(3):665–83.
7. Alyousef H, Osman EM, Gomha MA. Paratesticular Liposarcoma: A Case Report and Review of the Literature. *Case Rep Urol*. 2013 Feb 28;2013:e806289.
8. Mittal PK, Abdalla AS, Chatterjee A, Baumgarten DA, Harri PA, Patel J, et al. Spectrum of Extratesticular and Testicular Pathologic Conditions at Scrotal MR Imaging. *RadioGraphics*. 2018 May;38(3):806–30.
9. Wolfman DJ, Marko J, Gould CF, Sesterhenn IA, Lattin GE. Mesenchymal Extratesticular Tumors and Tumorlike Conditions: From the Radiologic Pathology Archives. *RadioGraphics*. 2015 Nov;35(7):1943–54.
10. Chintamani, Tandon M, Khandelwal R, Jain S, Narayan N, Kumar Y, et al. Liposarcoma of the spermatic cord: a diagnostic dilemma. *JRSM Short Rep*. 2010 Nov 9;1(6):49.
11. Yoshida K, Nakamura E, Kawahara T, Inoue T, Sawazaki H, Kamba T, et al. [A case of myxoid liposarcoma in the right inguinal region: a case report]. *Hinyokika Kyo*. 2006 Sep;52(9):727–31.

12. Ballo MT, Zagars GK, Pisters PW, Feig BW, Patel SR, von Eschenbach AC. Spermatic cord sarcoma: outcome, patterns of failure and management. J Urol. 2001 Oct;166(4):1306–10.

UNDER PEER REVIEW