

Thrombotic microangiopathies secondary to anticancer treatment in patients receiving gemcitabine and anti-vascular endothelial growth factor: A case series study.

ABSTRACT

Thrombotic microangiopathy (TMA) secondary to anticancer drug exhibits varying clinical pathological presentation and severity, with variable response and prognosis upon discontinuation of the medication. We conducted a retrospective, monocentric, descriptive, and analytical study involving 7 patients with anticancer drug-induced TMA. The first group received anti-VEGF treatment, while the second group received gemcitabine. Five patients were treated with anti-VEGF (71.4%), and two patients received gemcitabine (28.6%). The mean age of patients in the anti-VEGF group was 68.8 ± 10.4 years, compared to 61.0 ± 5.6 years in the gemcitabine group. Only 28.6% had evidence of biological TMA at the time of diagnosis ($n=2$), exclusively in the gemcitabine group. During the acute phase, two patients required hemodialysis, both of whom were receiving gemcitabine. The mean time to death from the initial diagnosis was 6.5 ± 3.1 months. The primary cause of death was cancer progression. The overall mean survival was 25.42 ± 9.02 months, with 53 ± 3 months in the gemcitabine group and only 14.4 ± 7.99 months in the second group.

Key word : Thrombotic microangiopathy, Anti-Vascular endothelial growth factor, Gemcitabine

I INTRODUCTION

Thrombotic microangiopathy (TMA) is a histological syndrome characterized by the presence of mechanical hemolytic anemia, peripheral thrombocytopenia, schistocytes, haptoglobin consumption, and organ failure. Renal involvement is manifested by arterial hypertension and elevated serum creatinine, sometimes requiring hemodialysis. Histologically, TMA is characterized by thrombi formation in the terminal arterioles and capillaries.

TMA syndrome generally indicates severe life-threatening conditions. Therefore, it is crucial to recognize these pathologies for early diagnosis and prompt initiation of appropriate treatment. In oncology, TMA syndrome can complicate the progression of malignant tumors or their treatment, including chemotherapy or targeted therapies.

The main causes of drug-induced TMA are observed in the treatment with anti-vascular endothelial growth factor (anti-VEGF) agents, used in several solid tumors, and complications associated with gemcitabine, a nucleoside analogue extensively employed in France since 1996 for pancreatic cancer treatment and with expanding indications in oncology (lung, bladder, kidney tumors, lymphomas). The incidence of TMA during gemcitabine treatment ranges from 0.015% to 1.4% of cases.

Drug-induced TMA does not exhibit the same clinical and pathological presentation or severity degree, with variable responses and prognoses upon discontinuation of the medication. More recent agents leading to drug-induced TMA, such as anti-VEGF, frequently manifest as isolated renal TMA without associated hematological abnormalities. However, the clinical presentation is often more severe with gemcitabine, and acute renal failure can potentially be irreversible. Discontinuation of the medication may be the best option, as drug-induced TMA can result in severe and fatal complications.

Currently available anti-angiogenic drugs on the market include bevacizumab (Avastin), sunitinib (Sutent), and sorafenib (Nexavar). The primary anti-angiogenic mechanism of action of these three drugs is the pharmacological inhibition of the VEGF pathway. They are now used in patients with advanced colon, kidney, liver, breast, or lung cancer [1].

The renal glomerular filtration barrier consists of endothelial cells, podocytes, and components of the basement membrane. VEGF, expressed by podocytes during development and in adults, activates VEGFR-2 on glomerular capillary endothelial cells. The interaction between VEGF produced by podocytes and VEGFR2 on glomerular endothelial cells is crucial for normal function and repair of the system.

Bevacizumab is a humanized monoclonal antibody of the IgG1 type that selectively binds to human VEGF and neutralizes its biological activity. It exhibits a high affinity for an epitope present on all isoforms of VEGF, partially overlapping the binding sites of VEGFR-1 and VEGFR-2 receptors. This results in the inhibition of VEGF binding to these receptors on the surface of endothelial cells. The blockade of endothelial proliferation by bevacizumab hinders the neovascularization process necessary for tumor growth and dissemination.

Sorafenib is a multi-target tyrosine kinase inhibitor, primarily targeting VEGFR-2, VEGFR-3, platelet-derived growth factor receptor (PDGFR- β), and FLT3 (fms-related tyrosine kinase 3).

Regardless of their subclass, anti-angiogenic drugs commonly present vascular and nephrological tolerance profiles characterized by arterial hypertension and proteinuria.

The pathophysiology of gemcitabine-induced TMA remains uncertain, but endothelial lesions induced by the therapy likely lead to the release of von Willebrand factor multimers and platelet activation, followed by subsequent fibrinogenesis. These endothelial lesions can be attributed to the direct toxicity of gemcitabine or mediated by immune complexes.

My study focused on investigating the clinical and evolutionary characteristics of drug-induced TMA associated with anti-VEGF medications and gemcitabine.

II OBJECTIVE OF THE STUDY

The objective of this study is to investigate, compare, and analyze the epidemiological, clinical, paraclinical, therapeutic, evolutionary, and prognostic characteristics of two groups of patients with thrombotic microangiopathy induced by gemcitabine and those secondary to anti-VEGF treatment.

III MATERIALS AND METHODS

This is a retrospective, monocentric, descriptive, and analytical study involving 7 patients with drug-induced thrombotic microangiopathy.

The first group consisted of patients receiving anti-VEGF treatment (5 cases), and the second group consisted of patients receiving gemcitabine (2 cases).

This study was conducted over a period of 5 years, from January 2017 to January 2022, at the Nephrology Department of Henri Mondor University Hospital in Paris. The data were recorded from hospitalization and outpatient consultation reports using the ORBIS computer software.

All the data were entered into an Excel spreadsheet, and statistical analyses were performed using IBM SPSS® 20 statistical software.

IV RESULTS

IV.1 Epidemiological Characteristics

In this study, 7 patients with secondary TMA were included, with an average follow-up duration of 21 months. Among them, 5 patients were receiving anti-VEGF treatment (71.4%), while only 2 patients were receiving gemcitabine (28.6%).

The mean age of patients at the time of diagnosis was 68.8 ± 10.4 [60.86] years in the anti-VEGF group and 61.0 ± 5.6 [57.65] years in the gemcitabine group.

Their main medical history is presented in Table 1. The adjuvant anti-VEGF treatments used were predominantly bevacizumab 80% of cases (n=4). The different types of cancers and their treatments are listed in Table 1.

Table 1: Different types of cancers and their treatments

Cancer Types	Number (n)	Frequency (%)	Treatment
Colon Adenocarcinoma	2	28.6	Bevacizumab/Aflibercept
Breast Adenocarcinoma	1	14.3	Gemcitabine
Clear Cell Renal Carcinoma	1	14.3	Sunitinib
Rectal Adenocarcinoma	1	14.3	Bevacizumab Apatinib
Pleural Mesothelioma	1	14.3	Bevacizumab
Pancreatic Adenocarcinoma	1	14.3	Gemcitabine

IV.2 . Clinical and Biological Characteristics at Diagnosis

Renal involvement was characterized by proteinuria in all patients in both groups. Hematuria was more frequent in the gemcitabine group, with 100% (n=2) compared to 20% in the anti-VEGF group (n=1), although this difference was not statistically significant (p=0.121).

Only 28.6% of all patients had evidence of biological thrombotic microangiopathy at the time of diagnosis (n=2), exclusively in the group of patients receiving gemcitabine. There was a strong positive correlation between gemcitabine treatment and the presence of biological thrombotic microangiopathy (p=0.008).

The main laboratory parameters at admission are presented in the table below.

Table 2: Main Laboratory Parameters at Admission

Data	Patients receiving anti-VEGF: (n=5)	Patients receiving gemcitabine (n=2)	p
Average time between the onset of symptoms and medical intervention (days)	36.6 ± 33.28	12 ± 2.82	0.108
Average time between the start of anticancer treatment and renal involvement (months)	13.4 ± 9.5	12 ± 7.07	0.185
Hypertension at admission (%)	80%	100%	0.121
Biological evidence of thrombotic microangiopathy (TMA) (%)	-	100%	
Biological data:			
Creatinine (µmol/L)	158.8 ± 73.8	459.8 ± 107.4	0.007
eGFR (ml/min/1.73 m ³)	48.8 ± 23.6	11.21 ± 3.2	0.087
Baseline creatinine (µmol/L)	89.2 ± 26.7	100 ± 70.7	0.758
Hemoglobin (g/dL)	11 ± 2.94	7.5 ± 0.7	0.191

Platelets (Giga/L)	227.8±105	17 ±1.41	0.045
Schistocytes (%)	20%	100%	0.053
Haptoglobin (g/L)	1.86 ± 0.6	<0.1	0.012
Lactate dehydrogenase	313.4 ± 110	2875 ± 350	0.0001

The initial creatinine at diagnosis was significantly higher in the group of patients receiving gemcitabine

As part of the etiological assessment of TMA:

- The evaluation of ADAMTS13 activity was systematically performed upon the appearance of biological markers of TMA, particularly in the 2 cases in the gemcitabine group, which were >10% in both cases.
- Both patients receiving gemcitabine had negative findings for abnormalities in the alternative complement pathway and genetic complement abnormalities.

IV.3 Histological characteristics

The different histopathological lesions observed under light microscopy are detailed in Table 3. Unfortunately, no statistically significant correlation was found between the histopathological lesions in the two groups.

Table 3: Different histopathological lesions observed under light microscopy

Histological Lesions under LM	Patients treated with anti-VEGF (n=5)	Patients treated with gemcitabine (n=2)	p
Number of glomeruli (mean)	23±12	10	0.005
Arteriolar thrombosis (%)	20	50	0.427
Glomerular thrombosis (%)	40	100	0.147
Apoptotic glomeruli	-	50	0.088
Mesangiolysis	60	100	0.290
Double contour	100	50	0.088
Enlarged podocytes	20	100	0.121
Myxoid arteritis	20	100	0.53
Interstitial fibrosis (%)			
<25%	80	50	0.427
25-50%	20	50	0.427
≥50%	-	-	

IV.4 Therapeutic Management

IV.4.1 Symptomatic Treatment:

One hundred percent of the patients in the gemcitabine group were treated with a calcium channel blocker using a self-pushing syringe. Only 40% of patients receiving anti-VEGF

treatmentwereretreatedwith a combination therapy of calcium channelblockers and angiotensin-converting enzyme inhibitors (n=2) at the time of diagnosis, while 40% did not have achange in treatment. During the acute phase, 2 patients requiredhemodialysis, accounting for 28.6% of cases. Both of these patients were in the gemcitabine group. Among the 2 dialyzed patients, 1 wassuccessfullyweaned off dialysisafter 12 hemodialysis sessions over a period of 27 days, while the other patient wastransitioned to chronicdialysis.

IV.4.2 EtiologicalTreatmentof TMA

- Cessation of Causative Treatment:

In all patients in ourseries, anti-cancertreatmentwaspermanentlydiscontinuedafterhistological confirmation of TMA diagnosis.

- Plasma Exchange:

Only in the gemcitabine group, 1 case wastreatedwith 5 plasma exchanges based on the suspicion of TTP (50%), whichwasdiscontinuedafter the diagnostic deviation (ADAMTS13 >10%).

- Eculizumab:

Eculizumabwasurgentlyinitiated in response to the development of biologicalsigns of TMA in the 2 patients receivinggemcitabine. The administered dose was 900 mg as a bolus everyweek for 4 weeks as an induction therapy, followed by 1200 mg as a bolus every 2 weeksuntilremission. The average duration of treatmentwas 3 ± 2.82 [1.5] months.

IV.5 Outcome

IV.5.1 TMA Progression:

In the gemcitabine group, a favorable progression of biological TMA signswasobservedin 100% of patients after correction of hypertension, with an average time of 2.5 ± 2.12 months.

IV.5.2 RenalFunctionEvolution:

In the gemcitabine group, 1 patient remaineddependent on dialysissince the initial diagnosis, and 1 patient wasweaned off dialysis but did not fullyrecover normal renalfunction. In contrast, in the anti-VEGF group, 60% of patients hadrecovered normal renalfunction, while 40% continued to have chronicrenalinsufficiency.

IV.5.3 TMA Recurrence:

Following the initial diagnosis, only one patient experienced a recurrence of biological TMA during follow-up, particularly in the gemcitabine group. The median time between the start of treatment and recurrencewas 3 months.

IV.5.4 Mortality:

A total of 4 patients in the cohort (57.1%) died, with 80% of deathsoccurring in the anti-VEGF group (n=4), while no deathswereobserved in the gemcitabine group. The median time from initial diagnosis to deathwas 6.5 ± 3.1 months [4,11]. The main cause of deathwasrelated to the progression of cancer.

IV.5.5 Overall Survival of Patients:

The mean overall survival was 25.42 ± 9.02 months, with 53 ± 3 months in the gemcitabine group and only 14.4 ± 7.99 months in the anti-VEGF group. We observed that survival was lower in the anti-VEGF group compared to the gemcitabine group, and this difference in survival was statistically significant ($p=0.041$)

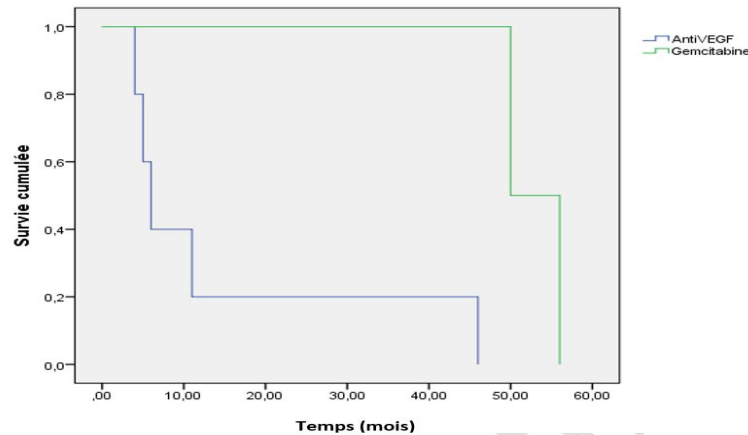


Figure 1: Patient Survival in the Two Groups: Gemcitabine and Anti-VEGF

V DISCUSSION

V.1 Epidemiological Data

Drug-induced TMA is more common than cancer-associated TMA. Clinically suspected drug-induced TMA has been well-documented in recent decades, although in the past, it likely accounted for 15% of cases overall. Currently, the incidence of drug-induced TMA from anticancer medications has increased and is higher than 15%, mainly due to the introduction of anti-vascular endothelial growth factor (VEGF) agents [2].

Caspar et al. [3] linked TMA to gemcitabine therapy in a phase II trial of pancreatic cancer patients receiving this agent. The reported incidence of gemcitabine-associated TMA in the literature is very low, with an estimate of 0.015% [4].

In our study, the average age of patients was 68.8 years in the anti-VEGF group and 61 years in the gemcitabine group. The age difference between the two groups was not significant in the literature; a French study reported an average age of 59.8 years in patients receiving anti-VEGF [5], compared to an average of 61.5 years in patients receiving gemcitabine [6]. The indications for gemcitabine were dominated by pancreatic cancer (52.9%) [6], which is consistent with the findings of our study.

V.2 Clinical and Biological Manifestations

In our series, the mean time between the start of anticancer treatment and renal involvement was almost identical in both groups: 12 months in the gemcitabine group

and 13.4 months in the anti-VEGF group. In the literature, shorter intervals of 7 months [7] and 5.3 to 13.3 months [8] have been reported for gemcitabine-treated patients, and 6.87 to 7.18 months for anti-VEGF-treated patients [5].

Recent onset hypertension or exacerbation of known hypertension are key signs of TMA, which can appear well before hemolysis, thrombocytopenia, and acute renal failure. In our series, the time between symptom onset and management was shorter in gemcitabine-treated patients, with a mean delay of 12 days compared to 36.6 days in the anti-VEGF group, which is consistent with the literature [9].

This difference can be explained by the abrupt onset of anuric acute renal failure, hypertension, and biological evidence of TMA observed in gemcitabine-treated patients, unlike anti-VEGF-treated patients who often present with proteinuria and insidious progression of renal failure without regular nephrological evaluation. Therefore, systematic screening for these early signs of TMA and raising awareness among physicians could lead to earlier detection and prevention of TMA associated with gemcitabine or anti-VEGF treatment [10]. Renal involvement in TMA can vary widely, presenting as a moderate increase in creatinine preceded by mild proteinuria and microscopic hematuria, or it can manifest dramatically as an oliguric or anuric acute renal failure with sodium and water retention [11]. Proteinuria was found in 100% of patients in both groups in this retrospective analysis, which is consistent with literature data reporting 93% proteinuria in the Flombaum report [12]. In this study, we found a significant correlation between the occurrence or worsening of renal failure and gemcitabine treatment. Our results align with the literature, which shows a higher frequency of renal failure in gemcitabine-treated patients, occurring in 97.4% of cases [13], compared to 40% in anti-VEGF-treated patients [5]. In a 2016 study in Iceland, 31% of patients with anti-VEGF-induced TMA presented with proteinuria, with excretion of up to 1 g/24 hours, and half of the TMA cases were limited to the kidney [14]. Regarding gemcitabine-induced TMA, mild proteinuria and microscopic hematuria have been reported in up to 58% and 41% of patients, respectively [15]. Thus, the clinical and biological presentation of gemcitabine-induced or anti-VEGF-induced TMA remains heterogeneous. In contrast to our study, which found a strongly positive correlation between gemcitabine treatment and the occurrence of biological TMA ($p=0.008$).

V.3 Histology

A definitive diagnosis theoretically relies on renal biopsy, where deposits of glomerular and/or arteriolar fibrin are detected using immunofluorescence techniques [16]. Localized renal TMA is more common with anti-VEGF agents and can develop in the absence of typical hematological abnormalities. Cases have been described in which localized TMA was diagnosed by renal biopsy and subsequently progressed to other organs [17]. The morphological appearance of glomerular lesions in anti-VEGF-induced TMA at high doses is distinct and allows identification of specific glomerular lesions resulting from the action of anti-VEGF agents on the glomerulus. It exhibits endothelial swelling, with highly distended endothelial cells protruding into the capillary lumen, as well as mesangiolysis characterized by swollen endothelial cells within the edematous, fibrillar extracellular mesangial matrix, accompanied by the loss of mesangial nuclei. The vessel walls show "double contours" with a clear space, and capillary lumens are reduced [18]. Capillary lumens are often congested and filled with red blood cells. Platelet or fibrin thrombi obstructing capillary lumens or preglomerular arterioles may also be observed. Immunofluorescence typically reveals little or no deposits, with fibrin and C3 observed in glomerular or arteriolar thromboses.

The histological appearance of gemcitabine-induced TMA is characterized by thickening of the glomerular capillary walls with double contours, indicating the presence of two distinct walls with a clear space between them. Capillary or glomerular arteriole thrombosis may also be present. Mesangial fibrosis and edema of the mesangial matrix are frequently observed, which can lead to a dissolution known as "mesangiolysis" [19].

Vascularendothelial lesions are considered the stimulus for capillary and arteriolar thrombosis and are responsible for TMA. Immunofluorescence studies may show fibrin deposits in vessels and glomeruli, as well as granular deposits of C3 and IgM.

In a French study, it was reported that half of the cases of TMA were limited to the kidneys without biological evidence of TMA. There were differences in the histopathological characteristics of TMA between those induced by anti-VEGF drugs, which showed exclusive glomerular thrombosis, and those induced by other causes of TMA, including gemcitabine, which had a pattern of capillary, arteriolar, and glomerular thrombosis [20]. These findings are consistent with our study, although the difference was not statistically significant. Furthermore, the remaining histopathological lesions, apart from arteriolar and glomerular thrombosis, were nonspecific and did not show a significant correlation with different pathological lesions or types of anticancer treatment.

V.4 Management

The understanding of the pathophysiology of gemcitabine-induced TMA remains unclear [21]. Similar to TMA induced by other chemotherapies (such as mitomycin C), endothelial lesions caused by the treatment are likely responsible for the release of von Willebrand factor multimers and platelet activation, leading to fibrin generation. These endothelial lesions could be due to the direct toxicity of gemcitabine or mediated by immune complexes [22]. This latter hypothesis has led some authors to propose rituximab as a treatment for gemcitabine-induced TMA [23]. Deficiency of ADAMTS-13, which is responsible for thrombotic thrombocytopenic purpura, is exceptionally identified in gemcitabine-induced TMA (13%) [24]. Although the involvement of complement in this type of TMA has not been extensively explored, its known role in endothelial protection and the pathophysiology of atypical hemolytic uremic syndrome (aHUS) has led to the use of eculizumab as a treatment for refractory gemcitabine-induced TMA [26].

To date, there is no consensus on the treatment of gemcitabine-induced TMA. Discontinuation of gemcitabine is essential. Platelet transfusion is not recommended, similar to therapeutic recommendations for thrombotic thrombocytopenic purpura. There is limited data on the efficacy of corticosteroid therapy. The use of plasma exchange (PE) in the treatment of gemcitabine-induced TMA is debated. A literature review conducted in 2009 based on 34 cases showed that among 26 patients with gemcitabine-induced TMA not treated with PE, 14 (56%) showed improvement, and 10 (38%) required dialysis. Among the 18 patients treated with PE, 6 (30%) improved, and 11 (61%) required dialysis [28].

Our management approach aligns with the literature, which involved discontinuing gemcitabine in all patients in our series. Eculizumab treatment was administered to the two cases with evidence of TMA, and plasma exchange was performed when there was suspicion of ADAMTS-13 deficiency, which was stopped after ruling out the diagnosis.

Regarding TMA induced by anti-VEGF drugs, immediate discontinuation of the implicated medication and effective control of blood pressure with renin-angiotensin inhibitors are universally considered imperative and maybe the most important step in treatment. Reintroduction of the medication at lower doses can be a useful strategy to prevent recurrence of TMA while allowing continuation of antitumor treatment. However, selecting an appropriate dose for reintroduction in cases of dose-dependent chemotherapy toxicity can be challenging [29].

In our series, for patients treated with anti-VEGF drugs, management involved discontinuation of the implicated medication and oral control of hypertension.

Regarding blood pressure control, several studies have reported that hypertension is more severe in patients receiving gemcitabine and requires intense therapeutic management [30]. This finding is consistent with our study results, although not statistically significant. Additionally, in our series, acute-phase hemodialysis was noted only in the gemcitabine group, while none of the patients receiving anti-VEGF drugs required dialysis. There was a strongly positive correlation between gemcitabine treatment and the need for hemodialysis, making gemcitabine treatment a risk factor for developing severe renal involvement requiring dialysis. This is consistent with the findings of a French study with a series of 58 patients receiving anti-VEGF drugs, where none of the patients developed severe renal failure requiring dialysis [5]. However, cases of patients developing acute kidney injury requiring hemodialysis have been reported [31]. Conversely, among patients receiving gemcitabine, 27.8% required dialysis in the series described by Daviet et al. [32].

V.5 Evolution

Our results are consistent with various studies that have shown that renal prognosis remains preserved with blood pressure control and discontinuation of anti-VEGF medication. These results have allowed differentiation between TMA related to VEGF inhibitors and other iatrogenic TMA [33]. The prognosis of chemotherapy-induced TMA is clearly poor, with reported mortality rates of 40% to 90% in most studies [34]. This rate is similar to our findings, with a mortality rate of 57.1%. To a large extent, this poor prognosis is determined by the underlying malignancy, as chemotherapy-induced TMA often occurs in advanced disease.

V.6 Study Limitations

This study has several limitations. Firstly, it is a retrospective and single-center study. The small sample size makes it challenging to compare our results with larger series. Furthermore, the follow-up period is not long enough to study long-term overall and renal survival. Therefore, further studies involving multicenter data are needed to improve the validity of our study.

VI CONCLUSION

Chemotherapy and targeted therapies remain essential treatments for several tumors. This study has shown that TMA induced by anticancer treatments is a serious condition that affects renal and overall prognosis, particularly gemcitabine-induced TMA, which is associated with more severe hematological and renal involvement than TMA secondary to anti-VEGF drugs. The increasing number of patients receiving gemcitabine and anti-VEGF drugs, as well as the severity of their renal complications, justifies close and regular monitoring by a nephrologist. Any worsening of anemia, thrombocytopenia, elevated lactate dehydrogenase (LDH) or serum creatinine, clinical deterioration with hypertension, dyspnea, peripheral edema, neurological signs, or hematuria should prompt careful evaluation and prompt discontinuation of anticancer treatment.

This study has identified a difference between the two patient groups, with gemcitabine-induced TMA showing a more abrupt and severe clinical presentation, more severe renal involvement with dialysis requirement, and an unfavorable prognosis. However, it is necessary to supplement this work with data from a larger number of patients and longer follow-up.

VII REFERENCES

1. Hurwitz H, Fehrenbacher L, Novotny W, et al. Bevacizumab plus irinotecan, fluorouracil, and leucovorin for metastatic colorectal cancer. *N Engl J Med* 2004;350:2335
2. HassanIzzedineMD, Ph.D.1Marque A. PerazellaMD2 *American Journal of Kidney Diseases*, novembre 2015,
3. Caspar ES, Green M, Kelsen DP, et al. Phase II trial of gemcitabine (2,2'-difluorodeoxycytidine) in patients withpancreaticadenocarcinoma, *Investing in new drugs*, 1994, vol. 12 (pp. 29-34)
4. fun MC, Storniolo A M, Nguyen B, Arning M, Brookfield O, Veillée J. A review of hemolyticuraemic syndrome in patients treatedwithgemcitabine, *Cancer*, 1999, vol. 85 (pp. 2023-2032)
5. Hassan Izzedine, Melanie Mangier, Virginie Ory, Shao-Yu Zhang, DjillaliSahali, Expression patterns of RelA and c-mip are associated with different glomerular diseases following anti-VEGF therapy, 2013 *International Society of Nephrology*
6. Florence Daviet, Franck Rouby, Pascale Poullin, Noémie Jourde-Chiche, *Microangiopathie thrombotique associée à l'utilisation de la gemcitabine : présentation et résultats dans une cohorte nationale rétrospective Français*, Février 2019)
7. Walter RB, Joerger M, Pestalozzi BC. Gemcitabine-associated hemolytic-uremic syndrome. *Am J Kidney Dis*. 2002;40(4):e16.1-e16.6
8. Zupancic M, Shah PC, Shah-Khan F, et al. Gemcitabine-associated thrombotic thrombocytopenic purpura. *Lancet Oncol*. 2007;8(7):634–641.
9. Humphreys BD, Sharman JP, Henderson JM, et al. Gemcitabine-associated thrombotic microangiopathy. *Cancer*. 2004;100(12):2664-70
10. Glezerman I, Kris MG, Miller V, et al. Gemcitabine nephrotoxicity and hemolytic uremic syndrome: report of 29 cases from a single institution. *Clin Nephrol*. 2009;71(2):130 9.
11. CitarrelleP, Gebbia V, Thérèse M, et coll. Syndrome hémolytique et urémique après chimiothérapie par gemcitabine et taxotère : à propos d'un cas, *Rés anticancéreux*, 2002, vol. 22 (p. 1183-1185)
12. Flombaum CD. Néphrotoxicité de la gemcitabine et syndrome hémolytique et urémique (SHU): rapport de 29 cas d'un seul établissement. SA-PO1008 ASN 2005
13. Melanie Zupancic 1, Prabodh C Shah, Farheen Shah-Khan Gemcitabine-associated thrombotic thrombocytopenic purpura *Lancet Oncol*. 2007 Jul
14. Izzedine H, Escudier B, Lhomme L, et al. Anti-VEGF associated kidney diseases: an 8-year monocentric observational study. *Medicine (Baltimore)*. 2014;93:333-339.
15. Green MR: Gemcitabine safety overview. *SeminOncol*23:S32-S35
16. Fun MC, Storniolo UN M, Nguyen B, Arning M, Brookfield O, Veillée J. Une revue du syndrome hémolytique et urémique chez les patients traités par la gemcitabine, *Cancer*, 1999, vol. 85 (p. 2023-2032),
17. Pham PT, Ping UN, Wilkinson Ah, et coll. Microangiopathie thrombotique associée à la cyclosporine et au tacrolimus, *Suis J Kidney Dis*, 2000, vol. 36 (p. 844-850)
18. Frangie´ C, Lefaucheur C, Medioni J, et al. Renal thrombotic microangiopathy caused by anti-VEGFantibody treatment for metastatic renal-cell carcinoma. *Lancet Oncol*2007;8:177
19. Lakkis FG, Campbell OC, Badr KF : *Maladies microvasculaires du rein*, dans Brenner BM (ed) : *The Kidney* (ed 5), chap 35. Philadelphia, PA, Saunders, 1996, pp 1712-1730 1
20. Hassan Izzedine, MD, PhD,1 and Mark A. Perazella, MD *Thrombotic Microangiopathy*, *Cancer, and Cancer Drugs 2015 by the National Kidney Foundation, Inc*
21. Fung MC, Storniolo AM, Nguyen B, Arning M, Brookfield W, Vigil J. A review of hemolytic uremic syndrome in patients treated with gemcitabine therapy. *Cancer* 1999;85:2023–32.
22. Flombaum CD, Mouradian JA, Casper ES, Erlandson RA, Benedetti F. Thrombotic microangiopathy as a complication of long-term therapy with gemcitabine. *Am J Kidney Dis* 1999;33:555–62.

23. Murugapandian S, Bijin B, Mansour I, Daheshpour S, Pillai BG, Thajudeen B, et al. Improvement in gemcitabine-induced thrombotic microangiopathy with rituximab in a patient with ovarian cancer: mechanistic considerations. *Case Rep Nephrol Dial* 2015;5:160–7.
24. Zupancic M, Shah PC, Shah-Khan F, Nagendra S. Gemcitabine-associated thrombotic thrombocytopenic purpura. *Lancet Oncol* 2007;8:634–41.
25. Salvadori M, Bertoni E. Update on hemolytic uremic syndrome: diagnostic and therapeutic recommendations. *World J Nephrol* 2013;2:56–76.
26. Starck M, Wendtner CM. Use of eculizumab in refractory gemcitabine-induced thrombotic microangiopathy. *Br J Haematol* 2013;164:894–6.
27. Scully M, Hunt BJ, Benjamin S, Liesner R, Rose P, Peyvandi F, et al. Guidelines on the diagnosis and management of thrombotic thrombocytopenic purpura and other thrombotic microangiopathies. *Br J Haematol* 2012;158:323–35.
28. Lhotta K, Kühr T, Rumpelt HJ, Wöll E, Thaler J, König P. Thrombotic microangiopathy with renal failure in two patients undergoing gemcitabine chemotherapy. *Am J Nephrol* 1999;19:590–3.
29. Hassan Izzedine, MD, PhD, 1 and Mark A. Perazella, MD2, Thrombotic Microangiopathy, Cancer, and Cancer Drugs, 2015 by the National Kidney Foundation.
30. Xavier Charmetant a, *, Anne Jolivota , Sandrine Lemoine c , Laurent Juillard, Gemcitabine-induced thrombotic microangiopathy: Can we improve screening and treatment? de´ cembre 2016
31. *Clin Nephrol* 2021 Jul;96(1):51-59. doi: 10.5414/CN110443
32. Florence Daviet, Franck Rouby, Joëlle Micallef, Noémie Jourde-Chiche, Thrombotic microangiopathy associated with Gemcitabine use: presentation and outcome in a national French retrospective cohort. – *BJ of Clinical Pharmacology* – 2018
33. Arun P, Brown MS, Ehsanian R et al. Nuclear NF-kappaB p65 phosphorylation at serine 276 by protein kinase A contributes to the malignant phenotype of head and neck cancer. *Clin Cancer Res* 2009; 15: 5974–5984)
34. Melnyk UN M, Solez K, Kjellstrand CM. Syndrome hémolytique et urémique de l'adulte. Un examen de 37 cas, *Arch Stagiaire Med*, 1995, vol. 155 (p. 2077-2084)