

Case study

Atypical presentations of progressive disseminated histoplasmosis in an immunocompetent adult: Ectopic calcification (Aneurysm of Sinus of Valsalva) and large vessel (left subclavian artery) stenosis in the background of adrenal insufficiency.

ABSTRACT:

Histoplasmosis is a systemic fungal disease caused by the dimorphic fungus *Histoplasma capsulatum* and is more common in immunocompromised patients. Histoplasmosis can present with a wide range of clinical manifestations from asymptomatic illness to severe organ dysfunctions and may need hospitalization. Histoplasmosis is a major opportunistic infection in North and Central America. Disseminated histoplasmosis is a progressive extrapulmonary infection, caused by hematogenous spread, mostly found in immunosuppressed patients.

Reports of histoplasmosis in nonendemic regions are very rare. Due to the varied and nonspecific clinical manifestations of histoplasmosis, most of the infections are misdiagnosed or underreported.

Here, we report a case of disseminated histoplasmosis in an immunocompetent individual from a non-endemic zone in eastern India, presented with long term fever along with ectopic calcification (Aneurysm of Sinus of Valsalva) and large vessel (left subclavian artery) stenosis in the background of adrenal insufficiency.

KEYWORDS:

Adrenal Insufficiency, Aneurysm of Sinus of Valsalva, Ectopic Calcification Large Vessel (Left Subclavian Artery) Stenosis, Progressive Disseminated Histoplasmosis (PDH)

INTRODUCTION:

Histoplasmosis is a systemic fungal infection caused by the dimorphic fungi *Histoplasma capsulatum* (1). It is most common in the Midwestern and Central United States, along with Ohio and Mississippi River Valleys (2). It occurs most commonly among individuals from non-endemic region who travel to endemic areas. In the environment it exists as mold, microconidia, and macroconidia form, whereas in human tissue it exists as yeast form. Inhalation of macroconidia and microconidia from the soil infected with bird dropping which act as the reservoir for the fungi, results in the pathogenesis (1). The Immunocompromised individuals especially the HIV-infected peoples are easy to infect with *H capsulatum* (3). Occasionally, Immunocompetent patients are also infected with *H capsulatum*, which is usually presented with nonspecific clinical manifestations such as prolonged fever, weight loss, oropharyngeal ulcers, hepatosplenomegaly, and lymphadenopathy (4).

Progressive disseminated (PDH), which is more common in immunocompromised patients such as those with HIV infection, usually presents with fever, malaise, hepatosplenomegaly, and lymphadenopathy, pancytopenia, disseminated intra vascular coagulation, skin lesions, gastrointestinal manifestations like diarrhoea and vomiting, CNS features like encephalopathy and focal parenchymal lesions, renal failure, and adrenal insufficiency (5).

Here, we report a rare case of progressive disseminated histoplasmosis in an immunocompetent individual presented with atypical manifestations of long-term fever along with ectopic calcification (Aneurysm of Sinus of Valsalva) and large vessel (left subclavian artery) stenosis in the background of adrenal insufficiency.

CASE REPORT:

A 40-year-old male, residing in a village of West Bengal, without any known comorbidity presented with low grade intermittent fever for 3 months. He developed some erythematous lesions over the nape of the neck and face for the same duration. He also complained light-headedness or dizziness when standing from sitting or lying down position. Last 20 days prior to admission, he experienced progressive oliguria. He also gave history of significant weight loss over the last 3 months. Physical examination revealed moderate pallor and multiple erythematous papules over the nape of neck and face. He also had

hyperpigmented palmar creases and tongue. (**Figure 1A&B**). Others systemic examinations were unremarkable except he had low blood pressure (90/50mmHg) with postural drop.

Complete hemogram parameters were within normal limits except he had moderate anaemia (8.5gm/dl). Inflammatory markers were raised (ESR 90mm/hour, CRP 40IU/L, Ferritin 480 ug/L). Serological tests for HIV, HBV and HCV were negative. Renal function test revealed raised levels of serum urea (56 mg/dL) and serum creatinine (2.58 mg/dL) with mild proteinuria on routine urine analysis was found. 24 hours urinary protein was 1.25gm/day. He had hypercalcemia (corrected serum calcium 12.3mg/dl) with normal serum iPTH and 25OH vitamin D3.

On the day after the admission the patient was landed up in shock with BP 50/40mmHg. Adrenal failure was suspected (based on hyperkalemia and hyponatremia on ABG) and patient was managed accordingly with intravenous hydrocortisone and fluid (0.9%NS).Subsequently, Serum cortisol was come to be very low (<1.2 ug/dl) with corresponding ACTH was very high (> 1250pg/ml), which further confirmed he had primary adrenal failure. USG whole abdomen revealed bilateral enlarged adrenal gland with raised cortical echogenicity of bilateral kidney. CECT whole abdomen showed bilateral adrenal hyperplasia with adrenal hemorrhage (**Figure 2A&B**). Due to presence of AKI and proteinuria, kidney biopsy was done, which revealed chronic tubulointerstitial nephritis.

In the background of chronic low-grade fever with erythematous papules, hypercalcemia, chronic tubulointerstitial nephritis and primary adrenal failure, systemic chronic inflammatory granulomatous diseases (like disseminated histoplasmosis, tuberculosis, sarcoidosis, autoimmune adrenalitis) were suspected. To confirm the diagnosis, CT guided true cut biopsy was done from adrenal gland. Disseminated tuberculosis was excluded by negative sputum AFB stain, CBNAAT of sputum and adrenal tissue. To rule out sarcoidosis, we did serum ACE level and CT chest, but all were noncontributory. Condition of the patient gradually was deteriorating , for lifesaving purpose, the patient was treated empirically with liposomal amphotericin B (3mg/kg) along with hydrocortisone (200mg/day) and IV fluid (0.9% NS). In the meantime, adrenal histopathology report was awaited.

On subsequent days, during admission, the patient developed claudication, tingling and numbness of left upper limb digits. On examination, feeble pulse at left brachial artery and left radial artery along with unrecordable blood pressure of left arm was found, but other peripheral pulses were palpable. USG color doppler of bilateral upper limb showed reduced blood flow in the left brachial, radial, and ulnar artery. For further better evaluation, CT Angiogram of aorta and upper limb arterial system was done, which showed severe focal narrowing of the left subclavian artery (**Figure 3A**) with calcific cavitory lesion arising from aortic sinus of ascending aorta. To better delineate this calcific cavitory lesion, cardiac CT scan was done which showed large sized lobulated cavitory lesion (55×55 mm) extending into the left ventricle basal region anteroseptal wall; diffuse junky wall calcification of this cavitory lesion, it appears to be arising from aortic sinus of Valsalva (**Figure 3B**).

Adrenal gland histopathology showed necrotic tissue and fibro collagenous tissue infiltrated by histocytes and inflammatory cells. Oval yeast like PAS positive fungal bodies is seen in some macrophages. Collection of macrophages forming ill-defined granuloma are also seen compatible with histoplasma (**Figure 4A&B**). After 2 weeks of liposomal amphotericin B, the patient was put on oral itraconazole(200mg) twice daily. Subsequently, for primary adrenal failure he was treated with oral fludrocortisone (50mcg/day) & oral hydrocortisone (25mg /day). The patient was improved gradually with respect to clinical and biochemical parameters.

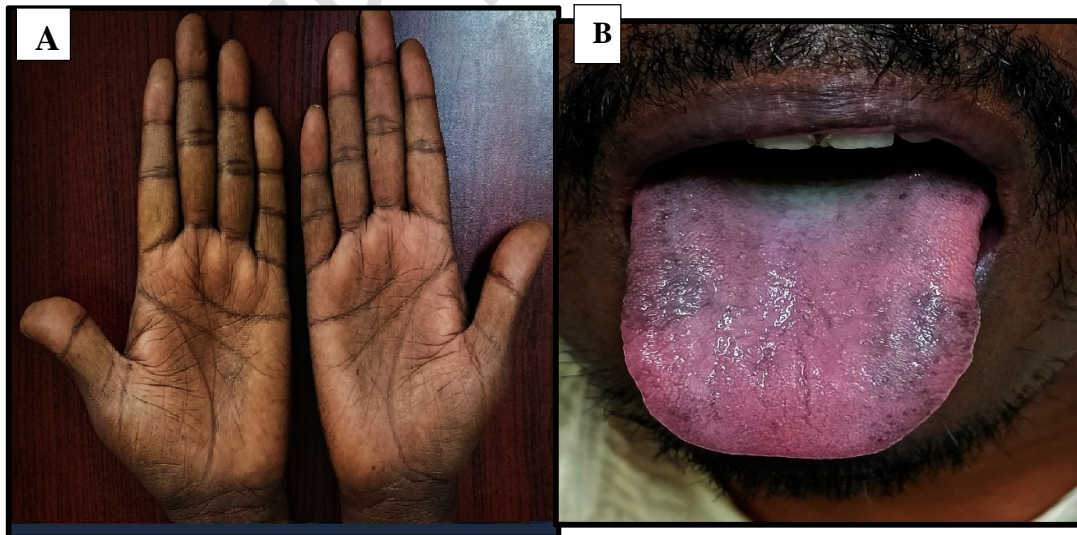


Figure 1: A) Showing hyperpigmentation of Palmar creases primary adrenal failure. B) Showing hyperpigmentation of tongue.

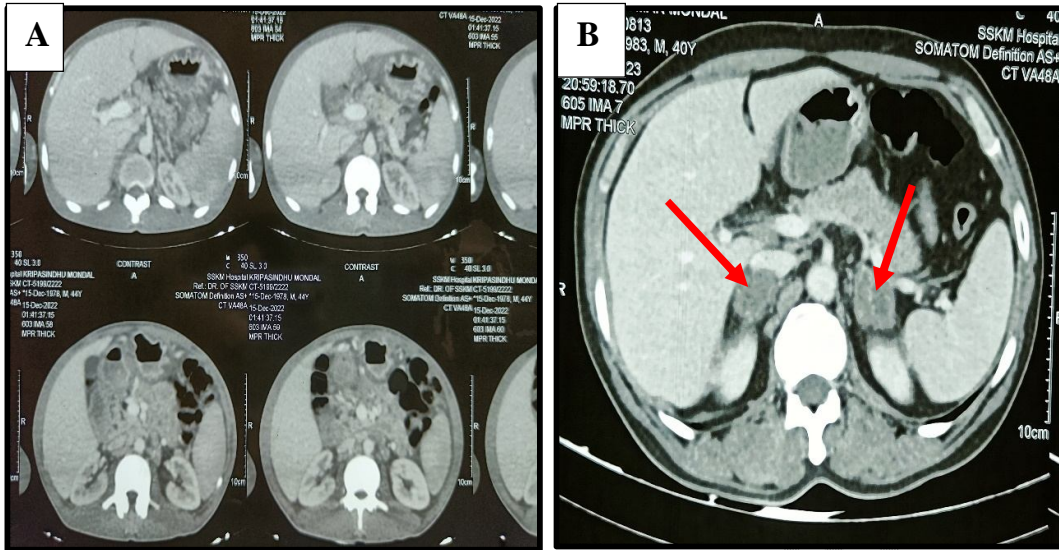


Figure 2 (A&B): CECT Whole Abdomen showing bilateral adrenal hyperplasia with adrenal hemorrhage (Red Arrow in figure 2B).

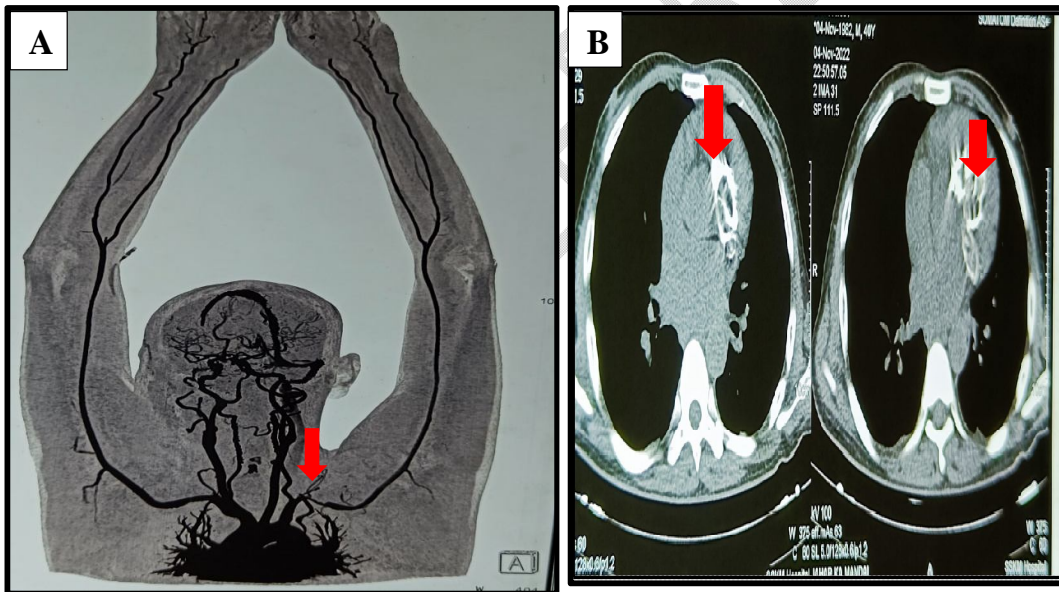


Figure 3 : A) CT angiogram of upper limb showing focal severe narrowing of left subclavian artery (red block arrow). B) Cardiac CT Showing wall calcification of Sinus of Valsalva Aneurysm (red block arrow)

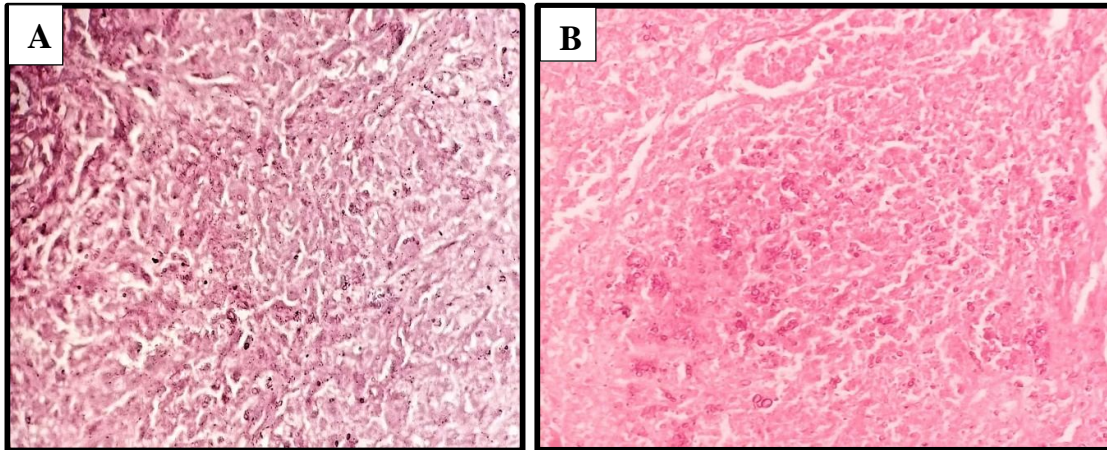


Figure 4 (A&B): (Adrenal Biopsy Sample): Shows necrotic tissue and fibro collagenous tissue infiltrated by histocytes and inflammatory cells. Oval yeast like PAS positive fungal bodies is seen in some macrophages. Collection of macrophages forming ill-defined granuloma are seen. (H&E, x400)

DISCUSSION:

Histoplasmosis is the systemic fungal infection. In India, histoplasmosis is not considered as an endemic disease, most cases reported from gangetic area of West Bengal and Uttar Pradesh (6). Disruption of the soil (activities like cleaning of chicken coops, bat-infested caves, excavation, demolition of old buildings, and cutting of dead trees) that contain the microorganism, lead to aerosolization of the microconidia and exposure of human nearby (5,6). In our case patient had history of exposure to construction activities of old house. Only less than one percent of the exposed individuals develop disease, and the extent of disease is determined by immune status of the host and level of exposure (5). Histoplasmosis can present with pulmonary and extrapulmonary manifestations or progressive disseminated histoplasmosis (PDH) (5).

The involvement of two or more sites by the fungus define the diagnosis of disseminated histoplasmosis (7,8). PDH may manifest as chronic disease in immunocompetent individuals (approximately 10%), and acute progressive disease in immunocompromised individuals (5). In our case, the patient was immunocompetent and had progressive involvement of skin (erythematous papules), adrenal gland (bilateral adrenal hyperplasia and adrenal hemorrhage),

kidney (tubulointerstitial nephritis) and vascular system in the form of ectopic calcification (Aneurysm of Sinus of Valsalva) and large vessel (left subclavian artery) stenosis.

The diagnosis of disseminated histoplasmosis requires a high index of suspicion, identification of the common modes of presentation, and proper diagnostic approach.

Diagnosis of PDH depends mainly on the histopathology of the biopsy from the affected tissue with sensitivity of 75-80% (3,9). Culture remains the gold standard for the diagnosis of histoplasmosis with sensitivity of 74%, however it may require up to 8 weeks (5). Measurement of histoplasma antigen in serum and urine is especially useful with sensitivity of around 94% and it can be used to monitor the response to therapy (8,10). In our case, biopsy specimens obtained from adrenal gland and demonstrated fungal elements by direct microscopy and PAS staining. So, histopathology remains an important diagnostic modality, as a positive result permits initiation of specific antifungal therapy.

Treatment of disseminated histoplasmosis is divided into two phases, an induction phase to achieve clinical remission and a maintenance phase to prevent relapse. Amphotericin B (3-5 mg/kg/day for 2 weeks) is the antifungal agent of choice for induction therapy followed by maintenance therapy with itraconazole (200 mg twice daily) is given for at least 12 months (5,8). In our case, the patients responded well to treatment as evidenced by marked clinical improvement on subsequent follow-up visits. Thus, PDH though uncommon, should be considered as a differential diagnosis in a case of fever of unknown origin in immunocompetent individuals belonging to non-endemic regions like India.

CONCLUSION:

Disseminated histoplasmosis poses a diagnostic challenge, due to its wide array of clinical manifestations, particularly in immunocompetent individuals. From this case we want to highlight the importance of a high index of clinical suspicion for disseminated histoplasmosis, whenever an immunocompetent patient presents with long term fever along with ectopic calcification and large vessel stenosis in the background of adrenal insufficiency, to prevent misdiagnosis and initiate early antifungal therapy.

Ethical Approval:

As per international standard or university standard written ethical approval has been collected and preserved by the author(s).

CONSENT:

Written informed consent was obtained from the patient for publication of this case report and accompanying images.

REFERENCE:

1. Mittal J, Ponce MG, Gendlina I, Nosanchuk JD. Histoplasma Capsulatum: Mechanisms for Pathogenesis. *Curr Top Microbiol Immunol*. 2019; 422:157-191. doi: 10.1007/82_2018_114. PMID: 30043340; PMCID: PMC7212190.
2. Baddley JW, Winthrop KL, Patkar NM, Delzell E, Beukelman T, Xie F, Chen L, Curtis JR. Geographic distribution of endemic fungal infections among older persons, United States. *Emerg Infect Dis*. 2011 Sep;17(9):1664-9. doi: 10.3201/eid1709.101987. PMID: 21888792; PMCID: PMC3322071.
3. Ling Q, Zhu W, Lu Q, Jin T, Ding S. Disseminated histoplasmosis in an immunocompetent patient from an endemic area: A case report. *Medicine (Baltimore)*. 2018 Jul;97(29): e11486. doi: 10.1097/MD.00000000000011486. PMID: 30024525; PMCID: PMC6086525.
4. Adamian CMC, de Lima Mota MA, Martins AAF, Aragão MC, Carvalho MS, Meneses GC, Silva Júnior GBD, Leitão TDMJS, De Francesco Daher E. Progressive disseminated histoplasmosis in HIV-positive patients. *Int J STD AIDS*. 2022 May;33(6):544-553. doi: 10.1177/09564624221076605. Epub 2022 Mar 28. PMID: 35343333.
5. Samaddar A, Sharma A, Kumar Ph A, Srivastava S, Shrimali T, Gopalakrishnan M, Bohra GK. Disseminated histoplasmosis in immunocompetent patients from an arid zone in Western India: A case series. *Med Mycol Case Rep*. 2019 Aug 1; 25:49-52. doi: 10.1016/j.mmcr.2019.07.012. PMID: 31453079; PMCID: PMC6702145.
6. Randhawa H.S., Gugnani H.C. Occurrence of histoplasmosis in the Indian Sub-Continent: an overview and update. *J. Med. Res. Pract*. 2018; 7:71–83
7. De D, Nath UK. Disseminated Histoplasmosis in Immunocompetent Individuals- not a so Rare Entity, in India. *Mediterr J Hematol Infect Dis*. 2015 Apr 20;7(1): e2015028. doi: 10.4084/MJHID.2015.028. PMID: 25960856; PMCID: PMC4418405.
8. Baudhha NK, Jadon RS, Mondal S, Vikram NK, Sood R. Progressive disseminated histoplasmosis in an immunocompetent adult: A case report.

Intractable Rare Dis Res. 2018 May;7(2):126-129. doi:

10.5582/irdr.2018.01022. PMID: 29862155; PMCID: PMC5982620.

9. Kauffman CA. Histoplasmosis: a clinical and laboratory update. Clin Microbiol Rev. 2007 Jan;20(1):115-32. doi: 10.1128/CMR.00027-06. PMID: 17223625; PMCID: PMC1797635.
10. Theel ES, Ramanan P. Clinical significance of low-positive histoplasma urine antigen results. J Clin Microbiol. 2014 Sep;52(9):3444-6. doi: 10.1128/JCM.01598-14. Epub 2014 Jul 16. PMID: 25031433; PMCID: PMC4313180.

UNDER PEER REVIEW