

Incidentally detected Morgagni diaphragmatic hernia : a case report

ABSTRACT

Congenital diaphragmatic hernia is a rare condition caused by a congenital defect in the diaphragm, leading to the protrusion of abdominal organs into the thoracic cavity. It can be isolated (in 40% of cases) or associated with other malformations. In 85% of cases, it is located postero-laterally (Bochdalek hernia), and less commonly antero-laterally (Morgagni and Larrey hernias).

We report the case of a patient presenting a Morgagni hernia, which is a rare hernia that accounts for 1 to 6% of diaphragmatic hernias, and is usually asymptomatic and often discovered incidentally.

We present the case of an infant born from a well-monitored pregnancy, delivered vaginally, with a normal birth weight of 3200 grams and a normal Apgar score, and no neonatal respiratory distress. The infant was discharged after 24 hours and remained in good health.

At 6 months of age, the infant presented with acute viral bronchiolitis, and an incidental discovery of an antero-lateral congenital diaphragmatic hernia was made through a chest X-ray. The patient was stabilized and referred to the pediatric surgery department for management after successful treatment of the bronchiolitis.

Key words: Morgagni diaphragmatic hernia, congenital diaphragmatic hernia, chest radiography.

1. INTRODUCTION:

Congenital diaphragmatic hernia (CDH) occurs when the pleuroperitoneal duct fails to close properly during fetal development. with a global prevalence reported at 2.3 per 10,000 births, and most cases being diagnosed prenatally or neonatally due to severe, life-threatening respiratory distress [1,2], However, when CDH presents only in adulthood, it is usually an incidental finding without clinical significance [3]. Hernias of the right sternocostal hiatus are called Morgagni hernias, described by Morgagni in 1761, while those of the left sternocostal hiatus are called Larrey's fissure hernias. If the opening is so large that it includes both hiatuses, they are called Morgagni-Larrey hernias. Usually, there is no clinical distinction between the two defects, and by extension, Morgagni hernia is used as a general term [3, 4].

2. PRESENTATION OF CASE:

The reported case involves a male infant from a non-consanguineous marriage, the pregnancy was well attended and carried to term, with the infant delivered vaginally and weighing 3200 grams, with

a normal Apgar score, without neonatal respiratory distress. After being discharged from the hospital 24 hours later, the infant remained healthy at home and had no history of trauma or falls.

At the age of 6 months, the infant presented with febrile respiratory distress, preceded three days earlier by viral prodromes. On clinical examination, the infant was found to be conscious, tonic, with a staturoponderal delay of -2 standard deviations (weighing 4 kg and measuring 56 cm in height). The infant was also polypneic, with a respiratory rate of 62 cycles per minute, tachycardic at 126 beats per minute, and with an SO₂ level of 92% in room air, associated with signs of respiratory struggle, made of sub-costal pulling, supra-sternal pulling with nasal wing flapping, and bilateral sibilant rales on auscultation.

A frontal chest X-ray showed a right apical atelectasis with a right antero-lateral colothorax [Fig. 1], and the thoracic radiography of profile revealed the colothorax in anterocardiac [Fig. 2].

Paraclinical workup found a blood count within normal limits and a negative C-reactive protein, but respiratory multiplex polymerase chain reaction (PCR multiplex) revealed a respiratory syncytial virus (RSV).

The infant was diagnosed with acute viral bronchiolitis on a congenital diaphragmatic Morgagni hernia terrain, and was treated with nasal decongestion, tracheobronchial aspiration, oxygen therapy, and good hydration.

The infant's condition improved favorably, he was stabilized before being referred to the pediatric surgery service for surgical management.

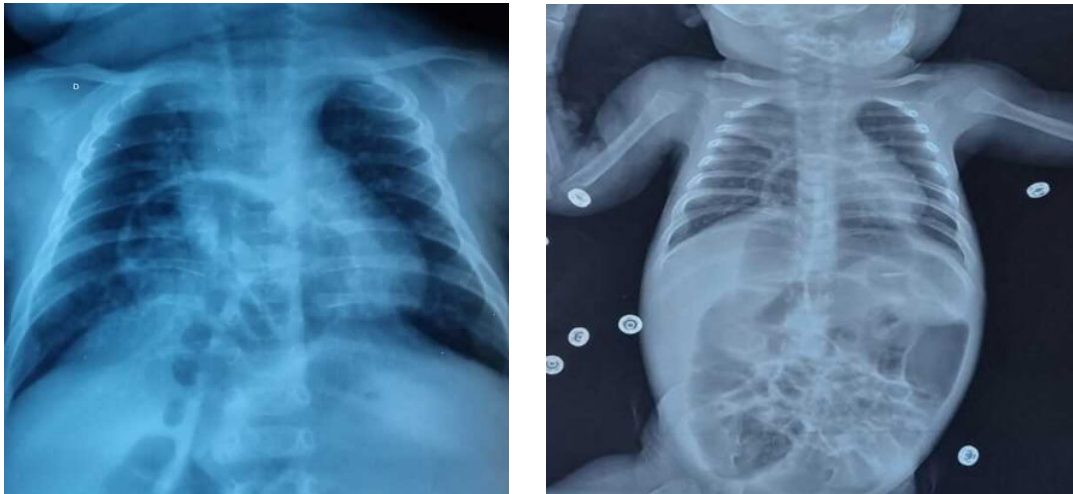


Fig.1 (a.b). A frontal chest X-ray showing a right apical atelectasis with a right antero-lateral colothorax through the hernia of Morgagni.

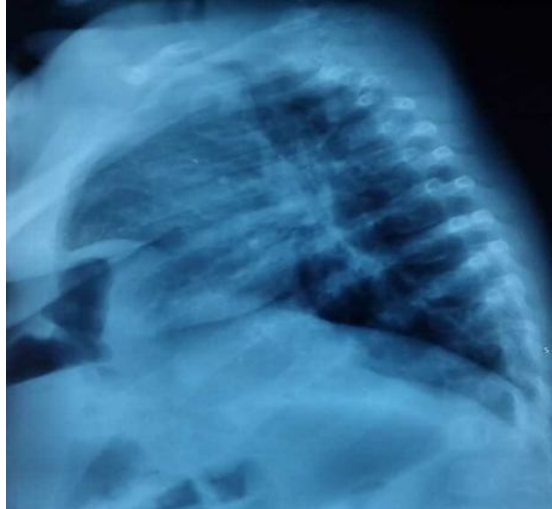

Fig.2. The lateral chest X-ray showing a colothorax in the anterior location to the heart.

3. DISCUSSION:

The congenital diaphragmatic hernia is a rare pathology, with a global prevalence reported at 2.3 per 10,000 births [5]. This condition is caused by a diaphragmatic defect that allows the peritoneal viscera to protrude into the pleural cavity [6]. It is usually diagnosed in neonates [1,2], where respiratory distress directly affects the prognosis, but when discovered later, respiratory and digestive symptoms are generally moderate and can be acute or chronic [7]. Sometimes it is asymptomatic, and the diagnosis is usually made after a thoracoabdominal X-ray. Surgical treatment is currently secondary after stabilizing patients with pulmonary arterial hypertension and/or hypoxia [5, 8]. Survival depends on associated malformations [9], diaphragmatic hernias can occur in a more general malformation context. Secondary malformations to the hernia such as intestinal malrotation, pulmonary or cardiac hypoplasia, syndromic or chromosomal lesion associations should be distinguished [9].

Diaphragmatic hernias are classified as Bochdalek hernias when they are posterolateral, often on the left but can sometimes be on the right, and as anterior or retrosternal-xiphoid hernias, which are rarer and called Morgagni hernias when the sterno-costal hiatus is on the right, and Larrey fissure hernias when the hiatus is on the left. If the opening is so large that it includes both hiatuses, they are called Morgagni-Larrey hernias. Usually, there is no clinical distinction between the two defects, and by extension, Morgagni hernia is used to refer to both [9, 10].

The formation of the diaphragm occurs from the fourth week to the third month of embryonic development. Initially, the three cavities, peritoneal, pleural, and pericardial, communicate. Then, the serous membranes are formed, and they are first simply adjacent. Starting from the eighth week, the space between the serous membranes is colonized by myoblastic tissue, leading to the formation of the diaphragm [11].

The different anatomical types of diaphragmatic hernias depend on the timing of embryonic development disorder. Thus, if it occurs before the sixth week, there is a complete absence of serous

membrane, and therefore, a hernia without a sac. If it occurs between the sixth and eighth week, after the adhesion of the serous membranes but before myoblastic colonization, it is a hernia with a sac (two serous membranes without muscle).

As for the diaphragm's musculature, it is composed of three parts [12]: a sternal part that is a large ventromedial portion of the transverse septum, a circumferential costal part, and a lumbar part. The hernia's location corresponds to the developmental defect of one of the anatomical portions of the diaphragm [13]. Thus, the retrosternal Morgagni hernia is located on the anterior part of the diaphragm, and the posterolateral hernia is located on its costal portion.

From a clinical point of view, while Bochdalek hernia presents rapidly and loudly with respiratory distress [14], Morgagni hernia is often asymptomatic at birth [15], but may sometimes manifest with epigastric or retrosternal discomfort or, less commonly, respiratory symptoms. Anterolateral hernia can be considered an intermediate form with symptoms between posterolateral and anterior hernia [9].

In the case of our patient, the Morgagni hernia was asymptomatic and incidentally discovered on a chest X-ray during a viral episode.

The differential diagnosis of diaphragmatic hernias includes anterior mediastinal tumors, pleuropericardial cysts, incomplete pneumothorax, pulmonary atelectasis, simple lipoma, and also interhepatodiaphragmatic colonic interpositions, bulges, and diaphragmatic hernias [16].

Given the potential risk of severe complications, albeit rare, surgical treatment is always recommended for Morgagni hernia, except in cases of asymptomatic hernia in an elderly and frail patient [17]. The main complications are intestinal obstruction, strangulated hernia, and perforation, which may present as peritonitis or mediastinitis.

The objective is to repair the diaphragmatic dome while preserving maximum pulmonary compliance, and to reintegrate the digestive elements into the abdomen and prevent the occurrence of complications. This can be done by minimally invasive approaches such as laparoscopy or thoracoscopy, which are safe with low morbidity and shorter hospital stays [9, 18], or by open surgery (laparotomy or thoracotomy).

The surgical procedure involves reduction of the herniated content, desirable resection of the hernia sac, which may be difficult on the left side as it adheres to the pericardium, closure of the anterior margin of the diaphragm to the anterior abdominal wall with separate sutures or non-absorbable suture, and in cases of severe diaphragmatic hypoplasia, reconstruction with a muscular flap (latissimus dorsi) may be necessary.

Aspirative drainage of the thoracic cavity may be necessary. The closure of the diaphragm is often accompanied, as far as possible, by additional reinforcement with mesh or plate. When fixing the mesh or plate, attention should be paid to the hepatic veins in a star shape and the pericardium [19].

Postoperative complications are rare in simple diaphragmatic hernias, and the prognosis is generally favorable. However, mortality ranges from 20 to 32% in cases of emergency intervention for acute complications [20].

4. CONCLUSION:

Morgagni hernia is the rarest form of congenital diaphragmatic hernias, usually presenting with non-specific symptoms that contribute to delayed diagnosis, which is often based on a chest radiograph. Surgical intervention is necessary, and laparoscopic approach is an excellent option, as it minimizes surgical morbidity and allows for shorter hospital stays.

Consent

As per international standard, parental written consent has been collected and preserved by the author(s).

Ethical Approval:

As per international standard or university standard written ethical approval has been collected and preserved by the author(s).

5. REFERENCES:

- 1- College of the High Authority of Health. Congenital diaphragmatic hernia National protocol of diagnosis and care for rare diseases. HAS / Good Professional practice service / October 2012.
- 2- Emmanuel Sapin. Congenital malformations of the abdominal wall of antenatal diagnosis. Monograph of the National College of Pediatric Visceral Surgery XXIXth Seminar of Pediatric Visceral Surgery. Publisher Sauramps Médical; 12/2010.
- 3- Praveen Kumar Chandrasekharan, Munmun Rawat. Congenital Diaphragmatic hernia - a review. *Matern Health Neonatol Perinatol*. 2017 Mar 11;3:6.
- 4- Murat Kemal Cigdem, Abdurrahman Onen, Selcuk Otcu, Hanifi Okur. Late presentation of bochdalek-type congenital diaphragmatic hernia in children: a 23-year experience at a single center. *Surg Today*. 2007;37(8): 642-5.
- 5- Paoletti M, Raffler G, Gaffi MS, Antounians L, Lauriti G, Zani A. Prevalence and risk factors for congenital diaphragmatic hernia: a global view. *J Pediatr Surg*. 2020 Nov;55(11):2297–2307.
- 6- Klein J, Sirota M. Congenital diaphragmatic hernia. *N Engl J Med*. 2017 Oct 26; 377(17):e25.
- 7- Elhalaby EA, Abo Sikeena MH. Delayed presentation of congenital diaphragmatic hernia. *Pediatr Surg Int*. 2002 Sep; 18(5-6):480–5.
- 8- Abdur-Rahman LO, Bamigbola KT, Adeoye PO, Akande HJ, Nasir AA, Obasa TO. Late presentation of congenital diaphragmatic hernia in sub-Saharan Africa: a call for screening and prompt treatment. *J Med Trop*. 2016; 18(1):1–5.
- 9- McGivern MR, Best KE, Rankin J, Wellesley D, Greenlees R, Addor MC, et al. Epidemiology of congenital diaphragmatic hernia in Europe: a register-based study. *Arch Dis Child Fetal Neonatal Ed*. 2015 Mar; 100(2):F137–44.
- 10- Leeuwen L, Fitzgerald D.A. Congenital diaphragmatic hernia. *J Paediatr Child Health*. 2014; 50: 667-673.
- 11- Chardot C, Montupet P. Hernies diaphragmatiques de l'enfant. Techniques chirurgicales - Appareil digestif. In: EMC. Paris: Elsevier SAS; 2006: 40–255. Doi:10.1016/S0246-0424(06)43043-0.
- 12- Steiner Z, Maers AJ. Anterolateral diaphragmatic hernia: is it a Morgagni hernia. *Eur J Pediatr Surg* 1993;3:112–4
- 13- Bargy F. La hernie diaphragmatique; https://www.orpha.net/data/patho/FR/PNDS_hernie_diaphragmatique_congenitale.pdf.

- 14- Didier F. Pathologie diaphragmatique périmatale. Radiodiagnostic-Appareil digestif. In: Encycl Méd Chir. Paris: Elsevier; 1999.
- 15- Thomas GG, Clitherow NR. Herniation through the foramen of Morgagni in children. Br J Surg 1977;64:215-7.
- 16- Elhalaby EA, Abo Sikeena MH. Delayed presentation of congenital diaphragmatic hernia. Pediatr Surg Int. 2002 Sep;18(5-6):480-5.
- 17- Kitano Y, Lally KP, Lally PA, Congenital Diaphragmatic Hernia Study Group Late-presenting congenital diaphragmatic hernia. J Pediatr Surg. 2005 Dec;40(12):1839-43.
- 18- Cigdem MK, Onen A, Otcu S, Okur H. Late presentation of bochdalek-type congenital diaphragmatic hernia in children: a 23-year experience at a single center. Surg Today. 2007;37(8):642-5.
- 19- Kherbouche S. Hernie diaphragmatique congénitale (à propos de 07 cas). Université Sidi Mohamed Ben Abdellah, Faculté de Médecine et de Pharmacie, Fès, 20.
- 20- Beyrouti MI, Beyrouti R, Benamar M, Affes N, Dhieb N, Bensalah K et al. Les hernies diaphragmatiques congénitales de l'adulte-à propos de 8 cas. Médecine du Maghreb. Juillet/août 2009-n°168.