

Review Article

ValsalvaManoeuvre- a versatile diagnostic and therapeutic method

ABSTRACT

Background:The method of the Valsalvamanoeuvre was described in the literature about 300 years ago. Since then it has been used in various specialities with various modifications. It has various therapeutics and diagnostic values in medical science. During the procedure, there is an increase in intra-thoracic pressure which sets in a cascade of reflex reactions in the body which indirectly affects the heart rate. In awake patients, it can be used as an emergency procedure to terminate supraventricular tachycardia. This article discusses its underlying physiological mechanism and intra-operative use in the management of postoperative hemorrhagic complications. The article also highlights its potential complications and usage effectiveness in current scenarios.

Conclusion: This review provides details on the physiological changes and usage of ValsalvaManoeuvre in head and neck surgeries.

Keywords: Valsalvamanoeuvre (VM), Supra ventricular tachycardia, bradycardia, tachycardia

1. INTRODUCTION

Valsalvamanoeuvre (VM) is a procedure where a forceful attempt is done to exhale against a closed airway. This will set in a variety of physiological responses by the body that can be utilised by surgeons and clinicians in various ways. VM was introduced by Antonio Maria Valsalva, an Italian anatomist. It was originally used to expel inflammatory exudates from the middle ear by raising the intra auricular pressure and thereby opening the eustachian tube.¹ The main aim of contemporary VM is to increase the intra-thoracic pressure by occluding the expiratory air. In an awake patient, this is accomplished by increasing the intra-oral pressure to 40 mm hg and its maintenance for 15-20 seconds.² During expiration there is a decrease in the volume and increase in pressure of the thoracic cavity due to the action of the diaphragm and internal intercostal muscles. This results in the movement of air outside of the lungs towards the pressure gradient. During VM there is occlusion of expiratory air movement, maintaining the lungs in an inflated state. The decreasing

thoracic volume and inflated state of the lungs produce high pressure inside the thoracic cavity until the end of this procedure. There are various day-to-day activities where a person performs unintentional Valsalva manoeuvres such as straining during urination and defecation, sexual intercourse, weightlifting etc.³

This article discusses various uses of VM, the physiology behind this mechanism and its potential complications. This article will particularly focus on the intraoperative production of Valsalva and its effectiveness in revealing occult haemorrhages of the surgical site.

DISCUSSION

PHYSIOLOGY INVOLVED IN VALSALVA MANUVER

There are 4 phases involved in the entire process of Valsalva Manoeuvre. Phase I starts with the beginning of forceful expiration against a closed airway. This results in increased intra-thoracic pressure which in turn compresses the thoracic blood vessels. The constriction of the thoracic aorta due to the surrounding rise in the pressure in turn increases the aortic blood pressure due to reduced size of lumen diameter. This sudden change in the aortic blood pressure is detected by the baroreceptors present in the aortic arch, which in turn causes a reflex reduction in the heart rate (Bradycardia) by stimulating the parasympathetic system. (Fig No. 1)

PHASE I-

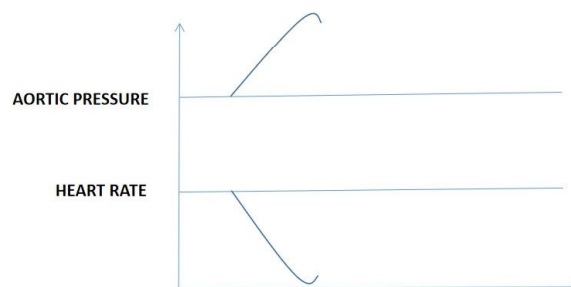
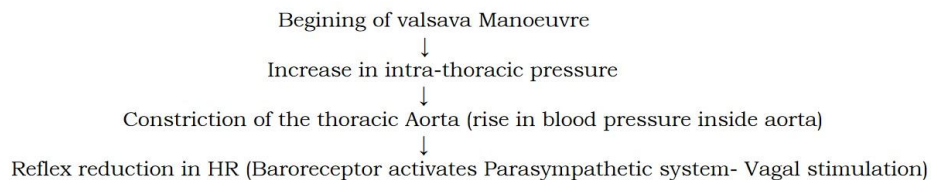


Fig No. 1 forceful expiration against a closed airway

In Phase II, there is a reduction in blood reaching the heart due to constriction of the thoracic veins of the heart. This in turn reduces the blood volume inside the aorta thus decreasing the aortic blood pressure. The aortic baroreceptors sense this fall in pressure and reflex sympathetic stimulation is done increasing the heart rate. (Fig No. 2)

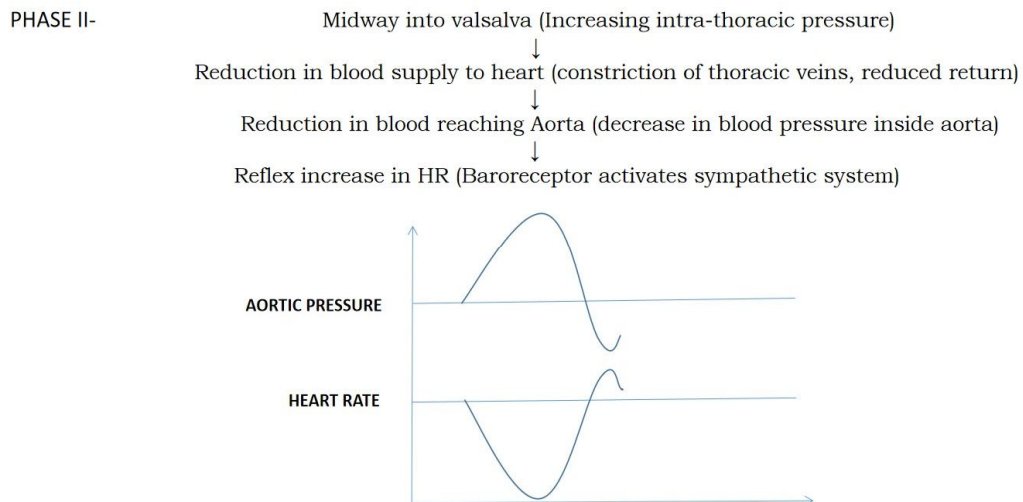


Fig No. 2 reduction in blood reaching the heart due to constriction

It should be clear that during the entire course of Valsalva Manoeuvre, there is a constant interplay between the sympathetic and parasympathetic nervous systems. There is alternate bradycardia and tachycardia during the process. The stimulation of the sympathetic system causes increased systemic vascular resistance which increases venous return. This causes a transient rise of aortic blood pressure due to a small amount of blood reaching the heart. Due to this transient rise in blood pressure, there is again reflex activation of bradycardia. This marks the end of phase II as well as the Valsalva manoeuvre. (Time elapsed 15-20 seconds)

Phase III starts with the sudden release of the intra-thoracic pressure by opening up the airway resulting in a forced expiration. This fall in thoracic pressure causes rapid

dilatation of the thoracic aorta and therefore transient fall in intra-aortic pressure. This results in reflex tachycardia. (Fig No. 3)

PHASE III-

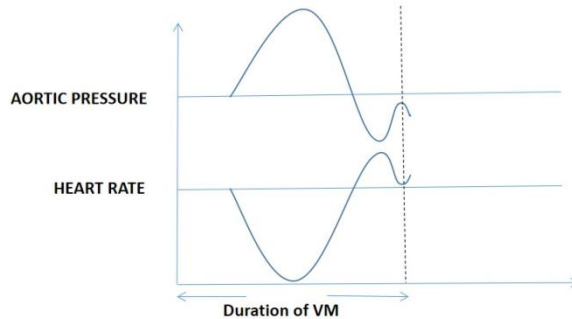
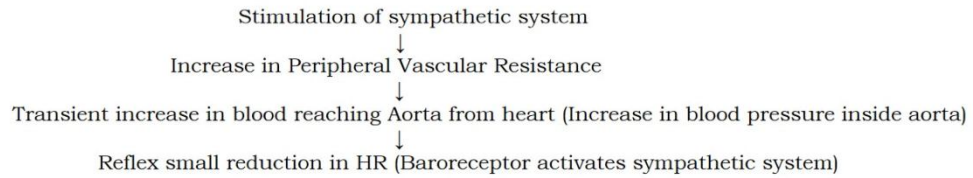


Fig No. 3 transient fall in intra-aortic pressure

Eventually, the pooled peripheral blood gushes back into the heart after the intra-thoracic pressure release. This causes a high volume cardiac output causing an increase in intra-aortic pressure. This again causes a reflex reduction in heart rate (Bradycardia). This marks phase IV and is the last physiological change seen in Valsalva Manoeuvre. (Fig No. 4)

PHASE IV-

End of Valsalva Manoeuvre (Rapid reduction in Intra-thoracic pressure)
↓
Aortic expansion leads to blood pressure drop inside lumen
↓
Reflex increase in heart rate
↓
Return of pooled peripheral blood into the heart resulting in high volume cardiac output
↓
Increased blood pressure in Aorta leading to reflex decrease in heart rate

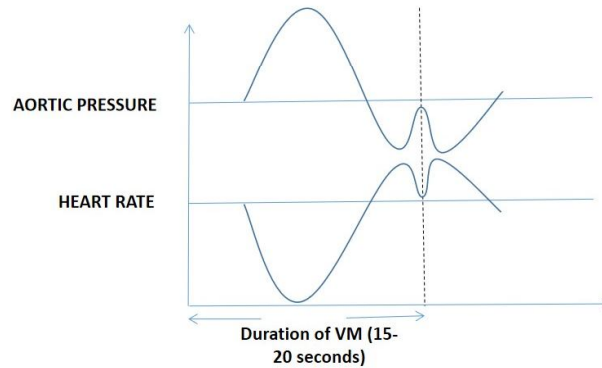


Fig No. 4 physiological change in Valsalva Manoeuvre.

An awake Valsalva manoeuvre is mostly practised in clinical medicine. It helps in the inhibition of supraventricular tachycardia. It can also be used to differentiate heart murmurs caused due to fixed or dynamic obstructions.⁴ Mostly it finds its use in diagnosing autonomic responses and associated neuropathies by identifying diminished responses during VM. It is also used in dentistry to record the posterior palatal seal in the fabrication of the denture for the upper jaw.⁵

Intra-operative Valsalva manoeuvre

Under the spectrum of oral and maxillofacial surgery, the Valsalva manoeuvre finds its use mostly in an intraoperative setting. A rich vascular supply in the head and neck region acts as a double-edged sword. While it gives excellent healing capacity to head and neck tissues, it also causes profuse life-threatening bleeding secondary to trauma or surgery. The presence of an airway in the head and neck region puts it at further risk of postoperative complications where adequate hemostasis is not achieved.⁶ Although the use of drains in surgeries involving the neck has significantly reduced the risk of postoperative airway compromise, the goal of every

surgeon must be to effectively manage haemorrhage before closing the wound in the first place. This is where the Valsalvamanoeuvre can be effectively put to use. The reduced venous return to the heart during VM causes increased pressure inside the jugular veins and their subsequent dilatation.⁴ This reveals the presence of any occult bleed present under the vessels which went unnoticed. In the present scenarios, VM is used by many surgeons in surgeries like thyroidectomy, neck dissections etc. Other methods such as Trendelenberg positioning, and usage of Hydrogen peroxide are also employed. There is still no clear consensus on the most effective method which can give ideal results. A study conducted by Mousoulidis et al showed superior results by using Trendelenberg over VM.⁷ Each method has its advantages and disadvantages. The VM is hazardous when it is extended to more than 42 seconds due to its ability to cause fatal barotrauma. Similarly, using a Trendelenberg position for more than 1 minute can cause a significant rise in intracranial pressure along with mean arterial pressure. The time frame in each method might not be sufficient for its effective diagnostic values, but combinations might help in such situations. Some studies also don't suggest the use of VM as they have shown no beneficial effects on post-operative hemorrhagic complications.⁸

Nonetheless, early detection and prompt management is the key to a successful outcome in case of any haemorrhage. It is therefore important for the surgeon to understand the underlying physiology of different methods and their usage indications individually or in a combined way.

Procedure of intra-operative valsalvamanoeuvre

After the completion of resection surgery of the head and neck, all remaining bleeding vessels are either ligated or cauterised. The anaesthetist is requested to apply a 30 cm PEEP (positive end-expiratory pressure) for 45 seconds.⁷ This can be done by adjusting the pressure limiting valve that is partially or fully closed and expiration is prevented. This results in the increase of pressure inside the internal jugular vein and can open by occult bleeding vessels. During this time, any fresh bleeding can be identified and can be managed with ligation or diathermy. Although

this procedure can reduce postoperative bleeding complications and drainage, it is always advised to use surgical drains to avoid compartment syndromes.

Other non-operative uses of Valsalva manoeuvre in Maxillofacial Surgery

They can be effectively used in the identification of oro-antral communication following a dental extraction of the upper jaw. The increased antral pressure can produce a gushing sound of air passing through the communication.⁹ It can also be used in the visualisation of the oro-pharyngeal region for trauma or infections. The increase in the size of the internal jugular vein can aid in easy central venous cannulation.⁷ Modifications of VM can be used in the identification of CSF leaks in orbital trauma reconstructions.

Complications in Valsalva manoeuvre

Although there are various studies that show VM is a safe procedure, identification of individuals on whom there can be possible risk factors are important. Patients with history of coronary heart disease, poor autonomic regulations are particularly sensitive to sudden changes in heart rate.⁷ It can precipitate a period of asystole in such patients and therefore caution must be exercised to handle such emergencies. There are reported cases of burst in of intracranial aneurisms after reflex increase in cerebral blood flow in phase II.⁷ A rare complication of production of buccal abscess was also reported post Oro-antral communication repair where the patient inadvertently performs VM causing subcutaneous emphysema.¹⁰

CONCLUSION

The effective use of the Valsalva manoeuvre depends on the knowledge of its underlying physiology and the identification of unsuitable candidates. Its effectiveness in managing postoperative bleeding is still controversial and therefore most surgeons still use a combination of other methods. There is a need for more technical refinement in this procedure to make it more safe and universal.

REFERENCES

1. Yale SH. Antonio Maria Valsalva (1666 - 1723). *Clin Med Res*. 2005 Feb;3(1):35-8. doi: 10.3121/cm.3.1.35. PMID: 15962020; PMCID: PMC1142106.
2. Taylor DM, Wong LF. Incorrect instruction in the use of the Valsalvamanoeuvre for paroxysmal supra-ventricular tachycardia is common. *Emerg Med Australas*. 2004 Aug;16(4):284-7. doi: 10.1111/j.1742-6723.2004.00628.x. PMID: 15283715
3. Klabunde RE. Cardiovascular Physiology Concepts. Hemodynamics of a Valsalva Maneuver 2012. Available from URL: <http://www.cvphysiology.com/Hemodynamics/H014> (accessed December 2017).
4. Kumar, C.M., Van Zundert, A.A.J. Intraoperative Valsalva maneuver: a narrative review. *Can J Anesth/J Can Anesth* **65**, 578–585 (2018). <https://doi.org/10.1007/s12630-018-1074-6>
5. Shah RJ, Lagdive SB, Modi DB, Darji B, Amin VA, Patel GC. A study of correlation between posterior palatal seal width and soft palatal angulation with palatal contour. *J Indian Prosthodont Soc*. 2016 Apr-Jun;16(2):154-8. doi: 10.4103/0972-4052.176519. PMID: 27141165; PMCID: PMC4837767.
6. Ozdemir M, Makay O, Icoz G, Akyildiz M. What adds Valsalva maneuver to hemostasis after Trendelenburg's positioning during thyroid surgery? *Gland Surg*. 2017 Oct;6(5):433-436. doi: 10.21037/g.2017.07.09. PMID: 29142831; PMCID: PMC5676157.
7. Moumoulidis I, Martinez Del Pero M, Brennan L, Jani P. Haemostasis in head and neck surgical procedures: Valsalvamanoeuvre versus Trendelenburg tilt. *Ann R CollSurg Engl*. 2010 May;92(4):292-4. doi: 10.1308/003588410X12664192076412. PMID: 20501015; PMCID: PMC3025209.
8. Tokaç M, Dumlu EG, Bozkurt B, Öcal H, Aydın C, Yalçın A, Çakır B, Kılıç M. Effect of Intraoperative Valsalva Maneuver Application on Bleeding Point Detection and Postoperative Drainage After Thyroidectomy Surgeries. *Int Surg*. 2015 Jun;100(6):994-8. doi: 10.9738/INTSURG-D-15-00002.1. PMID: 26414819; PMCID: PMC4587529.
9. Azzouzi A, Hallab L, Chbicheb S. Diagnosis and Management of oro-antral fistula: Case series and review. *Int J Surg Case Rep*. 2022 Aug;97:107436. doi: 10.1016/j.ijscr.2022.107436. Epub 2022 Jul 21. PMID: 35917603; PMCID: PMC9403197.
10. Shudo, Atsushi. (2020). Buccal abscess derived from subcutaneous emphysema caused by the Valsalva maneuver after oral surgery with pedicled buccal fat pad grafting. *Oral Surgery*. 14. 10.1111/ors.12590.