

Case study

Patent Omphalomesenteric Duct in a 6 Month Boy

Abstract

Patent omphalomesenteric duct or vitellointestinal duct is remnant of the duct, connecting the yolk sac to the gut in the developing embryo and provides nutrition until the placenta is established in infant. It is a rare congenital malformation of the gut, with an incidence of about 2% of the population.

The condition is most commonly observed within the first year of life, affecting males preferably and reported in about 15 % of all the vitellointestinal duct anomalies. Diagnosis is obvious in most of the cases due to presence of omphalomesenteric fistula and fecal discharge through the umbilicus. Standard surgical therapy for the patent duct is surgical resection of the patent duct with or without resection of adjacent small bowel.

Herein, we report a 6-month boy was referred by paediatrician for surgical treatment. Clinical presentation of a boy was the discharge of mucus and fecal matter through the umbilicus. Surgical treatment of resection of patent vitellointestinal duct, wide wedge resection of ileum and ileal repair was performed.

Key-words

Patent omphalomesenteric duct, Patent vitellointestinal duct, , vitelline duct

Introduction

"Patent vitellointestinal duct occurred due to the complete failure of the regression of the vitellointestinal duct and incidence of 1:15,000 hospital births, Meckel's diverticulum is most common anomaly 70-80%. Most of the cases of patent vitellointestinal duct clinically present during the infancy but also few cases are reported in adult also". [1,2,3]

A patent omphalomesenteric duct remnant may present, abdominal pain, intestinal obstruction, bleeding per-rectally, umbilical hernia during childhood. When a serious, feculent or bilious drainage are seen at the umbilicus and it is suggestive of a patent omphalomesenteric duct with fistulous communication with the umbilicus. Symptoms of fecal discharge and prolapse of the intestine are well known. Intestinal obstruction in adult is an extremely rare clinical presentation. [4,5]

Case Presentation

A 6-month male baby was referred by paediatrician for surgical line of treatment to our centre, in the year 1998. On clinical examination of a baby was having umbilical granuloma, discharging mucus and faeces through the umbilicus. The correct diagnosis was done by inserting a Nelaton's plastic sterile catheter through the umbilical opening and Fistulagram performed by radiopaque solution, showed the patient vitellointestinal fistula connecting to ileum and confirms the diagnosis of patent omphalomesenteric duct connecting to the ileum.

Next day operative procedure was planned. The baby underwent umbilical stump exploration under general anaesthesia. The routine haematological and biochemical laboratory test were normal. The abdomen of a baby was painted & draped. The skin was incised circumferentially around the umbilicus after negotiating the Nelaton's plastic catheter to know the length of fistulous tract, which was 5 cm in length, was traced and a small midline incision extended 2-3 cm below the umbilicus. The fistulous tract was dissected up to the ileal loop and fistulous tract was excised up to ileal segment and ileum repair with 2.0 vicryl. After palpation with fingers the ileal segment was normal, so ileal segment was not removed. The baby's postoperative course was unremarkable and baby discharged home on 8th postoperative day. (Figure 1,2,3)

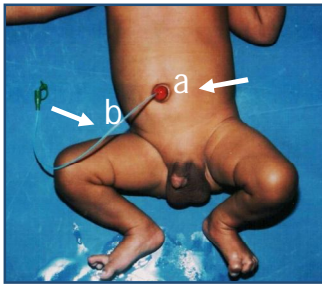


Fig-1 Showing a-patent omphalomesenteric duct or umbilical granuloma b-Nelaton's catheter

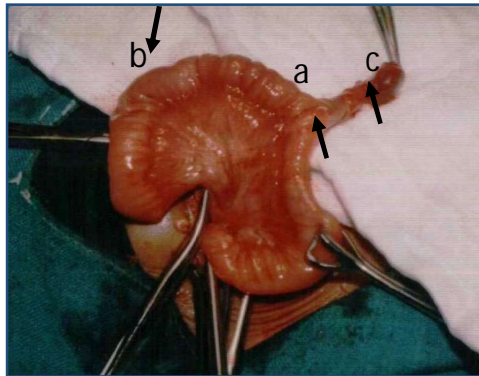


Fig-2 Showing a-patent omphalomesenteric duct or umbilical granuloma b-Small bowel segment c-umbilicus

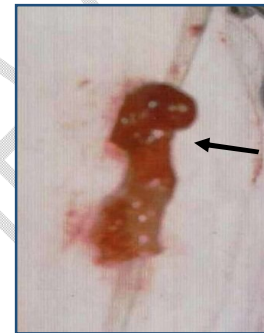


Fig-3 Showing total excision of omphalomesenteric duct of size 5x1 cm

Discussion

"The omphalomesenteric duct is a congenital anomaly connecting the primary yolk sac to the embryonic mid-gut, which usually regressed spontaneously the 5th-7th week of gestation. The failure of such closure may result in various anomalies, Meckel's diverticulum, patent omphalomesenteric duct, umbilical sinus or granuloma vitelline cyst, fibrous band connecting the ileum to the umbilicus. Meckel's diverticulum is the commonest 80-90% anomaly of the omphalomesenteric duct. Patent omphalomesenteric duct is a rare anomaly with a reported incidence of 0.0063-0.067% The patent vitellointestinal duct occurred more in infant and also more common in males a compare to females". [1,2,3]

Clinical presentation varies from the discharge of mucous, flatus, bile and faeces through the umbilicus, to the acute intestinal obstruction. Umbilical discharge raises the suspicion of a patent omphalomesenteric duct. Umbilical granuloma is one of the differential diagnosis of vitellointestinal duct. Umbilical granuloma responds to silver nitrate stick. The exact diagnosis can be done by a Fistulagram after catheterization of the duct by a radiopaque solution. [1,3,4,6]

There are options for the surgical resection of the patent vitellointestinal duct.

1. Resection of the patent vitellointestinal duct along with wide wedge resection of the ileum and ileal repair.
2. Resection of the patent vitellointestinal duct, along with adjacent small bowel segment and ileo-ileal anastomosis.

The above surgical procedures can be performed through the sub-umbilical incision, around the umbilicus or trans-umbilical approach. Surgical procedure done through the umbilicus and sub-umbilical incision carries the best cosmetic results. [2,3,4]

In our case of infant we performed the total excision of the patent vitellointestinal duct up to the ileum junction and ileal repair was done.

Conclusion

Patent Omphalomesenteric duct is a very rare entity and its timely diagnosis and management improve the ultimate outcome. Complete resection of patent omphalomesenteric duct along with segmental resection of ileum and end to end anastomosis is the mainstay of management in such cases.

Ethical Approval:

As per international standard or university standard written ethical approval has been collected and preserved by the author(s).

Consent

As per international standard or university standard, Parental written consent has been collected and preserved by the author(s).

COMPETING INTERESTS

Authors have declared that they have no known competing financial interests OR non-financial interests OR personal relationships that could have appeared to influence the work reported in this paper.

References

1. Markogiannakis H, Theodorou D, Toutouzas KG, Drimousis P, Persistent omphalomesenteric duct causing small bowel obstruction in an adult. World J Gastroenterol. 2007 Apr 21;13(15):2258-60. doi: 10.3748/wjg.v13.i15.2258. PMID: 17465515; PMCID: PMC4146858.
2. Jo sé Al bu qu er qu e La nd im Ju ni or a , Surgical treatment of patent omphalomesenteric duct, <https://doi.org/10.1016/j.epsc.2021.101883>
3. Rajendra K. Ghritlaharey¹, Management of Patent Vitellointestinal Duct in Infants, DOI <https://doi.org/10.1055/s-0041-1722836> ISSN 0379-038X
4. Ali GÜNER, Can KEÇE, Aydın BOZ, İzzettin KAHRAMAN, Erhan REİS, A rare cause of small bowel obstruction in adults: persistent omphalomesenteric duct, Turkish Journal of Trauma & Emergency Surgery, doi: 10.5505/tjtes.2012.77609
5. Feride ALEVL1 , Sami AKBULUT2 , Yasemin DOLEK3 , Bahri CAKABAY2 , Arsenal SEZGN4, Patent vitelline duct as a cause of acute abdomen: Case report of an adult patient, Turk J Gastroenterol 2011; 22 (1): 101-103 doi: 10.4318/tjg.2011.0167

6. YAVUZ YILMAZ, GAMZE DEMİREL, HÜLYA Ö. ULU, SUCCESSFUL MANAGEMENT OF AN OMPHALOMESENTERIC FISTULE IN NEWBORN PERIO, Medical Journal of Islamic World Academy of Sciences 19:4, 181-183, 2011
7. Dr. Hajira Fatima, Dr. Mrudula C, Dr. Archana.N, PATENT VITELLO-INTESTINAL DUCT -A RARE CADAVERIC PRESENTATIONCASE REPORT, INTERNATIONAL JOURNAL OF SCIENTIFIC RESEARCH, PRINT ISSN No. 2277 - 8179 | DOI : 10.36106/ijsr
8. Sawada F, Yoshimura R, Ito K, Nakamura K, Nawata H, Mizumoto K, et al. Adult case of an omphalomesenteric cyst resected by laparoscopic-assisted surgery. World J Gastroenterol 2006;12:825-7
9. Amendolara M, Pasquale S, Perri S, Carpentieri L, Errante D, Biasiato R. et al. Intestinal occlusion caused by persistent omphalomesenteric duct and Meckel's diverticulum: report of 2 cases. Chir Ital 2003;55:591-5.
10. Alevli F, Akbulut S, Dolek Y, Cakabay B, Sezgin A. Patent vitelline duct as a cause of acute abdomen: case report of an adult patient. Turk J Gastroenterol 2011;22(1):101-103

UNDER PEER REVIEW