

Case study

An Unusual Clinical Manifestation of a Rare-Site Duodenal Perforation

Abstract

Background: The incidence of duodenal perforation is less than 1%^[1], and less than 1% of gastrointestinal perforations are caused by ingested bodies.^[2] Duodenal perforations often present with rapidly progressing peritonitis and are subsequently managed via emergency laparotomy. In our case, the patient accidentally ingested a sharp object that subsequently perforated the duodenum. We report this case of D3 segment Perforation along with its diagnosis and the attendant management challenges. **Case presentation:** A 70-year-old male visited the emergency department with complaints of scrotal swelling. On examination, the patient was found to be in septic shock. An abdominal computed tomography (CT) scan revealed a foreign body perforating the horizontal segment of the duodenum with a retroperitoneal fluid collection. An emergency laparotomy was planned and executed, with the abscess cavity drained, the foreign body removed, and the perforation repaired. The postoperative period was uneventful. **Conclusion:** Foreign body perforation in the duodenum is easily missed due to its atypical presentation. An early CT examination helps to identify the foreign body and the localization of the perforation, which can reduce the mortality and morbidity associated with perforation.

Keywords: D3 segment, foreign body, perforation

Introduction

The Incident of Duodenal Perforation is less than 1%^[1]. Duodenal perforations often present with rapidly progressing peritonitis and are subsequently managed via emergency laparotomy. This condition is often missed in view of atypical presentation. Foreign body ingestion is usually involuntary or accidental and involves patient extreme age with mental or swallowing disorder^[3]. There will be latent period between the time of ingestion and the time of clinical presentation. Duodenal perforation related to foreign body ingestion is rare, in this case, the patient accidentally ingested a sharp object that subsequently perforated the 3rd part of duodenum.

Case Report

A 70-year-old male presented to the emergency department with complaints of swelling of the scrotum for 15 days and abdominal pain for 10 days, with no history of testicular pain, burning micturition, or alteration of bowel habits. On examination, the patient was conscious and oriented, with a Hypotension and desaturation. An abdominal examination revealed tenderness in the right hypochondrium, right lumbar, right iliac region, and epigastrium. No free fluid was discovered, and on scrotal examination, skin discoloration and tenderness were present over the right half of the scrotum. Both testes were normal in size, shape, and consistency. An ultrasound evaluation revealed right funiculitis and right hemiscrotal wall thickening (hypochoic edematous with internal septation and low-level internal echoes of (2.5 cm). Figure 1a shows the edema, an evolving abscess, and cellulitis, while as Figure 1b shows, the blood parameters RFT and CBC deranged.

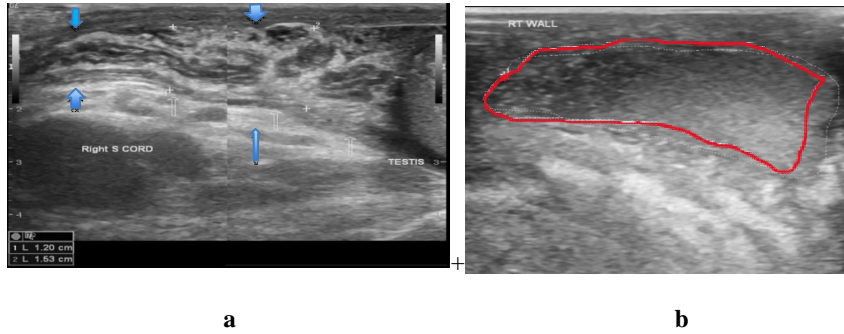
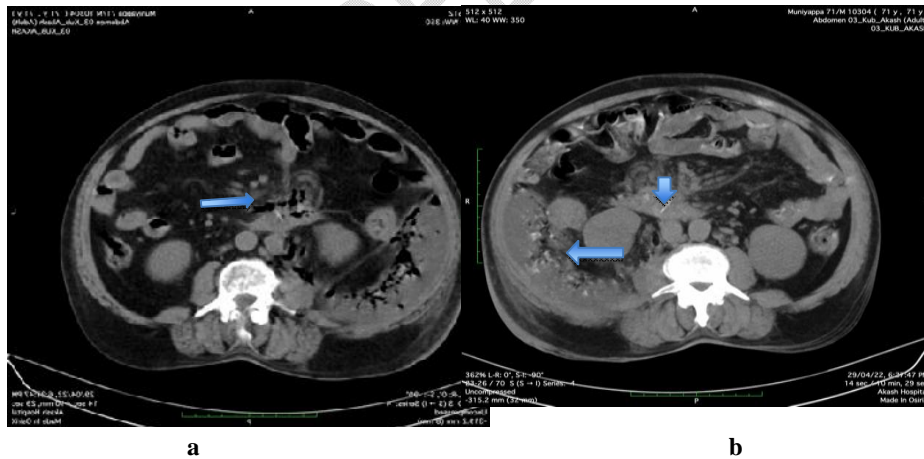
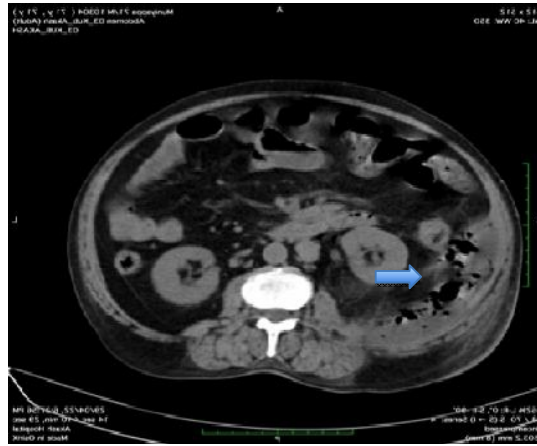


Figure 1. a) Thickened spermatic cord, increased echogenicity, increased vascularity, and right funiculitis.

b) Wall thickening and collection with low-level internal echoes in the right hemi-scrotal wall with a thickness of 2.5 cm. Perilesional hyper-vascularity and scrotal wall cellulitis.

Since the patient's serum creatinine level was deranged contrast enhanced computed tomography (CECT) was not deemed to be a viable option. The patient thus underwent a non-contrast computed tomography (NCCT) scan of the abdomen and pelvis (Figure 2), which revealed a large collection with copious amounts of air in the right extraperitoneal compartment communicating with a large quantity of air in the mesentery and extending into the right scrotal cavity. This suggested hollow viscus perforation. A linear hyperdensity in the D3 segment of the duodenum foreign body was visualized as the suspected perforation site.





c

Figure 2. a, b) Linear density in the D3 segment and the right extraperitoneal collection site, displacing the right kidney; c) air in the mesentery communicating with the collection and fat stranding.

After being counseled about the need for the proposed surgery (explorative laparotomy), as well as the risks involved and the associated complications, the patient's attendee was unwilling to consent to the procedure and opted for discharge against medical advice. Six days later, the patient returned to the hospital with complaints of a wound over the right half of the scrotum and two or three episodes of fever per day for six days. The patient was reevaluated, and the decision was made to proceed with an emergency explorative laparotomy. The patient and his attendees were informed of the risks and complications associated with this surgery, and with their consent, an explorative laparotomy was performed. Intraoperatively, on the mobilization of the caecum and ascending colon, 1,000 ml of purulent collections were found around the caecum and ascending colon, with pockets of pus behind the mesentery. These were drained, and on further exploration of the abscess cavity, an elongated foreign body (possibly a toothpick or fishbone) was found to be perforating the posterior wall of the horizontal segment of the duodenum. The foreign body was extracted, and the perforation was closed using an omental patch. Inflamed mucosa in the third part of the duodenum was noted. A thorough saline wash of the peritoneal cavity was performed, and a drain tube was placed in the Morrisons' pouch, followed by debridement of the scrotal wound (Fournier's gangrene). The postoperative period was uneventful, and the drain tube was removed on postoperative day 10.

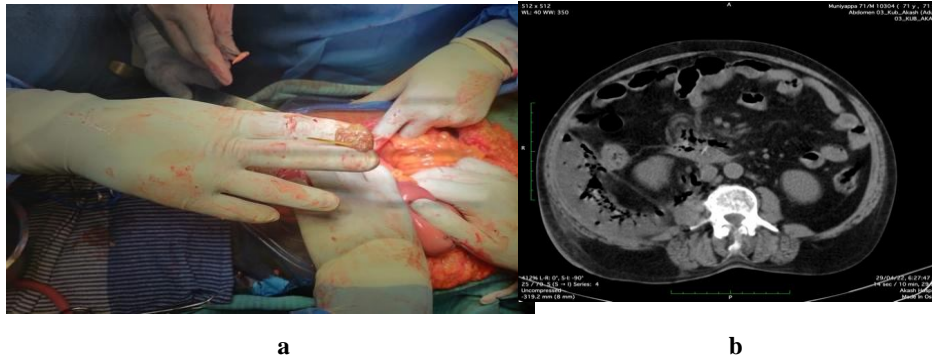


Figure 3. a, b) Sharp, linear, gray-and-white structure with slough retrieved from the D3 segment.




Figure 4. The swallowed 5-cm toothpick.

Discussion

Foreign body ingestion is often related to children, mental retardation, alcohol intoxication, psychiatric disorders, prisoners, and the wearing of dentures.^[4] In our case, the patient was intoxicated at the time of ingestion. Most reported cases of perforation are caused by thin, pointed objects, such as needles, toothpicks, fishbones, or chicken bones^[5]. Most ingested foreign bodies can pass through the bowel lumen without any complication^[6].

A CECT scan with oral and intravenous contrast is the investigation of choice for blunt trauma injuries in view of diagnosing retroperitoneal injuries accurately.^[7], and the method is sensitive to small amounts of retroperitoneal air, blood, or leaked contrast from the injured duodenum.^[8] Here, due to the increased serum creatine levels, CECT was deemed not to be a viable option. An NCCT scan of the abdomen was thus performed to evaluate the abdominal pain, revealing a foreign body in the duodenum that might have caused perforation, and the patient was thus taken for an emergency laparotomy. This confirmed the presence of a foreign body in the posterior wall of the D3 segment. Various treatment options are available for repairing perforations, including simple repair (duodenorrhaphy), resection and

anastomosis, repair and decompressive enterostomy, serosal or mucosal patch, pyloric exclusion, duodenal diverticulization, and pancreaticoduodenectomy^[9.]. In the present case, the patient underwent a Graham patch repair with no significant post-operative complications.

Conclusion

The usual Perforation site are angulated area like Ileocecal Junction and recto-sigmoid ,colonic flexure ,DJ flexure^[10]. Duodenal injuries secondary to foreign body ingestion are rare and been reporting ,CT scan is best modality for preoperative imaging which helps to identify the cause and locate the foreign body which helps in planning surgery . A history of foreign body ingestion was not obtained in the majority of cases, high suspicion is required to make a diagnosis of ingested foreign body in acute abdomen patients, especially in the elderly patient ,Though majority of patient will require an explorative laprotomy .The timely diagnosis and surgical intervention were crucial in preventing possible mortality and morbidity.

References

- (1) Ansari D, Torén W, Lindberg S, Pyrhönen H-S, Andersson R. Diagnosis and management of duodenal perforations: a narrative review. *Scand J Gastroenterol* [Internet]. 2019;54(8):939–44.
- (2) Sarmast A, Showkat H, Patloo A, Parray F, Lone R, Wani K. Gastrointestinal Tract Perforations Due to Ingested Foreign Bodies; A review of 21 cases. *British Journal of Medical Practitioners* 2012
- (3) Li, C., Yong, CC. & Encarnacion, D.D. Duodenal perforation nine months after accidental foreign body ingestion, a case report. *BMC Surg* **19**, 132 (2019). <https://doi.org/10.1186/s12893-019-0594-5>
- (4) Webb WA. Management of foreign bodies of the upper gastrointestinal tract: Update. *Gastrointestinal Endoscopy*. 1995;41(1):39–51. DOI: 10.1016/s0016-5107(95)70274-1
- (5) Kim SH, Shin SS, Jeong YY, Heo SH, Kim JW, Kang HK. Gastrointestinal tract perforation: MDCT findings according to the perforation sites. *Korean Journal of Radiology*. 2009; 10(1): 63. DOI: 10.3348/kjr.2009.10.1.63
- (6) Ma T, Zheng W, An B, Xia Y, Chen G. Small bowel perforation secondary to foreign body ingestion mimicking acute appendicitis: Case report. *Medicine (Baltimore)*. 2019 Jul;98(30):e16489. doi: 10.1097/MD.00000000000016489
- (7) Golikhatir I, Sazgar M, Jahanian F, Mousavi Amiri SJ, Aminiahidashti H. Comparison of the diagnostic accuracy of CT scan with oral and intravenous contrast versus CT scan with intravenous contrast alone in the diagnosis of blunt abdominal trauma. *Chin J Traumatol*. 2023 May;26(3):174-177. doi: 10.1016/j.cjte.2022.12.006.
- (8) Celik A, Altinli E, Koksal N, Onur E, Sumer A, Uzun MA, et al. Management of isolated duodenal rupture due to blunt abdominal trauma: Case series and literature review. *European Journal of Trauma and Emergency Surgery*. 2010;36(6):573–8.

(9) Nepal P, Maemura K, Mataka Y, Kurahara H, Kawasaki Y, Hiwatashi K, Iino S, Sakoda M, Arigami T, Ishigami S, Shinchi H, Natsugoe S. Management of horizontal duodenal perforation: a report of three cases and review of literature. Surg Case Rep. 2017 Dec 1;3(1):119. doi: 10.1186/s40792-017-0397-9.

(10) Rodriguez JER, Coelho DPD, Villalaz EDS, Figueiredo AR, Martins PDK, Guimarães JJP, de Souza AMC, Guimarães AGDP. Rectosigmoid transition perforation by ingá (*Inga aurina*) seeds in the Brazilian amazon: Case report and surgical treatment. Ann Med Surg (Lond). 2021 Sep 27;70:102897. doi: 10.1016/j.amsu.2021.102897.

UNDER PEER REVIEW