

GUIDE FLANGE PROSTHESIS: A CASE REPORT

ABSTRACT:

Patients who have undergone surgical hemi/segmental/subtotal mandibulectomy for various reasons with resulting mandibular deviation are given a guide flange. If secondary osseous grafting is planned, the doctor must wait for the graft, lesion, or radiotherapeutic effects to resolve. A definitive prosthesis can be planned only when the graft has been healed. During this time lag, the patient must be fitted with a prosthesis to rectify mandibular deviation caused by unilateral muscle strain. Furthermore, in some circumstances, a definitive prosthesis must be postponed due to bone grafting failure or the patient's unwillingness to undergo a second surgery. This clinical case report shows a mandibular guide flange prosthesis fabricated for a patient.

KEY WORDS: Guide Flange Prosthesis (GFP), Mandibular deviation, Mandibulectomy, Mandibular continuity.

INTRODUCTION:

“Benign or malignant neoplasms of the lower jaw usually necessitate surgical removal of the pathologic lesion as well as significant resection of the lower jaw”.¹ “Following surgical therapy for neoplastic lesions of the oral cavity, mandibular resection causes a variety of problems, including altered

mandibular motions, disfigurement, trouble swallowing, decreased speech and articulation, and mandibular deviation toward the resected site”.² “The loss of continuity leads the remaining segments to deviate toward the defect and the mandibular occlusal plane to rotate downwards”.^{3,4}

“Masticatory function is reduced after a segmental mandibulectomy surgery due to muscular imbalance caused by unilateral muscle removal, altered maxillomandibular relationship, and decreased tooth to tooth contacts” [8,9]. “Even though immediate mandibular restoration strives to restore face symmetry, arch alignment, and secure occlusion, masticatory function is frequently affected. Following mandibular resection, the loss of the proprioceptive sensation of occlusion results in uncontrolled movements of the jaw”.⁴

The primary goal of rehabilitation is to re-educate muscles to re-establish an acceptable occlusal connection. Guide flange prosthesis (GFP) is a conventional mandibular prosthesis designed for patients who can achieve an appropriate mediolateral maximum intercuspal position of the mandible without much effort but are unable to repeat this position consistently for

adequate mastication and to limit further deviation.⁵

CASE REPORT:

A 19 year male patient reported to the Department of Prosthodontics with mandibular deviation. History revealed that patient has ameloblastoma due to which his mandible was resected in the 3rd quadrant from 1st premolar to the Condyle. As a result of which there is a gross deviation of the mandible towards the patient's left side. So, Guide Flange Prosthesis (GFP) was planned for the patient to maintain occlusion on the non-resected side and to maintain the aesthetics.

Fig 1 and 2 shows the extraoral and intraoral images of the patient. Both the maxillary and mandibular impressions are made with alginate (Fig 3) and casts are poured in dental stone (Fig 4).

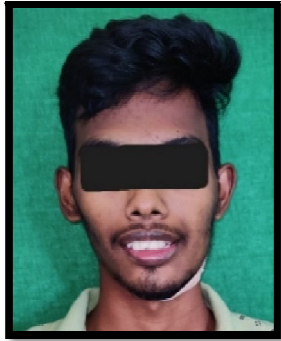

Fig 1: Extra-oral image of the patient

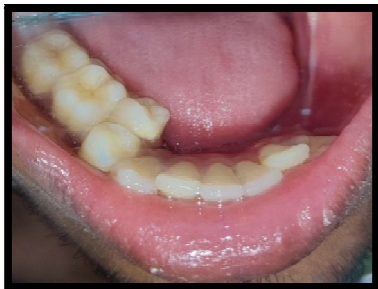
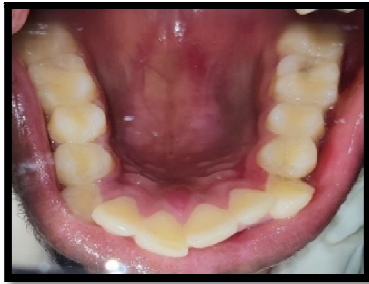
Fig 2: Intra-oral image of maxillary and mandibular arches

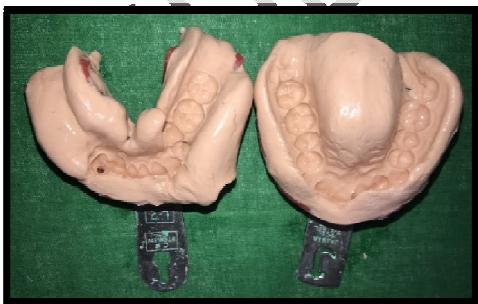


Fig 3: Impression of maxillary and mandibular arches

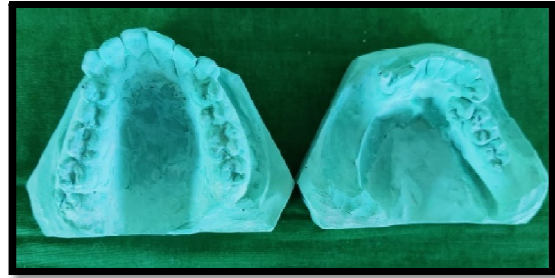


Fig 4: Maxillary and mandibular master cast

Later a framework was fabricated for the guide prosthesis (Fig 5) over which wax pattern was fabricated (Fig 6). Then the wax pattern was invested, and processing was done, then it was retrieved, finished, and polished (Fig 7) and delivered to the patient (Fig 8).



Fig 5: Framework for guide prosthesis



Fig 6: Wax pattern for guide prosthesis

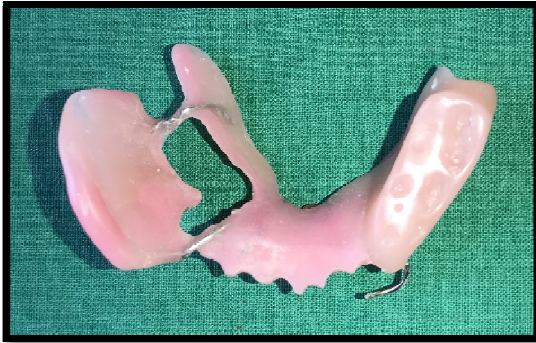


Fig 7: Guide flange prosthesis

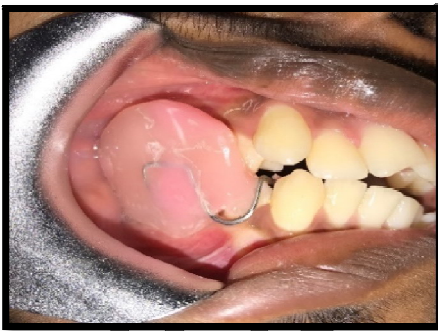
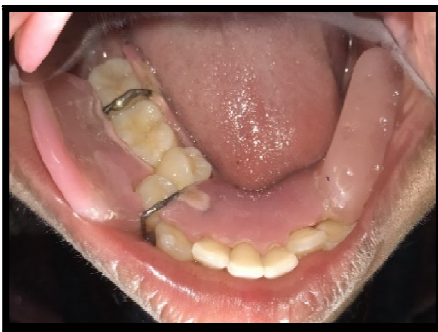

Fig 8: Intra-oral guide flange prosthesis

DISCUSSION:

“A resection of a piece of the mandible that does not include loss of mandibular continuity is usually less debilitating than a resection that

includes loss of mandibular continuity”.²

“Mandibular deviation, rotation, and retrusion are debilitating difficulties for maxillofacial patients with mandibular discontinuity, causing the residual section of the mandible to rotate inferiorly following closure, deviate toward the resected side, and be retruded when compared to presurgical positions. Most of the patient's difficulties can be solved during surgery by reconstructing mandibular continuity with a bone transplant or metal plates. However, if the deviation is not corrected, it can result in loss of occlusion on the nonresected side and an anterior open bite, which can impact the patients' speech, swallowing, regulation of salivary secretions, and aesthetics”.⁶

The removable partial denture framework of this mandibular guide prosthesis extends 7-10 mm laterally and superiorly on the buccal surface of

the premolars and molars on the non-defect side. During mandibular closure, this flange engages the maxillary teeth, directing the lower jaw to an adequate intercuspal position.

“In case of palatal-based guide flange, the index should not extend below the level of the upper teeth”.⁷ “If it does, it may obstruct speaking, deglutition, and other oral activities that require tongue motions. This observance may not be necessary in certain patients with restricted tongue movements”.⁴

“The guide flange can be made of either cast chrome cobalt metal or acrylic resin. The material of choice will be determined by the patient's existing occlusal relationship and the requirement for modification”.⁴ In our clinical case we restored with acrylic resin GFP because they were only going to be used for a limited period and required regular adjustments.

“The GFP can be thought of as a training prosthesis. If the patient can successfully repeat the pose, the GFP is frequently stopped. However, some patients may have to continue permanently, and the tension on the remaining teeth must then be carefully monitored”.⁴

CONCLUSION:

A GFP is used as an interim prosthesis following a mandibulectomy or postsurgical restoration of the defect to allow the patient to perform everyday duties such as mastication while also maintaining aesthetics to some extent by limiting jaw deviation to the damaged side. In some situations, the patient may be obliged to use the prosthesis indefinitely due to factors such as poor post-bone grafting prognosis.

Ethical Approval:

As per international standard or university standard written ethical approval has been collected and preserved by the author(s).

Consent

As per international standard or university standard, patient(s) written consent has been collected and preserved by the author(s).

REFERENCES

1. Beumer J 3rd, Curtis TA, Marunick MT. Maxillofacial rehabilitation. In: Prosthodontic and Surgical Consideration. St. Louis, Euro America: Ishiyaku; 1996. p. 113-224.
2. Taylor TD. Clinical Maxillofacial Prosthetics. Illunios: Quintessence Publication Co.; 1997. p. 171-88.
3. Marathe AS, Kshirsagar PS. A systematic approach in rehabilitation of hemimandibulectomy: A case report. J Indian Prosthodont Soc 2016; 16:208-12.
4. Hazra R, Srivastava A, Kumar D. Mandibular guidance prosthesis: Conventional and innovative approach: A case series. J Indian Prosthodont Soc 2021; 21(2):208-14.
5. Desjardins RP. Relating examination findings to treatment procedures. In: Laney WR, editor. Maxillofacial Prosthetics. Littleton: PSG Publishing; 1979. p. 69-114.
6. Geramipanah F, Fallahi Sichani S, Mirmohammadrezaei S, Ghodsi S. Practical guidelines for fabricating mandibular guide flange prostheses: A new technique for measuring the flange angulation. Prosthodont Int 2016; 40(4):528-31.
7. Kadain P. Prosthodontic rehabilitation of a

hemimandibulectomy patient. J
Indian Prosthodont Soc 2020;
20 Suppl S1:26-7.

8. Patil PG, Patil SP. Guide flange
prosthesis for early management of
reconstructed hemimandibulectomy: a
case report. The Journal of Advanced
Prosthodontics. 2011 Sep 1;3(3):172
9. Bandodkar S, Arya D, Singh SV,
Chand P. Guide flange Prosthesis for
management of hemimandibulectomy.
National Journal of Maxillofacial
Surgery. 2021 May;12(2):289.

UNDER PEER REVIEW