

## Case report

### **An unusual fronto-orbital open trauma pattern due to foreign body at work**

#### **1. Abstract**

The authors report here a rare case of fronto-orbital foreign body that enter the skull through the right eye region during professional activity. The patient was not protected and the aim of this case is to emphasize on the importance of safety measures. On arrival of the patient, first aid, clinical evaluation and tomodynamometry were done prior to surgery. The evaluation revealed: burns and traumatic lesions concerning the skin, the skull, the dura mater, the frontal lobe the eye and the eyelid. Under general anaesthesia, the foreign body has been removed by two teams, neurosurgical and ophthalmologic. Hemostasis and drainage of the cerebral frontal area were done by a neurosurgeon. The eye was completely destroyed, removed by an ophthalmologist and is covered by the ptosis. There was no complication on the crânio –encephalic aspect. The patient resume work after one month and is doing well 10 months after surgery. This rare case raise the importance of safety measure at worksite. The foreign body should never be removed prior to anaesthesia and surgery.

**Key words :** Foreign body – Fronto –orbital traumatism – Cylinder

#### **2. Introduction**

Many Traumatic Brain Injury (TBI) are reported [1-6]. Opened TBI due to foreign bodies are reported in the civilian and military contexts [7-11]. Also, various IntraOrbital Foreign Bodies (IOFB) are already published [12-19]. The association of a foreign body TBI to an IOFB is also reported [20-22]. But, the association of these lesions to solid metal projection and incarceration, burn and fuel explosion is a rare mechanism of trauma. For these surgical emergencies, it is important to take a thorough history with the mechanism of the trauma, a complete physical examination and paraclinical investigations to have a good management. The role of tomography and sonography is reported [23]. TBI can be mild, moderate or severe. IOFB may result in severe structural and functional damage to the eye or orbital contents. The outcome is variable [20-25]. The present case study highlights a rare mechanism of a severe TBI associated to a severe IOFB secondary to an unusual accident at work with a good outcome for the brain and a poor outcome for the globe.

#### **3. Case presentation**

##### **Identification:**

Mr. D G, 30 years old, is a metal carpenter with no particular background, working in Dschang, West region in Cameroon.

##### **Main complain :**

The patient was referred in emergency with a large right fronto-orbital foreign body that had been evolving for approximately one hour before his admission.

##### **History:**

The history reveals an accident at the work site, located in Foréké Dschang, on May 20<sup>th</sup>, 2022, around mid-day, while working with a machine, and without protective equipment. The patient wanted to seal a cylindrical screen to the inlet of a truck's tank to prevent the fuel from being stolen. But the tank was not empty and the weld next to the fuel triggered a violent explosion, throwing the cylinder against its right fronto-orbital region.

This was followed by frontal cranioencephalic and right oculo-orbital trauma. After the first aid provided in a nearby district hospital (tetanus serum, local care, intra venous line), he was immediately transferred to the Kouekong Regional Hospital where he received multidisciplinary care. He did not lose consciousness and complained of right craniofacial pain.

### **Evaluation:**

On arrival, the clinico-biological evaluation revealed a preserved general state and stable vital parameters.

Locally, on inspection, the large metallic foreign body was implanted around the right eye (Figure 1A), with haemorrhage and pain. The scanner (Figure 1B, 1C, 1D and 1E) made it possible to better visualize the foreign body and the lesions it had created. An angiogram was not done.

### **Management:**

**Preoperative management:** After respiratory, circulatory and neurologic stabilization, the patient was immediately taken to the operating room.

**Peroperative management:** Under general anaesthesia an initial washing was done followed by disinfection. There was a large circular scalp wound encircling the orbit, with more lacerations on its frontal part, an arciform fracture of the frontal bone, a lesion of the meninges and of the right cerebral frontal lobe with minimal haemorrhage. The right eye was destroyed by explosion and heat. There were superficial second degree burn injuries on his face, concerning 4% of his body surface area.

The foreign body was removed (Figure 1G) by two teams, neurosurgical and ophthalmological, after a direct approach and without enlargement craniectomy or flap. The right eye was totally destroyed by the explosion and the burn.

After haemostasis, abundant lavage and drainage, the meningeal lesions were repaired directly without plasty or flap and the scalp sutured (Figure 1F).

**Postoperative management:** Frontal drainage of the residual hematoma was performed for 48 hours. There were no intraoperative incidents and the patient remained stable. The patient was also given, 3 antibiotics (ceftriaxone, metronidazole and gentamycin) for 5 days without obvious signs of infection, tetanus vaccine, analgesics and local care. The postoperative course was simple regarding the involvement of the frontal lobe: no hematoma, no cerebro spinal fluid leak, no meningitis, no frontal syndrome. However, he had complete monocular blindness and paralysis of the levator oculi muscle on the right side. At 2 weeks (Figure 1H), the patient was fine and resumed work at one month postoperative. The patient is doing well at 6 months postoperative (Figure 1I) and at 10 months. This case emphasizes protective equipment, safety rules and multidisciplinary collaboration.

#### **4. Discussion**

A similar mechanism was not found in the literature limited to Medline and BMC data bases. Cranioencephalic wounds represent between three and eight percent of cranioencephalic trauma similar environment [26-29]. The diagnosis of a craniocerebral wound is confirmed during surgery by the demonstration of dural penetrating lesion by the injuring agent. Several cranioencephalic wounds with foreign body in place are reported in the recent literature [7-11; 26-29]. There is a male predominance. CT angiography should be done [23]. Angioscanner was not available for the case presented. Removal may require an enlargement craniectomy or a flap. The closure must be done under drainage. Closure of the dura mater may require autologous grafting of the scalp or the aponeurosis of the temporalis muscle [4]. These artifices were not necessary in the presented case. The burned and exposed eye could not be conserved.

Medical treatment should include intensive care, tetanus serum and vaccine therapy, antibiotics and local care as performed in our case to avoid infection as with Anan and al. in 2022. The prognosis is pejorative if the Glasgow is low, which was not the case for our patient. The patient was seen 10 months postoperatively and is doing well. The permission to publish the images was obtained.

#### **5. Conclusion**

Opened orbito-frontal wounds associated to projected and incarcerated foreign bodies, in the context of fuel explosion is a rare traumatic mechanism the main complication of which is haemorrhage and meningeal infection. Early management by a multidisciplinary team, with debridement and antibiotic prophylaxis and drainage might provide satisfactory results in minor lesions in the African context. The foreign body should never be removed prior to anaesthesia and surgery.

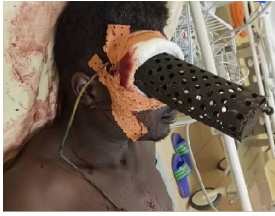## 6. References

1. Gabriela I, Michael DC and Wenshan L. Prosodic processing post traumatic brain injury - a systematic review. *Systematic Reviews*. 2017; 6(1)1-18. DOI 10.1186/s13642-017-0411-1.
2. Xavier D, Frederic B, Eric S, Mathieu H, Sandrine C, Charles-Henri Houze-Cerfon1 and Dominique Lauque1. Cutaneous impact location: a new tool to predict intracranial lesion among the elderly with mild traumatic brain injury? *Scandinavian Journal of Trauma, Resuscitation and Emergency Medicine*. 2020; 28(87):1-9. <https://doi.org/10.1186/s13049-020-00781-2>.
3. Sophie MC, Bram J, Myrthe EK, Gerard H, Gerwin R and Joukje van der N. Patients with mild traumatic brain injury and acute neck pain at the emergency department are a distinct category within the mTBI spectrum: a prospective multicentre cohort study *BMC Neurology*. 2020; 20(315):1-10. <https://doi.org/10.1186/s12883-020-01887-x>.
4. Bella HDS, Yolaine GA, Alphonse K, Donatien D, Emmanuel L and Yves C. Effect of wearing a helmet on the occurrence of head injuries in motorcycle riders in Benin: a case-control study. *Injury Epidemiology*. 2021; 8(17):1-11. <https://doi.org/10.1186/s40621-021-00311-3>.
5. Giovanni A, Matteo P, Vincenzo F and Francesca C. A cranioencephalic trauma due to electric scooter accident: could the wearing of a helmet reduce this. *Forensic Science, Medicine and Pathology* (2022) 18:264–268 <https://doi.org/10.1007/s12024-022-00477-2>.
6. Juliet H-K, Mary JP, Eric MP, Nicole H, Jessica W and Kristine Y. Epidemiology of Chronic Effects of Traumatic Brain Injury. *J Neurotrauma*. 2021 December; 38(23): 3235–3247. doi:10.1089/neu.2021.0062.
7. Diallo Moussa, Sogoba Youssouf, Kanikomo Drissa. Non-projectile penetrating head trauma by nails: an unusual case. *AJNS* 2019 Vol. 38, No. 1.
8. Jan O, Christoph M, Jonas W, Benedicta BB, Tobias E, Jana V and al. Imaging foreign bodies in head and neck trauma: a pictorial review. *Insights Imaging*. 2021; 12(20):1-16. <https://doi.org/10.1186/s13244-021-00969-9>.
9. Ling ZK, Rui Li Z, Shao Hua H and Jian Bo L. Military traumatic brain injury: a challenge straddling neurology and psychiatry. *Military Medical Research*. 2022; 9(2):1-18. <https://doi.org/10.1186/s40779-021-00363-y>.
10. Krueger EM, Moll J, Kumar R et al. Simple Wound Closure for Civilian Cranial Gunshot Wounds: A Systematic Literature Review. *Cureus*. 2022; 14(5): e25187. DOI 10.7759/cureus.25187.
11. Haoyi Q and Kunzheng L. Civilian gunshot wounds to the head: a case report, clinical management, and literature review. *Chinese Neurosurgical Journal* (2021) 7:12. <https://doi.org/10.1186/s41016-020-00227-9>.
12. Mirzaei F, Salehpour F, Shokuhi G, Asvadi Kermani T, Salehi S, Parsay S. An unusual case of intra orbital foreign body; diagnosis, management, and outcome: a case report. *BMC surgery*. 2019; 19(1):1-6.
13. Ya-Yan Y, Bing-Jie S, Xin-Yan W, Jin C, Zheng-Rong W, Xing-Hua W and Fa-Gang J. Intraorbital wooden foreign bodies: case series and literature review. *Int J Ophthalmol*. 2021; 14(10): 1619-27.
14. Yayan Y, Xinghua W, Shengnan C, Ru Z, Bowen W, Shuang L and Fagang J. Clinical analysis of 96 patients with intraorbital foreign bodies: A 10-year retrospective study. *Front. Med.* 2022. 9:1018905. doi: 10.3389/fmed.2022.1018905.

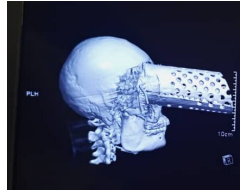
15. Santos TD, Melo AR, Moraes HH, Almeida Júnior P, Dourado E. Impacted foreign bodies in orbital region: review of nine cases. *Arquivos Brasileiros de Oftalmologia*. 2010;73:438-42.
16. Jia L, Li-Ping Z, Jing J and Hong-Feng Y. Clinical diagnosis and treatment of intraorbital wooden foreign bodies. *Chinese Journal of Traumatology* 2016 ; 19 : 322-325.
17. Ying Z, Xin K, Qiong W, Zhong Z, Jun Y and Mao Nian Z. Explosive eye injuries: characteristics, traumatic mechanisms, and prognostic factors for poor visual outcomes. *Military Medical Research* (2023) 10:3. <https://doi.org/10.1186/s40779-022-00438-4>.
18. Marina BP, Felipe BSC, Mariana BP and Juliana TDR. Epidemiology and prognosis factors in open globe injuries in the Federal District of Brazil. *Ophthalmology* (2022) 22:111. <https://doi.org/10.1186/s12886-021-02183-z>.
19. Zhitao S, Panpan Y, Jijian L, Li Z and Xiaodan H. Minimal surgery achieved good visual acuity in selected patients with magnetic intravitreal foreign body and traumatic cataract. *BMC Ophthalmology*. 2019; 19(54):1-5. <https://doi.org/10.1186/s12886-019-1065-6>.
20. Agaly H, Ndzie Essomba LD, Diallo M, Dama M, Sogoba B, Sogoba Y and Kanikomo D. Unusual Cranio-Encephalic Foreign Body with Orbital Entry Point: A propos of a Case. *Health Sci. Dis: 2021;22 (2):89-91* Available free at [www.hsd-fmsb.org](http://www.hsd-fmsb.org)
21. Hui L, Shengli H and Wei Q. Traumatic prolapse of the globe into the anterior cranial fossa: a case report. *BMC Ophthalmology*. 2020; 20(128):1-4. <https://doi.org/10.1186/s12886-020-01403-2>.
22. Massimo M, Paolo A, Luca DM, Fabio DG, Piero C and Antonino R. An unusual case of orbito-frontal rod fence stab injury with a good outcome. *BMC Surgery* 2013, 13:31. <http://www.biomedcentral.com/1471-2482/13/31>.
23. Abdolaziz H, Alireza S, Negar K. Comparison between Computed Tomography and Ultrasonography in Detecting Foreign Bodies Regarding Their Composition and Depth: An In Vitro Study. *J Dent Shiraz Univ Med Sci.*, 2016 September; 17(3): 177-184.
24. Anan W, Qihua X, Yaohua W and HL. Orbital and intracranial Nocardia farcinica infection caused by trauma to the orbit: a case report. *BMC Infectious Diseases*. 2019; 19:953 <https://doi.org/10.1186/s12879-019-4605-z>.
25. Syeda FH, Zara R, Andrew TGC, Thomas Z, Robert AM, Randy HK and Renata SMG. Traumatic brain injury and sight loss in military and veteran populations– a review. *Military Medical Research*. 2021; 8(42): 1-14. <https://doi.org/10.1186/s40779-021-00334-3>.
26. Pare P.E. Study of cranio-cerebral wounds in Senegal from the experience of the neurosurgical clinic of the University Hospital of Dakar. About 148 cases. Med thesis. Dakar 1986.
27. Sami A., Choukri M., Achouri M., Ait Benali S. Cranio-cerebral wounds about 150 cases. *Magreb Medical* 1994;278:38-9 7.
28. Sanon T. Cranio-encephalic trauma in Senegal. Apropos of 1039 cases at the neurosurgery clinic in Dakar. Thesis of Med. Dakar 1980 n° 38 8.
29. Diop Abdul Aziz, Tine Ibrahima, Hode Luphin. Cranio-encephalic wounds: epidemiological-clinical and therapeutic aspects in Dakar. *AJNS* 2011 Vol. 30, No. 1.

UNDER PEER REVIEW

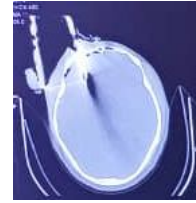
Figure 1 : Iconography



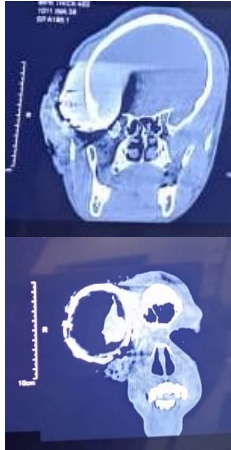
A. Aspect on admission



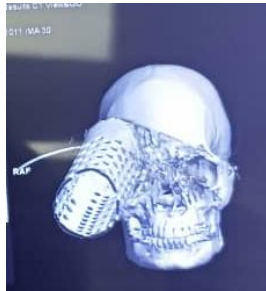B. 3D Reconstruction



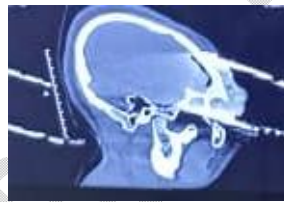
C. Horizontal section



D. Frontal view



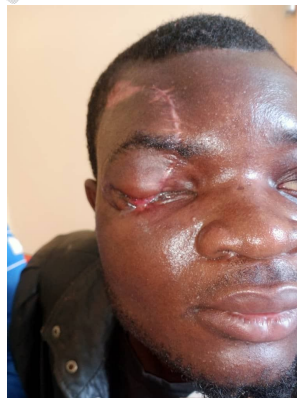E. 3D and sagittal view



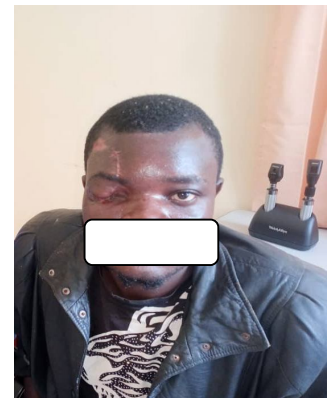F. Immediate post operative aspect



G. Removed foreign body (Fuel lock cylinder)



H. Two weeks post op



I. Six months post op