

Case report

A case of Hookworm infection in a child causing severe anemia diagnosed by endoscopy: a neglected tropical disease

Abstract

Hookworm (*Necator americanus*, *Ancylostoma duodenale*) infection are common in tropical and subtropical countries. These are still an neglected tropical disease in rural areas, leading to severe iron deficiency anemia and even mortality. Here we present a case from a tertiary care center in northern India of a 3 year old child with progressive complaint of pallor and generalised body swelling. On upper gastrointestinal gastroscopy hookworms were visualised and recovered. Patients stool sample was sent to lab in which egg of hookworm was also seen on microscopy. The child was treated with albendazole and anemia was also cured .

Key words: Hookworm, Child, Endoscopy, Severe anaemia, Infection.

Introduction

Hookworms are an important soil-transmitted helminth for humans around the world. It is estimated that about 740 million people are infected by hookworms [1]. The two main species known to cause human infection are *Ancylostoma duodenale* (*A. duodenale*) and

Necator americanus (*N. americanus*). According to reports, the major burden of infection is almost 472 million people from developing rural countries. Amongst these, the majority of cases occur in South-East Asia and Sub-Saharan Africa [2, 3]. It is estimated that hookworm disease is globally responsible for >4 million disability-adjusted life years (DALY) lost annually and a financial burden of over 100 billion US dollars per year (4). The main symptoms of hookworm infection include chronic blood loss, vomiting, abdominal pain, iron deficiency anaemia, and signs and symptoms of anaemia. Hookworm infestation is usually diagnosed by characteristic non-bile-stained oval eggs on stool microscopy and eosinophilia on blood examination [5]. Most infected individuals are asymptomatic. A heavy worm burden, prolonged duration of infection, and inadequate iron intake may result in iron deficiency anaemia (IDA) and hypoproteinemia [6]. Hookworm infection is most common in the paediatric population, as children are more likely to acquire the infection when they start to crawl or walk. Hookworm infection in children can lead to severe acute malnutrition and failure to thrive if not diagnosed and treated on time [7].

Case Report

A 3-year-old female child was admitted with complaints of progressive pallor of the body for 3 months and generalised body swelling for 1 month. These symptoms were followed by loose stools around 6 times per day with a small amount of blood and mucus for 3 days, which were watery in consistency and small in volume and not associated with perianal excoriation. The symptoms of diarrhoea subsided within 6 days. There was no history of coughing, loss of appetite, respiratory distress, decreased urine output, hematuria, recurrent chest infections, or other site infections.

On examination, weight was 8.3 kg with edema; height was 83 cm (less than the 3rd centile); mid-upper arm circumference (MUAC) was 10 cm; Vitals: HR-88/min, RR-20/min, B.P.-98/70 mmHg; pallor was present; bilateral pitting with periorbital puffiness. The child also had frontal bossing and angular cheilitis. There was no history of icterus or any significant lymphadenopathy. Lab investigations report showed hemogram: Hb 4.8 g/dl, TLC 18.2 X 1000/l (N-56, L-40, E-2) and platelet- count: 200 X 1000/cumm. Retic -3.1 %, serum sodium: 126; potassium: 2.8; calcium: 0.97. Serum iron study reports showed iron at 38 g/dl, ferritin at 32 g/dl, total iron binding capacity (TIBC) at 173 g/dl, transferrin saturation at 4.5%, B12 at 283 pmol/l, and folate at 9 ng/ml, suggesting iron deficiency anaemia. The child had anasarca with low serum albumin (1.5 g/dl).

On upper gastrointestinal endoscopy, worms were seen shown in figure 1. A duodenal aspirate with a single worm (shown in figure 2) and two consecutive stool samples were sent for microscopy to the parasitology lab. The worm was identified as adult female hookworm on DPDx mount with pointed posterior tail shown in figure 3. On microscopy, a saline mount of concentrated duodenal aspirate showed non-bile-stained hookworm eggs, as shown in Figure 4. The routine microscopy of the first stool sample was negative for any ova, cyst, trophozoite, or larvae, but the second stool sample showed an ovum of hookworm with no cyst, trophozoite, or larvae.

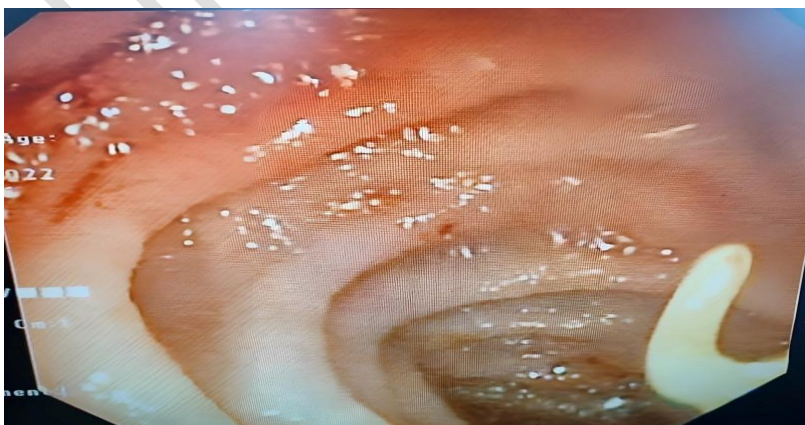

Figure 1. Upper gastrointestinal endoscopy showing adult hookworm

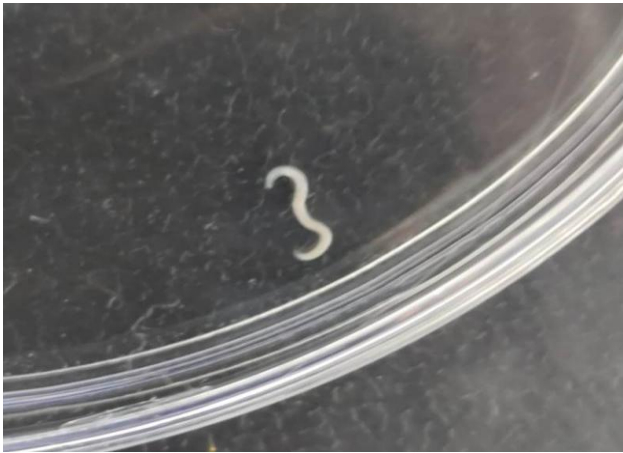

Figure 2. Adult Worm detected in duodenal aspirate

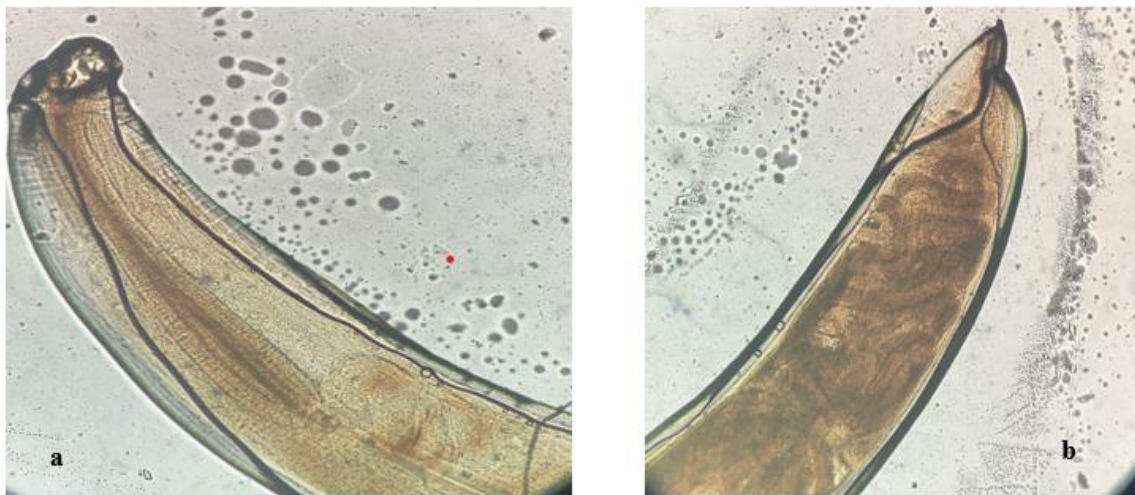


Figure 3. a) Anterior end , b) Posterior pointed end of adult female hookworm

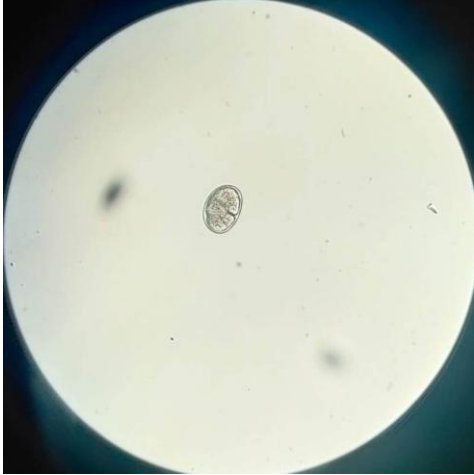


Figure 4. 40X Microscopic view of egg of hookworm in duodenal aspirate

The child had severe microcytic hypochromic anaemia due to iron deficiency, hookworm infestation, low albumin, and generalised anasarca. The child was transfused with two units of packed RBC (PRBC) during hospitalisation for severe anaemia, and post-blood transfusion haemoglobin improved to 8.5 g/dl. Injections of albumin were given, after which serum albumin increased to 2.7 and edema started to reduce. The child was also started on severe acute malnutrition (SAM) supplements, and nutritional rehabilitation was done. Initially, the patient was given a F75 diet, followed by a F100 diet. The child was treated with albendazole 400 mg in a single dose.

Discussion

As per the recent reports in India, a higher prevalence of hookworm infection is estimated than for other soil-transmitted helminths (STH). In India, 258 million (or 1 in 5) individuals

are estimated to be infected with STH, with 148 million *Ascaris*, 109 million hookworm, and 41 million *Trichuris* infections [8]. Long-term consequences of hookworm infection include both iron deficiency anaemia and protein malnutrition, which result in stunted growth and poor cognitive capacity in children [9]. The importance of prevention and timely diagnosis of hookworm infection is more relevant in India, as more than half of the under-5-year-old children are stunted [10]. In endemic areas, hookworm infection often occurs despite drug treatment. Thus, there is a need for vaccine development to prevent infection. Mebendazole and albendazole are the currently approved drugs against hookworm infection and are used against multiple helminth species.

Conclusion

In our case after the treatment with albendazole, the child improved clinically with no edema, normal haemoglobin levels and was discharged. However, their efficacy in curing hookworm infections is rather limited, reducing the infection burden by more than 90%. Oral vaccines are under research, and a strategy of mass immunisation would be highly beneficial in hookworm-endemic areas [11].

Ethical Approval:

As per international standard or university standard written ethical approval has been collected and preserved by the author(s).

Consent

As per international standard or university standard, Parental' written consent has been collected and preserved by the author(s).

References

1.Hotez PJ, Bethony J, Bottazzi ME, Brooker S, Buss P. Hookworm: “The great infection of mankind”. PLoS Med 2005;2:e67.

2. Jourdan PM, Lamberton PHL, Fenwick A, Addiss DG. Soil-transmitted helminth infections. *Lancet*. 2018;391:252–65.
3. Warren KS, Bundy DA, Anderson RM, Davis AR, Henderson DA, Jamison DT et al. Helminth infection. In: Jamison DT, Mosley WH, Measham AR, Bobadilla JL, editors. *Disease Control Priorities in Developing Countries*. 1st ed. New York: Oxford University Press; 1993. P.131-60.
4. Grosby WH. The deadly hookworm. Why did the Puerto Ricans die? *Arch Intern Med* 1987; 147:577-9.
5. Wu KL, Hsu SK, Chiu KW, Chiu YC, Changchien CS. Endoscopic diagnosis of Hookworm Disease of the Duodenum: A Case Report. *J Int Med Taiwan* 2002; 13:27-30.
6. Kuo YC, Chang CW, Chen CJ, Wang TE, Chang WH, Shih SC. Endoscopic diagnosis of hookworm infection that caused anemia in an elderly person. *Int J Gerontol* 2010; 4:199-201.
7. Umbrello, G., Pinzani, R., Bandera, A. *et al.* Hookworm infection in infants: a case report and review of literature. *Ital J Pediatr* **47**, 26 (2021).
8. Lai YS, Biedermann P, Shrestha A, Chammartin F, N AP, Montresor A, et al. Risk profiling of soil-transmitted helminth infection and estimated number of infected people in South Asia: A systematic review and Bayesian geostatistical Analysis. *PLoS Negl Trop Dis*. 2019; 13(8):e0007580. <https://doi.org/10.1371/journal.pntd.0007580> PMID: 31398200
9. Jill E, Weatherhead, Hotez PJ. Worm Infections in Children. *Pediatr Rev*. 2015;36:341.
10. Government of India. National Family Health Survey (NFHS-4)- 2015–2016. [Internet]. 2018. [cited 2020 Apr 27].
11. Shalash AO, Hussein WM, Skwarczynski M, Toth I. Hookworm infection: Toward development of safe and effective peptide vaccines. *The Journal of Allergy and Clinical Immunology*. 2021 Dec;148(6):1394-1419.e6. DOI: 10.1016/j.jaci.2021.10.013. PMID: 34872650.

UNDER PEER REVIEW