

Case study

RARE CASE OF SCAR ECTOPIC PREGNANCY : PRESENTING AS MISSED ABORTION

Abstract:

*Scar ectopic pregnancy is one of the **rarest form** of ectopic pregnancy It is a life-threatening form of abnormal implantation of embryo within the myometrium and fibrous tissues in a previous scar on the uterus, especially following caesarean section*

*The **early and accurate diagnosis** with timely management can prevent pregnancy complications such as haemorrhage, uterine rupture and can preserve fertility ⁽¹⁾*

Key words: *Scar Ectopic, Caesarean , Pregnancy, TVS , Haemorrhage, Uterine Rupture,*

Introduction:

UNDEP DEED REVIEW

Scar ectopic pregnancy is becoming increasing common all over the globe. It is novel and life-threatening form of abnormal implantation of embryo within the myometrium and the fibrous tissue of the previous scar following caesarean section; hysterotomy; dilation and curettage; abnormal placentation; surgery on uterus like myomectomy, metroplasty, hysteroscopy and manual removal of placenta. (1)

Two different types of scar ectopic pregnancies are identified. Type I is caused by implantation in the prior scar with progression towards the cervicoisthmic (in prior caesarean section) space or the uterine cavity. Type II is caused by deep implantation into scar defect with infiltrating growth into the uterine myometrium and to uterine serosal surface which may result into uterine rupture and massive haemorrhage in first trimester of pregnancy which is most dangerous. (1)

The most frequent symptom is painless vaginal bleeding usually in the first trimester It has been reported by Rotas et al. [3] in their series that 37 % women were asymptotic, 39 % women had scanty, painless vaginal bleeding, and 16 % had mild-to-intense pain in abdomen. Nine per cent of women had only pain in abdomen.

In 2011, Yu et al. [4] reported in their series of 100 cases with scar ectopic pregnancies that 45 % patients were asymptomatic, 55 % had vaginal bleeding, and 7 % had pain in lower abdomen.

Sometimes, undiagnosed scar ectopic pregnancy can present with heavy bleeding, haemoperitoneum and shock after termination of early pregnancy or missed abortion [5].

Sonography is the first-line diagnostic tool for Cesarean scar pregnancy. The diagnosis can be made by visualizing enlargement of the cesarean scar and a mixed mass or clear gestational sac at the site of the scar. A very thin layer of myometrium should be seen separating the maternal urinary bladder wall and the gestational sac [7]. This latter finding may be best appreciated using MRI [8]

Magnetic Resonance Imaging (MRI) also has important role when sonography is equivocal or inconclusive before therapy or intervention. (2)

Clinical Presentation:

A **25yr Female** patient presented to JNMCH Emergency Department, Aligarh with 2 months amenorrhea and marked bleeding per vaginum. She had history of **previous 2 caesarean section** done due to fetal distress.

In view of pregnancy, the initial TVS imaging was reported as retained product of conception leading to misdiagnosis of the case as **incomplete abortion**.

Dilatation and curettage was done and the patient was discharged subsequently.

In the next few days the patient had continuous episodes of bleeding p/v which lead to development of hemorrhagic shock. Blood transfusion was initiated and the patient was stabilized. **B-HCG was found to be raised (7500mIU/L)** which showed an increasing trend in the subsequent days.

Further imaging lead to the diagnosis of **scar ectopic on TVS and MRI**.

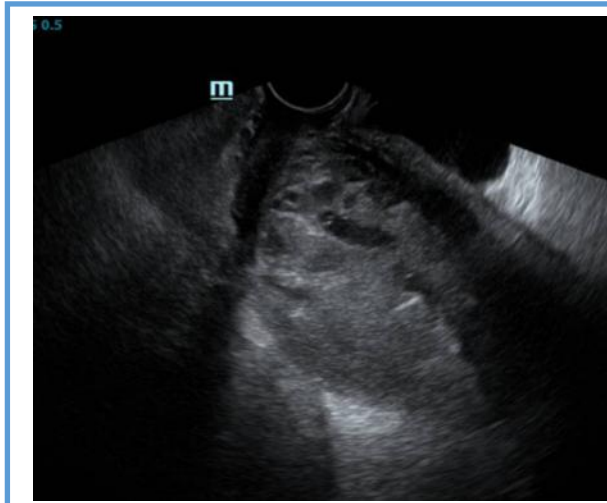
Imaging:**TVS Scan**

FIGURE 1a

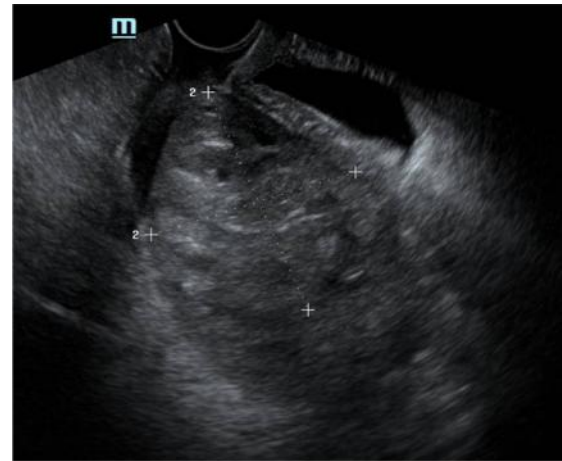

FIGURE 1b

Figure 1a , 1b : Heterogenous mass with hypo echoic areas within it in lower uterine segment. Mass is bulging into bladder anteriorly

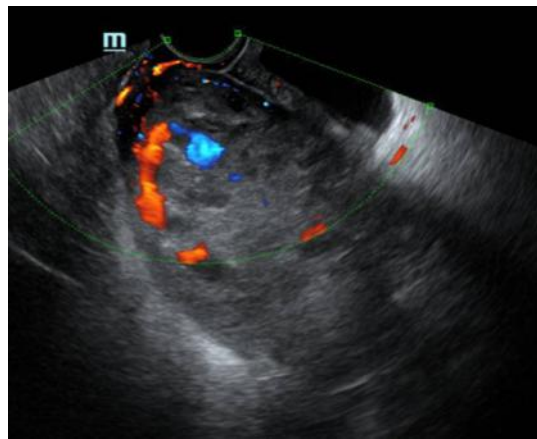


Figure 2

Figure 2: Doppler examination shows heterogenous mass with hyperechoic rim with excessive vascularity was seen in lower uterine segment. The mass is bulging anteriorly and infiltrating into bladder.

MRI PELVIS

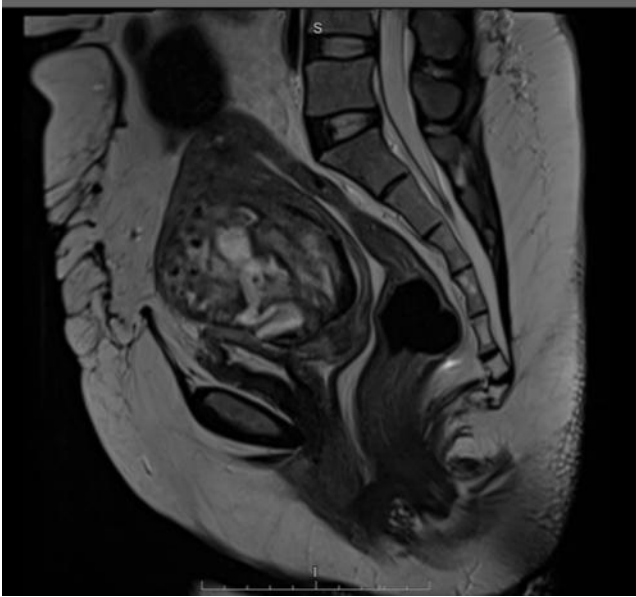


IMAGE 2: T2WI SAG

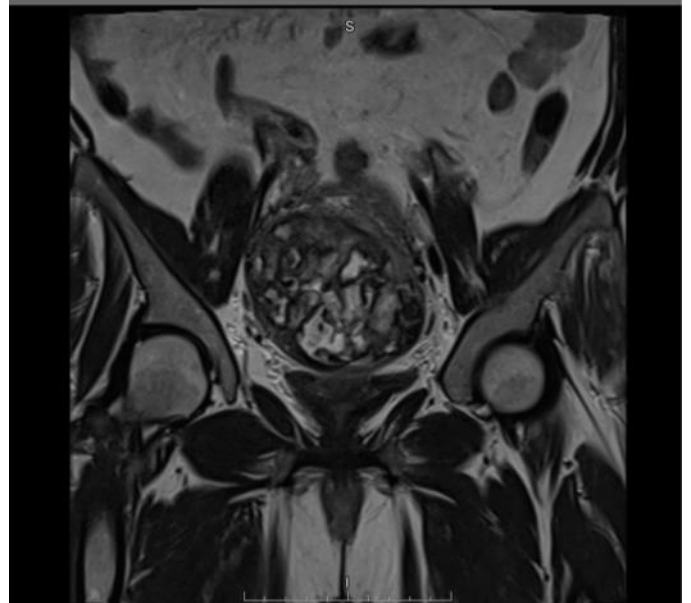
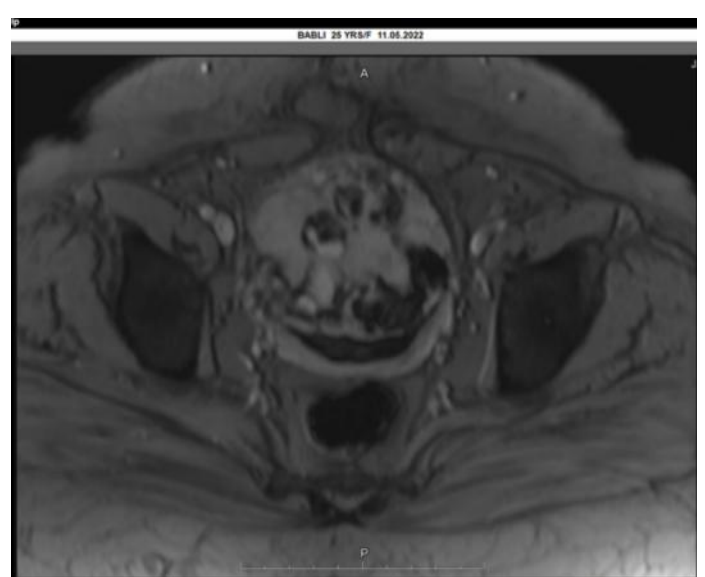


IMAGE 3: T2WI COR

IMAGE 4: T1WI TRA

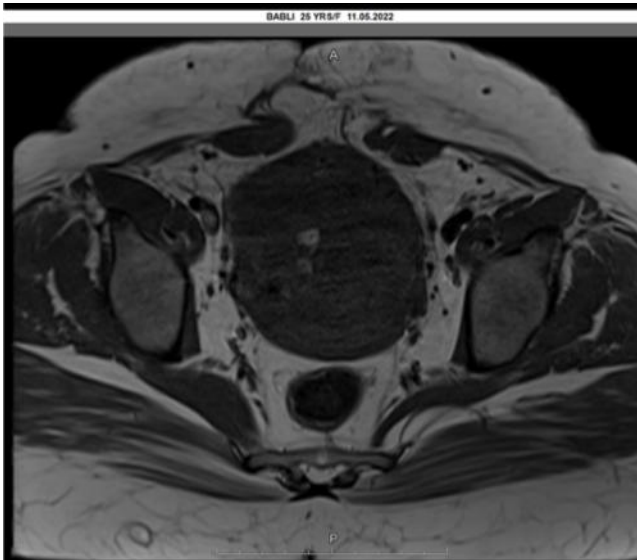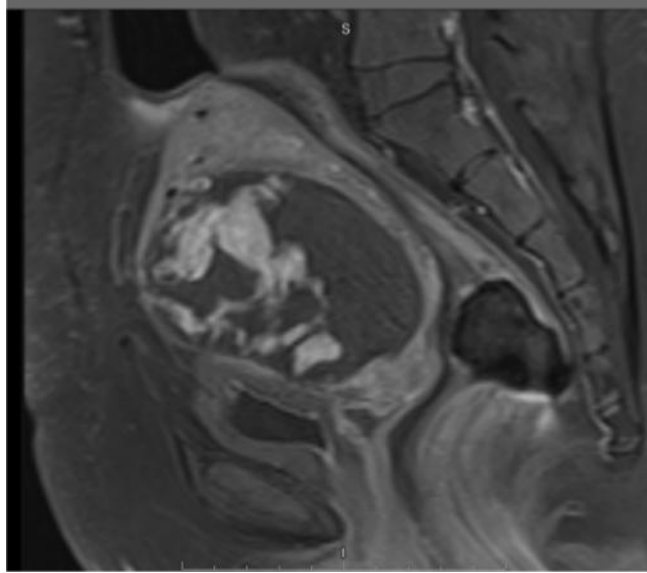


IMAGE 5: GRE



UNDER PEER REVIEW

IMAGE 6: T1Post Contrast FS SAG



UNDER PEER REVIEW

Interpretation and Diagnosis

The images (Figure 2,3,4,5,6) show an altered signal intensity lesion with areas of T1/T2 hyper intensity showing blooming on GRE (hemorrhagic areas) at lower uterine segment at caesarean scar site . The lesion is eccentrically bulging out anteriorly and is having focally indistinct margins with superior aspect of urinary bladder

Post contrast images (Figure 6) shows strong heterogeneous enhancement within the solid areas of the lesion with non-enhancing hemorrhagic areas. Contrast enhancement is noted in superior aspect of bladder indistinct with the ectopic tissue (Infiltration) S/O Grade IV Ectopic pregnancy at scar site

The posterior wall of lower uterine segment and fundus of uterus appear normal with normal endometrium within the fundus and upper uterine body.

Discussion:

Scar ectopic pregnancy is one of the rarest type of ectopic pregnancy. It can closely mimic retained product of conception both clinically and radiographically unless there is a high index of suspicion.

Many times, it does not have any specific symptom and can be easily misdiagnosed. This can lead to life-threatening haemorrhage during pregnancy or curettage, uterine rupture, disseminated intravascular coagulation and even a death.

Transvaginal ultrasound equipped with color Doppler imaging may serve as an additional tool to augment the diagnostic capabilities of transvaginal ultrasound; high-velocity, prominent, low-impedance blood flow can be detected surrounding an ectopic gestational sac, consistent with normal early pregnancy (6)

Radiologists should be familiar with these features and should always consider the possibility of ectopic pregnancy in the setting of hemoperitoneum or a pelvic mass in a woman of child-bearing age. (9)

UNI *MRI offers the benefits of multiplanar imaging, lack of ionizing radiation, greater soft-tissue contrast than sonography, and more-specific characterization of tissues and fluids [10]*

PATIENT COURSE

*The patient was initiated on methotrexate therapy and subsequent **B HCG levels showed a gradual declining trend.** However the patient continued bleeding per vaginum and further lapratomy was done.*

It revealed a vascularized mass adhered to lower uterine segment at the scar site with infiltration into bladder.Histopathology of the specimen confirmed the diagnosis of scar ectopic pregnancy

CONCLUSION:

Caesarean scar ectopic pregnancies can have very catastrophic outcomes, such as uterine rupture, significant hemorrhage, and maternal mortality. To prevent complications and maintain fertility, it is crucial to get an early and precise diagnosis. TVS and Color flow Doppler are highly useful for its diagnosis. When sonography is ambiguous or inconclusive prior , MRI plays a crucial role due to characteristic imaging features.

CONSENT

Written informed consent was obtained from the patient for publication of this case report and accompanying images.

Ethical clearance was obtained from the Ethical Committee.

REFERENCES:

- 1) Patel MA. Scar Ectopic Pregnancy. *J Obstet Gynaecol India*. 2015 Dec;65(6):372-5. doi: 10.1007/s13224-015-0817-3. Epub 2015 Nov 21. PMID: 26663994; PMCID: PMC4666214.
- 2) Deepika, Gupta T, Wahi S. A Rare Case Report of Caesarean Scar Ectopic Pregnancy. *J Clin Diagn Res*. 2017 Aug;11(8):QD10-QD11. doi: 10.7860/JCDR/2017/24611.10523. Epub 2017 Aug 1. PMID: 28969218; PMCID: PMC5620859.
- 3) Rotas MA, Haberman S, Levгур M. Cesarean scar ectopic pregnancies: etiology, diagnosis and management. *Obstet Gynecol*. 2006;107:1373–1377. doi: 10.1097/01.AOG.0000218690.24494.ce
- 4) Yu XL, Zhang N, Zuo WL, et al. Cesarean scar pregnancy: an analysis of 100 cases. *Zhonghua Yi Xue Za Zhi*. 2011;91(45):3186–3189
- 5) Timor-Tritsch IE, Monteagudo A, Santos R, et al. The diagnosis, treatment and follow-up of cesarean scar pregnancy. *Am J Obstet Gynecol*. 2012;207:44–46. doi: 10.1016/j.ajog.2012.03.007.
- 6) Jurkovic D, Jauniaux E, Kurjak A, Hustin J, Campbell S, Nicolaides KH. Transvaginal color Doppler assessment of the uteroplacental circulation in early pregnancy. *Obstet Gynecol* 1991; 77: 365– 369.
- 7) Maymon R, Halperin R, Mendlovic S, Schneider D, Herman A. Ectopic pregnancies in a caesarean scar: review of the medical approach to an iatrogenic complication. *Hum Reprod Update* 2004; 10:515–523
- 8) Chiang AJ, La V, Chou CP, Wang PH, Yu KJ. Ectopic pregnancy in a cesarean section scar. *Fertil Steril* 2011; 95:2388–2389m

9) Linda Y. Kao, Meir H. Scheinfeld, Victoria Chernyak, et al *Beyond Ultrasound: CT and MRI of Ectopic Pregnancy. AJR, Volume 202, Issue 4*
<https://doi.org/10.2214/AJR.13.10644>

10) Singh AK, Desai H, Novelline RA. *Emergency MRI of acute pelvic pain: MR protocol with no oral contrast. Emerg Radiol 2009; 16:133–141*

UNDER PEER REVIEW