

Case report

Acute Appendicitis with Concomitant Typhoid Fever: A Case Report

ABSTRACT

Typhoid fever is one of the leading causes of mortality and morbidity in crowded and unhygienic areas. Acute appendicitis is a relatively common cause of acute abdomen, especially in young adults. Infection with *Salmonella typhi* can be a rare cause of acute appendicitis. A 40-year-old man was admitted to Emergency Department with complaints of fever, abdominal pain, nausea, and vomiting for more than a week. His vital signs were stable. Physical examinations showed hyperactive bowel sounds (borborygmus), tenderness in the right lower quadrant region, and a positive Rovsing sign. The complete blood count and other laboratory results were within normal limits, as the patient had received oral antibiotics while on treatment at another hospital before. IgM anti-*S. typhi* was positive. Abdominal ultrasound revealed a blind end tube, a non-peristaltic, non-compressible appendix showing a target sign, and fluid collection periappendiceal. The patient underwent appendectomy on the fourth day of treatment, and the pathological examinations revealed that the mucosa was necrotic and that a large number of lymphoid follicles were evident. Typhoid fever may manifest as mesenteric lymphadenopathy, ileocolitis, or even bowel perforation, which mimics appendicitis. Appendicitis is usually caused by appendiceal lumen occlusion. Less frequently, enteric infections could directly infect the appendix or cause localized appendiceal lymphoid hyperplasia with obstruction. It is unclear whether primary appendicular lumen obstruction brought on by lymphoid hyperplasia or direct bacterial invasion of the appendix causes acute appendicitis and typhoid fever. There is no proof that the pathogen directly invades the appendix or that it obstructs it through proliferating lymph nodes. This case might remind clinicians that appendicitis might be a potential but uncommon differential diagnosis for typhoid fever in patients who have persistent abdominal pain, nausea, vomiting, and fever. We suggest performing a culture on appendix tissue in future studies to determine whether the bacteria that cause typhoid fever and acute appendicitis are related.

Keywords: *Acute Appendicitis, Concomitant Typhoid Fever, Case Report, Appendicitis Diagnosis, Typhoid Fever Diagnosis*

Introduction

Typhoid fever is one of the leading causes of mortality and morbidity in crowded and unclean regions, caused by human-specific food and water-borne pathogens, such

as *Salmonella enterica* subspecies, enterica serovar typhi (*S. typhi*) or by *Salmonella paratyphi* A, B, and C, collectively called typhoidal *Salmonella*.¹

In 2019, an updated study estimated 9.2 million (95% CI = 5.9–14.1) typhoid fever cases and 110,000 (95% CI = 53,000–191,000) deaths worldwide, with the WHO South-East Asian region having the highest estimated incidence (306 cases per 100,000 people).² In Indonesia, the average incidence of typhoid fever is 500 per 100,000 individuals, with a mortality rate of 0.6–5%.³ The Report on Basic Health Research 2018 of the Indonesian Ministry of Health found that 1.7% of Indonesians had typhoid fever.^{4,5} In Semarang, one of the provincial capitals in Indonesia, the incidence of typhoid fever was the second most common disease that caused hospitalization in 2018.^{6,7,8}

The disease condition progresses from early gastrointestinal distress to nonspecific systemic illness, with numerous consequences possible.⁹ Since the illness can cause hyperplasia in the appendix's lymphoid tissue or direct luminal invasion, typhoid fever may have appendicitis as its predominant presentation.¹⁰

There are few reports of appendicitis appearing in typhoid fever.¹¹ We present a case of a 40-year-old man with typhoid fever who developed acute appendicitis and required an emergency appendectomy.

CASE PRESENTATION

A 40-year-old man was admitted to our hospital with complaints of fever, abdominal pain, nausea, and vomiting for more than a week. He was treated with omeprazole, cefadroxil, and acetaminophen for two days in another hospital, but the complaint has not improved. At the time of admission, his vital signs were blood pressure: 124/72 mmHg, heart rate: 86 beats per minutes, respiratory rate: 20 times per minutes, and temperature: 36.5°C

¹ “Habte L, Tadesse E, Ferede G, Amsalu A. Typhoid Fever: Clinical Presentation and Associated Factors in Febrile Patients Visiting Shashemene Referral Hospital, Southern Ethiopia. *BMC Res Notes*. 2018 Aug 22;11(1):605.”; “Bhandari J, Thada PK, DeVos E. Typhoid Fever. 2022 Aug 10. In: *StatPearls*. Treasure Island (FL): StatPearls Publishing; 2023 Jan–. PMID: 32491445.”

² “Institute for Health Metrics and Evaluation. Typhoid Fever–Level 4 Cause. Seattle, WA: Institute for Health Metrics and Evaluation, Global Burden of Disease Collaborative Network; 2020.”

³ Xena and Aliviameita, “The Relationship of Differential Counting with the Erythrocyte Sedimentation Rate in Patients with Typhoid Fever.”

⁴ Arif et al., “Chikungunya in Indonesia: Epidemiology and Diagnostic Challenges.”

⁵ “[RISKESDAS] Riset Kesehatan Dasar. 2018. Jakarta: Badan Penelitian Dan Pengembangan Kesehatan, Departemen Kesehatan, Republik Indonesia.”

⁶ “Dinas Kesehatan Kota Semarang. 2018. Profil Kesehatan Kota Semarang Tahun 2018. Semarang.”

⁷ Soedarmono et al., “The Characteristics of Bacteremia among Patients with Acute Febrile Illness Requiring Hospitalization in Indonesia.”

⁸ Merati et al., “Prevalence of HIV Infection and Resistance Mutations in Patients Hospitalized for Febrile Illness in Indonesia.”

⁹ “Bhandari J, Thada PK, DeVos E. Typhoid Fever. 2022 Aug 10. In: *StatPearls*. Treasure Island (FL): StatPearls Publishing; 2023 Jan–. PMID: 32491445.”

¹⁰ “Mehrabani S. Acute Appendicitis Associated With Typhoid Fever: A Case Report and Review of Literature. *Journal of Pediatrics Review*. 2020; 8(4):255-260.”

¹¹ “Sartori DJ, Sun K, Hopkins MA, Sloane MF. Typhoid Fever and Acute Appendicitis: A Rare Association Not yet Fully Formed. *Case Reports in Gastroenterology*. 2017; 11(2):446-51.”; “Wong SY, Lee SKL, Er C, Kuthiah N. Appendicitis in Non- Typhoidal Salmonella Bacteraemia. *Oxford Medical Case Reports*. 2018; 2018(11):Omy082.”

Physical examinations showed hyperactive bowel sounds (borborygmus), tenderness in the right lower quadrant region, and a positive Rovsing sign. Laboratory test results were as follows: CBC (complete blood count): leukocytes: $7.82 \times 10^3 / \mu\text{L}$; segment neutrophils: 54%; lymphocytes; 34%; monocytes: 6%; eosinophils: 5%; basophils: 1%; hemoglobin: 15.2 g/dL; platelets: $346 \times 10^3 / \mu\text{L}$. IgM anti *S. typhi* was positive. Other laboratory results were within normal limits. Patient was treated with ceftriaxone injections for three days, but the symptoms still have not improved. On the 4th day of admission, laboratory results showed an increase in leukocytes ($9.44 \times 10^3 / \mu\text{L}$). His abdominal ultrasound revealed an enlarged, non-peristaltic, and non-compressible blind-ended loop of his appendix and a fluid collection periappendiceal (Figure 1). Therefore, metronidazole injections were added to the patient's medications to cover the treatment of acute appendicitis.

After a surgical consultation, the patient underwent appendectomy 4 days after admission. His pathological examinations revealed that the mucosa was necrotic and a large number of lymphoid follicles were evident (Figure 2). After surgery, ciprofloxacin was added to the patient's medications. The patient was thus treated with ceftriaxone for six days, metronidazole for four days, and ciprofloxacin for two days during hospital admission. He was then discharged in good condition and has remained well since then.

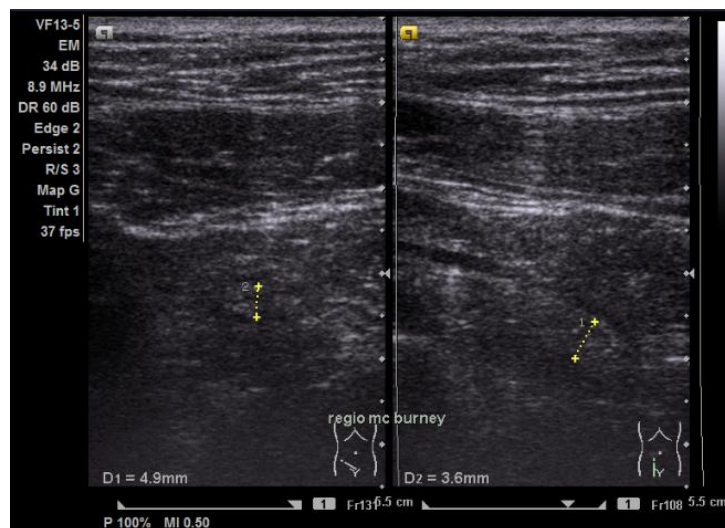


Figure 1. Ultrasound of the McBurney area (transverse view) reveals a blind end tube, a non-peristaltic, non-compressible appendix showing a target sign, and fluid collection periappendiceal.

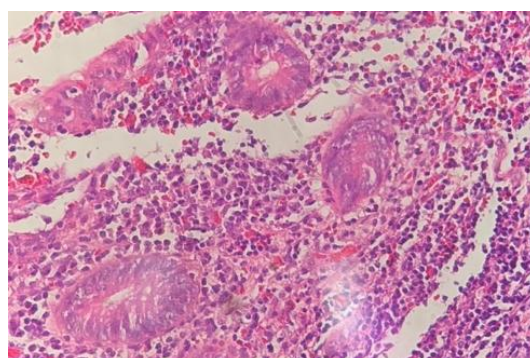


Figure 2. H&E (Hematoxylin-Eosin), M40x staining post-laparoscopic appendectomy demonstrating reactive lymphoid follicles.

DISCUSSION

Typhoid fever may manifest as mesenteric lymphadenopathy, ileocolitis, and even bowel perforation, which mimic appendicitis.¹² *Salmonella Typhi* could multiply in the submucosa, leading to Peyer's patches, mesenteric lymphoid hyperplasia, and intestinal tissue hypertrophy. Abdominal pain and any resulting ileal bleeding, perforation, or hypertrophy of the submucosal tissues may be the cause. Patients with enteric fever are likely to develop secondary bacteremia with additional species due to macroscopic or microscopic breaches in the intestinal mucosal barrier.¹³

Culture isolation of the pathogenic bacterium in typhoid fever patients remains the gold standard for diagnosis. Culture is the most reliable method of identifying typhoid in infected patients, and it is commonly done with blood, however bone marrow culture has a higher sensitivity. However, in most underdeveloped nations, a serological test is used.¹⁴ In our patient, the diagnosis of typhoid fever was carried out by anti *S. typhi* IgM rapid test due to limited resources.

Appendicitis is usually caused by appendiceal lumen occlusion. This may result from an appendicolith (appendix stone) or another mechanical cause. Appendiceal occlusion and appendicitis are both known to be caused by appendiceal tumors, including carcinoid tumors, appendiceal adenocarcinomas, intestinal parasites, and hypertrophied lymphatic tissue. Acute appendicitis typically has an uncertain exact cause. Bacteria accumulate in the appendix as a result of obstruction of the appendiceal lumen, resulting in acute inflammation, perforation, and abscess formation.¹⁵ Less frequently, enteric infections could directly infect the appendix or cause localized appendiceal lymphoid hyperplasia with an obstruction.¹⁶

Very few cases of acute appendicitis are preceded by enteritis that has been verified by culture. It is unclear whether primary appendicular lumen obstruction brought on by

¹² “Mehrabani S. Acute Appendicitis Associated With Typhoid Fever: A Case Report and Review of Literature. *Journal of Pediatrics Review*. 2020; 8(4):255-260.”

¹³ “Toapanta FR, Bernal PJ, Fresnay S, Darton TC, Jones C, Waddington CS, et Al. Oral Wild-Type *Salmonella Typhi* Challenge Induces Activation of Circulating Mono- Cytes and Dendritic Cells in Individuals Who Develop Ty- Phoid Disease. *PLoS Neglected Tropica*”; “Ochoa TJ, Santisteban-Ponce J. *Salmonella*. In: Cherry JD, Demmler-Harrison GJ, Kaplan SL, Steinbach WJ, Ho- Tez PJ, Editors. *Feigin and Cherrys Textbook of Pediatric Infectious Diseases*. London: Elsevier; 2019. p. 1066-81.”

¹⁴ “Ajibola O, Mshelia MB, Gulumbe BH, Eze AA. Typhoid Fever Diagnosis in Endemic Countries: A Clog in the Wheel of Progress? *Medicina (Kaunas)*. 2018 Apr 25;54(2):23. Doi: 10.3390/Medicina54020023. PMID: 30344254; PMCID: PMC6037256.”

¹⁵ “Jones MW, Lopez RA, Deppen JG. Appendicitis. [Updated 2022 Oct 24]. In: StatPearls. Treasure Island (FL): StatPearls Publishing; 2023 Jan-.”

¹⁶ “Lamps LW. Infectious Causes of Appendicitis. *Infectious Disease Clinics of North America*. 2010; 24(4):995-101.”

lymphoid hyperplasia or direct bacterial invasion of the appendix causes acute appendicitis and typhoid fever.¹⁷

Wong et al. reported a 78-year-old man presented with fever, cough, diarrhoea, and vomiting for a day. Stool and blood cultures were positive for non-typhoidal Salmonella species. A computed tomography (CT) aortogram showed an enlarged, fluid-filled appendix with hyperenhancement of the wall, minimal adjacent fat stranding, and small mesenteric nodes in the right iliac fossa, was found. He was treated conservatively due to multiple comorbidities. His condition improved after the completion of 2 weeks of antibiotics guided by the blood and stool culture results.¹⁸

Zheng et al. reported a 25-year-old man presented to the hospital with a 3-d history of fevers, vomiting, and abdominal pain. Computed tomography (CT) revealed a thickened intestinal wall of the ileocecal junction with multiple enlarged lymph nodes nearby. He was diagnosed with acute appendicitis and received laparoscopic appendectomy, which showed mild inflammation of the appendix. After the surgery, the patient presented again with a high fever (>39 °C) and diarrhoea. According to the blood culture, the diagnosis was finally clear: Salmonella typhi infection. The pyrexia and enteric symptoms were relieved after the application of intravenous levofloxacin.¹⁹

In this report, a 40-year-old man was admitted to our hospital with complaints of fever, abdominal pain, nausea, and vomiting for more than one week. The patient was diagnosed with typhoid fever due to a positive anti S.typhi IgM. Given that the patient's complaint had not changed and that the McBurney area was painful, we suspected that the patient had acute appendicitis. Contrast-enhanced CT is the first-line imaging test for diagnosing appendicitis in adults (sensitivity: 85.7%–100%, specificity: 94.8%–100%).²⁰ However, we did an abdominal ultrasound, which showed a picture of acute appendicitis due to cost limitations.

Due to widespread resistance to older, first-line antibiotics, the World Health Organisation (WHO) presently advises treating typhoid fever with azithromycin, ciprofloxacin, or ceftriaxone.²¹ According to the 2017 WSES recommendations, the empiric antibiotic regimens for non-critically ill patients with community-acquired intra-abdominal infections include amoxicillin/clavulanate 1.2–2.2 g 6 hourly, ceftriazone 2 hourly + metronidazole 500 ml 6 hourly, or cefotaxime 2 hourly + metronidazole 500 ml 6 hourly.²² In

¹⁷ “Sartori DJ, Sun K, Hopkins MA, Sloane MF. Typhoid Fever and Acute Appendicitis: A Rare Association Not yet Fully Formed. Case Reports in Gastroenterology. 2017; 11(2):446-51.”

¹⁸ “Wong SY, Lee SKL, Er C, Kuthiah N. Appendicitis in Non- Typhoidal Salmonella Bacteraemia. Oxford Medical Case Reports. 2018; 2018(11):Omy082.”

¹⁹ “Zheng BH, Hao WM, Lin HC, Shang GG, Liu H, Ni XJ. Samonella Typhi Infection-Related Appendicitis: A Case Report. World J Clin Cases. 2021 Oct 16;9(29):8782-8788.”

²⁰ “Garcia EM, Camacho MA, Karolyi DR, et Al.; Expert Panel on Gastrointestinal Imaging. ACR Appropriateness Criteria: Right Lower Quadrant Pain—Suspected Appendicitis. J Am Coll Radiol 2018; 15(Suppl 11):S373–S387.”

²¹ “Kuehn R, Stoesser N, Eyre D, Darton TC, Basnyat B, Parry CM. Treatment of Enteric Fever (Typhoid and Paratyphoid Fever) with Cephalosporins. Cochrane Database Syst Rev. 2022 Nov 24;11(11):CD010452.”

²² “Sartelli M, Chichom-Mefire A, Labricciosa FM, et Al. The Management of Intra-Abdominal Infections from a Global Perspective: 2017 WSES Guidelines for Management of Intra-Abdominal Infections. World J Emerg Surg. 2017;12:29.”

this study, the patient was treated with ceftriaxone for six days, metronidazole for four days, and ciprofloxacin for two days during hospital admission.

There is no proof that the pathogen directly invades the appendix or that it obstructs it through proliferating lymph nodes.²³ In the current study, the pathology examination supported the diagnosis of acute appendicitis and demonstrated that appendectomy may have been the best course of treatment. These data suggested that acute appendicitis should be considered a differential diagnosis in cases with persistent abdominal pain, nausea, vomiting, and fever.²⁴

In this case report, we found several limitations due to limited resources, which serves as a reminder to clinicians that some improvements would have been needed in our clinical practice. First of all, more attention is needed if patients with typhoid fever have not improved with standard antibiotics, especially with the main complaints of abdominal pain and diarrhoea. And second, culture and antibiotic sensitivity are needed, especially in appendix samples, to establish whether the cause of appendicitis is salmonella or a non-salmonella agent.

CONCLUSION

This case might remind clinicians that appendicitis might be a potential but uncommon differential diagnosis for typhoid fever in patients who have persistent abdominal pain, nausea, vomiting, and fever. We suggest performing a culture on appendix tissue in future studies to determine whether the bacteria that cause typhoid fever and acute appendicitis are related.

Ethical Approval:

As per international standard or university standard written ethical approval has been collected and preserved by the author(s).

Consent

As per international standard or university standard, patient(s) written consent has been collected and preserved by the author(s).

REFERENCES

- “[RISKESDAS] Riset Kesehatan Dasar. 2018. Jakarta: Badan Penelitian Dan Pengembangan Kesehatan, Departemen Kesehatan, Republik Indonesia.” n.d.
- “Ajibola O, Mshelia MB, Gulumbe BH, Eze AA. Typhoid Fever Diagnosis in Endemic Countries: A Clog in the Wheel of Progress? *Medicina (Kaunas)*. 2018 Apr 25;54(2):23. Doi: 10.3390/Medicina54020023. PMID: 30344254; PMCID: PMC6037256.” n.d.
- Arif, Mansyur, Patricia Tauran, Herman Kosasih, Ninny Meutia Pelupessy, Nurhayana Sennang, Risna Halim Mubin, Pratiwi Sudarmono, Emiliana Tjitra, Dewi Murniati, and Anggraini Alam. “Chikungunya in Indonesia: Epidemiology and Diagnostic Challenges.” *PLoS Neglected Tropical Diseases* 14, no. 6 (2020): e0008355.
- “Bhandari J, Thada PK, DeVos E. Typhoid Fever. 2022 Aug 10. In: StatPearls. Treasure

²³ “Sartori DJ, Sun K, Hopkins MA, Sloane MF. Typhoid Fever and Acute Appendicitis: A Rare Association Not yet Fully Formed. *Case Reports in Gastroenterology*. 2017; 11(2):446-51.”

²⁴ “Mehrabani S. Acute Appendicitis Associated With Typhoid Fever: A Case Report and Review of Literature. *Journal of Pediatrics Review*. 2020; 8(4):255-260.”

- Island (FL): StatPearls Publishing; 2023 Jan-. PMID: 32491445.,” n.d.
- “Dinas Kesehatan Kota Semarang. 2018. Profil Kesehatan Kota Semarang Tahun 2018. Semarang.,” n.d.
- “Garcia EM, Camacho MA, Karolyi DR, et Al.; Expert Panel on Gastrointestinal Imaging. ACR Appropriateness Criteria: Right Lower Quadrant Pain—Suspected Appendicitis. *J Am Coll Radiol* 2018; 15(Suppl 11):S373–S387,” n.d.
- “Habte L, Tadesse E, Ferede G, Amsalu A. Typhoid Fever: Clinical Presentation and Associated Factors in Febrile Patients Visiting Shashemene Referral Hospital, Southern Ethiopia. *BMC Res Notes*. 2018 Aug 22;11(1):605.,” n.d.
- “Institute for Health Metrics and Evaluation. Typhoid Fever—Level 4 Cause. Seattle, WA: Institute for Health Metrics and Evaluation, Global Burden of Disease Collaborative Network; 2020.,” n.d.
- “Jones MW, Lopez RA, Deppen JG. Appendicitis. [Updated 2022 Oct 24]. In: StatPearls. Treasure Island (FL): StatPearls Publishing; 2023 Jan-.,” n.d.
- “Kuehn R, Stoesser N, Eyre D, Darton TC, Basnyat B, Parry CM. Treatment of Enteric Fever (Typhoid and Paratyphoid Fever) with Cephalosporins. *Cochrane Database Syst Rev*. 2022 Nov 24;11(11):CD010452.,” n.d.
- “Lamps LW. Infectious Causes of Appendicitis. *Infectious Disease Clinics of North America*. 2010; 24(4):995-101.,” n.d.
- “Mehrabani S. Acute Appendicitis Associated With Typhoid Fever: A Case Report and Review of Literature. *Journal of Pediatrics Review*. 2020; 8(4):255-260.,” n.d.
- Merati, Tuti P, Muhammad Karyana, Emiliana Tjitra, Herman Kosasih, Abu T Aman, Bacht Alisjahbana, Dewi Lokida, Dona Arlinda, Frank Maldarelli, and Aaron Neal. “Prevalence of HIV Infection and Resistance Mutations in Patients Hospitalized for Febrile Illness in Indonesia.” *The American Journal of Tropical Medicine and Hygiene* 105, no. 4 (2021): 960.
- “Ochoa TJ, Santisteban-Ponce J. Salmonella. In: Cherry JD, Demmler-Harrison GJ, Kaplan SL, Steinbach WJ, Ho- Tez PJ, Editors. *Feigin and Cherrys Textbook of Pediatric Infectious Diseases*. London: Elsevier; 2019. p. 1066-81.,” n.d.
- “Sartelli M, Chichom-Mefire A, Labricciosa FM, et Al. The Management of Intra-Abdominal Infections from a Global Perspective: 2017 WSES Guidelines for Management of Intra-Abdominal Infections. *World J Emerg Surg*. 2017;12:29.,” n.d.
- “Sartori DJ, Sun K, Hopkins MA, Sloane MF. Typhoid Fever and Acute Appendicitis: A Rare Association Not yet Fully Formed. *Case Reports in Gastroenterology*. 2017; 11(2):446-51.,” n.d.
- Soedarmono, Pratiwi, Aly Diana, Patricia Tauran, Dewi Lokida, Abu Tholib Aman, Bacht Alisjahbana, Dona Arlinda, Emiliana Tjitra, Herman Kosasih, and Ketut Tuti Parwati Merati. “The Characteristics of Bacteremia among Patients with Acute Febrile Illness Requiring Hospitalization in Indonesia.” *Plos One* 17, no. 9 (2022): e0273414.
- “Toapanta FR, Bernal PJ, Fresnay S, Darton TC, Jones C, Waddington CS, et Al. Oral Wild-Type Salmonella Ty- Phi Challenge Induces Activation of Circulating Mono- Cytes and Dendritic Cells in Individuals Who Develop Ty- Phoid Disease. *PLoS Neglected Tropica*,” n.d.
- “Wong SY, Lee SKL, Er C, Kuthiah N. Appendicitis in Non- Typhoidal Salmonella Bacteraemia. *Oxford Medical Case Reports*. 2018; 2018(11):Omy082.,” n.d.
- Xena, Alfanny Juliannindy, and Andika Alivameita. “The Relationship of Differential Counting with the Erythrocyte Sedimentation Rate in Patients with Typhoid Fever.” *Indonesian Journal of Innovation Studies* 12 (2020): 10–21070.
- “Zheng BH, Hao WM, Lin HC, Shang GG, Liu H, Ni XJ. Samonella Typhi Infection-Related Appendicitis: A Case Report. *World J Clin Cases*. 2021 Oct 16;9(29):8782-8788.,” n.d.

UNDER PEER REVIEW