

Case study

Bard's syndrome : rare presentation of pulmonary miliary metastases of gastric carcinoma : About a case report and literature review

Abstract :

The Bard's syndrome is a rare disease related to miliary dissemination of gastric cancer to the lungs. The symptoms of primary neoplasm are subclinical despite the advanced proliferative process, and the metastatic lesions cause many respiratory symptoms suggesting primary pulmonary pathology, which explain the difficulties in diagnosis between numerous diseases. We report the case of a 39-year-old man presented for a chest pain, progressive worsening dyspnea appeared one month ago, dry cough, apyrexia, fatigue and weight loss. The chest CT scan showed a disseminated micronodular lesions, a thickened interlobular septa and mediastinal lymphadenopathy. Flexible bronchoscopy showed a diffuse inflammation on the entire bronchial tree. Staged bronchial biopsies revealed the presence of metastatic carcinoma, probably stomach in origin. The cytologic examination from bronchial aspirate reveal the presence of neoplastic cells. After re-interviewing the patient, he reported the history of intermittent epigastralgia, so we completed by an oesophageal-gastro-duodenal fibroscopy that confirmed the gastric adenocarcinoma and the diagnosis of bard's syndrome was made.

Key words:

Bard's syndrome, pulmonary miliary metastases, gastric carcinoma

Introduction

The Bard's syndrome is a rare disease, few cases are reported in the literature. It is related to miliary dissemination of gastric cancer to the lungs which

revealed by respiratory symptoms and explain the difficulties in diagnosis between numerous pulmonary diseases. We report the observation of a patient with adenocarcinoma gastric revealed by miliary pulmonary metastases.

Case présentations :

A 39-year-old man, chronic smoker with 2 pack-years, without comorbidities, had never treated for pulmonary tuberculosis and with no known recent tuberculosis contagion, his family history was negative. Presented for a chest pain, dry cough and progressive worsening dyspnea appeared one month ago, apyrexia, fatigue and weight loss.

The physical examination found a skin pallor, the epigastrium was painful on palpation, and no abnormalities were found in the rest of clinical examination.

Chest X ray showed a reticulomicronodular interstitial pattern predominantly in the bases (Figure1). Chest computed tomography scan revealed disseminated micronodular lesions, a thickened interlobular septa and mediastinal lymphadenopathies (Figure 2).

The blood count found microcytic hypochromic anemia, and no abnormalities in other laboratory tests.

Flexible bronchoscopy showed a bilateral inflamed bronchial tree. Staged bronchial biopsies revealed the presence of metastatic carcinoma, probably stomach in origin. The cytologic examination from bronchial aspirate reveal the presence of neoplastic cells. The search for mycobacterium tuberculosis by Genexpert MTB/RIF in fluid aspiration was negative.

After re-interviewing the patient, he reported the history of intermittent epigastralgia for one year medically treated (*Helicobacter pylori* serology was negative). We completed by an oesophageal-gastro-duodenal fibroscopy that showed a non-stenosing ulcerative cardiac process suspected of malignancy (figure 3), and the examination of the specimens led to the diagnosis of a differentiated infiltrating adenocarcinoma with independent cells.

We completed by an abdominal-pelvic CT scan, showing a metastatic liver mass (figure 4). After a multidisciplinary decision, the patient was transferred to the oncology centre for palliative chemotherapy. The evolution was marked by his death 10 days after the diagnosis.

Discussion :

Pulmonary lymphangitic carcinomatosis refers to the metastatic malignant tumor infiltration of the lung lymphatic vessels secondary to a primary site [1]. It occurs in about 6-8% of patients with lung metastasis and may rarely develop in the course of gastric cancer [2].

The exact prevalence is not known because its delayed diagnostic consideration often lead to autopsy confirmation. In a previous retrospective study in 43 patients with pulmonary lymphangitic carcinomatosis six gastric carcinoma were found [3].

Patients with primary gastric cancer and lymphangitic carcinomatosis usually present with progressive dyspnea lasting for two to four months before definite diagnosis [4], dry cough and loss of weight are usually found. Often these patients experience no gastric complaints at all. In a series of six young patients (aged from 21–29 years) only one had gastrointestinal symptoms (nausea and epigastric burning) [5].

Chest X ray may be normal in 30% to 50% of patients [6], and have often nonspecific appearances, it shows septal lines (Kerley A and B lines), increased bronchovascular markings, linear, reticulonodular and micronodular infiltrates [4]. HRCT is the imaging technique of choice, it reveals thickening of interlobular septa, fissures and bronchovascular bundles, nodularity in pleura and ground glass opacity. They may be seen as limited or diffuse, unilateral or bilateral, symmetric or asymmetric infiltrates. Pleural effusion can also be observed [7].

The final diagnosis can often only be made by biopsy using minimally invasive methods such as transbronchial biopsy or lung biopsy under videothoracoscopic control. In the study of Dennstedt et al. the final diagnosis

was only made at autopsy in four of six patients with a primary gastric tumour and lymphangitic carcinomatosis [5].

The differential diagnosis of diffuse interstitial lung changes should include sarcoidosis, viral pneumonias, pulmonary oedema, radiation pneumonitis, drug-induced lung disease, miliary tuberculosis and lymphocytic interstitial pneumonia. [8,9]

Currently, there are no proven effective treatment strategies on recent studies for pulmonary lymphangitic carcinomatosis, it mainly based on chemotherapy [10]. The general prognosis of patients with lymphangitis carcinomatosis is poor with an average survival of only three months in historical series [2].

The Bard's syndrome, a rare disease, is a primary stomach carcinoma with miliary dissemination to the lungs. The symptoms of primary neoplasm are subclinical despite the advanced proliferative process, and the metastatic lesions cause many respiratory symptoms suggesting primary pulmonary pathology. In fact few cases are reported in literature and that is due to misdiagnosis and difficulties to separate of between numerous pulmonary diseases.

Conclusion :

The pulmonary lymphangitic carcinomatosis should be suspected in patients with advanced gastric cancer presenting with respiratory symptoms. The Bard's syndrome, a rare disease, should be always taken into account particularly due to prevalence of gastric cancer.

References

1. Doyle L. Gabriel Andral (1797-1876) and the first reports of lymphangitis carcinomatosa. *J R Soc Med.* 1989;82(8):491–493.
2. Bruce DM, Heys SD, Eremin O. Lymphangitis carcinomatosa: a literature review. *J R Coll Surg Edinb.* 1996;41(1):7–13.
3. Zhang K, Huang Y. [Clinical features and diagnosis of pulmonary lymphangitic carcinomatosis]. *Ai Zheng.* 2006;25(9):1127–1130.

4. Desigan G, Wang M, Wofford B, Dunn GD, Vaughan S. Occult gastric cancer manifested by progressive shortness of breath in a young adult. *South Med J*. 1986;79(9):1173–1176.
5. Dennstedt FE, Greenberg SD, Kim HS, Weilbaecher DG, Bloom K. Pulmonary lymphangitic carcinomatosis from occult stomach carcinoma in young adults: an unusual cause of dyspnea. *Chest*. 1983;84(6):787–788.
6. Thomas A, Lenox R. Pulmonary lymphangitic carcinomatosis as a primary manifestation of colon cancer in a young adult. *CMAJ*. 2008;179(4):338–340.
7. Perez-Lasala G, Cannon DT, Mansel JK, McGehee RP, Allen KG. Case report: lymphangitic carcinomatosis from cervical carcinoma--an unusual presentation of diffuse interstitial lung disease. *Am J Med Sci*. 1992;303(3):174–176.
8. Witczak A, Prystupa A, Zamecka M, Biłan A, Krupski W, Mosiewicz J. Pulmonary lymphangitic carcinomatosis in the course of gastric cancer – Case report. *Journal of Pre-Clinical and Clinical Research*. 2015;8(2):116–119.
9. Elicker B, Pereira CA de C, Webb R, Leslie KO. High-resolution computed tomography patterns of diffuse interstitial lung disease with clinical and pathological correlation. *J Bras Pneumol*. 2008;34(9):715–744.
10. Bhattacharya PK, Jamil M, Khonglah Y, Roy A, Subrahmanya MV. A Rare Case of Pulmonary Lymphangitic Carcinomatosis in a Young Adult with Carcinoma Stomach. *J Clin Diagn Res*. 2017;11(8):OD07–OD09.

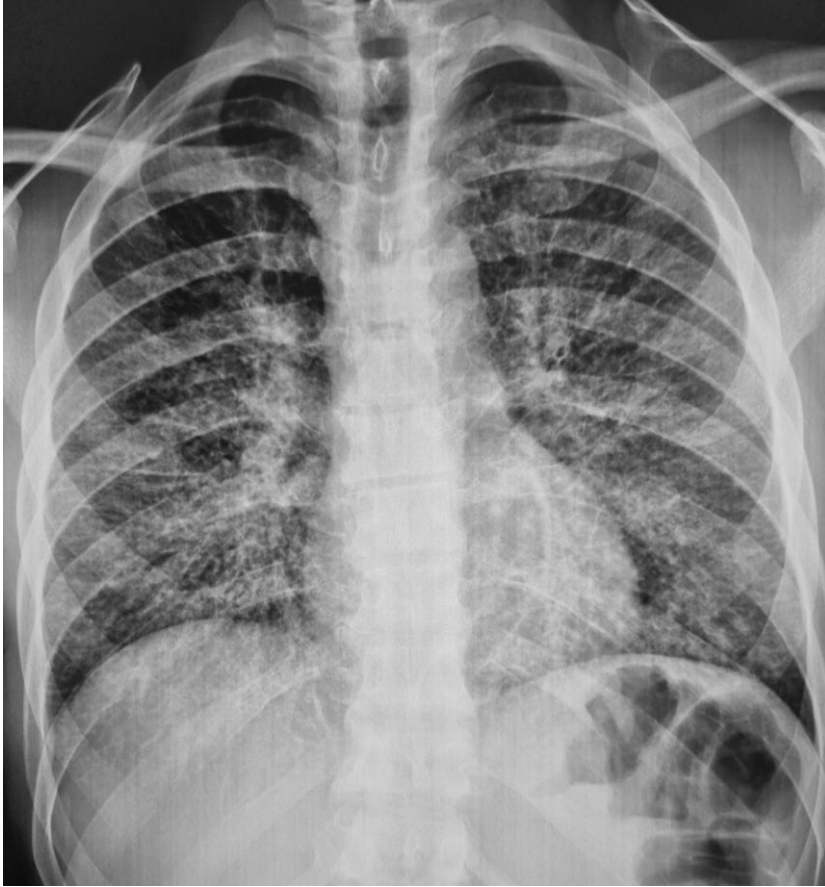
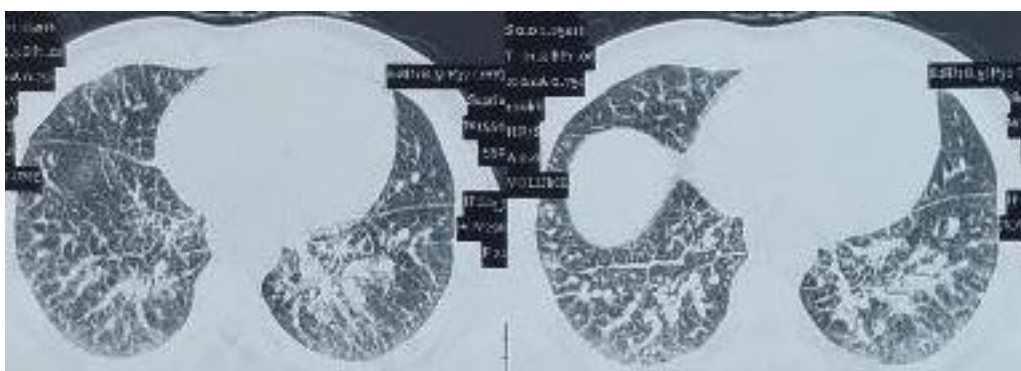
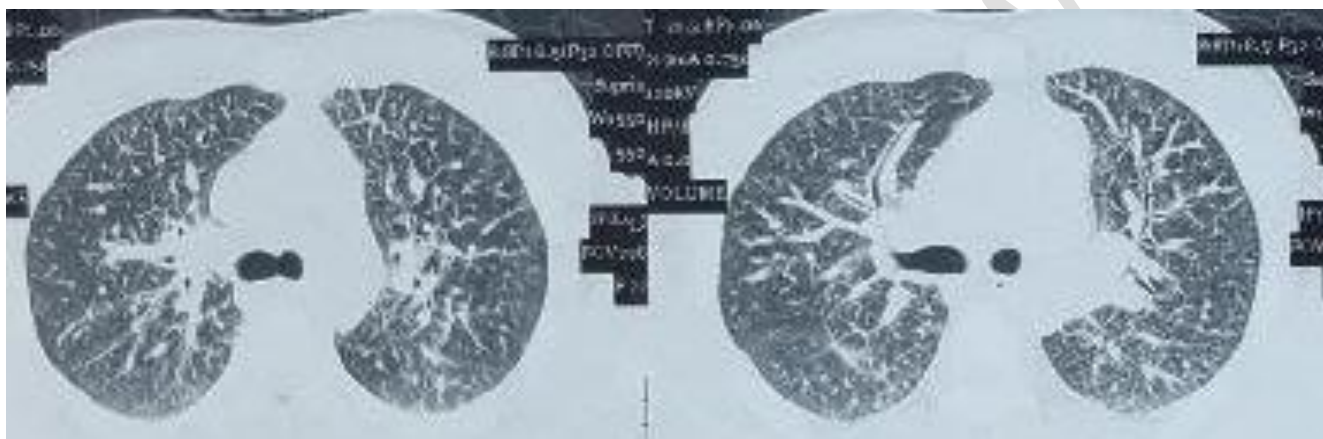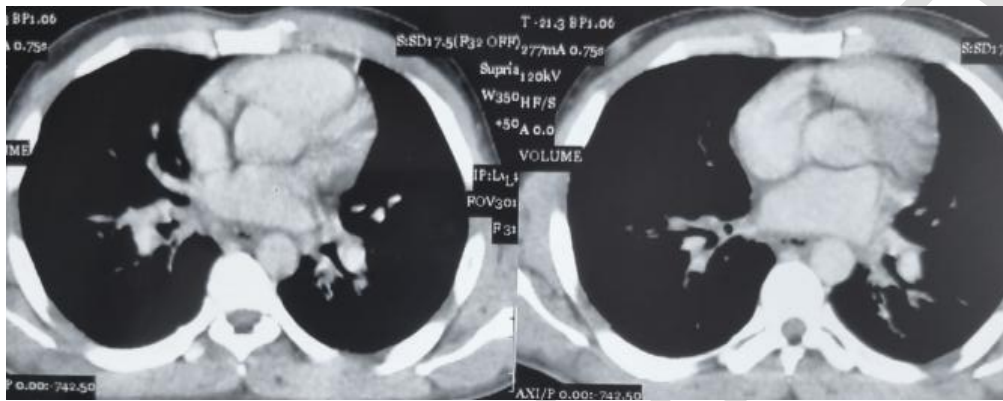


Figure 1 : Chest X-ray showed diffuse reticulomicronodular pattern.

UNL





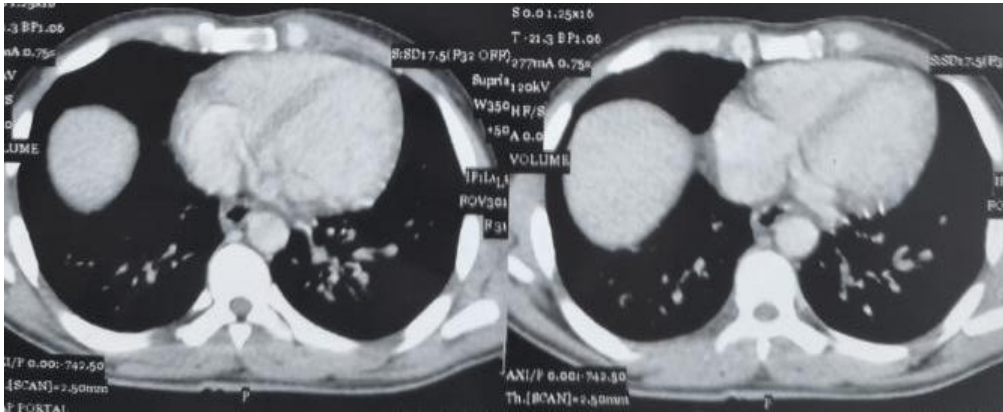


Figure 2 : Chest computed tomography scan showed disseminated micronodular lesions, a thickened interlobular septa and mediastinal lymphadenopathies.

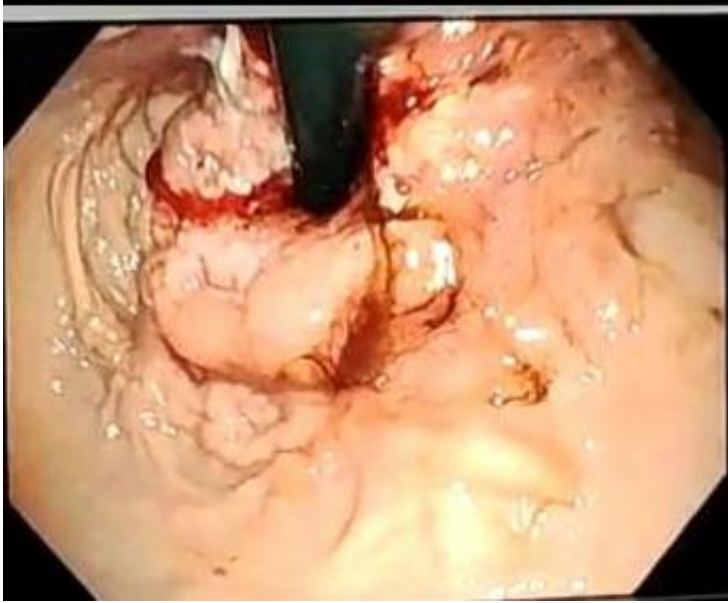

Figure 3 : oesophageal-gastro-duodenal fibroscopy showed a non-stenosing ulcerative cardiac process suspected of malignancy.

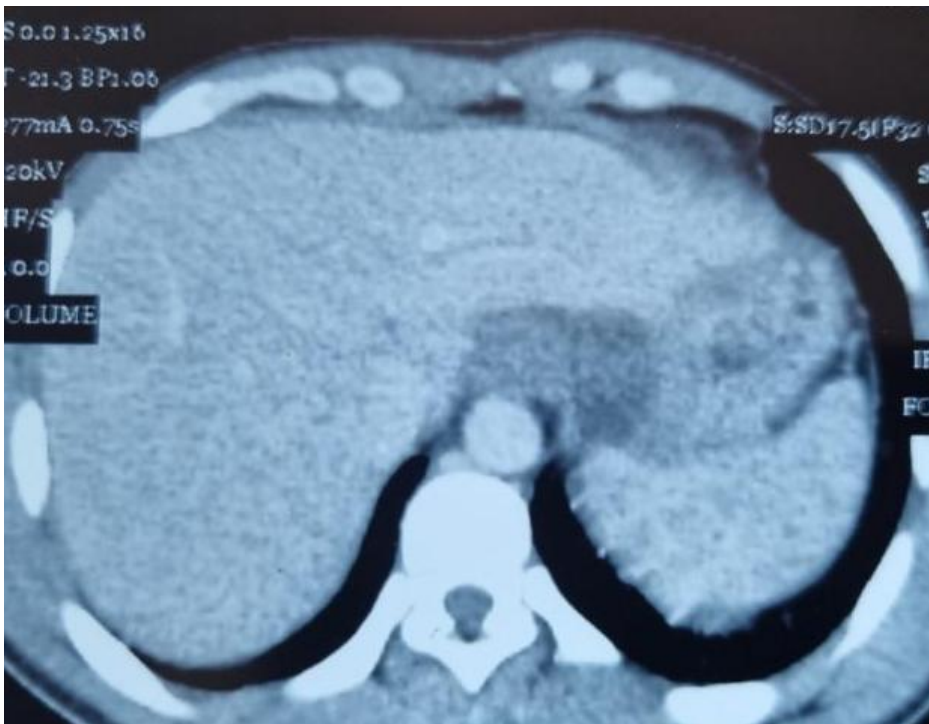


Figure 4 : abdominal-pelvic CT scan showed a metastatic liver mass.