

## Original Research Article

# Stroke in a retrospective cohort of patients with eclampsia

### ABSTRACT

**Aims:** To identify the incidence, vascular origin, type and outcome of stroke in a retrospective cohort of patients with eclampsia.

**Study design:** Cross-sectional, retrospective and analytical study.

**Place and Duration of Study:** Intensive Care Unit (ICU), High Specialty Medical Unit of Gynecology and Obstetrics Hospital No. 3, National Medical Center "La Raza", Mexican Institute of Social Security, Mexico City between January 1, 2019 to December 31, 2022.

**Methodology:** The research was carried out in a retrospective cohort of 43 patients with eclampsia admitted to the ICU. The clinical record, Cranial Tomography (CT), and Magnetic Resonance Imaging (MRI) findings were consulted to determine the incidence, vascular origin, type and outcome of the stroke. ICU stay and patient mortality were reported. Data were analyzed with descriptive and inferential statistics (Kolmogorov–Smirnov test, chi-square, paired Student's t-test, Mann-Whitney-Wilcoxon U test). The value  $P < 0.05$  was significant.

**Results:** Incidence of stroke 27.90% ( $n=12/43$ ). Findings by CT 41.66% ( $n=5$ ) and CT with MRI 58.34% ( $n=7$ ). Vascular origin: arterial 58.34% ( $n=7$ ), arterial-venous 33.33% ( $n=4$ ) and venous 8.33% ( $n=1$ ). Type of stroke: arterial hemorrhagic 50% ( $n=6$ ), arterial ischemic 58.33% ( $n=7$ ), subarachnoid hemorrhage 25% ( $n=3$ ) and venous thrombosis 41.66% ( $n=5$ ). Presentation: solitary stroke 58.33% and combinations 41.66% (proportion 1.4). Management in the same hospital 58.33% ( $n=7$ ) and transfers to highly specialized units for serious complications 41.67% ( $n=5$ ). ICU stay  $3.95 \pm 1.82$  days, it was similar in patients with and without stroke ( $p=0.226$ ). Maternal mortality 0%.

**Conclusion:** The incidence of stroke was very high with extremely severe lesions, but without effect on ICU stay and mortality. Team management was necessary in a high percentage of cases.

**Keywords:** Stroke; Neurological complications; Subarachnoid hemorrhage; Eclampsia; Obstetric intensive care; High risk pregnancy.

## 1. INTRODUCTION

Stroke during pregnancy is a relatively rare event.<sup>1,2</sup> In patients with preeclampsia its incidence increases when complications such as HELLP syndrome, eclampsia or

**Comment [oa1]:** Consider rephrasing this to become "among 43 patients with eclampsia admitted in the ICU"

coagulation disorders appear.<sup>3,4</sup> Stroke can occur in the arterial or venous territory, but it can occur simultaneously in both territories in the same patient. The arterial origin of the stroke is the most frequent in preeclampsia. Endothelial damage, structural changes in the vascular wall, platelet hyperactivity, a hypercoagulable state, and congenital thrombophilia are predisposing factors for arterial ischemia due to thrombosis. Thrombocytopenia, disseminated intravascular coagulation, aneurysms or vascular malformations, hypertensive crises in general, and systolic hypertension favor hemorrhage in the brain parenchyma and ventricles.<sup>1,5,6</sup> Ischemia and arterial hemorrhage predominate in the territory of the basal ganglia, stem, and cerebral hemispheres, which are considered areas of selective vascular vulnerability. These are the most lethal complications in patients with preeclampsia, mainly when they occur in the parenchymal tissue.<sup>1,2,7</sup>

In patients with preeclampsia, the frequency of subarachnoid hemorrhage is also increased, it can occur individually or combined simultaneously with diffuse edema, ischemia, or hemorrhage from a parenchymal artery.<sup>8</sup> Stroke of venous origin has also been described in preeclampsia. Chronic use of contraceptives or estrogen-containing hormone replacement therapy, thrombophilia, hyperhomocysteinemia, extreme dehydration, hyperemesis gravidarum, and severe and prolonged reduction in cerebral blood flow clearly predispose to thrombosis of the veins and venous sinuses.<sup>1,5,9</sup>

Early detection of a stroke is a priority. Patients with preeclampsia and neurological examination abnormalities are candidates for Cranial Tomography (CT) and Magnetic Resonance Imaging (MRI). Cerebral angiography and its modalities are reserved only for inconclusive cases or candidates for surgery.<sup>5,7</sup> Local or diffuse parenchymal edema and Posterior Reversible Encephalopathy Syndrome (PRES) are the most common forms of brain injury in preeclampsia, but stroke has drawn more attention throughout the ages. once it has greater aggressiveness, percentage of mortality and long-term sequelae. The correlation of clinical data with imaging studies is the most valuable tool to establish the neurological diagnosis and the bases for conservative management, indications for surgery and the prognosis of the patients.<sup>10-14</sup> The aim of the study was To identify the incidence, vascular origin, type and outcome of stroke in a retrospective cohort of patients with eclampsia.

**Comment [oa2]:** Consider rephrasing this to "the study aimed to"

## 2. MATERIAL AND METHODS

A cross-sectional, retrospective and analytical study was carried out in a cohort of 43 patients with eclampsia from the Intensive Care Unit (ICU) of a High Specialty Medical Unit of Mexico City (Gynecology and Obstetrics Hospital No. 3, National Medical Center "La Raza", Mexican Institute of Social Security, Mexico City) that were attended between January 1, 2019 to December 31, 2022. Clinical and electronic records were consulted to know their general data and imaging studies (CT, MRI) to identify cases that were complicated by a stroke, its vascular origin (arterial, venous, arterial and venous), type (hemorrhagic, ischemic, thrombotic), its anatomical location and mortality. The cases were selected for convenience. It was ruled out that the patients had a history of stroke, head trauma, head surgery, congenital disorders, infectious or degenerative neurological diseases, epilepsy, and preeclampsia-eclampsia or HELLP syndrome in previous pregnancies. The information necessary for the study was available in all the patients, so none was eliminated. The original interpretation of the CT, MRI, or both images was compared with the opinion of another specialist in Radiology and Imaging from the same hospital who was unaware of the diagnosis.

**Comment [oa3]:** Consider rephrasing this to become " the following were excluded from the study.....  
Or patients with a history of any of the following conditions..... were excluded from the study

### 2.1 Data analysis

Descriptive statistics (mean, median, standard deviation, range) and inferential statistics (Kolmogorov–Smirnov test, chi-square, paired Student's t test, Mann-Whitney-Wilcoxon U test) with the statistical program SPSS<sup>®</sup> version 25 (IBM Corp. Armonk, New York, United States) were used. The *P* value < 0.05 was significant.

### 3. RESULTS

The 43 patients with eclampsia represented 2.41% of the total cases admitted to the ICU during the study period (43/1,783 cases). The general data are shown in **Table 1**. Morbidities were found in 23.25% (10 cases; chronic arterial hypertension 2 cases, antiphospholipid syndrome 2 cases, inactive systemic lupus erythematosus 2 cases, gestational diabetes 1 case, controlled primary hypothyroidism 1 case, controlled primary hyperthyroidism 1 case, chronic kidney disease K-DIGO class 3 1 case). When they were admitted to the ICU, 60.46% (26 cases) were in the postpartum period and 39.54% (17 cases) were pregnant, the termination of pregnancy took place during their stay in the ICU.

**Table 1**

**Comment [oa4]:** Consider replacing this phrase with "puerperium"

**Table 1. General data of 43 patients with eclampsia**

Parameter	Result
Maternal age years limits	27.41 ± 7.88 15 to 42
Body mass index limits	30.45 ± 5.32 20.54 to 42.4

Weeks of pregnancy	33 ± 4.56
limits	22 to 39
Obstetric condition in ICU	
With pregnancy, singleton fetus	39.54%, n=17
Postpartum period	60.46%, n=26
Parity	
One	55.81%, n=24
Two	20.93%, n=9
Three	11.62%, n=5
Four	9.30%, n=4
Five	2.32%, n=1
Onset of preeclampsia	
Early < 34 weeks	34.88% n=15
Late ≥ 34 weeks	65.12% n=28
Admission-delivery time hours n=17	15.76 ± 1.73
limits	1 to 72
Type of delivery	
Caesarean operation	88.37%, n=38
Vaginal	11.63%, n=5
Bleeding ml	643.54 ± 570.04
limits	1,100 to 3,500
Fetal weight g	1908.85 ± 774.18
limits	565 to 3475
Apgar score birth median	
minute 1	6 limits 2 to 8
minute 5	8 limits 4 to 9
Prematurity < 37 weeks	69.76%, n=30
Term newborn ≥ 37 weeks	30.23%, n=13
Maternal mortality	0%
Fetal mortality	2.32%, n=1

ICU = Intensive Care Unit

Comment [oa5]: Cesarean

Seizures due to eclampsia occurred in the antepartum period 41.86% (18 cases), postpartum 51.16% (22 cases) and in both periods 6.97% (3 cases). The most frequent premonitory symptoms of eclampsia were: headache 55.81% (24 cases), epigastric pain 23.25% (10 cases), drowsiness 18.60% (8 cases) and visual disturbances 9.3% (4 cases). The most common exploratory signs were: edema of the pelvic limbs 81.9% (35 cases), hyperreflexia 79.06% (34 cases) and positive Babinsky sign 13.9% (6 cases). Complications that accompanied eclampsia were: Mississippi class II HELLP syndrome 32.55% (14 cases), acute kidney injury (AKI) without dialysis 27.90% (12 cases), anemic syndrome 6.97% (3 cases) and acute pulmonary edema without ventilatory support 2.32% (1 case). The hemodynamic and clinical laboratory data of all the patients are shown in **Table 2**.

**Table 2. Hemodynamic and clinical laboratory data of 43 patients with eclampsia**

Parameters	Measurements in the ICU		P-value
	Admission	Discharge	

Comment [oa6]: measurements

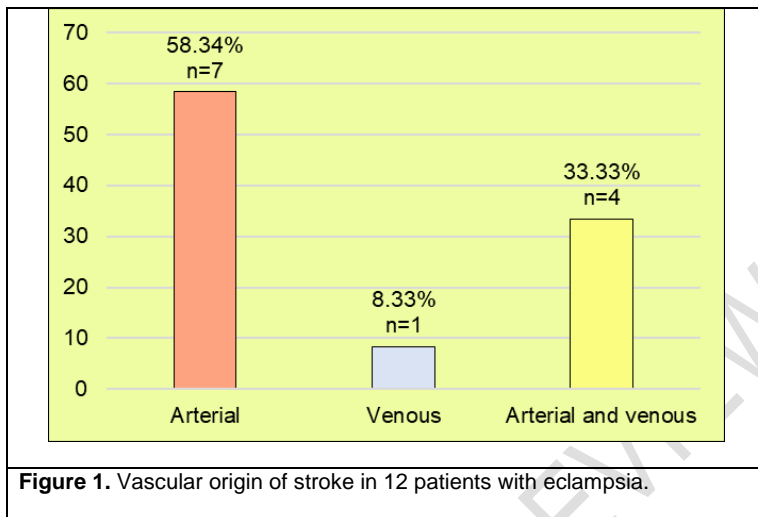
Blood pressure mmHg			
systolic	143.41 ± 23.64	128.23 ± 11.53	.002
diastolic	89.32 ± 14.93	79.06 ± 9.26	.002
Central venous pressure			
cm water	7.88 ± 4.18	10.87 ± 4.97	.312
Uresis ml/K/hour	1.28 ± 1.23	2.15 ± 1.82	.017
Plasma colloid osmotic pressure			
mmHg	15.36 ± 3.05	17.25 ± 3.46	.621
Hemoglobin g/dL	11.65 ± 2.15	10.77 ± 1.42	.030
Platelets / $\mu$ L	192,590 ± 153,600	198,900 ± 99,090	.821
Uric acid mg/dL	5.99 ± 2.24	4.7 ± 1.59	.009
Glucose mg/dL	116.58 ± 35.07	86.46 ± 19.78	.066
Creatinine mg/dL	0.88 ± 0.52	0.81 ± 0.61	.620
Aspartate aminotransferase U/L	102.6 ± 138.18	31.6 ± 26.63	.002
Alanine aminotransferase U/L	99.09 ± 27.93	43.22 ± 39.44	.004
Lactic dehydrogenase U/L	678.65 ± 443.96	452.87 ± 141.65	.003
Arterial pH	7.42 ± 0.06	7.41 ± 0.06	.880
Prothrombin time seconds	12.1 ± 1.2	11.52 ± 1.5	.875

ICU = Intensive Care Unit

When the data on admission were compared with that on discharge from the ICU, significant differences were found in systolic blood pressure ( $P = .002$ ), blood pressure diastolic ( $P = .002$ ), uresis ( $P = .017$ ), hemoglobin ( $P = .030$ ), uric acid ( $P = .009$ ), aspartate aminotransferase enzyme ( $P = .002$ ), alanine aminotransferase enzyme ( $P = .004$ ), and lactic dehydrogenase enzyme ( $P = .003$ ).

When brain imaging studies were reviewed, the following was found: no study 9.30% (4 cases), normal structures 11.63% (5 cases), diffuse parenchymal edema 27.91% (12 cases), PRES 23.26% (10 cases) and stroke 27.90% (12 cases). The most frequent vascular origin of the stroke was arterial 58.34% (7/12 cases: hemorrhagic 2 cases, ischemic 4 cases and hemorrhagic-ischemic 1 case) followed by arterial-venous origin 33.33% (4/12 cases: hemorrhagic arterial with venous thrombosis 2 cases, ischemic arterial with venous thrombosis 1 case, hemorrhagic and ischemic arterial with thrombosis venous 1 case) and venous origin due to thrombosis 8.33% (1/12 cases). **Figure 1** In 41.66% (5/12 cases) the findings were demonstrated by CT as an individual study and in 58.34% (7/12 cases) CT with MRI was performed.

**Comment [oa7]:** Followings were



The presentation of stroke alone prevailed over the combinations (58.33% vs 41.66%), the proportion was 1.4. Details of the vascular origin, type, and imaging study findings are shown in **Table 3**.

**Table 3. Origin, type and findings of stroke in 12 patients with eclampsia**

Case	Origin and type	Findings	Imaging studies
Arterial origin			
1	Hemorrhagic	Fisher class IV subarachnoid hemorrhage	CT
2	Ischemic	Left frontal lobe infarction	CT
7	Ischemic	Left parietal lobe infarction	CT
9	Hemorrhagic	Frontoparietal intraparenchymal hemorrhage	CT
10	Ischemic	Hypodensity in right basal ganglia Perilesional edema Right temporal lobe infarction	CT and MRI
11	Ischemic	Left frontoparietal infarction	CT and MRI
12	Ischemic and hemorrhagic	Multiple cortical hypodense regions Fisher class IV left parietal subarachnoid hemorrhage Intraparenchymal hemorrhage	CT and MRI
Arterial-venous origin			
3	Hemorrhagic arterial and thrombotic venous	Left frontal lobe hemorrhage Superior longitudinal venous sinus thrombosis	CT
4	Ischemic arterial and thrombotic venous	Biparietal hypodense images Superior longitudinal venous sinus thrombosis	CT and MRI
5	Ischemic-hemorrhagic arterial and thrombotic venous	Left frontal lobe infarction Right frontal parenchymal hemorrhage Superior longitudinal sinus thrombosis	CT and MRI
6	Hemorrhagic arterial and thrombotic venous	Fisher class IV subarachnoid hemorrhage Frontal parenchymal hemorrhage Superior longitudinal venous sinus thrombosis	CT and MRI
Venous origin			
8	Thrombotic	Superior longitudinal venous sinus thrombosis	CT and MRI

CT = Cranial Tomography  
MRI = Magnetic Resonance Image

The **Figure 2** shows the images of the most representative cases of stroke.

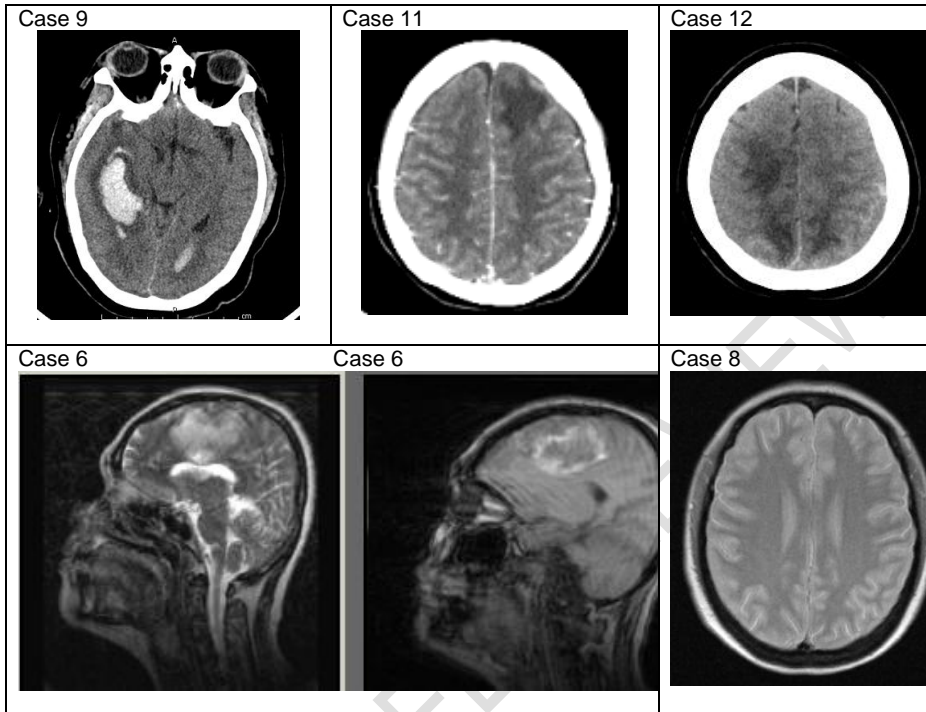


Figure 2. CT and MRI images representative of stroke.

Case 9: Hemorrhagic stroke of arterial origin.

Case 11: Ischemic stroke of arterial origin.

Case 12: Hemorrhagic-ischemic stroke of arterial origin.

Case 6: Stroke of arterial-venous origin: parenchymal hemorrhagic of arterial origin with Fisher class IV subarachnoid hemorrhage and thrombotic stroke of venous origin.

Case 8: Thrombotic stroke of venous origin.

With the intention of identifying any difference of interest, the hemodynamic and clinical laboratory data from admission to the ICU of the 12 patients with stroke were compared with the 21 patients who did not present it. Plasma colloid osmotic pressure was the only parameter that showed a significant difference ( $P = .042$ ). **Table 4**

**Comment [oa8]:** Consider rephrasing this to become "to identify"

**Table 4. Comparison of hemodynamic and clinical laboratory data on admission to the ICU in patients with eclampsia with and without stroke.**

Parameter	Patients with stroke (12 cases)	Patients without stroke (31 cases)	P-value
Blood pressure mmHg			
systolic	141.83 ± 15.35	144.03 ± 26.35	.788
diastolic	88.91 ± 10.05	89.48 ± 16.59	.912
Central venous pressure cm water	6.73 ± 4.05	8.72 ± 4.66	.576
Uresis ml/Kg/hour	1.16 ± 0.83	1.32 ± 1.37	.715
Plasma colloid osmotic pressure mmHg	13.20 ± 2.35	17.52 ± 3.25	.0425
Hemoglobin g/dL	11.12 ± 2.28	11.85 ± 2.10	.324
Platelets / $\mu$ L	154,900 ± 14,513	205,967 ± 15,390	.343
Uric acid mg/dL	5.04 ± 1.64	6.31 ± 2.35	.145
Glucose mg/dL	122 ± 30.40	114 ± 36.97	.534
Creatinine mg/dL	0.79 ± 0.2	0.91 ± 0.59	.514
Aspartate aminotransferase U/L	95.66 ± 79.89	105.43 ± 156.67	.839
Alanine aminotransferase U/L	123.25 ± 129.32	89.43 ± 109.14	.394
Lactic dehydrogenase U/L	822 ± 584.72	626.06 ± 378.55	.214
Arterial pH	7.43 ± 0.06	7.41 ± 0.06	.250
Prothrombin time seconds	12 ± 0.8	11.8 ± 1.4	.786

ICU = Intensive Care Unit

The stay in the ICU of the 43 patients was  $3.95 \pm 1.82$  days (limits 1 to 9), no difference was found in the stay of the patients with stroke versus patients without stroke ( $4.5 \pm 1.83$  days, limits 2 to 9 vs  $3.74 \pm 1.80$  days, limits 1 to 8;  $P = 0.226$ ). Regarding the outcome of patients with stroke, 58.33% (7/12 cases) continued to be managed in a general ward of the same hospital and 41.67% (5/12 cases) were transferred to a specialized hospital (Neurological Intensive Care Unit 4 cases, Hemodialysis Unit 1 case). There were no cases of maternal death in the ICU. Fetal death was 2.32%, (1 case).

#### 4. DISCUSSION

Redman<sup>15</sup> has proposed two stages for preeclampsia, stage 1 corresponds to the placental phase and stage 2 includes maternal disease. Evidence has documented that the endothelium is the first maternal organ affected by preeclampsia. Endothelial swelling and apoptosis, structural alterations of the capillary and arteriolar wall, vasoconstriction, perivascular edema, capillary leak, thrombosis, and hemorrhage of the smallest vessels are the characteristic findings in maternal tissues and organs.<sup>16,17</sup> These lesions correspond to a disease of small vessels, the transition from preeclampsia to a disease of the great arterial vessels seems to be given by elevated blood pressure and hypertensive complications while other pathophysiological mechanisms and complications of preeclampsia predispose to

thrombosis of the veins and venous sinuses. Thus, the maternal panorama is adverse in the entire circulatory system of the brain.<sup>8,9</sup>

In this research, a retrospective cohort of 43 patients with eclampsia treated in the ICU of a highly specialized medical unit in Mexico City was studied. Mean maternal age was in the third decade of life with pregnancy around  $33 \pm 4.56$  weeks and high percentages of known high maternal and fetal risk factors (primiparity, early onset of preeclampsia, cesarean section, prematurity, cardiovascular-renal-immunological-metabolic morbidities). A group of serious complications accompanied eclampsia: HELLP syndrome 32.55%, acute kidney injury (AKI) 27.90% and acute pulmonary edema 2.32%). **Table 1**

The hemodynamic and clinical laboratory data showed significant favorable changes once the 43 patients received intensive care and were discharged from the ICU. **Table 2** When the same data were compared from the cases with stroke versus patients without stroke, the only data that showed a significant difference was plasmatic colloid osmotic pressure with reduced values in the patients with stroke ( $P = .0425$ ). **Table 4** On the other hand, brain imaging studies showed diffuse cerebral edema as the most common finding 27.91%. The percentage was similar to that reported by Harandou et al.<sup>18</sup> in 2006. In the present investigation, PRES, a type of edema located in the occipital lobes, was found in 23.26%, this percentage was similar to the report by Vázquez et al.<sup>19</sup> published in 2022 and performed on patients from the same hospital.

The simultaneous presentation of cerebral edema and PRES with stroke in preeclampsia has been of interest to investigators. McDermott et al.<sup>20</sup> have reviewed the association of PRES with the pathophysiology of stroke in patients with preeclampsia, while Tshering et al.<sup>21</sup> reported in 2021 the postpartum development of subarachnoid hemorrhage and cerebral venous thrombosis in the PRES scenario in eclampsia. The two data (reduced plasma colloid osmotic pressure and diffuse or localized cerebral edema) are relevant because reduced plasma colloid osmotic pressure has been implicated as one of the pathophysiological mechanisms of cerebral edema, which may explain its high frequency in imaging studies, but they do not explain the development of a stroke.<sup>22</sup>

Stroke occurred in 27.90% (12/43 cases) and the most frequent vascular origin was arterial 58.34% followed by arterial-venous origin 33.33% and exclusively venous origin 8.33%. Figure 1 According to the type of stroke, imaging studies showed hemorrhagic arterial stroke in 50%, ischemic stroke in 58.33%, subarachnoid hemorrhage in 25%, and venous thrombosis in 41.66%. **Table 3** The presentation of stroke alone prevailed over the combinations (58.33% vs 41.66%), the proportion was 1.4. The stroke combinations in the same patient has also been reported by Harandou,<sup>18</sup> Jaigobin et al.<sup>23</sup> and Brouh et al.<sup>24</sup> The comparison of the hemodynamic and clinical laboratory data did not show any substantive difference to explain the clinical behavior of stroke. **Table 2 and 4**

In the present retrospective cohort, arterial stroke occurred in the frontal, parietal, and temporal ~~lobe~~, and no predominance was found in the middle cerebral artery territory. **Table 3, Figure 2** No cases with systolic hypertension were identified as a factor with stroke as reported by Martin et al.<sup>6</sup> nor were coagulation diseases documented that could be related to bleeding. **Table 1**

Jaigobin et al.<sup>23</sup> reported in the year 2000 the results of a retrospective analysis of patients from a Hospital in Toronto, Canada admitted between January 1, 1980 and June 30, 1997 with a diagnosis of stroke during pregnancy or within 6 weeks postpartum. Of the total of 50,700 admissions, the authors identified 34 patients with stroke (21 infarcts and 13 hemorrhages). Of the patients with infarcts, 13 were arterial and 8 venous. The etiological

Comment [oa9]: have

Comment [oa10]: lobes

diagnosis was made in 7 of 13 patients with arterial infarction (cardiac emboli, coagulopathies, and carotid artery dissection). Of the 13 patients with hemorrhage, 7 had subarachnoid hemorrhage and 6 cases developed intracerebral hemorrhage. The etiology was identified in 10 patients with hemorrhage: 3 were due to ruptured aneurysms, 5 were associated with arteriovenous malformations, and 2 cases had disseminated intravascular coagulation. All patients with arterial infarction survived, but 3 patients with hemorrhage died. In contrast to these data, no pre-existing vascular lesions or cardiac disease were documented in the present study.

In 2003 Beye et al.<sup>25</sup> published the clinical results of a cohort of 28 patients with eclampsia admitted to a hospital in tropical Africa between January 1997 and December 1999. They reported cerebral hemorrhage in 14.28% (4/28 cases). The authors found no cases with stroke of venous origin. In 2006 Harandou et al.<sup>18</sup> reported the CT and MRI findings of 19 patients with eclampsia who persisted with neurological signs for 24 hours or more. CT was normal in 3 cases, the predominant lesion was edema in 14 cases (parietal or occipital area 12 cases, paraventricular area 1 case, and diffuse edema 1 case). Diffusion-weighted MRI was performed in 4 cases and discovered cytotoxic cerebral edema in 1 suspected case. 3 cases of cerebral venous thrombosis and 2 cases of intracerebral hemorrhage were identified. The authors concluded that imaging studies can reveal multiple brain lesions in the same patient and recommended that diffusion-weighted MRI should be performed routinely in all patients with clinical signs of neurological disorders that persist after postpartum management.

In 2016 Brouh et al.<sup>24</sup> reported a study similar to the present investigation. It was a series of 54 patients with eclampsia from a University Hospital in Côte d'Ivoire, Africa. Complications that accompanied eclampsia were HELLP syndrome, AKI with and without dialysis, and acute pulmonary edema. All the patients were studied with CT, the authors found absence of lesions in 20 cases, ischemic stroke in 10 cases, isolated cerebral edema in 5 cases, cerebral edema with ischemia in 4 cases, parenchymal hemorrhage in 3 cases, subarachnoid hemorrhage in 1 case, and meningeal hemorrhage in 1 case. The location of the lesions varied: parietal, parietal-frontal, parieto-fronto-occipital, occipital, and in the territory of the middle cerebral artery.

Brouh et al.<sup>24</sup> and Beye et al.<sup>25</sup> did not identify venous lesions, in the present investigation the stroke of venous origin appeared in a significant percentage of cases 41.66%, thrombosis of the superior longitudinal sinus was the only site of venous lesion. Coutinho et al.,<sup>9</sup> carried out a systematic review of venous stroke in both women and men and concluded that its incidence is higher in women, the difference lies in the complications of pregnancy and puerperium. Similar to the data from this study, Couitinho et al.<sup>9</sup> found that thrombosis of the superior longitudinal venous sinus is the most frequently injured venous structure.

In accordance with the recommendations of Ohno et al.<sup>26</sup> and other researchers<sup>18,19,24,25</sup> all the patients in the current investigation were admitted to the ICU of a tertiary care center to overcome the acute stage of eclampsia and stroke with the support of other specialties. Thus, there were no cases of maternal death, possibly due to intensive care and the collaborative participation of the multidisciplinary medical team.

Because the incidence and severity of stroke were very high, it is recommended to perform CT, but rather MRI in all cases with eclampsia during pregnancy and postpartum, since removal of the placenta does not ensure the absence of complications. Soydinc et al.<sup>27</sup> have described that the first 5 hours postpartum are the period with the highest risk for maternal death from a venous stroke. Patients with eclampsia and stroke currently represent a

**Comment [oa11]:** This phrase is rather confusing  
Did the author mean 1. it is recommended not to perform CT but rather MRI  
Or 2. it is recommended to perform CT along side MRI  
It would be grate if the author could clarify

diagnostic and therapeutic challenge with a high degree of difficulty that has not been resolved.<sup>28</sup> Furthermore, contemporary research suggests an association between preeclampsia and stroke during pregnancy and postpartum, but also in later life.<sup>13,14,29</sup>

Finally, the main strength of the research is the identification and description of stroke in the field of eclampsia and its clinical follow-up in the acute stage. The study's weaknesses lie in its retrospective design, the small sample size, the limitation of data analysis during their stay in the ICU, and the fact that pharmacological management was not described.

## 5. CONCLUSION

The incidence of stroke was very high with extremely severe lesions in all cases, but with no effect on ICU stay and mortality. CT and MRI are recommended for all eclampsia patients for early diagnosis of brain lesions. Critical care and the participation of a multidisciplinary medical team are necessary in all cases to reduce morbidity, mortality, and potential short- and long-term neurological sequelae.

## CONSENT

As per international standard or university standard, patient(s) written consent has been collected and preserved by the author.

## ETHICAL APPROVAL

The study was previously approved by the local Health Research Committee no. 3504 and Ethics in Health Committee of the host hospital (Registration: R-2022-3504-47).

## REFERENCES

1. Cauldwell M, Rudd A, Nelson-Piercy C. Management of stroke and pregnancy. *Eur Stroke J.* 2018;3:227–36. DOI:10.1177/2396987318769547
2. Khalid A, Hadbavna A, Williams D, Byrne B. A review of stroke in pregnancy: incidence, investigations and management. *The Obstetrician & Gynaecologist.* 2020;22:21-33. DOI:10.1111/tog.12624
3. Curiel-Balsera E, Prieto-Palomino MA, Muñoz-Bono J, Ruiz de Elvira MJ, Galeas JL, G. Quesada García G. Analysis of maternal morbidity and mortality among patients admitted to obstetric intensive care with severe preeclampsia, eclampsia or HELLP syndrome. *Med Intensiva.* 2011;35:478-83. DOI: 10.1016/j.medin.2011.05.011.
4. Collantes Cubas JA, Vigil-De Gracia P, Pérez Ventura SA, Morrillo Montes OE. Enfermedad cerebrovascular hemorrágica en la eclampsia asociada al síndrome HELLP. *Rev Peru Ginecol Obstet.* 2018;64:555-62. Spanish DOI:10.31403/rpgov64i2123
5. Bushnell C, Chireau M. Preeclampsia and stroke: risks during and after pregnancy. *Stroke Res Treat.* 2011;Article ID 858134. DOI:10.4061/2011/858134
6. Martin Jr JN, Thigpen BD, Moore RC, Rose CH, Cushman J, May W. Stroke and severe preeclampsia and eclampsia: a paradigm shift focusing on systolic blood pressure. *Obstet Gynecol.* 2005;105:246-54. DOI:10.1097/01.AOG.0000151116.84113.56.

7. Crovetto F, Somigliana E, Peguero A, Figueras F. Stroke during pregnancy and pre-eclampsia. *Curr Opin Obstet Gynecol.* 2013;25:425-32.  
DOI:10.1097/GCO.0000000000000024
8. Bateman BT, Olbrecht, VA, Berman MF, Minehart RD, Schwamm LH, Leffert LR. Peripartum subarachnoid hemorrhage: nationwide data and institutional experience. *Anesthesiology.* 2012;116:324-33.  
DOI:10.1097/ALN.0b013e3182410b22.
9. Coutinho JM, Ferro JM, Canhao P, Barinagarrementeria F, Cantú C, Bousser MG, et al. Cerebral venous and sinus thrombosis in women. *Stroke.* 2009;40:2356-61.  
DOI:10.1161/STROKEAHA.108.543884
10. Hinchey J, Chaves C, Appignani B, Breen J, Pao L, Wang A, et al. A reversible posterior leukoencephalopathy syndrome. *N Engl J Med.* 1996;334:494-500.  
DOI:10.1056/NEJM199602223340803.
11. Malvino E, Ríos J, Mc Loughlin D, Moreno A. Correlacion clínica y neuro-radiológica en la eclampsia. *Medicina (Buenos Aires).* 2004;64:497-503. Spanish  
<http://www.scielo.org.ar/pdf/medba/v64n6/v64n6a04.pdf>
12. Aukes AM, de Groot JC, Aarnoudse JG, Gerda G. Zeeman. Brain lesions several years after eclampsia. *Am J Obstet Gynecol.* 2009;200:504,e1-5.  
DOI:10.1016/j.ajog.2008.12.033.
13. Chuang CJ, Chiou WY, Yang HJ, Lin HY, Hung SK, Lee MS, et al. Impact of preeclampsia/eclampsia on hemorrhagic and ischemic stroke risk: a 17 years follow-up nationwide cohort study. *PLoS ONE.* 2022;17:e0276206.  
DOI:10.1371/journal.pone.0276206
14. de Havenon A, Delic A, Stulberg E, Sheibani N, Stoddard G, Hanson H, et al. Association of preeclampsia with incident stroke in later life among women in the Framingham Heart Study. *JAMA Netw Open.* 2021;4:e215077.  
DOI:10.1001/jamanetworkopen.2021.5077.
15. Redman CWG. Pre-eclampsia and the placenta. *Placenta.* 1991;12:301-08.  
DOI:10.1016/0143-4004(91)90339-h.
16. Abramova MY, Churnosov MI. Modern concepts of etiology, pathogenesis and risk factors for preeclampsia. *Journal of Obstetrics Women's Diseases.* 2021;70:105–16.  
DOI:10.17816/JOWD77046
17. Dimitriadis E, Rolnik DL, Zhou W, Estrada-Gutiérrez G, Koga K, Francisco RPV, et al. Pre-eclampsia. *Nat Rev Dis Primers.* 2023;9:8.  
DOI:10.1038/s41572-023-00417-6
18. Harandou M, Madani N, Labibe S, Messouak O, Boujraf S, Benkirane S, et al. Neuroimaging findings in eclamptic patients still symptomatic after 24 hours: a descriptive study about 19 cases. *Ann Fr Anesth Reanim.* 2006;25:577- 83.  
DOI:10.1016/j.annfar.2006.02.022
19. Vázquez-Rodríguez JG, Salas-Magaña MT, Serrano-Rodríguez J. Incidence and Clinical Manifestations of Posterior Reversible Encephalopathy Syndrome (PRES) in patients with eclampsia. 2017-2021 Data from a High Specialty Medical Unit, Mexico City. *IJRRGY.* 2022;5:90-97.  
<https://journalijrrgy.com/index.php/IJRRGY/article/view/65/129>
20. McDermott M, Miller EC, Rundek T, Hurn PD, Bushnell CD. Preeclampsia: association with posterior reversible encephalopathy syndrome and stroke. *Stroke.* 2018;49:524-30.  
DOI: 10.1161/STROKEAHA.117.018416.
21. Tshering S, Youden S, Pema D. Eclampsia and postpartum onset of subarachnoid hemorrhage in dual setting of cerebral venous thrombosis and posterior reversible encephalopathy syndrome: A case report. *Clin Case Rep.* 2021;9(4):2210-13.  
DOI:10.1002/ccr3.3985.
22. Vázquez-Arredondo JG, Vázquez-Rodríguez JG. Plasma colloid osmotic pressure in preeclampsia. Review of the mexican literatura 1997-2018. *Cir Cir.* 2021;89:547-52.

DOI:10.24875/CIRU.19001263

23. Jaigobin C, Silver FL. Stroke and pregnancy. *Stroke*. 2000;31:2948- 51.

doi:10.1161/01.str.31.12.2948.

24. Brouh Y, Jean KK, Ouattara A, Tétchi Y, Pete Y, Koffi N, et al. Brain lesions in eclampsia: a series of 39 cases admitted in an Intensive Care Unit. *Indian J Crit Care Med*. 2016;20:178-81.

DOI:10.4103/0972-5229.178183

25. Beye MD, Diouf E, Kane O, Ndoye A, Seydi A, Ndiaye PI. Intensive care management of 28 patients with severe eclampsia in a tropical African setting. *Ann Fr Anesth Reanim*. 2003;22:25-29.

DOI:10.1016/s0750-7658(02)00807-9.

26. Ohno Y, Kawai M, Morikawa S, Sakakibara K, Tanaka K, Ishikawa K, et al. Management of eclampsia and stroke during pregnancy. *Neurol Med Chir (Tokyo)*. 2013;53:513-19.

DOI:10.2176/nmc.53.513.

27. Soydinc HE, Ozler A, Evsen MS, Sak ME, Turgut A, Basaranoglu S, et. al. A case of cerebral sinus venous thrombosis resulting in mortality in severe preeclamptic pregnant woman. *Case Rep Obstet Gynecol*. 2013;2013:402601.

<http://dx.doi.org/10.1155/2013/402601>.

28. Grammatas AL, Catton HL, Hilton D. Ischaemic stroke and pre-eclampsia in the third trimester of pregnancy: a diagnostic and therapeutic challenge. *BMJ Case Rep*. 2019;12:e229635.

DOI:10.1136/bcr-2019-229635

29. Chuang 1CJ, Chiou WY, Yang HJ, Lin HY, Hung SK, Lee MS, et al. Impact of preeclampsia/eclampsia on hemorrhagic and ischemic stroke risk: a 17 years follow-up nationwide cohort study. *PloS One*. 2022;17(11):e0276206.

DOI: 10.1371/journal.pone.0276206