

## **Case report**

**Post renal transplant fungal infections of lung- series of 3 case reports.**

### **Abstract:**

**Invasive fungal infections are a significant risk to solid organ transplant patients, with the highest risk observed in small bowel and lung transplants. Fungal infections, including candidiasis, aspergillosis, and cryptococcosis, account for a considerable proportion of infections in renal transplant recipients. The interplay between host and environmental factors, as well as the impact of antifungal prophylaxis strategies, plays a crucial role in the development of specific fungal infections. Despite advancements in therapeutic and diagnostic options, invasive fungal infections continue to cause substantial morbidity and mortality. This case series presents three cases of post-renal transplant pulmonary fungal infections: cryptococcosis, mucormycosis, and invasive pulmonary aspergillosis. Prompt diagnosis and treatment, along with optimising antifungal drug pharmacokinetics, are essential in managing fungal infections in post-renal transplant patients. Antifungal medication should be started as soon as possible, even before laboratory confirmation. This series highlights the challenges involved in diagnosing and managing invasive fungal infections in solid organ transplant recipients, emphasizing the importance of intensive antifungal therapy for successful outcomes.**

**Keywords: post renal transplant, fungal infections, lung, cryptococcosis, mucormycosis, invasive pulmonary aspergillosis, diagnosis, management, antifungal therapy.**

### **Introduction**

**Invasive fungal infections are a major problem in solid organ transplant (SOT) recipients. Host and environmental factors are critically important determinants in the epidemiology of fungal infections in transplantation. The highest risk is in small bowel (11.6%) and lung (8.6%) transplants, followed by liver (4.7%), heart (4.0%), pancreas (3.4%) and kidney (1.3%) [1]. Factors that impact the risk for developing an invasive fungal infection include the patient's environmental exposure and/or colonization with**

pathogenic fungi, use of antifungal prophylaxis, as well as the net state of immuno-suppression. Fungal infections represent 5% of infections in renal transplant recipients. Candidiasis is the most frequent, followed by aspergillosis and cryptococcosis. Invasive aspergillosis is severe and has a poor prognosis, but recent series focused on outcomes are scarce in the literature. Where as aspergillosis is most common in lung transplant recipients. The net state of immunosuppression varies widely depending on the type of transplant received. The interplay between host and environmental factors and the impact of antifungal prophylaxis strategies is more relevant to development of specific fungal infections than number of days after transplantation. For example, the median time to onset of invasive candidiasis ranges from several weeks to months in lung and liver transplant recipients, to over 2 years in kidney recipients [2]. Similarly, the median time to invasive aspergillosis is <6 months in liver transplant recipients, but occurs much later in kidney, heart and lung transplant recipients. The latter onset of invasive aspergillosis in lung transplant recipients is likely influenced by widespread use of mold-active prophylaxis in that population. Finally, cryptococcosis tends to occur between 2 and 5 years post-transplant, but can be observed much earlier in cases of donor transmission or heavy environmental exposure [2]

Improvements in therapeutic and diagnostic options are providing clinicians with unprecedented tools to evaluate, manage and prevent invasive fungal infection in solid organ transplant (SOT) recipients. Despite these advances, invasive fungal infections continue to be a major cause of morbidity and mortality in this population. Recent studies have shed new light on the epidemiology of invasive fungal infections in SOT recipients [1–3]. The overall cumulative incidence during the first year after transplantation is approximately 3%, although this varies depending on the type of organ transplanted [1]. However, the risk of infection, particularly due to inhaled fungi, persists for many years after transplant. Current epidemiological trends indicate a shift towards later infections. The consequences of fungal infection can be dire and include long hospitalizations, allograft damage and high mortality rates. Data from 15 centers involved in a prospective cohort study of invasive fungal infections in SOT recipients indicate that mortality at 12 months is approximately 40% for aspergillosis, 34% for candidiasis and 27% for cryptococcosis [1].

Infections caused by geographically limited endemic fungi are infrequent, and *Aspergillus* species, *Mucorales* species, *Candida* species, mucormycosis and *Cryptococcus neoformans* are the opportunistic fungi responsible for most such infections. The symptoms of systemic fungal infections are nonspecific, particularly in their early stages. The high rates of mortality and graft loss owing to fungal infections render early diagnosis and treatment imperative in immunosuppressed patients. Current methods for

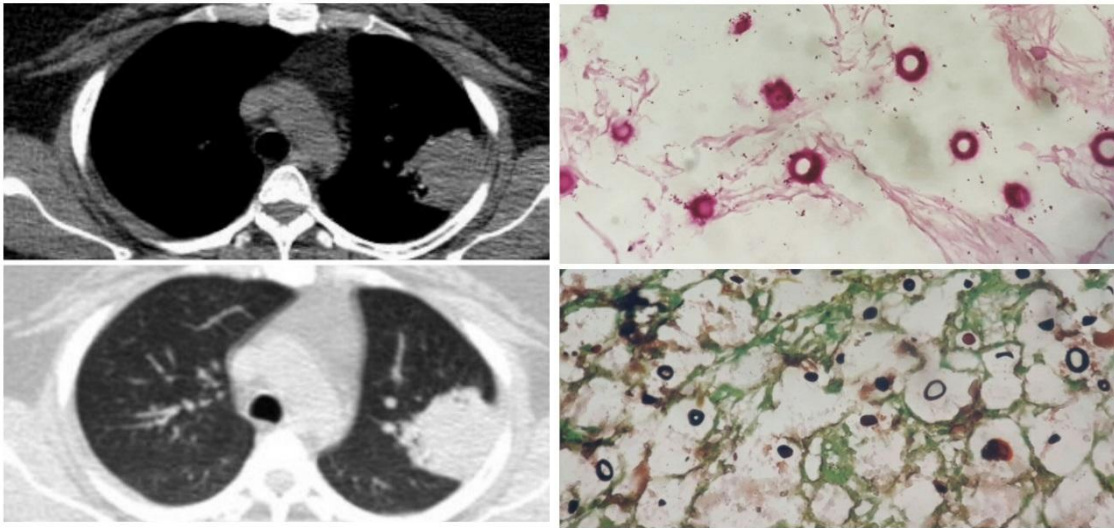
the diagnosis of systemic fungal infections include imaging procedures, endoscopic methods, biopsies, microscopic and culture techniques, antibody and antigen-based serologic testing, and the detection (via polymerase chain reaction) of fungal deoxyribonucleic acid in blood or bronchoalveolar lavage fluid, as well as the careful analysis of signs and symptoms. Antifungal therapy should be initiated early in patients with a suspected fungal infection (even before laboratory findings have confirmed that diagnosis) and should be administered with appropriate adjustment of immunosuppressive regimens. It is challenging to manage fungal infections in post renal transplant patients, optimizing the pharmacokinetics of antifungal drugs to reduce the risk of nephrotoxicity is crucial. In this article, we describe the 3 cases of post transplant pulmonary fungal infections .

Case presentation

## **CRYPTOCOCCOSIS**

**Case 1-**A Middle aged obese lady 6months post renal transplant presented to our institute with complains of dry cough, chest pain and on-off low grade fever since 1 month. She also had one episode of hemoptysis and complained of reduced appetite. Her general examination was unremarkable. Vitals were also within normal limits. Her respiratory system examination revealed dull percussion note on left side with reduced breath sounds in axillary region. Oxygen saturation was 97% at room air and normal body temperature was recorded. Her routine blood chemistry was within normal limits. She was negative for HIV and for any chronic infections. Renal function, liver function, and coagulation studies were within normal limits. She underwent chest x-ray which showed left upper lobe opacity with blunting of cardio phrenic angle. Her contrast CT scan was also done which showed peripheral well defined solid mass lesion in left upper lobe apico posterior segment with a thin rim of pleural effusion (**Figure 1.a**). Pleural fluid was exudative but negative for malignant cells. Her bronchoscopic findings was unremarkable and BAL was negative for any malignant cells and culture was also sterile. Subsequently she underwent CT guided trans-thoracic biopsy of solid lesion and tissue was sent for histopathological examination. Distinctively, it was negative for malignancy but revealed abundant fungal yeast. Gomori's silver Methenamine staining and Mucicarmine staining was carried out which confirmed presence of cryptococcal infection (**Figure 1.b**). She was also found positive for serum cryptococcal antigen. Her blood, urine and CSF culture were negative for cryptococcal. She denied any travel history or any immunosuppressant drugs exposure. Her detail immunological screening was carried out. Her IgG, IgM and IgA levels were within normal limits with normal absolute CD4 counts. She was diagnosed as Cryptococcal pneumonia and treatment was started with Inj. Amphotericin B for 2 weeks followed by oral Fluconazole 400mg BD for 10 weeks. Patient was followed

up after completion of treatment with resolution of symptoms but had persistent radiological opacity.



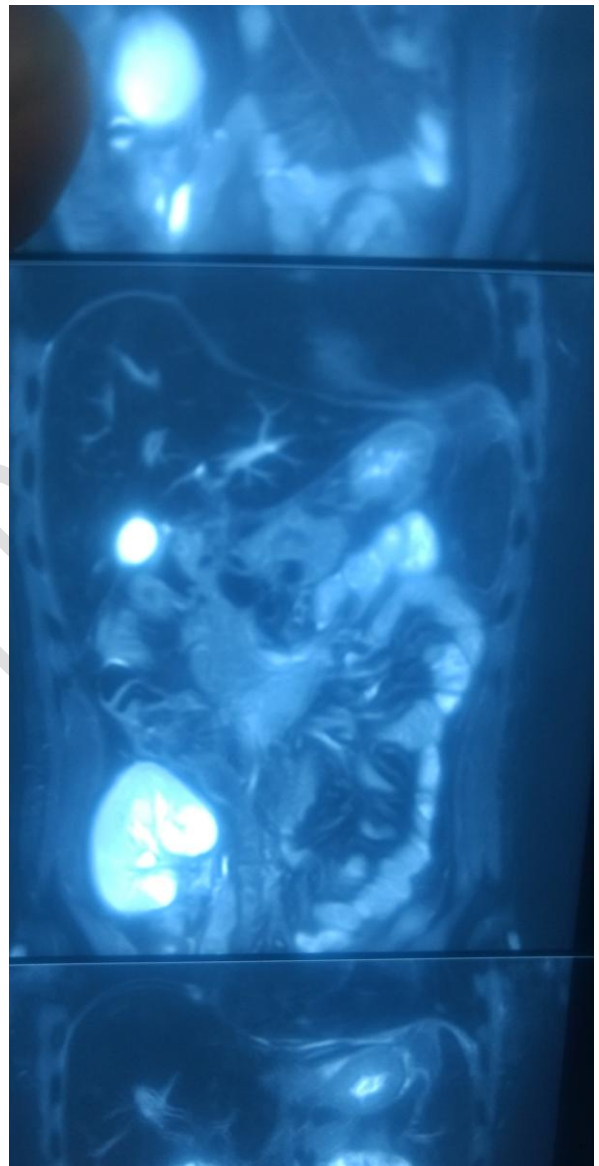
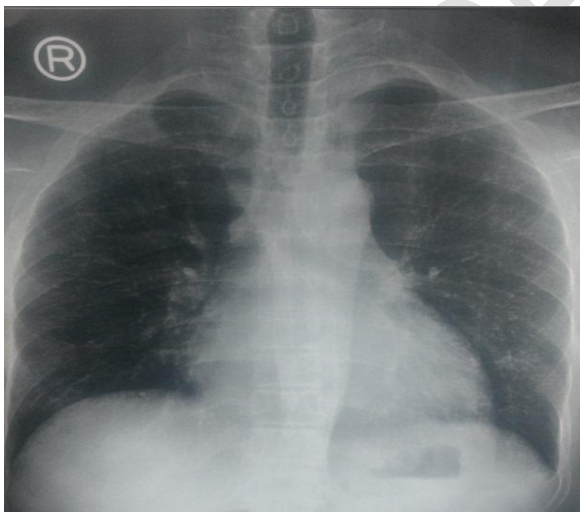
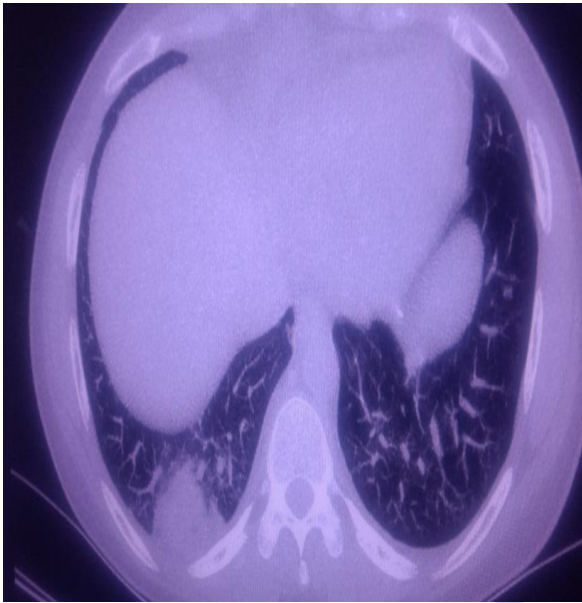
Case 1- Figure 1.a

Case 1- Figure 1.b

## MUCORMYCOSIS

**Case2-A** 24-year-old male presented with progressive generalized weakness and fever for 1 month after receiving a living unrelated kidney transplant for end-stage kidney disease of unclear etiology. He was maintained on hemodialysis for 5 years prior to the transplant. The patient was on maintenance therapy of immunosuppression consisting of mycophenolate mofetil, tacrolimus, and corticosteroids, in addition to trimethoprim/sulfamethoxazole and valganciclovir for microbial prophylaxis. On evaluation of the transplanted kidney usg showed a mass lesion in transplanted kidney. ct scan of abdomen was done, which confirmed the mass lesion of 4x5cms as shown in the **figure (2.a)** and upper cuts of ct also showed mass lesion in the right lower lobe basal segments of lung. A kidney biopsy showed evidence of acute tubular necrosis. CT guided transthoracic biopsy of the mass lesion was also performed, which revealed mucormycosis. Ct of the head showed no involvement of the sino-orbital areas or the brain. The patient was started on liposomal amphotericin B (5 mg/kg daily i.v o.d) with syrup posaconazole per oral 200mg thrice a day for mucormycosis. A cumulative dose of 3 grams of liposomal amphotericin b was administered over 2 weeks. Mycophenolate and tacrolimus were discontinued and the dose of prednisone reduced. Patient had acute increase in levels of serum creatinine levels which was treated with dialysis

every third day during treatment with amphotericin b. he became asymmtomatic within 3 days of starting the treatment and lesion showed regression in size repeat ct scan done after completion of cumulative dose. Patient is on regular follow up, and required dialysis only twice after cumulative dose in 1 month and the patient serum creatinine level is stable now.

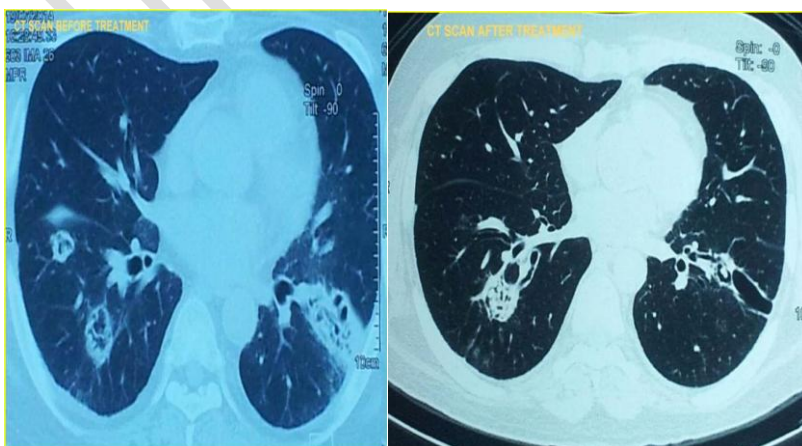


**CASE 2 -FIGURE 2.a, 2.b**CT scan of abdomen confirmed the mass lesion of 4x5cms as shown in the figure 2.b and upper cuts of CT also showed mass lesion in the right lower lobe basal segments of lung in figure 2.a

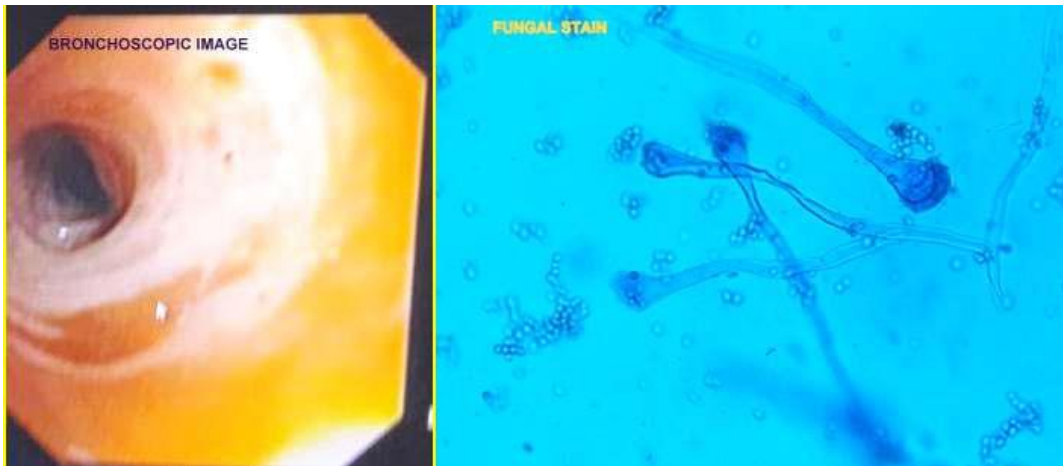
## Invasive pulmonary aspergillosis

**Case report 3:-** Case2-A 43-year-old male presented with cough with expectoration, fever, haemoptysis for 15 days after 4 years of receiving a cadaver kidney transplant for end-stage kidney disease. The patient was on maintenance therapy of immunosuppression consisting of cyclosporine and corticosteroids.

Vital signs in the emergency department were temperature 100.8F, blood pressure 144/66 mm Hg, heart rate 80/min, respiratory rate 30/min, and oxygen saturation 99% on room air. Clinical examination revealed fine crepitations in bilateral infrascapular area. Laboratory data showed white cell count 7000 cells/dl with 82% neutrophils, hemoglobin 10 g/dl, hematocrit 25%, blood urea nitrogen 77 mg/dl, and serum creatinine 3.5 mg/dl. Liver function tests and electrolytes were normal. Electrocardiogram was normal and chest X-ray was showed b/l cavitary lesion in lower lobes. Peak expiratory flow rate was 200 L/min. ct scan confirmed the cavitating macro nodules with halo sign in both lower lobes. Serum mycoplasma antibody, urine legionella antigen, nasal swab for respiratory syncytial virus and influenza antigen, and rapid streptococcal throat tests were negative. Bronchoscopy revealed whitish plaques in lower lobe bronchus. Bal b-galactomann was highly positive, bronchial washing showed branching hyphae and cultures showed green colour aspergillus fumigatus. Hence the diagnosis of IPA was confirmed. He was treated with incremental doses of amphotericin b followed by voriconazole 200mg for 6 months, follow up ct scan and clinical improvement was satisfactory.



### CASE 3 -FIGURE 3.a



### CASE 3 -FIGURE 3.b

## DISCUSSION

The diagnosis of invasive fungal infection in patients undergoing solid organ or bone marrow transplantation remains a significant clinical challenge. Consideration of the epidemiology of these infections and host risk factors may be an important clue to a specific fungal diagnosis. Despite extensive investigation on methods such as serologic techniques to improve the rapid diagnosis of these infections, the diagnosis of invasive mycoses remains largely dependent on clinical presentation. For example, the signs and symptoms that result from angioinvasion of fungal organisms include pleuritic chest pain or hemoptysis. In a high-risk patient these findings can be important clues to invasive fungal infection. Cultures of opportunistic fungi in certain settings, such as *Aspergillus* in respiratory samples from immunosuppressed patients, may be associated with infection. Radiographic findings can also be useful to establish a diagnosis of infection such as halo and reverse halo sign. In patients with invasive mucormycosis as well as other angioinvasive moulds, chest CT scans may demonstrate lesions that are not visible on plain radiographs as seen in our case 2 where chest x ray is normal . Serodiagnosis of these infections remains largely investigational. Microbiological antifungal resistance has increasingly been reported, but in patients at high risk for serious fungal infection, antifungal resistance remains uncommon, particularly in *Candida albicans*. Higher doses of azoles should be used to treat patients with infections due to less susceptible yeasts and those with **infection that is**

**more serious.** Prompt recognition of fungal infection combined with intensive antifungal therapy is needed for successful therapy.

## **Cryptococcosis**

Pulmonary cryptococcosis is caused mainly by inhalation of aerosols containing yeast. Commonly found neoformans variant of cryptococcal neoformans is an encapsulated, unimorphic fungus that is ubiquitous in soil and particularly abundant in pigeon excreta. Cryptococcosis most commonly occurs in immunocompromised conditions like HIV reactive or organ transplant patients. *Cryptococcus neoformans* var. *neoformans* is mainly found amongst the immunocompromised while immunocompetent patients usually have *C.gatti* variant.<sup>1</sup>In immunocompromised patients, the organism may cause diffuse pulmonary disease rather than an isolated pulmonary disease like in immunocompetent individuals. Meningoencephalitis remains the commonest form of cryptococcal infection overall. Here we present a case of apparently non immunocompromised female having respiratory symptoms which was diagnosed subsequently as cryptococcal infection.

## **IPA**

The diagnosis of IPA is challenging due to the nonspecific nature of the symptoms and is often delayed due to lack of clinical suspicion in patients without classic risk factors. Tissue biopsy with histopathologic demonstration of tissue invasion by fungal hyphae is considered the 'gold standard' (9). Invasive aspergillosis can be a catastrophic complication in SOT recipients and is associated with high rates of graft loss and death. Data from 15 centers involved in a prospective cohort study indicate that mortality at 12 months for SOT recipients with aspergillosis exceeds 50% [1]. The most common infecting species is *Aspergillus fumigatus*. Infections due to *Aspergillus flavus*, *Aspergillus niger* and *Aspergillus terreus* are less common [67,68]. However, obtaining tissue specimens from critically ill, often intubated, and hemodynamically unstable patients is not always feasible. Identification of *Aspergillus* species in the sputum could represent colonization, especially in immunocompetent patients (1, 10). On the contrary, isolation of *Aspergillus* from sputum in patients with leukemia, or in those who have undergone SCT, has a positive predictive value of 80-90% for the presence of IPA (1, 11, 12). Nosocomial transmission leading to colonization and even infection has been described [71]. In one notable case, debridement and dressing of wounds from a patient with aspergillosis resulted in aerosolization of spores and airborne person-to-person transmission in a transplant ICU [72]. Diagnosis of invasive aspergillosis can be challenging and frequently require histological evidence for infection

and culture. Specimens (e.g., smears and tissue) can be stained with Gomori's Methenamine Silver and periodic acid-Schiff or with fluorescent dyes such as Calcofluor white [84]. Immunohistochemistry techniques are another promising diagnostic modality, but are not in widespread use as of yet

With regard to imaging studies, Patterson et al., in their review of 595 cases of IPA, reported that 85% of the cases had computed tomographic (CT) scan findings suggestive of IPA (13). HRCT is recommended in all cases of suspected IPA. Pulmonary nodules are the most commonly seen abnormality whereas the 'halo sign' is relatively more specific with a high predictive value for IPA in patients with neutropenic fever after SCT (14). Laboratory tests to detect *Aspergillus* antigens in body fluids, either serum or bronchoalveolar lavage fluid (BAL), are increasingly helpful in the diagnosis of IPA. Galactomannan (GM) testing or *Aspergillus* polymerase chain reaction (PCR) assay in BAL has good sensitivity and specificity for IPA (2, 15). BAL GM testing is part of the diagnostic criteria for IPA (16). The mortality rate of IPA continues to be very high, exceeding 50% in neutropenic patients (14), and 90% in SCT recipients (18). Amphotericin used to be the preferred antifungal, until a large randomized clinical trial comparing amphotericin with voriconazole for primary treatment of IPA showed a better response rate and higher survival (71 vs. 58%) at 12 weeks of therapy in the voriconazole group. Voriconazole also has a better side effect profile and is generally better tolerated. Echinocandins, such as caspofungin, are used as salvage therapy in patients not responding to or not tolerating first-line therapy (1). Due to differences in their mechanisms of action, combination therapy with azoles, trienes, and echinocandins could be a strategy to treat IPA (1). At present, voriconazole is considered the therapy of choice (19). Prolonged and high-dose corticosteroid therapy is an established risk factor for the development of IPA (1, 2). Steroids inhibit macrophage killing of *Aspergillus* by nonoxidative mechanisms (20). Steroids may also promote the growth of *Aspergillus* (21). Although IPA is seen in patients with chronic lung diseases on long-term steroids, it is rarely seen with short use of corticosteroids (1, 2, 22).

## **Mucormycosis**

The most form of disease was rhino-cerebral , followed by pulmonary . Overall mortality rate was 52%, particularly in recipients with pulmonary infection (100%); however, the mortality rate in rhino-cerebral form of disease was low (30.8%). There was no statistically significant difference in mortality rate between male and female . In addition, no significant differences were seen in mortality rate with age of patients and time of diagnosis since transplantation . Pulmonary infection was more seen in

recipients received azathioprine compared to those on mycophenolate mofetil .

Mucorales are ubiquitous in nature and rarely cause disease in immunocompetent hosts, except in the settings of uncontrolled diabetes mellitus[7], heavy exposure as in natural disasters, [8, 9] or rarely without apparent predisposing factors [7, 10, 11]. Recipients of SOT are at higher risk given their multiple predisposing factors. Diabetes mellitus remains the leading risk factor among all studied patient populations, as 36% of Roden et al.'s 929 cases were diabetic, mostly type 2, and in the setting of ketoacidosis [7]. Thus it remains an independent risk factor even in the presence of other predisposing factors [12]. Another major risk factor is the state of immunosuppression, especially the use of potent T cell depleting agents [13, 14] Use of tacrolimus was associated with a 4-fold reduction in the risk of developing mucormycosis [6]. This could be explained by the synergy demonstrated in vitro between calcineurin inhibitors and triazole antifungals against some species of mucormycosis [18, 19] In the reported literature, the species of Mucorales accounting for most of the cases is variable, likely reflecting regional and hospital variability. *Rhizopus* species is the most common, accounting for 35%–73% of cases, followed by *Mucor* (13%–37%) and *Mycocladius* (0%–13%) [4, 6, 7, 15]. The infection is acquired through inhalation of spores or rarely through direct contact with the skin. The hyphae of pathogenic Mucorales are angioinvasive, which lead to hemorrhagic necrosis, vascular thrombosis, and tissue infarction [1, 9]. The primary site of infection varies according to the host's condition. Localized sinonasal or sino-orbital disease with involvement of the brain accounts for 66% of mucormycosis in diabetic patients. However, pulmonary infection is the predominant site affected in recipients of SOT [4, 7], accounting for 39% of cases with involvement of other organ sites in 48% [6].

In the SOT population, disseminated disease occurs in 9–26% of cases, with the highest incidence among liver transplant recipients (26–55%), followed by lung (11–25%), heart (11–20%), and kidney transplant recipients (9–13%) [6, 7, 12, 15]. The unique factors that increase the risk of dissemination in specific organ transplant groups remain undefined. The risk of dissemination based on the primary site of infection among SOT recipients is unknown but has been reported among all cases of mucormycosis, including but not exclusive to SOT [7]. About 50% of patients with pulmonary infection suffered from dissemination [7]. The diagnosis of mucormycosis is challenging and often delayed [29, 36], as the clinical presentation is not specific and symptoms and signs are often muted by the

blunted immune response. Timely diagnosis and treatment are crucial due to the aggressive course of mucormycosis that may eventually lead to tissue necrosis and dissemination. The diagnosis is confirmed by a high index of suspicion and suggestive signs and symptoms are combination of radiological, histological, and microbiological studies. Plain or contrast enhanced CT or magnetic resonance imaging (MRI) of the head, sinuses, brain, chest, and abdomen may show some suggestive radiological signs [1, 13]. CT features of pulmonary mucormycosis in SOT recipients commonly include consolidation or mass-like lesions, nodules, or cavities in about 25% of cases. The etiological diagnosis, and direct identification of the organism by culture or histopathology is the gold standard. The hyphae of Mucorales are broad, irregularly branched, thin-walled, and sparsely septate (Figure 1)

Molecular diagnostic tests for identification of Mucorales are increasingly used

for early detection of infection and identification of genus even in cases when cultures are negative. Qualitative and quantitative PCR has been used to detect infection in lung tissue, bronchoalveolar lavage fluid, and serum samples [39]. Whether these techniques can be recommended for routine use remains unclear, although PCR testing should be considered in cases where the histopathology is suggestive of Mucorales, but cultures are negative [39–41]. Mucorales

do not release  $\beta$ -D-glucan during their growth, so a positive galactomannan serum assay indicates coinfection with *Aspergillus* [4]. Timely initiation of treatment is crucial and associated with better survival [36]. The optimal management

of mucormycosis is based upon early recognition and initiation of treatment, surgical resection of necrotic tissue if possible, and reversal of predisposing factors, such as uncontrolled glycemia, IS, and neutropenia. Surgery is an essential part of the management of localized disease, such as rhino-orbito-cerebral disease, and surgical resection and debridement are associated with improved

outcomes [7]. Lobectomy and nephrectomy were reported to be successful in isolated pulmonary [29, 43] and renal disease, respectively [22]. Salvage hepatic resection and retransplantation have also been reported [44]. Amphotericin B (AmB) and posaconazole are the only antifungal agents currently available that are active against Mucorales. AmB is considered the drug of choice. Lipid formulations of AmB are thought to have better activity and safety profile compared to conventional AmB. Treatment with AmB lipid complex

(ABLCL) was reported to be successful in 8 of 14 (57%) SOT recipients with mucormycosis [6, 29], compared to 16 of 17 patients (94%) treated with liposomal AmB (LAmB) [6]. The reduced nephrotoxicity associated with standard doses of LAmB would make it the primary agent for treatment in

SOT recipients, as these patients are usually receiving other potentially nephrotoxic agents such as calcineurin inhibitors. LAmB would also be preferred in renal transplant recipients where nephrotoxicity can result in graft failure.

Posaconazole is available in oral formulation only and has been used as an oral step-down agent after successful response with AmB or for salvage therapy in case of refractory disease or intolerance to side effects of AmB [32, 33]. In a

retrospective study, 91 patients with mucormycosis (including 10 SOTs) received at least 30 days of enteric posaconazole at 400mg twice a day as a salvage therapy. At 12 weeks, total response rate was 60%, of which complete and partial responses accounted for 14% and 46%, respectively. The disease remained stable in 21% of patients and progressed in 17%, and the outcome in the remaining 2% was not known [32]. The initiation of posaconazole as first-line therapy for the treatment of serious fungal infections remains problematic. Posaconazole is presently available for oral administration only. The oral bioavailability is enhanced when administered with a fully fatty meal and with a lower stomach acid pH

[47]. Hence posaconazole has to be administered soon after a full meal especially with fatty foods, liquid nutritional supplements, or an acidic carbonated beverage [48]. Therapeutic drug monitoring may be important in optimizing outcomes

due to erratic absorption resulting in unpredictable levels. This is especially true in the presence of a concentration effect relationship [47]. The dietary requirements for optimal absorption and achievement of therapeutic drug levels can be

difficult in transplant recipients receiving several other oral medications.

Various outcomes have been reported using different combination therapies with a small number of patients. Combination of LAmB with posaconazole was no more effective than LAmB alone in a murine model of mucormycosis [49].

Although echinocandins are reported to have no to moderate activity against Mucorales [30, 50–54], the use of an echinocandin in combination therapy has been attempted. Combined with a median of 2 surgical procedures per

patient, Reed et al. [30] reported a 100% success rate (6/6) with the combination of caspofungin with a lipid AmB, compared to 45% (14/31) success rate for those treated with ABLC monotherapy.

Isavuconazole is a new broad-spectrum triazole antifungal agent that has good *in vitro* activity against clinically important yeasts and molds including *Aspergillus* and Mucorales. The drug has a favorable pharmacokinetic profile, is available as an intravenous and oral formulation, and has the advantage of less drug-drug interaction than voriconazole and

posaconazole. It is presently in phase III clinical trials for the treatment of invasive aspergillosis and other molds [55].

Mucormycosis occurs in patients with iron overload, as host iron availability is important for the pathogenesis of mucormycosis. Adjunctive therapy with deferasirox iron chelation and LAmB had shown improved outcomes in the diabetic mouse model of mucormycosis. However, a small clinical trial of 20 patients (DEFEAT Mucor Study) using LAmB and deferasirox demonstrated worse outcomes in the deferasirox arm [56]. Currently, there are no recommendations regarding routine prophylaxis against fungal infections in kidney transplant recipients.

The overall mortality rate of mucormycosis ranges from 38% to 56.5%. The primary site of infection plays a major role in determining the outcome, with marked increase in mortality when dissemination occurs, reportedly up to 100%. Mortality has been reported from 33% to 60% for isolated pulmonary infection, but 95% when disseminated.

### **Conclusion & future perspective**

Invasive fungal infections are an important cause of morbidity and mortality in SOT recipients. In the past few years there have been major advances in our understanding of the epidemiology of these infections and development of improved diagnostic and therapeutic tools. However, outcomes in patients with these infections continue to be suboptimal. In the next 5–10 years, several key trends will likely impact the landscape of invasive fungal infections occurring in SOT recipients. Specifically, these include a changing epidemiology of transplant organ recipients, an improved ability to diagnose fungal infections and widespread availability of newer antifungal agents. The epidemiology of organ recipients will be affected by use of novel and highly immunosuppressive regimens to prevent and manage organ rejection episodes. Moreover, mirroring national trends, the population of organ recipients will likely become increasingly diverse with respect to age, ethnicity and comorbid medical conditions. The ability to detect fungal colonization and/or infection will improve with further development and increasing deployment of nonculture-based diagnostic tools (e.g., antigen, antibody and nucleic acid detection assays). These, coupled with the increasing use of potent, broad-spectrum antifungal agents (e.g., voriconazole and posaconazole) for prophylaxis and treatment, will significantly alter the timing and outcomes of invasive fungal infections in this population. At the same time, advances in understanding fungal pathogenesis, host immune mechanisms and the pharmacology of antifungal compounds will provide new avenues for prevention and treatment. Therapy with liposomal AmB remains the cornerstone of treatment, with posaconazole used as a second-line option in case of treatment failure or intolerance. The role of combination therapy and newer

agents such as isavuconazole therapy remains to be defined. Despite early diagnosis and treatment, graft loss and mortality rate remain high in patients with disseminated disease. New data that integrates the results generated from traditional prospective clinical trials, clinical and genomic databases and laboratory-based investigations will be needed to meet these challenges.

## References:

1. Capoor M, Nair D, Deb M, Gupta B, Aggarwal P. Clinical and mycological profile of cryptococcosis in a tertiary care hospital. *Indian Journal of Medical Microbiology*. 2007;25(4):401–404
2. Banerjee U, Datta K, Casadevall A. Serotype distribution of *Cryptococcus neoformans* in patients in a tertiary care center in India. *Medical mycology*. 2004 Apr 1;42(2):181-6.
3. Matsushita T, Suzuki K. Spastic paraparesis due to cryptococcal osteomyelitis: a case report. *Clinical Orthopaedics and Related Research*. 1985;196:279–284
4. Nunez M, Peacock JE, Chin R. Pulmonary cryptococcosis in the immunocompetent host: therapy with oral fluconazole—a report of four cases and a review of the literature. *Chest*. 2000;118(2):527–534
5. Nadrous H, Antonios V, Terrell C, Ryu J. Pulmonary cryptococcosis in nonimmunocompromised patients. *Chest* 2003; 124:2143–7.
6. Hammerman KJ, Powell KE, Christianson CS, et al. Pulmonary cryptococcosis: clinical forms and treatment. *Am Rev Respir Dis* 1973; 108:1116–1123
7. Robinson GR II. Severe cryptococcal pneumonia. *N Engl J Med* 1995; 332:1752
8. Fox DL, Müller NL. Pulmonary cryptococcosis in immunocompetent patients: CT findings in 12 patients. *AJR* 2005; 185:622–626

9. McAdams HP, Rosado-de-Christenson ML, Templeton PA, Lesar M, Moran CA. Thoracic mycosis from opportunistic fungi: radiologic–pathologic correlation. *RadioGraphics* 1995; 15:271–286
10. Fisher JF, Valencia-Rey PA, Davis WB. Pulmonary Cryptococcosis in the Immunocompetent Patient—Many Questions, Some Answers. In *Open forum infectious diseases* 2016 May 1 (Vol. 3, No. 3, p. ofw167). Oxford University Press.
11. Perfect J, Dismukes W, Dromer F, et al. Clinical practice guidelines for the management of cryptococcal disease: 2010 update by the Infectious Diseases Society of America. *Clin Infect Dis* 2010; 50:291–322.
12. Kosmidis C, Denning DW. The clinical spectrum of pulmonary aspergillosis. *Thorax* 2014; Oct 29. pii: thoraxjnl-2014-206291. doi: 10.1136/thoraxjnl-2014-206291.
13. Lake KB, Browne PM, Van Dyke JJ, Ayers L. Fatal disseminated aspergillosis in an asthmatic patient treated with corticosteroids. *Chest* 1983; 83(1): 138\_9.
14. Choi YR, Kim JT, Kim JE, Jung HW, Choe KH, Lee KM, et al. Invasive aspergillosis involving the lungs and brain after short period of steroid injection: A case report. *Tuberc Respir Dis (Seoul)* 2012; 72(5): 448\_51.
15. Steinbach WJ, Marr KA, Anaissie EJ, Azie N, Quan SP, Meier-Kriesche HU, et al. Clinical epidemiology of 960 patients with invasive aspergillosis from the PATH Alliance registry. *J Infect* 2012; 65(5): 453\_64.
16. Chandrasekar P. Invasive mold infections: Recent advances in management approaches. *Leuk Lymphoma* 2009; 50(5): 703\_15.
17. Pini G, Faggi E, Donato R, Sacco C, Fanci R. Invasive pulmonary aspergillosis in neutropenic patients and the influence of hospital renovation. *Mycoses* 2008; 51(2): 117\_22.
18. Lambourne J, Agranoff D, Herbrecht R, Troke PF, Buchbinder

A, Willis F, et al. Association of mannose-binding lectin deficiency with acute invasive aspergillosis in immunocompromised patients. *Clin Infect Dis* 2009; 49(10): 1486\_91.

19. Shelhamer JH, Gill VJ, Quinn TC, Crawford SW, Kovacs JA, Masur H, et al. The laboratory evaluation of opportunistic pulmonary infections. *Ann Intern Med* 1996; 124(6): 585\_99.

20. Soubani AO, Khanchandani G, Ahmed HP. Clinical significance of lower respiratory tract *Aspergillus* culture in elderly hospitalized patients. *Eur J Clin Microbiol Infect Dis* 2004; 23(6): 491\_4.

21. Horvath JA, Dummer S. The use of respiratory-tract cultures in the diagnosis of invasive pulmonary aspergillosis. *Am J Med* 1996; 100(2): 171\_8.

22. Yu VL, Muder RR, Poorsattar A. Significance of isolation of *Aspergillus* from the respiratory tract in diagnosis of invasive pulmonary aspergillosis. Results from a three-year prospective study. *Am J Med* 1986; 81: 249\_54.

23. Patterson TF, Kirkpatrick WR, White M, Hiemenz JW, Wingard JR, Dupont B, et al. Invasive aspergillosis. Disease spectrum, treatment practices, and outcomes. I3 *Aspergillus* Study Group. *Medicine (Baltimore)* 2000; 79(4): 250\_60.

24. Yeghen T, Kibbler CC, Prentice HG, Berger LA, Wallesby RK, McWhinney PH, et al. Management of invasive pulmonary aspergillosis in hematology patients: A review of 87 consecutive cases at a single institution. *Clin Infect Dis* 2000; 31(4): 859\_68.

25. Hoenigl M, Prattes J, Spiess B, Wagner J, Pruellner F, Raggam RB, et al. Performance of galactomannan, beta-d-glucan, *Aspergillus* lateral-flow device, conventional culture, and PCR tests with bronchoalveolar lavage fluid for diagnosis of invasive pulmonary aspergillosis. *J Clin Microbiol* 2014; 52(6): 2039\_45.

26. De Pauw B, Walsh TJ, Donnelly JP, Stevens DA, Edwards JE, Calandra T, et al. Revised definitions of invasive fungal disease from the European Organization for Research and Treatment of Cancer/Invasive Fungal Infections Cooperative Group and the National Institute of Allergy and Infectious Diseases Mycoses Study Group (EORTC/MSG) Consensus Group. *Clin Infect Dis* 2008; 46(12): 1813\_21. doi: 10.1086/588660.
27. Bulpa P, Dive A, Sibille Y. Invasive pulmonary aspergillosis in patients with chronic obstructive pulmonary disease. *Eur Respir J* 2007; 30(4): 782\_800.
18. Fukuda T, Boeckh M, Carter RA, Sandmaier BM, Maris MB, Maloney DG, et al. Risks and outcomes of invasive fungal infections in recipients of allogeneic hematopoietic stem cell transplants after nonmyeloablative conditioning. *Blood* 2003; 102(3): 827\_33.
29. Herbrecht R, Denning DW, Patterson TF, Bennett JE, Greene RE, Oestmann JW, et al. Invasive Fungal Infections Group of the European Organisation for Research and Treatment of Cancer and the Global Aspergillus Study Group. Voriconazole versus amphotericin B for primary therapy of invasive aspergillosis. *N Engl J Med* 2002; 347(6): 408\_15.
30. Schaffner A, Schaffner T. Glucocorticoid-induced impairment of macrophage antimicrobial activity: Mechanisms and dependence on the state of activation. *Rev Infect Dis* 1987; 9(Suppl 5): S620\_9.
31. Ng TT, Robson GD, Denning DW. Hydrocortisone-enhanced growth of *Aspergillus* spp.: Implications for pathogenesis. *Microbiology* 1994; 140(Pt 9): 2475\_9.
32. Cornet M, Mallat H, Somme D, Gue´rot E, Kac G, Mainardi JL, et al. Fulminant invasive pulmonary aspergillosis in immunocompetent

patients \_ A two-case report. *Clin Microbiol Infect* 2003; 9(12): 1224\_7.

33. Lopes Bezerra LM, Filler SG. Interactions of *Aspergillus fumigatus* with endothelial cells: Internalization, injury, and stimulation of tissue factor activity. *Blood* 2004; 103(6): 2143\_9.

34. Einollahi B, Lessan-Pezeshki M, Pourfarziani V et al: Invasive fungal infections following renal transplantation: A review of 2410 recipients. *Ann Transpl*, 2008; 13(4): 55–58

35. Chkhotua A, Yussim A, Tovar A et al: Mucormycosis of the renal allograft: case report and review of the literature. *Transpl Int*, 2001; 14(6): 438–41

36. Nampoory MR, Khan ZU, Johny KV et al: Invasive fungal infections in renal transplant recipients. *J Infect*, 1996; 33(2): 95–101

37. Grossi PA: Clinical aspects of invasive candidiasis in solid organ transplant recipients. *Drugs*, 2009; 69(Suppl.1): 15–20

38. Almyroudis NG, Sutton DA, Linden P et al: Zygomycosis in solid organ transplant recipients in a tertiary transplant center and review of the literature. *Am J Transplant*, 2006; 6(10): 2365–74

39. Aslani J, Eizadi M, Kardavani B et al: Mucormycosis after kidney transplantations: report of seven cases. *Scand J Infect Dis*, 2007; 39(8): 703–6

40. Roden MM, Zaoutis TE, Buchanan WL et al: Epidemiology and outcome of zygomycosis: A review of 929 reported cases. *Clinical Infectious Diseases*, 2005; 41(5): 634–53

*Ann Transplant*, 2011; 16(3): 44-48 Einollahi B et al – Two decades of experience in Mucormycosis after... 47

42. Kubak BM, Huprikar SS: Emerging & rare fungal infections in solid organ transplant recipients. *Am J Transplant*, 2009;9(Suppl.4): S208–26
  43. Ghadiani MH, Ahmadpour P, Lessan-Pezeshki M et al: Mucormycosis after Living Donor Kidney Transplantation: A Multicenter Retrospective Study. *Int J Nephrol Urol*, 2009; 1(1): 39–44
  44. Kontoyiannis DP, Wessel VC, Bodey GP, Rolston KV: Zygomycosis in the 1990s in a tertiary-care cancer center. *Clin Infect Dis*, 2000; 30(6): 851–56
  45. Singh N, Gayowski T, Singh J, Yu VL: Invasive gastrointestinal zygomycosis in a liver transplant recipient: case report and review of zygomycosis in solid-organ transplant recipients. *Clin Infect Dis*, 1995; 20(3): 617–20
  46. Marr KA, Carter RA, Crippa F et al: Epidemiology and outcome of mould infections in hematopoietic stem cell transplant recipients. *Clin Infect Dis*, 2002; 34(7): 909–17
  47. Stelzmueller I, Lass-Floerl C, Geltner C et al: Zygomycosis and other rare filamentous fungal infections in solid organ transplant recipients. *Transpl Int*, 2008; 21(6): 534–46
  48. Nouri-Majalan N, Moghimi M: Skin mucormycosis presenting as an erythema-nodosum-like rash in a renal transplant recipient: a case report. *J Med Case Reports*, 2008; 2: 112
  49. Page AV, Evans AJ, Snell L, Liles WC: Primary cutaneous mucormycosis in a lung transplant recipient: case report and concise review of the literature. *Transpl Infect Dis*, 2008; 10(6): 419–25
- Original Paper *Ann Transplant*, 2011; 16(3): 44-48 48