

## Case report

### **Endobronchial glandular papilloma : A case report**

#### **Abstract:**

Endobronchial glandular papilloma is a rare benign tumor without malignant transformation, often unrecognized, histology confirms the diagnosis and treatment differs depending on the clinical manifestations and the location of the tumor.

Our 52 years old patient complained from expiratory dyspnea , the flexible bronchoscopy has allowed to confirm the diagnosis , rigid bronchoscopy allowed a complete resection of the tumor.

#### **Keywords:**

Benign tumors, glandular papilloma, epithelial tumors, solitary papilloma

#### **Introduction :**

Solitary pulmonary papillomas are rare benign neoplasms derived from bronchial gland in adults. Above all, glandular papilloma is one of the rarest subtypes of this entity. Glandular papillomas occur predominantly in the central tracheobronchial tree (1), most reported symptom reported is coughing but can be asymptomatic, bronchoscopic biopsy or computed tomography (CT) guided biopsy is needed to confirm the diagnosis (2) . The treatment should be

decided on a case by case basis according to clinical manifestations and the location, morphology, and time course of the tumor (3).

### **Case Report :**

A 52 years old female , with no toxic habits and no particular pathological history was admitted in our pulmonology department complaining of expiratory dyspnea , without productive cough or hemoptysis, and with no other thoracic or extrathoracic signs, all evolving in a context of conservation of the general state.

The clinical examination showed reduced vesicular murmurs with hypertympanism in the left hemithorax, the rest of the clinical examination was without abnormalities.

Chest X-ray revealed increased transparency of the left hemithorax with likely obstructive emphysema (Figure 1); Chest CT showed obstructive emphysema with a mass in the left main bronchus ( Figure 2).

Flexible bronchoscopy revealed almost complete obstruction of the left upper lobar bronchus by a magma of superimposed buds giving a grape-like appearance vascularized in some parts (Figure 3); tumor biopsies revealed a tumor proliferation with a papillary architecture without atypia in favor of a bronchial papilloma.

The patient was referred for thoracic surgery, a complete removal of the tumor was performed by rigid bronchoscopy, histology revealed an endobronchial glandular papilloma.

The clinical course was marked by the disappearance of expiratory dyspnea, the pleuropulmonary examination was essentially normal; the chest X-ray was essentially normal (Figure 4), the chest CT scan did not show any visible tumor or obstructive emphysema (Figure 5). A follow-up flexible bronchoscopy was performed after 3 months, showing no visible tumor (Figure 6).

### **Discussion:**

Benign tumors of the lung are less common than malignant tumors; their incidence ranges from 1% to 5% of lung tumors (4). According to the World Health Organization classification in 1999, benign bronchopulmonary tumors can be divided into epithelial tumors, mesenchymal tumors, and tumor-like lesions (5).

Papillomatous lesions of the endobronchial tree have been classified into 3 groups: multiple squamous papillomas, inflammatory polyps and solitary papilloma (6). Solitary endobronchial papillomas constitute only 0.38% of all lung tumors and about 7% of all benign epithelial and mesenchymal lung tumors (3). Three histologic subtypes of solitary papillomas have been recognized: squamous cell papilloma, glandular papilloma, and mixed squamous cell and glandular papilloma. The glandular papilloma is one of the rarest subtypes of pulmonary papillomas (1), Only 30 cases have been published mentioning glandular papilloma from 1954 to 2019 (7), Glandular papillomas occur predominantly in the central

tracheobronchial tree (1), most reported symptom reported is coughing but can be asymptomatic (2), our patient was complaining of expiratory dyspnea. On CT or roentgenogram, these lesions were demonstrated as the findings of atelectasis, nodule, airspace consolidation, or mass (1), the presence of air and solid components within the nodule have also been described in the literature , It is essential to distinguish such tumors from active inflammation, granulomatous disease, carcinoid, and lung cancer and hence bronchoscopic biopsy or computed tomography (CT) guided biopsy is needed to confirm the diagnosis (2), Compared with squamous papillomas showing a malignant potential, there have been no reports of malignant transformation of glandular papillomas (1). For differential diagnosis, it is noteworthy that endobronchiolar papillomatous fronds are consistently seen and spread along alveolar walls is limited in adjacent alveoli. Glandular papillomas seldom show necrosis, and the presence of ciliated cells is considered to be an important finding for ruling out peripheral well-differentiated adenocarcinoma (3).

In the absence of demonstrable malignant potential, conservative management of glandular papillomas (i.e., with laser ablation or bronchoscopic debridement) seems justifiable, in contrast to surgical resection that is favored for squamous papillomas. In small lesions, the bronchoscopic treatment, i.e., electrocautery or photodynamic therapy or yttrium aluminum garnet laser may be sufficient , there

were no data to support these procedures. The best appropriate treatment is unclear (8), the treatment should be decided on a case by case basis according to clinical manifestations and the location, morphology, and time course of the tumor (3).

Glandular papilloma remains very rare benign tumors without malignant transformation, histology confirms the diagnosis and treatment differs depending on the clinical manifestations and the location of the tumor.

**Ethics statement :**

The authors declare that appropriate written informed consent was obtained for the publication of this manuscript and accompanying images

**References:**

1. Nakagawa M, Hara M, Shibamoto Y, Yano M, Takahashi S. CT findings of bronchial glandular papilloma. *Journal of Thoracic Imaging*. 2008;23(3):210–2.
2. Agrawal A, Alagusundaramoorthy SS. Respiratory papillomas. *Lung India*. 2016;33(5):522.
3. Suzuki S, Goto T, Emoto K, Hayashi Y. Rapidly growing glandular papilloma associated with mucus production: A case report. *World Journal of Surgical Oncology*. 2014;12(1).

4. Yoon YC, Lee KS, Kim TS, Seo JB, Han J. Benign bronchopulmonary tumors: Radiologic and pathologic findings. *Journal of Computer Assisted Tomography*. 2002;26(5):784–96.
5. Brambilla E, Travis WD, Colby TV, Corrin B, Shimosato Y. The New World Health Organization classification of Lung Tumours. *European Respiratory Journal*. 2001;18(6):1059–68.
6. Ichrouch F, Hoa D, Durand G, Sénac J-P. Tumeurs Bénignes Bronchopulmonaires. *EMC - Radiologie*. 2005;2(4):457–73.
7. Wu C-W, Chen A, Huang T-W. Diagnosis and management of glandular papilloma of Lung: A case report. *World Journal of Clinical Cases*. 2020;8(6):1104–7.
8. Tryfon S, Dramba V, Zoglopitis F, Iakovidis D, Sakkas L, Kontakiotis T, et al. Solitary papillomas of the Lower Airways: Epidemiological, clinical, and therapeutic data during a 22-year period and review of the literature. *Journal of Thoracic Oncology*. 2012;7(4):643–8.

**Figures:**

Figure 1: Chest X-Ray

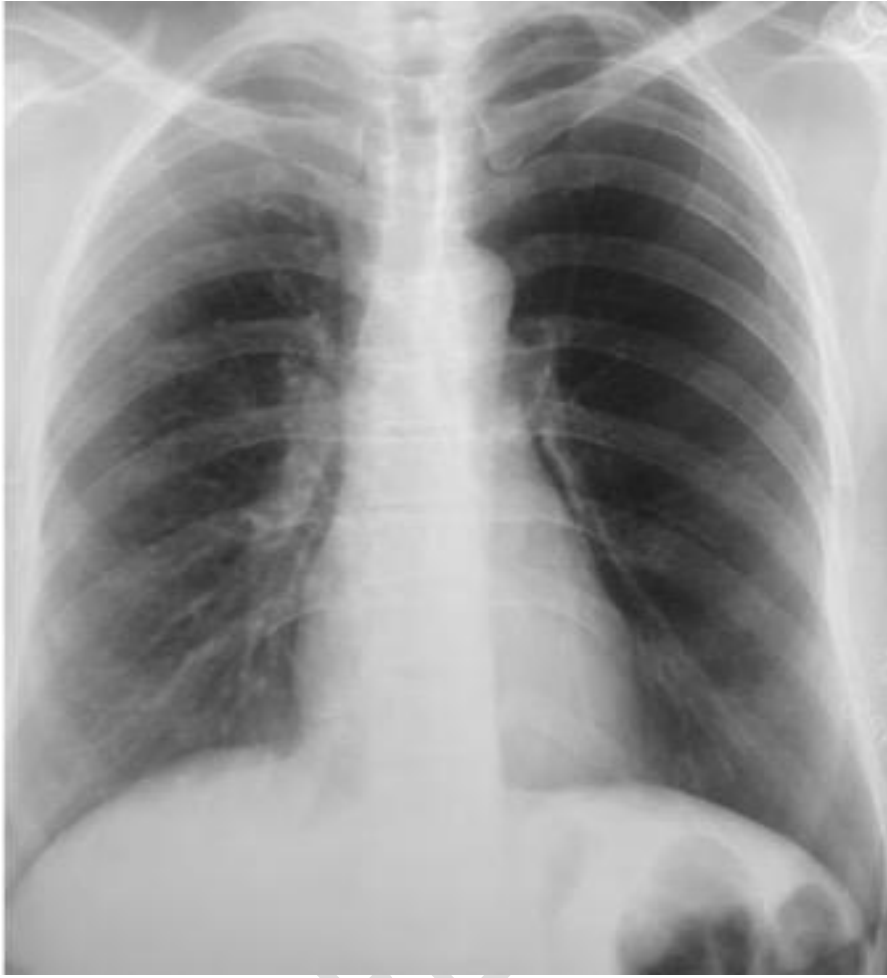
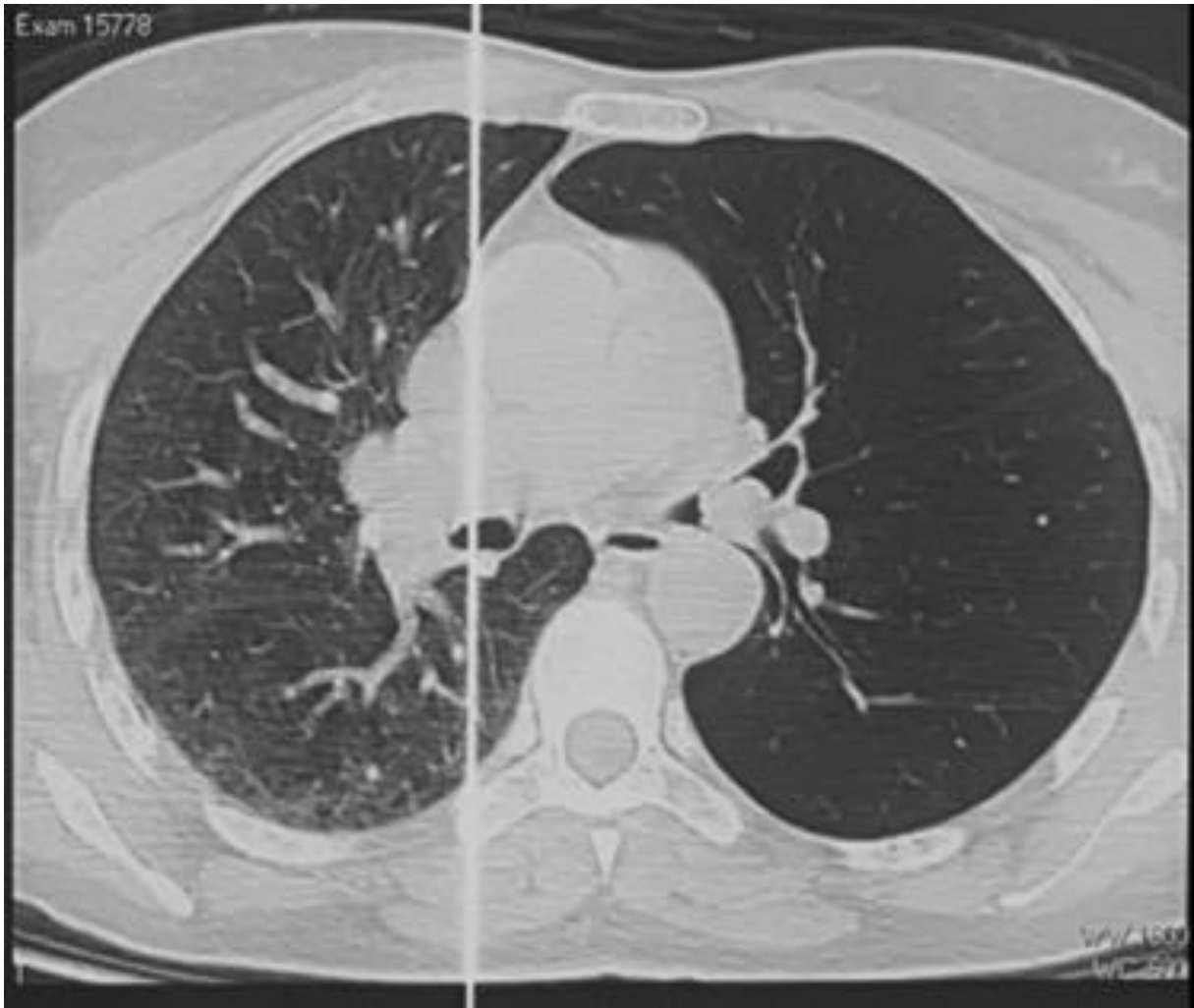
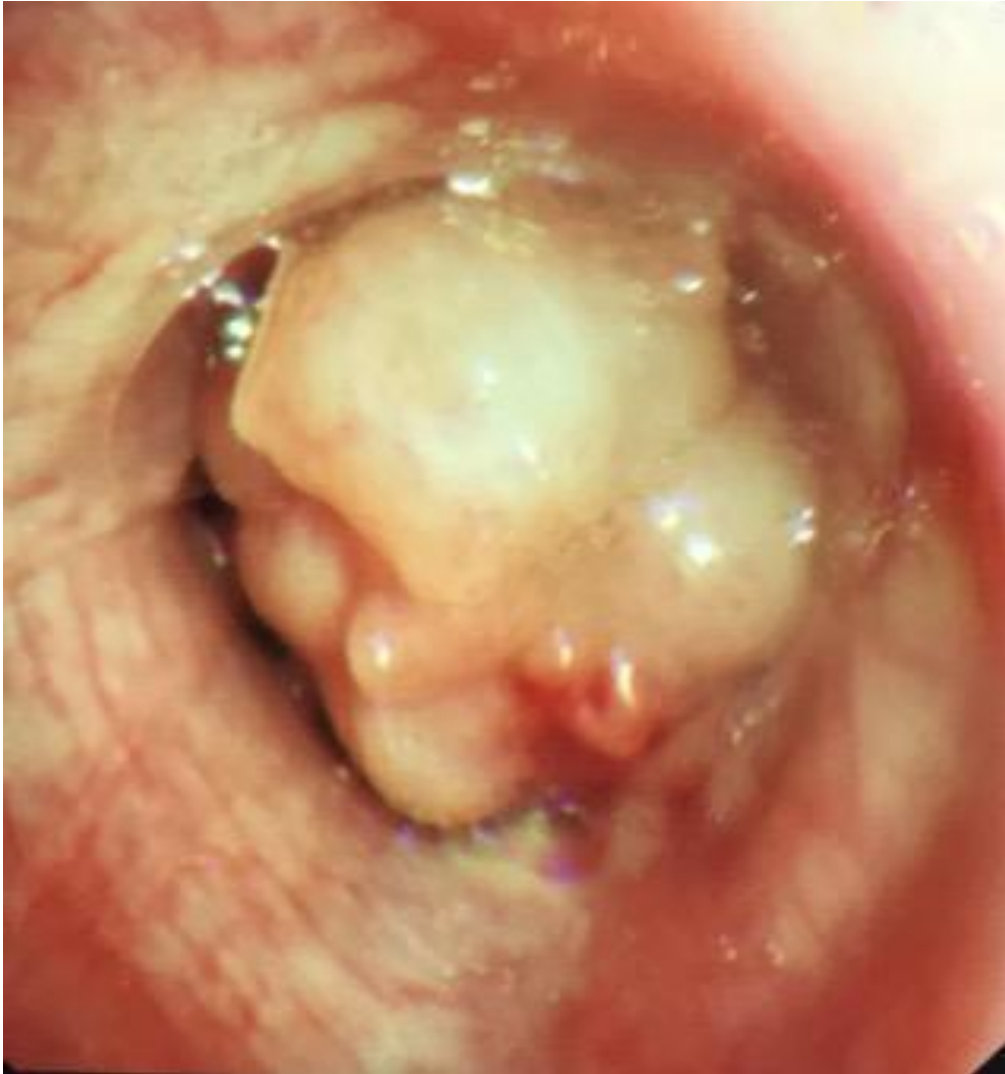Figure 2 : Chest-CT



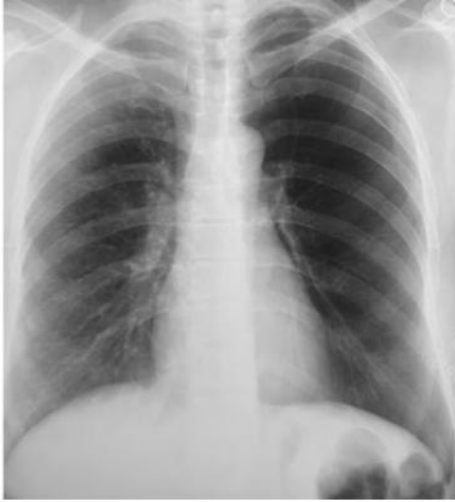UNDER REVIEW

Figure 3 : Flexible bronchoscopy

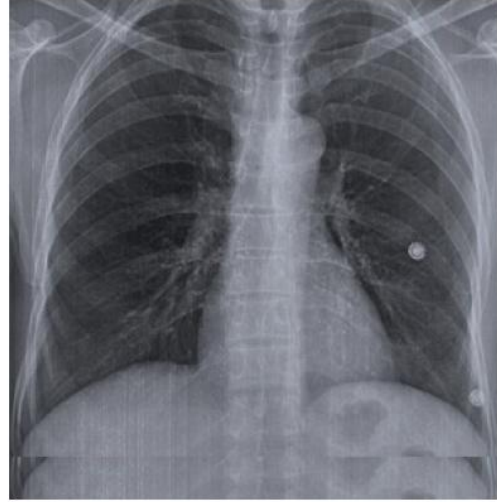


UNDER

Figure 4 : Follow-up Chest X-Ray ( before and after)



**Before**



**After**

UNDER PEER REVIEW

Figure 5: Follow-up Chest-CT ( before and after)

