

### **Original Research Article**

## CLINICO-RADIOLOGICAL STUDY OF POST TRAUMATIC PNEUMOCEPHALUS IN HEAD INJURY PATIENTS: EXPERIENCE AT A TERTIARY CENTRE WITH REVIEW OF LITERATURE

### **Abstract**

Introduction : Post traumatic Pneumocephalus, also known as intracerebral aerocele or pneumatocele, is a collection of air in the cranial cavity following a traumatic injury to head<sup>1</sup>. The term "aerocele" or "pneumocephalus," which refers to intracranial air, was first used by Chiari to describe it at an autopsy in 1884.

Comment [خوذة1]:  
Delete

Comment [خوذة2]:  
Delete

This study set out to look at the radiological and clinical features of tension pneumocephalus following traumatic brain injury.

Material and methods: The study includes 114 cases of traumatic head injury with CT findings suggestive of Pneumocephalus that presented to our centre and were treated.

Observations: This study comprises of 114 patients of pneumocephalus, male patients were the majority in our study. RTA was the most common cause of head injury. Majority patients are managed conservatively and 13 patients were treated surgically for pneumocephalus.

Conclusion: Pneumocephalus diagnosis is on rise with the advent of CT scan in head injury patients. TP, CSF leak and meningitis are life threatening complications of post traumatic pneumocephalus. Being a life-threatening neurosurgical emergency, tension pneumocephalus needs to undergo immediate surgical evacuation.

Keywords: head injury; pneumocephalus; tension pneumocephalus; csf leak;GCS; skull fracture

### **Introduction**

Post traumatic Pneumocephalus, also known as intracerebral aerocele or pneumatocele, is a collection of air in the cranial cavity following a traumatic injury

Comment [خوذة3]: The introduction is written in cursory form. It should be written in the form of an article that deals with the research topic in a comprehensive and focused way, so that it gives a full impression of what the research is interested in

Comment [خوذة4]:  
This phrase has already been used in abstract

to head[1] . The term "aerocele" or "pneumocephalus," which refers to intracranial air, was first used by Chiari to describe it at an autopsy in 1884[2].

Two theories are being proposed to describe the mechanism of pneumocephalus development:[1,4] First was Dandy theory of "ball valve" where unidirectional air movement from outside into the cranial cavity whenever the patient strain leading to entrapment of the air.

The recent one was described by Horowitz "Inverted-soda-bottle effect". It describe loss of Cerebrospinal Fluid[CSF] through a cranio-dural fistula connecting the subarachnoid space to the paranasal sinuses or mastoid air cells causing negative intracranial pressure. The negative pressure then sucks in air through the same fistula.

When post traumatic pneumocephalus causes intracranial hypertension and mass effect, it is called tension pneumocephalus[1,5]. If not diagnosed early and treated appropriately, tension pneumocephalus can be fatal

Pneumocephalus is a common complication after craniotomies. However, trauma remains the most important cause of pneumocephalus, and the prevalence of the condition following traumatic brain injuries ranges from 1% to 82%, depending on the series.[3]

This study set out to look at the radiological and clinical features of tension pneumocephalus following traumatic brain injury.

## Material and methods

This is a Hospital based prospective study **be** conducted from Nov 2020 to Oct 2022 at JNMCH, AMU, Aligarh which is a tertiary Healthcare Centre in state of Uttar Pradesh. The study **includes** 114 cases of traumatic head injury with CT findings suggestive of Pneumocephalus that presented to our centre and were treated.

All head injury patients were managed with National Guidelines for the Management of Traumatic Brain Injury. CT scan was done as and when indicated. Location of the pneumocephalus ,its distribution ,skull fracture presence or absence and features of mass effect **was** noted. Demographical details and mode of injury were noted. All **patient** with post traumatic Pneumocephalus [PTP] were managed with head and flat and high flow oxygen with mask till the resolution of the air. Prophylactics Anti epileptic **a were** used along with other supportive treatment. Patients were observed for any signs of meningitis and clinical [Glasgows coma scale ] deterioration. Empirical antibiotics [Ceftriaxone ] **was** used whenever there is CSF leak. Lumbar puncture for CSF analysis was done if not contraindicated. Surgical management of the CSF leak was undertaken when there **is** persistent leak despite aggressive medical management or leak is associated with recurrent meningitis.

Comment [خوطة 5]: was

Comment [خوطة 6]: included

Comment [خوطة 7]: were

Comment [خوطة 8]: patients

Comment [خوطة 9]: was

Comment [خوطة 10]: were

Comment [خوطة 11]: wwas

Surgical management of PTP was undertaken when there is Tension Pneumocephalus [TP] with mass effect. All the patients were followed up at 15 days, 1 month and 3 months after discharge.

Comment [خوذة 12]:  
was

## Observation and Results

This study comprises of 114 traumatic brain injury patients who had pneumocephalus that were admitted and managed at our hospital. Out of these, 88 patients in the study were male and 26 patients were female. The mean age was 29 years ranging from 7 years to 75 years of age. The number of paediatric patients [ <14 years] is 19 out of 114. Majority of the patients who have presented were in the age group of 14-30 years.

Comment [خوذة 13]:  
name of the hospital

Comment [خوذة 14]:  
was

Among various causes of the trauma, road traffic accident was the most common mode of injury among all [figure 1]

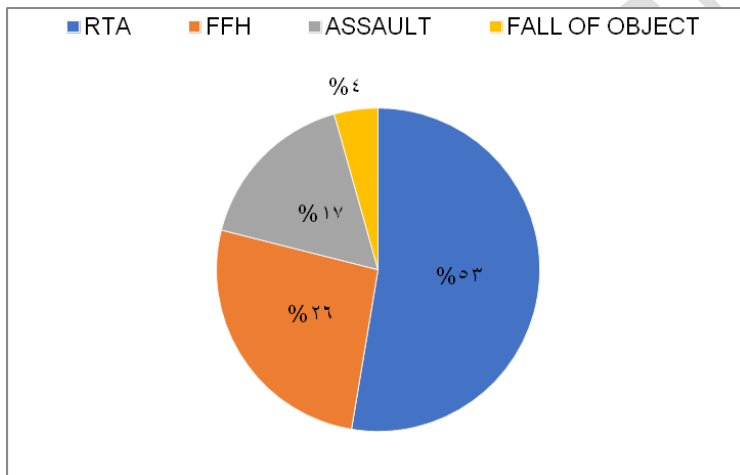


Fig 1- data of patients according to etiology of head injury

Based on the GCS [Glasgow coma Scale] scores at presentation, patients were categorised into three groups: mild Head Injury [GCS scores of 13 to 15 points], moderate Head Injury [GCS scores of 9 to 12 points], and severe Head Injury [GCS score below 8]. According to this classifications maximum patients were in mild head injury [83/114] with GCS ranging from 13 to 15, 22 patients had a GCS ranging

in the moderate head injury group while 9 patients had severe head injury based on the GCS.

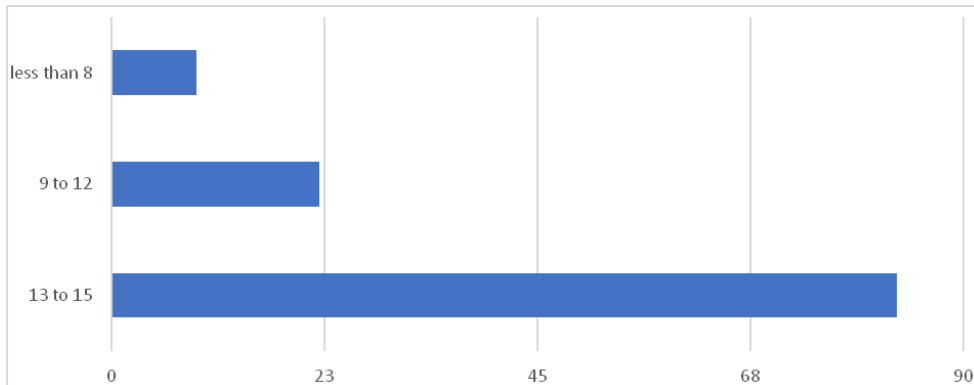


Fig 2: Division of patients according to their GCS score

Based on the pattern of pneumocephalus on CT Head, patients were divided into three groups, focal, patchy and mount fuji pattern. 70 patients had focal type of pneumocephalus on CT scan, 31 patients had patchy or air bubble type of pneumocephalus and 13 patients had the classic mount fuji pattern on CT scan [Figure 3[a], 3[b], 3[c]]

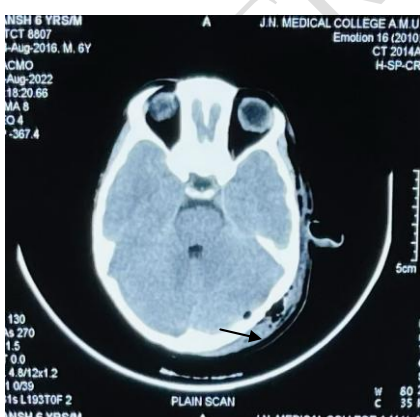

Fig 3[a]: Focal pattern

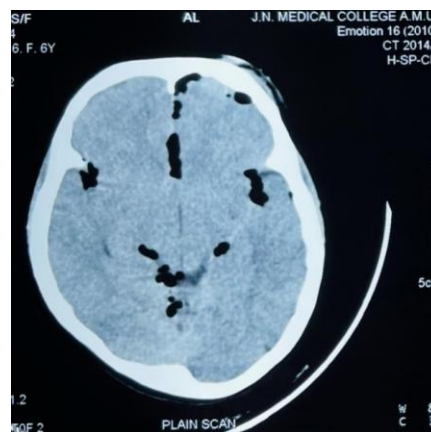


Fig 3[b]: Air bubble/

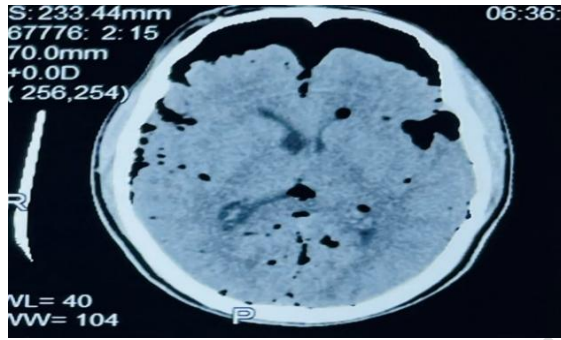


Fig 3[c]: Mount Fuji pattern

Anatomical distribution PTP is shown in Fig 4. Subdural was the most common site of post traumatic pneumocephalus.

Anatomical location	Number
Subdural	48
Extradural	22
Parenchymal	6
intraventricular	1
Extradural + Subdural	3
Subdural + subarachnoid	32
Subdural + subarachnoid+ parenchymal	2

Fig 4: showing anatomical distribution of PTP.

Fracture in the skull bone for the air to gain access to the cranial cavity is seen in all the patients with traumatic pneumocephalus. In our study, the most common skull bone to fracture is temporal bone of either side. It is followed by the frontal bone parietal bone and sphenoid sinus. 5 patients had depressed skull fracture.

Skull fracture	No. of patients
Temporal	36
Frontal	23
Sphenoid sinus	15
Parietal	14
Orbit	13
Zygomatic arch	11
Ethmoid sinus	5
Maxillary sinus	8
Nasal bone	7
Occipital	5

Table 1: showing number of skull bone fractures in patients of pneumocephalus

Among the patients with pneumocephalus, 68 patients had no associated intracranial finding except for the air in the cranial cavity, while the 63 patients with pneumocephalus also had other associated intracranial finding in the form of hemorrhagic contusion, acute epidural hemorrhage [AEDH], acute subdural hemorrhage [ASDH], and sub arachnoid hemorrhage [ASAH]. AEDH was the most common intracranial injury that was associated with pneumocephalus in head injury patients [26 out of 114]. It was followed by hemorrhagic contusion, ASDH and ASAH.

Associated intracranial injury	Number of patients
--------------------------------	--------------------

None	68
Hemorrhagic contusion	20
AEDH	26
ASDH	12
ASAH	5

Table 2 showing associated cranial injuries in patient with pneumocephalus

In this study, majority patient did not have features of CSF leak, only 39 patients out of 114 had a history of CSF leak including rhinorrhea and otorrhea. 27 patients had rhinorrhea, 12 patients had history of otorrhea. History of seizure was present in 5 patients, out of which 3 patients developed seizure prior to reaching the hospital while 2 patients developed seizure during the course of their hospitalisation.

Complications	Number of patients
Seizure	5
Otorrhea	12
Rhinorrhea	27
Cranial nerve injury	
Optic nerve	1
Olfactory	6
Facial nerve	2
Meningitis	2

Table 3: Table showing the incidence of various complications of pneumocephalus.

The other most important complication of pneumocephalus is meningitis. Prophylactic antibiotic was given to all the patients with pneumocephalus to prevent the development of meningitis. In our study 2 patients developed meningitis post TBI.

Out of 114 patients with pneumocephalus, 13 patients were managed surgically, but their reason for surgery in 8 out of 10 was the extra-axial bleed or persistent CSF leak or depressed skull fracture and not pneumocephalus per se. Two patients were treated surgically for symptoms due to tension pneumocephalus. In both the patients, subdural drain connected to underwater seal resulted in decompression and resolution of tension pneumocephalus. a CSF leak which does not last for more than 4 to 5 days and usually resolves spontaneously. But patients with persistent leak often require surgical intervention in the form of Dural repair. In our study we found 3 such patients with rhinorrhea persisting for more than 1 week. Broad spectrum antibiotic was continued for prophylaxis against meningitis. Craniotomy with primary closure of the dura or with patch closure was done. 2 out of 3 patients responded well and were successfully discharged under stable condition with no neurological deficit

3 patients underwent Craniotomy with evacuation of clots while the other 3 patients underwent dural repair for persistent rhinorrhea. 5 patients were managed surgically due to presence of depressed skull fracture along with pneumocephalus.

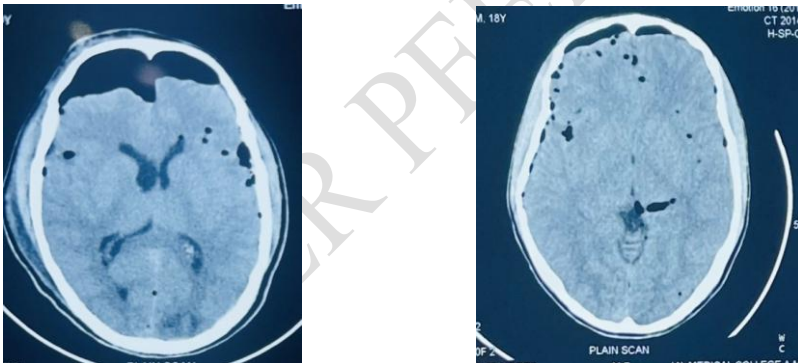


Fig 5(a, b): CT scan of a patient showing mount fuji sign

Case 1 : CT scan of a patient showing mount fuji sign. The second pic shows successive scan done at 7<sup>th</sup> day of admission showing resolution of mount fuji sign.

Patient was successfully managed conservatively with oxygen and antiepileptic. Patient also had early CSF rhinorrhea which resolved on 6<sup>th</sup> day of admission.

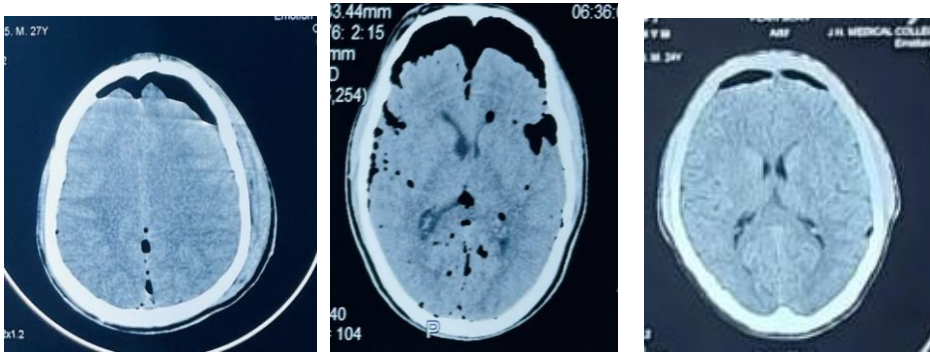


Fig 6(a,b,c): Scan showing patient with traumatic head injury

Case 2 : A patient with traumatic head injury who was diagnosed with pneumocephalus based on CT scan at admission. GCS of the patient started falling on day 3 of admission, CT scan showing mount fuji sign suggestive of Tension pneumocephalus. Patient was then operated, controlled decompression by a subdural drain which was connected to underwater seal was done. Patient improved and was discharged in stable condition on day 17 of admission. Picture 3 is the scan done at day 15 after discharge showing resolution of most of pneumocephalus. Patient also developed delayed rhinorrhea which subsided conservatively.

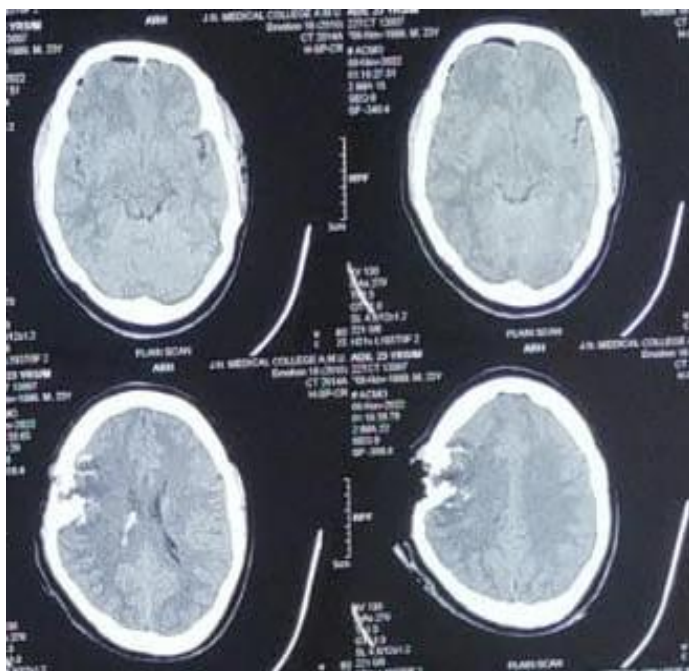


Fig 7. A 25 years old patient with history of RTA, NCCT head suggestive of a depressed skull fracture

Case 3: A 25 years old patient with history of RTA, NCCT head suggestive of a depressed skull fracture along with pneumocephalus at the frontal lobe. Patient was operated for depressed fracture, exploration of wound followed by elevation of depressed bone, removal of bone fragments and dural repair with patch was done.

Four patients expired during the course of their treatment. 2 out of 3 patients also had associated injuries in the form of blunt trauma to chest, blunt trauma to abdomen and long bone injuries. Mortality in one patient was associated with development of meningitis post dural repair of persistent CSF leak. One patient had ICU related complication and could not be salvaged.

In the follow up majority patients were free of any morbidity and had good outcome. Patients were evaluated on basis of their Glasgow outcome score on follow up, majority patients had full recovery and returned to normal functioning in their life with a score of 5 at 15 days after discharge, while 4 patients had a GOS of 1, and none of the patient had GOS of 2. At the end of 1st month, 10 patients had GOS of 4 i.e. minor neurological deficit that do not hamper their daily life. These were the patients who developed delayed complication of pneumocephalus in the form of cranial nerve injury or CSF leak. 18 patients were lost to follow up.

Features	15 days	1 month	6 month
Pneumocephalus			
Increased	-	-	-
Decreased/ resolved	72	78	78
Rhinorrhea	2	4	-
Otorrhea	1	-	-
Cranial nerve injury			
Optic nerve	1	-	-
Olfactory nerve	6	5	2
Facial nerve	2	1	-
Meningitis	-	-	-

Table 4: Data of the patients at various stages of follow up.

## DISCUSSION

In this study we aimed at elaborating the clinical and radiological outcome of patients who were diagnosed with pneumocephalus post traumatic head injury and were managed at our centre.

In a study conducted by Avinash Sharma et al[13] in 2018 70% patients with pneumocephalus had a GCS score of more than 13. In our study also, 83 patients with pneumocephalus were of mild head injury group based on their GCS score at

presentation, while 22 patients had GCS of moderate head injury group while 9 patients were classified as severe based on their GCS at admission.

In our study maximum patients had a single air bubble [focal] type of pneumocephalus while 13 patients had mount fuji appearance on their CT scan. 31 patients had multiple air bubble type of pneumocephalus in our study. It was also found that presence of mount fuji appearance on CT scan does not amount to tension pneumocephalus. In fact 1 patient with tension pneumocephalus in our study had a multiple air bubble type of pneumocephalus, the patient was managed surgically with help of subdural drain insertion connected to underwater seal.

Temporal bone was the most common bone to fracture in our study followed by frontal, sphenoid sinus and others. In a study by Ki Seong Eom[4] at Department of Neurosurgery at Iksan, Korea. Temporal fracture was found in 32% cases and was the most common bone to fracture, it was followed by frontal, parietal ad others. Although pneumocephalus can develop in the absence of fracture, however this phenomenon is rare and mechanism remains unknown.

Clemens M. Schirmer et al[6] reported that the incidence of CSF leak in patients of pneumocephalus is around 30% and a 10 yr cumulative incidence can be as high as 85%. In our study, 27 patients developed CSF rhinorrhea while 12 patients had a history of CSF otorrhea following traumatic brain injury. This includes both early and delayed cases. We also reported other complications of pneumocephalus including meningitis, seizure and cranial nerve injury. However rhinorrhea is the most common complication of pneumocephalus, which if remain persistent for more than a week may require surgical repair of dura using a patch. CSF leak can also give rise to meningitis which require prophylactic antibiotic for its prevention. However using prophylactic broad spectrum antibiotic in all patients of head injury is still controversial. With many studies advocating against the use of antibiotic in all patients. In our study broad spectrum antibiotics was given to all patients of pneumocephalus, 2 patients of pneumocephalus developed meningitis, with one developing post surgical repair of dura.

According to Eftekhari et al[9] in a study conducted in 2004 the incidence of meningitis was 21.5 %. The study rejected the use of antibiotic in all patients with head injury, stating that broad spectrum antibiotic might be required in patients with CSF leak and extensive open injury with high chances of developing meningitis. However prophylactic antibiotics like ceftriaxone has also proven to be ineffective in preventing meningitis in patients with CSF leak. Sharma et al also concluded that the use of antibiotic in preventing meningitis is under debate. However we conclude that prophylactic antibiotic be given to patients with high risk of developing meningitis.

The first surgical repair of traumatic CSF leak was done by Dandy[2] in 1926 through frontal craniotomy. This approach remained the mainstay of treatment for decade still 1980 when Dohlman, Calcaterra and others reported extracranial nasal endoscopic repair of cranio-dural defect. However Locatelli et al. advocated the key for endoscopic transnasal surgical repair of leak is accurate preoperative localization of fistula, adequate operative field and clear demarcation of size and anatomical location of the defect[64]. So endoscopic approaches are limited for specific indications. In our study, 3 patients were operated for CSF leak that persisted for more than 1 week. One of the patient developed meningitis post dural repair. 2 patients were successfully treated and discharged without any recurrence of symptoms. 2 patients were operated because of the depressed skull fracture due to the trauma, exploration of wound, elevation of depressed segment and removal of bone fragment along with dural repair with G patch was done.

3 patients with pneumocephalus were also operated, but for associated intracranial injury. All the three patients had AEDH along with pneumocephalus on their CT scan. All patients were successfully treated and were discharged in stable condition. Majority of pneumocephalus patients have their GCS ranging in mild head injury score and hence can be managed conservatively. Even those patient who have mount fuji sign on their CT scan were also managed non-operatively and were discharged successfully. 2 patients who had tension pneumocephalus had to be operated and a subdural drain connected to underwater seal system was inserted. Patient improved post operatively and returned home in stable condition. Until recently majority patients who had mount fuji sign were considered to be tension pneumocephalus and were operated for the same. But recent studies have shown change in the trend with patients having mount fuji sign were also managed conservatively. In addition, Ishiwata et al have found no substantial difference between the volume of air in tension pneumocephalus and that in non-tension post traumatic pneumocephalus.

## CONCLUSION

The epidemiological, clinical and radiological characteristics of post traumatic pneumocephalus was discussed by the authors. With emergent CT scan done in all cases of head injury, the incidence of pneumocephalus is on rise. With prompt diagnosis and management majority patients only require observation and minimal care in the form of oxygen, antibiotic and anti convulsant and monitoring of any symptoms of raised Intracranial pressure.

TP, CSF leak and meningitis are life threatening complications of post traumatic pneumocephalus. Early recognition and high index of clinical suspicion and prompt treatment results in improvement of vast majority of patients.

Antibiotic prophylaxis to be given in all patients with pneumocephalus and CSF leak in order to prevent the development of meningitis.

Being a life-threatening neurosurgical emergency, tension pneumocephalus needs to undergo immediate surgical evacuation.

## REFERENCES

1. M Das J, Bajaj J. Pneumocephalus. [Updated 2022 Sep 24]. In: StatPearls [Internet]. Treasure Island [FL]: StatPearls Publishing; 2022 Jan-. Available from: <https://www.ncbi.nlm.nih.gov/books/NBK535412/>
2. Dandy, W.E, Pneumocephalus[ intracranial pneumomatocele or arocele]. Arch Surg.12[1926], 949-982
3. Weerakkody, Y., El-Feky, M. Pneumocephalus. Reference article, Radiopaedia.org. <https://doi.org/10.53347/rID-9879>
4. Eom KS [2020]. Clinical and radiological characteristics of traumatic pneumocephalus after traumatic brain injury. Korean J Neurotrauma 16, 49-59.
5. Pillai P, Sharma R, MacKenzie L,[2017]. Traumatic tension pneumocephalus– Two cases and comprehensive review of literature. International Journal of Critical Illness & Injury Science 7, 58-64.
6. Schirmer CM, Heilman CB, Bhardwaj A. Pneumocephalus: case illustrations and review. Neurocrit Care. 2010 Aug;13[1]:152-8. - PubMed
7. Dexter F, Reasoner DK. Theoretical assessment of normobaric oxygen therapy to treat pneumocephalus. Anesthesiology. 1996 Feb;84[2]:442-7
8. Chiari H. A case of accumulation of air in the ventricles of human brain. Zschr F Heilk. 1884;5:383–390. [Google Scholar]
9. Eftekhari B, Ghodsi M, Hadadi A, Taghipoor M, Sigarchi SZ, Rahimi-Movaghar V, et al. Prophylactic antibiotic for prevention of posttraumatic meningitis after traumatic pneumocephalus: design and rationale of a placebo-controlled randomized multicenter trial [ISRCTN71132784] Trials. 2006;7:2. [PMCFreearticle] [PubMed] [Google Scholar]
10. Ishiwata Y, Fujitsu K, Sekino T, Fujino H, Kubokura T, Tsubone K, et al. Subdural tension pneumocephalus following surgery for chronic subdural hematoma. J Neurosurg. 1988;68:58–61. [PubMed] [Google Scholar]
11. Dr C.V.Rajendran, Dr Nowshad.M et al Post Traumatic Pneumocephalus- Clinical Profile in a Tertiary Care Centre JMSCR vol 5 issue 7 DOI: <https://dx.doi.org/10.18535/jmscr/v5i7.58>
12. Luckett WH. Air in the ventricles of the brain, following a fracture of the skull: report of a case. Surg GynecolObstet. 1913;17:237–240. [Google Scholar]

13.Sharma A, Sharma A, Sengar R, Iyengar SN. Post traumatic pneumocephalus: a tertiary institute experience. Glob J Res Anal. 2018;7:401–402. [Google Scholar]

UNDER PEER REVIEW