

# Anesthetic Management with Remimazolam in a Patient with Arrhythmogenic Right Ventricular Cardiomyopathy with a History of Stable Sustained Ventricular Tachycardia: A Case Report

## ABSTRACT

**Aims:** Arrhythmogenic right ventricular cardiomyopathy (ARVC) may cause sudden and unexpected deaths during the perioperative period. This study reports a case of ARVC, safely managed using total intravenous anesthesia with remimazolam.

**Presentation of Case:** A 51-year-old male patient (weight: 100.1 kg, height: 171.0 cm) with a history of ARVC underwent open cholecystectomy. The patient underwent total intravenous anesthesia with remimazolam, remifentanyl, and a modified thoracoabdominal nerves block perichondrial approach for postoperative analgesia. Hemodynamic stability was maintained throughout the surgery. Catecholamine use was not warranted during the perioperative period. No episodes of stable sustained ventricular tachycardia or other cardiovascular episodes were observed.

**Discussion and Conclusion:** ARVC is a genetically-determined heart muscle disease characterized by life-threatening ventricular arrhythmias in apparently healthy young people. Anesthesiologists should pay close attention to the anesthetic management of patients with ARVC. Remimazolam can be safely used in such cases.

**Keywords:** arrhythmogenic right ventricular cardiomyopathy, ventricular tachycardia, perioperative sudden cardiac death, electrocardiogram,  $\beta$ -blockers

## 1. INTRODUCTION

Arrhythmogenic right ventricular cardiomyopathy (ARVC) is a rare but serious cardiovascular disease that can lead to heart failure, potentially fatal ventricular arrhythmias, and perioperative sudden cardiac death (PSCD) [1,2]. ARVC is an inherited heart disease with a prevalence of approximately 1:5,000 [3,4]. The average age of onset of ARVC is 30–40 years, and the disease is characterized by life-threatening ventricular arrhythmias in healthy young people [3,4]. The main goals of anesthesia in patients with ARVC are to maintain hemodynamic stability, minimize stress, and avoid tachycardia, hypertension, and hypotension [5]. Ventricular arrhythmias are exacerbated by  $\beta$ -adrenergic stimulation, whereas  $\alpha$ -agonists are less likely to be arrhythmogenic [5]. PSCD can occur at any time during the perioperative period; therefore, sympathetic stimulation should be minimized by providing adequate analgesia [5]. Herein, we report a case of ARVC managed without ventricular arrhythmias using remimazolam.

## 2. PRESENTATION OF A CASE

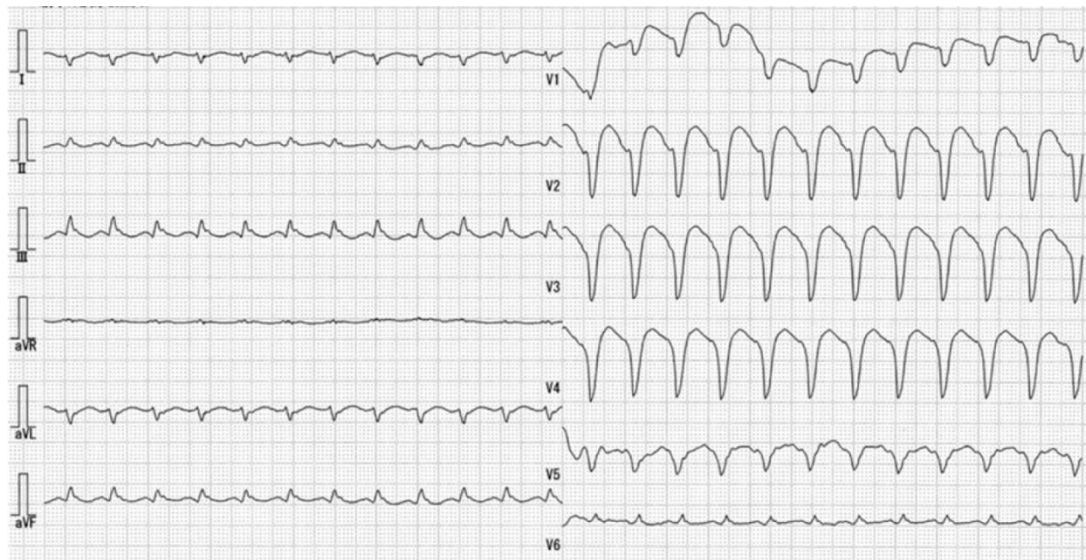
Written informed consent was obtained from the patient for the publication of this case report and accompanying images. Ethical approval for this study (Nagasaki Rosai No.05001, 2023/04/14) was provided by the Nagasaki Rosai Hospital Institutional Review Board, Sasebo, Japan.

A 51-year-old male patient (weight: 100.1 kg, height: 171.0 cm) with a history of ARVC was scheduled for open cholecystectomy.

The patient was presented to the emergency department with palpitations approximately 2 years before surgery. He had frequent episodes of ventricular tachycardia (VT). Electrocardiogram (ECG) showed stable sustained VT with positive QRS in II, III, and augmented vector foot and negative QRS in lead augmented vector left (Fig. 1). He was awake and

37  
38  
39  
40  
41  
42

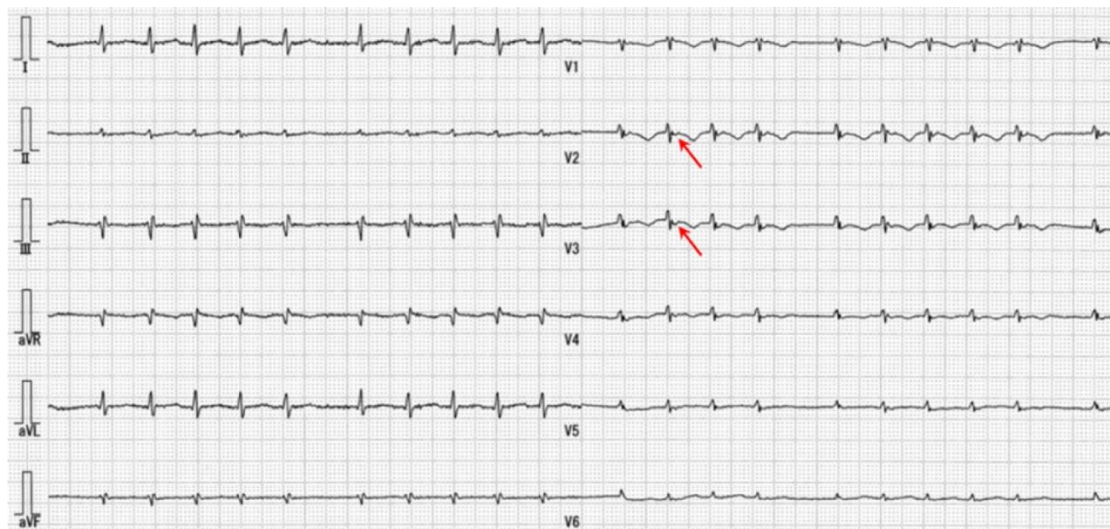
alert, and his vital signs were unremarkable. This finding is consistent with a left bundle branch block in the inferior axis, as described in the 2010 ARVC Task Force Criteria (Table 1), [6,7] which requires the presence of epsilon waves (red arrow) at V2 and V3, and inverted T waves at V1, V2, and V3 (Fig. 2). Echocardiography showed a right ventricular fractional area change of 22.43% (Fig. 3). The patient's family history of ARVC was unknown. The patient met the 2010 ARVC Task Force Criteria because three major criteria were met [6,7].



43  
44  
45  
46  
47  
48  
49  
50  
51

**Fig. 1. Stable sustained ventricular tachycardia in the emergency department**

The patient was presented to the emergency department with palpitations. An electrocardiogram (ECG) showed positive QRS complexes in leads II, III, and aVF and negative QRS complexes in lead aVL. These ECG findings are consistent with a left bundle branch block in the inferior axis, as described in the 2010 ARVC Task Force Criteria. aVF, augmented vector foot; aVL, augmented vector left



52  
53  
54  
55  
56  
57  
58

**Fig. 2. Preoperative ECG**

Epsilon waves (red arrows) are seen in leads V2 and V3 and inverted T waves in leads V1, V2, and V3. ECG, electrocardiogram

**Table 1. 2010 Revised Task Force Criteria for the diagnosis of arrhythmogenic right ventricular cardiomyopathy**  
[6,7]

---

**Modified Task Force Criteria for ARVC – Diagnostic Categories Major and Minor Criteria**

---

Definite: two major or one major and two minor or four minor criteria from different categories

---

Borderline: one major and one minor or three minor criteria from different categories

Possible: one major or two minor criteria from different categories

	Major	Minor
Global or regional dysfunction and structural alterations determined using echo, MRI, or RV angiography		
Echo	Regional RV akinesia, dyskinesia, or aneurysm and one of the following (end diastole): a) PLAX RVOT $\geq 32$ mm (PLAX/BSA $\geq 19$ mm/m <sup>2</sup> ) b) PSAX RVOT $\geq 36$ mm (PSAX/BSA $\geq 21$ mm/m <sup>2</sup> ) c) Fractional area change $\leq 33\%$	Regional RV akinesia, dyskinesia, or aneurysm and one of the following (end diastole): a) PLAX RVOT $\geq 29$ mm to $< 32$ mm (PLAX/BSA $\geq 16$ to $< 19$ mm/m <sup>2</sup> ) b) PSAX RVOT $\geq 32$ to $< 36$ mm (PSAX/BSA $\geq 18$ to $< 21$ mm/m <sup>2</sup> ) c) Fractional area change $> 33$ to $\leq 40\%$
MRI	Regional RV akinesia, dyskinesia, or dyssynchronous RV contraction and one of the following a) Ratio RVEDV/BSA $\geq 110$ mL/m <sup>2</sup> (male), $\geq 100$ mL/m <sup>2</sup> (female) b) RVEF $\leq 40\%$	Regional RV akinesia, dyskinesia, or dyssynchronous RV contraction and one of the following: a) Ratio RVEDV/BSA $\geq 100$ to $< 110$ mL/m <sup>2</sup> (male), $\geq 90$ to $100$ mL/m <sup>2</sup> (female) b) RVEF $> 40$ to $\leq 45\%$
RV angiography	Regional RV akinesia, dyskinesia, or aneurysm	
Tissue characterization of the wall		
Endomyocardial biopsy showing fibrous replacement of the RV free wall myocardium in more than one sample, with or without fatty replacement and with	Residual myocytes $< 60\%$ by morphometric analysis (or $< 50\%$ if estimated)	Residual myocytes $60\%$ to $75\%$ by morphometric analysis (or $50\%$ to $65\%$ if estimated)
Repolarization abnormalities		
ECG	Inverted T waves in the right precordial leads (V1–3) or beyond in individuals aged $> 14$ years (in the absence of complete RBBB QRS $\geq 120$ ms)	I. Inverted T waves in leads V1–2 in individuals aged $> 14$ years (in the absence of complete RBBB) or in V4–6 II. Inverted T waves in leads V1–4 in individuals aged $> 14$ years in the presence of complete

RBBB	
Depolarization/conduction abnormalities	
ECG	<p>Epsilon wave (reproducible low-amplitude signals between the end of the QRS complex to the onset of the T wave) in the right precordial leads (V1–3)</p> <p>I. Late potentials using SAEKG in more than one of three parameters in the absence of QRS duration <math>\geq 110</math> ms on the standard ECG:</p> <p>a) Filtered QRS duration (fQRS) <math>\geq 114</math> ms</p> <p>b) Duration of terminal QRS <math>&lt; 40</math> <math>\mu</math>V (low-amplitude signal duration) <math>\geq 38</math> ms</p> <p>c) Root-mean-square voltage of terminal 40 ms <math>\leq 20</math> <math>\mu</math>V</p> <p>II. Terminal activation duration of QRS <math>\geq 55</math> ms measured from the nadir of the S wave to the end of the QRS, including R' in V1–3 in the absence of complete RBBB</p>
Arrhythmias	
	<p>Nonsustained or sustained VT of LBBB with superior axis (negative or indeterminate QRS in leads II, III, aVF and positive in lead aVL)</p> <p>I. Nonsustained or sustained VT or RV outflow configuration, LBBB morphology with inferior axis (positive QRS complexes in leads II, III, aVF and negative in lead aVL) or of unknown axis</p> <p>II. <math>&gt; 500</math> ventricular extrasystoles per 24 h (Holter)</p>
Family history	
	<p>I. ARVC confirmed in a first-degree relative who meets the current Task Force Criteria</p> <p>II. ARVC confirmed pathologically at autopsy or surgery in a first-degree relative</p> <p>III. Identification of a pathogenetic mutation categorized as associated or probably associated with ARVC in the patient under evaluation</p> <p>I. History of ARVC in a first-degree relative in whom it is not possible or practical to determine whether the family member meets the current Task Force Criteria</p> <p>II. Premature sudden death (aged <math>&lt; 35</math> years) due to suspected ARVC in a first-degree relative</p> <p>III. ARVC confirmed pathologically or by the current Task Force Criteria in a second-degree relative</p>

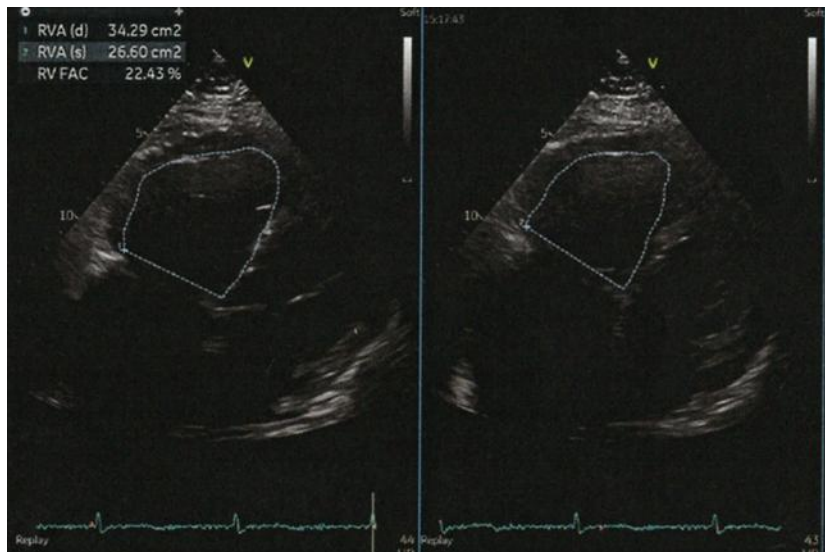
59 BSA: body surface area; ECG: electrocardiogram; echo: echocardiogram; MRI: magnetic resonance imaging;

60 PLAX: parasternal long-axis; PSAX: parasternal short-axis; RBBB: right bundle branch block;

61 RV: right ventricular; RVEDV: right ventricular end-diastolic volume; RVEF: right ventricular ejection fraction;

62 RVOT: right ventricular out flow tract; SAECCG: signal-averaged electrocardiogram;

63 VT: ventricular tachycardia; aVF, aVF, augmented vector foot; aVL, augmented vector left



67  
68 **Fig. 3. Right ventricular fractional area change of 22.43% is seen on echocardiography**

69  
70 When the patient presented to the emergency department with a stable sustained VT, procainamide was administered.  
71 Afterward, amiodarone was administered due to the persistence of the stable sustained VT. Cardioversion was required  
72 due to the failure of medical therapy to manage his VT. He was then started on oral amiodarone and has not had VT  
73 since.

74  
75 Approximately 2 years later, he was scheduled for elective open cholecystectomy. When he was admitted to the surgical  
76 ward, his ARVC was well-controlled. Total intravenous anesthesia, mainly remimazolam, was planned because of its  
77 limited hemodynamic effect. In addition to the usual ECG and oxygen saturation, monitoring was performed with an  
78 invasive intra-arterial pressure monitor and central venous catheter, and a defibrillation pad was applied to allow  
79 synchronized cardioversion/defibrillation as needed. In patients with ARVC, transesophageal echocardiography (TEE)  
80 should also be considered for monitoring during major and prolonged surgical procedures with significant blood loss [5,8].  
81 TEE may also provide additional diagnostic information for patients with intraoperative cardiac arrest and may directly  
82 guide specific, potentially life-saving therapies [4]. The patient had stable ARVC and was unlikely to have major bleeding;  
83 therefore, TEE was only prepared for use at any time. We planned to administer phenylephrine and noradrenaline for  
84 hypotension and atropine for bradycardia.  $\beta$ -stimulants are not recommended in the presence of hypotension or  
85 bradycardia because  $\beta$ -stimulation is the most common cause of stable sustained VT [2,5,8]. General anesthesia was  
86 induced with remimazolam (12 mg/kg/h) and fentanyl (500  $\mu$ g), and tracheal intubation was performed after the  
87 administration of rocuronium (1.0 mg/kg). The use of remimazolam helped maintain hemodynamic stability during  
88 anesthesia induction. Following intubation, anesthesia was maintained with remimazolam (0.5–1.0 mg/kg/h), remifentanyl  
89 (0.1–0.2  $\mu$ g/kg/min), rocuronium (7.0  $\mu$ g/kg/min), and oxygen-in-air gas mixture. The bispectral index (BIS) was used to  
90 titrate the remimazolam dose, maintained at 40–60 throughout anesthesia.

91  
92 After induction of general anesthesia, the modified thoracoabdominal nerves block perichondrial approach (m-TAPA) was  
93 performed as part of the multimodal analgesia protocol. Levobupivacaine (60 mL, 0.25%) was then administered.  
94 Acetaminophen 1,000 mg and fentanyl 150  $\mu$ g were intravenously administered during skin closure. A total of 750  $\mu$ g of  
95 fentanyl was administered. Hemodynamic stability was maintained intraoperatively, and catecholamine use was not  
96 warranted. The operative time was 154 min, and the anesthesia time was 265 min. There was no intraoperative  
97 hypotension, uncompensated blood loss, hypercarbia, hypoxia, or acidosis, which can induce cardiac arrhythmias with  
98 anesthetic management, and no VT or other arrhythmias. Muscle relaxation was antagonized by sugammadex, and  
99 remimazolam was antagonized by flumazenil. The patient was extubated in the operating room as he was fully awake,  
100 had adequate spontaneous respiration, and vital signs were stable. Remimazolam was used under BIS monitoring  
101 between 40 and 60 until before extubation; therefore, there was no intraoperative awareness. After the surgery, the  
102 patient did not complain of intraoperative awareness. The patient's numerical rating score (NRS) was 0/10 during the first  
103 12 h of follow-up. No analgesic medication was administered within 48 h. "Little pain" was recorded in the clinical record at  
104 24 h and "no pain" at 48 h. No episodes of stable sustained VT or other cardiovascular episodes were observed during

105 the perioperative period. No serious adverse events, such as allergic reactions, local anesthetic systemic toxicity,  
106 pneumothorax, or uncontrollable persistent hypotension, were observed.

### 107 3. DISCUSSION

109 Sufficient anesthetic management during an open cholecystectomy of a patient with ARVC, with a history of recurrent  
110 stable sustained VT, was achieved. The patient received total intravenous anesthesia with remimazolam, fentanyl,  
111 remifentanyl, and m-TAPA for postoperative analgesia. Although relatively rare, ARVC may cause sudden, unexpected  
112 deaths during the perioperative period [4]. When a  $\beta$ -stimulator is used, ARVC can increase the risk of arrhythmias, such  
113 as stable sustained VT [2,5]. Therefore, it is important to maintain hemodynamic stability to avoid the need for  $\beta$ -  
114 stimulants to prevent fatal arrhythmias during the perioperative period in patients with ARVC [5].

115 We considered which general anesthesia would be the preferred choice.

116 Thiopental has been shown to promote adrenaline-induced arrhythmias; therefore, general anesthesia with propofol or  
117 benzodiazepines is preferred [2,4,8]. In another report comparing remimazolam and propofol use in cardiac surgery,  
118 adrenaline, cortisol, and blood glucose levels measured 2 h after surgery were significantly lower in the remimazolam  
119 group [9]. Therefore, remimazolam reduces surgical hemodynamic changes and the surgical stress response. In addition,  
120 remimazolam is less likely to cause hypotension and requires less use of  $\beta$ -stimulators. Therefore, remimazolam may be  
121 the best choice for the anesthetic management of ARVC.

122 Remimazolam is a benzodiazepine agonist created as an ultra-short-acting anesthetic with a high affinity for the  
123 benzodiazepine-binding site of the  $\gamma$ -aminobutyric acid receptor and is metabolized by esterases. Remimazolam has a  
124 context-sensitive half-time of 6–7 min during its administration for various durations, and the elimination half-time of  
125 remimazolam is approximately 48 min [10,11]. Only angle-closure glaucoma is contraindicated.

126 Remimazolam can maintain hemodynamic stability, eliminating the need for catecholamines, but it has no effect on the  $\beta$   
127 receptors themselves. As for catecholamines,  $\alpha$ -adrenergic agonists, such as phenylephrine or noradrenaline, are  
128 preferred over  $\beta$ -adrenergic stimulators in patients with ARVC [2,5,8]. However, catecholamine use was not needed for  
129 this patient. In this case, atropine was administered for bradycardia. Remifentanyl, fentanyl, and rocuronium were  
130 administered safely [4,8]. Oh et al. reported that remimazolam at 0.35 mg/kg could induce loss of consciousness and did  
131 not cause significant hemodynamic depression [12]. Therefore, remimazolam alone may be sufficient to induce  
132 anesthesia without the use of remifentanyl when hypotension should be avoided.

133 On the other hand, postoperative pain is associated with increased levels of endogenous catecholamines, which can lead  
134 to severe arrhythmia [2,5]. M-TAPA was used as postoperative analgesia. With the use of 60 mL of 0.25%  
135 levobupivacaine, the pain was NRS 0–1 12 h after surgery; thus, there was no need for additional analgesics.

136  $\beta$ -blockers not only prevent ventricular arrhythmias but are also thought to be beneficial in the management of patients  
137 with heart failure [13–15]. If a patient is being actively treated with  $\beta$ -blockers for ARVC, they should continue to undergo  
138  $\beta$ -blockers perioperatively and should be administered their usual dose the morning of the surgery [4].  $\beta$ -blocker such as  
139 landiolol or esomolol should be available for suppression of VT, if they occur [8].

140 Prior to elective surgery, patients should be clinically optimized with pharmacologic or invasive treatment [8], and the  
141 surgery should be postponed until the arrhythmia and symptoms are controlled [4,5]. Emergency surgery should be  
142 avoided in situations where ARVC is unstable. In this case, surgery was performed approximately 2 years after the onset  
143 of VT. During this time, no VT occurred, and the ARVC was well-controlled.

144 Though ARVC appears to be a major cause of sudden and unexpected perioperative death, to the best of our knowledge,  
145 there are no published reports on the incidence of ARVC during the perioperative period [4]. A French autopsy report  
146 found ARVC in 18 (36%) of 50 sudden perioperative deaths [16]. No preoperative cardiac, intraoperative anesthetic, or  
147 surgical complications were observed in the 18 ARVC cases. This autopsy report has some limitations. The percentage of  
148 cases in the actual number of anesthesia management cases was not shown, preoperative ECGs were not presented,  
149 family history was not described, and there were regional and racial differences in the prevalence of ARVC.  
150 Anesthesiologists should pay special attention to ARVC because of the high risk of VT and sudden death during the  
151 perioperative period despite the above-mentioned limitations.

152 Among the diagnostic criteria for ARVC, the most frequently described ECG finding are T wave inversions in V1–3  
153 [15,17]. T wave inversion in V1–3 in those aged > 14 years is seen in only 4% of women and 1% of men and is a useful  
154 sign in this patient group [5–7]. If T wave inversion is observed in V1–3 in a young patient, further evaluation, such as  
155 echocardiography, may be considered [2,5]. In the future, it would be desirable to investigate the sensitivity in the

165 diagnosis of ARVC in cases with V1–3 T wave inversion on routine preoperative ECGs. The epsilon wave observed in this  
166 case was inappropriate for screening because it was observed in only 30% of the patients with ARVC [18].  
167

168 A limitation of this case report is that there was only one case. Further studies are needed to determine whether  
169 remimazolam is the best choice for anesthesia in patients with ARVC.  
170

#### 171 4. CONCLUSION

172  
173 We report a case of ARVC that was safely managed using total intravenous anesthesia with remimazolam. Although  
174 ARVC is a rare heart disease, it may cause sudden death during the perioperative period and should be managed  
175 promptly and appropriately. Anesthesiologists should pay close attention to anesthetic management in patients with  
176 ARVC.

#### 177 ACKNOWLEDGMENTS

178  
179 This report was supported by research funds to promote the hospital functions of the Japan Organization of Occupational  
180 Health and Safety. We would like to thank Editage (www.editage.com) for the English language editing.  
181

#### 182 COMPETING INTERESTS

183  
184 Authors have declared that no competing interests exist.  
185

#### 186 AUTHORS' CONTRIBUTIONS

187  
188 HA experienced this case. HA wrote the first draft of the manuscript. YT supervised and reviewed this study. YT, HI, EF,  
189 MO, NO, and TH advised and revised the manuscript. All authors have read and approved the final manuscript.  
190

#### 191 CONSENT

192  
193  
194 Written informed consent was obtained from the patient (or other approved parties) for the publication of this case report  
195 and accompanying images.  
196

#### 197 ETHICAL APPROVAL

198  
199  
200 All authors hereby declare that all experiments have been examined and approved by the appropriate ethics committee  
201 and have been performed in accordance with the ethical standards laid down in the 1964 Declaration of Helsinki. This  
202 report has been approved by the Nagasaki Rosai Hospital Institutional Review Board (No.05001, 2023/04/14).  
203

#### 204 REFERENCES

- 205  
206 1. Hu CS. A comprehensive strategy for managing arrhythmogenic right ventricular cardiomyopathy. *Turk Kardiyol Dern*  
207 *Ars.* 2020;48(2):88–95. Available: <https://doi.org/10.5543/tkda.2019.74184>. PMID: 32147655.  
208 2. Kato Y. Anesthetic management of patients with arrhythmogenic right ventricular cardiomyopathy. *Masui.*  
209 2014;63(1):39–48. PMID: 2455893.  
210 3. Chen S, Chen L, Duru F, Hu S. Heart failure in patients with arrhythmogenic cardiomyopathy. *J Clin Med.* 2021;10(20).  
211 Available: <https://doi.org/10.3390/jcm10204782>. PMID: 34682905.  
212 4. Alexoudis AK, Spyridonidou AG, Vogiatzaki TD, Iatrou CA. Anaesthetic implications of arrhythmogenic right ventricular  
213 dysplasia/cardiomyopathy. *Anaesthesia.* 2009;64(1):73–8. Available: <https://doi.org/10.1111/j.1365-2044.2008.05660.x>.  
214 PMID: 19087010.  
215 5. Levy D, Bigham C, Tomlinson D. Anaesthesia for patients with hereditary arrhythmias; part 2: congenital long QT  
216 syndrome and arrhythmogenic right ventricular cardiomyopathy. *BJA Educ.* 2018;18(8):246–53. Available:  
217 <https://doi.org/10.1016/j.bjae.2018.04.005>. PMID: 33456840.  
218 6. Marcus FI, McKenna WJ, Sherrill D, Basso C, Bauce B, Bluemke DA, et al. Diagnosis of arrhythmogenic right  
219 ventricular cardiomyopathy/dysplasia: proposed modification of the task force criteria. *Circulation.* 2010;121(13):1533–41.  
220 Available: <https://doi.org/10.1161/circulationaha.108.840827>. PMID: 20172911.  
221 7. Marcus FI, McKenna WJ, Sherrill D, Basso C, Bauce B, Bluemke DA, et al. Diagnosis of arrhythmogenic right  
222 ventricular cardiomyopathy/dysplasia: proposed modification of the Task Force Criteria. *Eur Heart J.* 2010;31(7):806–14.  
223 Available: <https://doi.org/10.1093/eurheartj/ehq025>. PMID: 20172912.

- 224 8. Staikou C, Chondrogiannis K, Mani A. Perioperative management of hereditary arrhythmogenic syndromes. *Br J*  
225 *Anaesth.* 2012;108(5):730-44. Available: <https://doi.org/10.1093/bja/aes105>. PMID: 2249946.
- 226 9. Tang F, Yi JM, Gong HY, Lu ZY, Chen J, Fang B, et al. Remimazolam benzenesulfonate anesthesia effectiveness in  
227 cardiac surgery patients under general anesthesia. *World J Clin Cases.* 2021;9(34):10595–603. Available:  
228 <https://doi.org/10.12998/wjcc.v9.i34.10595>. PMID: 35004991.
- 229 10. Godai K. What are mechanisms of re-sedation caused by remimazolam? *J Anesth.* 2021;35(3):466. Available:  
230 <https://doi.org/10.1007/s00540-021-02926-8>. PMID: 33751202.
- 231 11. Doi M, Hirata N, Suzuki T, Morisaki H, Morimatsu H, Sakamoto A. Safety and efficacy of remimazolam in induction and  
232 maintenance of general anesthesia in high-risk surgical patients (ASA Class III): results of a multicenter, randomized,  
233 double-blind, parallel-group comparative trial. *J Anesth.* 2020;34(4):491–501. Available: [https://doi.org/10.1007/s00540-](https://doi.org/10.1007/s00540-020-02776-w)  
234 [020-02776-w](https://doi.org/10.1007/s00540-020-02776-w). PMID: 32303884.
- 235 12. Oh J, Park SY, Lee SY, Song JY, Lee GY, Park JH, et al. Determination of the 95% effective dose of remimazolam to  
236 achieve loss of consciousness during anesthesia induction in different age groups. *Korean J Anesthesiol.* 2022;75(6):510–  
237 7. Available: <https://doi.org/10.4097/kja.22331>. PMID: 35912426.
- 238 13. Corrado D, Link MS, Calkins H. Arrhythmogenic right ventricular cardiomyopathy. *N Engl J Med.* 2017;376(1):61–72.  
239 Available: <https://doi.org/10.1056/NEJMra1509267>. PMID: 28052233.
- 240 14. Wallace R, Calkins H. Risk Stratification in Arrhythmogenic Right Ventricular Cardiomyopathy. *Arrhythm Electrophysiol*  
241 *Rev.* 2021;10(1):26–32. Available: <https://doi.org/10.15420/aer.2020.39> PMID: 33936740
- 242 15. Cho Y. Arrhythmogenic right ventricular cardiomyopathy. *J Arrhythm.* 2018;34(4):356–68. Available:  
243 <https://doi.org/10.1002/joa3.12012>. PMID: 30167006.
- 244 16. Tabib A, Loire R, Miras A, Thivolet-Bejui F, Timour Q, Bui-Xuan B, et al. Unsuspected cardiac lesions associated with  
245 sudden unexpected perioperative death. *Eur J Anaesthesiol.* 2000;17(4):230–5. Available: [https://doi.org/10.1046/j.1365-](https://doi.org/10.1046/j.1365-2346.2000.00653.x)  
246 [2346.2000.00653.x](https://doi.org/10.1046/j.1365-2346.2000.00653.x). PMID: 10866005.
- 247 17. Sinagra G, Cappelletto C, A DEL, Romani S, Paldino A, Korcova R, et al. Focus on arrhythmogenic right ventricular  
248 cardiomyopathy. *Eur Heart J Suppl.* 2020;22(Suppl L):L129–L35. Available: <https://doi.org/10.1093/eurheartj/suaa152>.  
249 PMID: 33239987.
- 250 18. Li KHC, Bazoukis G, Liu T, Li G, Wu WKK, Wong SH, et al. Arrhythmogenic right ventricular  
251 cardiomyopathy/dysplasia (ARVC/D) in clinical practice. *J Arrhythm.* 2018;34(1):11–22. Available:  
252 <https://doi.org/10.1002/joa3.12021>. PMID: 29721109.

253  
254

## 255 **DEFINITIONS, ACRONYMS, ABBREVIATIONS**

256 ARVC: arrhythmogenic right ventricular cardiomyopathy  
257 VT: ventricular tachycardia  
258 PSCD: perioperative sudden cardiac death  
259 ECG: electrocardiogram  
260 m-TAPA: modified thoracoabdominal nerves block perichondrial approach  
261 NRS: numerical rating scale  
262