

## Original Research Article

### Hepatoprotective and Nephroprotective effects of *Harunganamadagascariensis* in combination with antioxidant compounds in albino SpragueDawley rats

**Comment [M1]:** As long as the plant have English name, it should be put the English name before Latin name  
dragon's blood tree, orange-milk tree or haronga.

#### **Abstract.**

**Aim:**The aim of this study is to evaluate the effects of *Harunganamadagascariensis* stem bark ethyl acetate extract with antioxidants on the liver and kidney in rats.

**Study Design:** Experimental

**Place and Duration of Study:** Department of Veterinary Pharmacology and Toxicology, University of Ibadan (from January-February, 2020).

**Methodology:** This was done using ethyl acetate extracts (EHM) of the plant in combination with Ascorbic acid, Selenium or Allopurinol. Albino rats (Wistar) grouped into 12 of 5 animals per group for protective studies were used to determine the hepatotoxic and nephrotoxic effects of Acetaminophen (800mg/kg) in a 9-days study.

**Result:**This study showed that acetaminophen induced-stress on the liver and kidney causing increase in liver biomarkers such as the aspartate transaminase (AST), alanine transaminase (ALT), alkaline phosphate (ALP), creatinine, blood urea, total protein and gamma-glutamyltransferase (GGT). The combination of Ethyl acetate extract with Ascorbic acid, Allopurinol or Selenium at different doses causes protective effects by reducing the release of biomarkers and stabilized the elevated enzymes level shown in acetaminophen group. The histopathology of the liver in the acetaminophen group showed moderate portal congestion with mild periportal cellular infiltration and a moderate to severe portal fibrosis, while the kidney showed severe diffuse tubular degeneration and necrosis.

**Conclusion:** The EHM (500mg/kg and 200mg/kg) in combination with Ascorbic acid, Allopurinol or Selenium protected the liver and kidney from injury induced by Acetaminophen. The Ethyl acetate extract of the plant showed synergy with Ascorbic acid, Selenium and Allopurinol to prevent injury on both organs.

**Key words:** *Harunganamadagascariensis*, Biomarkers, Antioxidants, Protective, Histopathology.

**Comment [M2]:** Which type of rats

#### **INTRODUCTION**

Hepatic injury or diseases account for over 500 million cases of health challenges in both acute and chronic forms as estimated by World Health Organization[1].

Hepatotoxicants or hepatotoxins are the substances responsible for these dysfunctions. It may be due to intake of alcohol, overdose of therapeutic drugs, herbal remedies and dietary supplements; inhalation of xenobiotics like industrial chemicals or smoking [2,3]. Certain drugs can cause damage to the liver and kidney even at therapeutic dose level because of their reactive metabolites [4,5,6] or from an immunologically-mediated response affecting hepatocytes, biliary epithelial cells and/or liver vasculature [7].

Acetaminophen is a common over the counter drug used as analgesic, it is hepatotoxic because it is metabolically activated by cytochrome P450 enzymes to a reactive metabolite N-acetyl-p-benzoquinone imine (NAPQI) that depletes glutathione (GSH) and covalently binds to protein [8]. It was shown that repletion of GSH prevented the toxicity [9]. Acetaminophen overdose is toxicant not only to the liver but also to the kidney [10] because the level of glutathione and free proteins will be depleted in the system with increase of this metabolite leading to organs injury [11].

Antioxidants can either be exogenous or endogenous which help in scavenging free radicals and neutralizing them thereby preventing damage to the tissues [12,13]. Catalase, superoxide dismutase and glutathione systems are endogenous

antioxidants while ascorbic acid, selenium, allopurinol, vitamin A and E etc are exogenous antioxidants [3].

Ascorbic acid is a monosaccharide oxidation-reduction (redox) catalyst found in both animals and plants [14]. It is required for the conversion of the procollagen to collagen by oxidizing proline residues to hydroxyproline [14]. In addition to its direct antioxidant effects, it is also a substrate for the redox enzyme ascorbate peroxidase which is important for stress resistance in plants [15].

Selenium is an important antioxidants, at least 30 selenoproteins that have been identified in mammals, and about 25 in humans [16]. Foods are the major source of Se; seafood, cereals and meat products contain relatively high levels of Se and low levels in milk, vegetables and fruits [17]. It is an important component of antioxidant enzymes, such as glutathione peroxidase (GPx), thioredoxin reductase (TrxR) and iodothyronine deiodinases (IDD) [18].

Allopurinol is an inhibitor of xanthine oxidase enzymes that catalyses uric acid formation from xanthine [19]. It was shown to scavenge superoxide anion and hydroxyl radicals in *in vitro* and experimental studies, whereas it improves endothelial dysfunction caused by oxidative stress in patients of congestive heart failure, type 2 diabetes, and coronary artery disease, and in smokers [20].

*Harunganamadagascariensis* is a monotypic medium to tall tree species commonly called dragon's blood tree. It is used in folkloric treatment of jaundice, diarrhea, dysentery, typhoid fever, constipation, liver problems, anaemia and malaria, river blindness, ulcer, asthma, hepatitis, dysmenorrhea, and toothache [21,10]. Several scientific reports validating the folkloric use of the leaves and stem bark of this plant in the treatment of anaemia, diabetes, oxidative stress related diseases, bacterial infections, diarrhoea and gastro-intestinal disorders are documented [22,23]. The phytochemistry of the roots, leaves and stems bark of *Harunganamadagascariensis* have been investigated to have bioactive compounds like: anthracene derivatives with anti-plasmodial and antibacterial flavonoids [13, 24]. Scientific studies also indicate compounds like anthrones, anthraquinones, xanthenes, flavonoids, and essential oils from this plant [21,25].

A combination study was therefore carried out to assess the effects of the Ethyl acetate extract of the plant along with vitamin C, selenium or allopurinol in Sprague Dawley rats.

## MATERIAL AND METHODS

### 2.1 Plant material

About 1000g of fresh stem bark of *Harunganamadagascariensis* was purchased from Molete market, Ibadan, Nigeria. The bark was washed by rinsing in distilled water and air-dried completely at room temperature ( $30 \pm 2^\circ\text{C}$ ), protected from heat and direct sunlight for about 4 weeks. The dried plant stem bark was homogenized to fine powder using Laboratory Hammer mill (Zhen Chang Equipment SFS P66) and solvent to solvent extraction of fine powder of the plant was done using N-hexane, Ethyl acetate and Methanol respectively.

### 2.2 Pilot Toxicity Study

Doses at 5000mg/kg, 3000mg/kg and 1000mg/kg body weight of Ethyl acetate extract were used for acute toxicity test [26]. The animals were observed for changes in behavior and mortality for 24 hours and a week.

#### 2.2.1 Experimental Animals and their care

A total of 60 Albino rats (Wistar) of both sexes weighing 180-220g were kept in Experimental Animal Unit of the Department of Veterinary Pharmacology and Toxicology, University of Ibadan, Ibadan, Nigeria were used for the study. The animals were handled in accordance with international principles guiding the Use and Handling of experimental animals (United States National Institutes for animal Health) after an ethical approval was obtained from the Animal Care and Use Research Ethics Committee (ACUREC) of the University of Ibadan, Ibadan, Nigeria, with an approval number of UI-ACUREC/19/0121. The rats were maintained

**Comment [M3]:** 1-Fine may some of bioactive components were destroy or oxidized  
2- Also, you should be analyze bioactive components as antioxidants

**Comment [M4]:** 1-Hexane and methanol are not prefer to produce edible safe extract  
Its prefer ethanol or ethyl acetate  
2- The method of extraction incomplete (you must be use rotary evaporated to protect the bioactive components) also need the reference method of extraction

**Comment [M5]:** 1-How many male and female  
2-In this type of experiment prefer male rats

on standard rat feed (Vital Feeds from Grand Cereals Limited, Jos Nigeria) The rats were maintained at an ambient temperature between 28-30 °C, humidity of 55±5%, and standard (natural) photoperiod of approximately 12 hours of lighting (06:30 hours – 18:30 hours) alternating with approximately 12 hours of darkness (18:30 hours – 06:30 hours)

### 2.3 Acetaminophen induced toxicity in animals

The animals were grouped into 12 of 5 Albino rats for protective study.

All groups of animals that received acetaminophen was at a dose of 800mg/kg orally.

Group 1 received acetaminophen once daily for the last two days, Group 2 served as normal control received distill water orally for ten days, Group 3 received Sylimarin 100mg/kg for 8 days before acetaminophen on day 9, Group 4 received ethyl acetate extract (500mg/kg) and ascorbic acid (200mg/kg) for 8 days before giving acetaminophen on day 9. Group 5 received Ethyl acetate extract (200mg/kg) and ascorbic acid (200mg/kg) for 8days before giving acetaminophen on day 9. Group 6 animals were administered ethyl acetate extract (100mg/kg) and ascorbic acid (200 mg/kg) for 8 days before giving acetaminophen on day 9; same for selenium 1mg/kg and allopurinol 50mg/kg was giving in combination with Ethyl acetate extract at 500mg/kg, 200mg/kg and 100mg/kg respectively and were in groups 7-12.

#### 2.3.1 Biochemical Analysis

On day 10, animals were anaesthetize with diethyl ether and blood samples were collected from retro-orbital vein into plain bottles for the determination of biochemical parameters. Well-labeled plain bottles were used to collect 10 mL of blood sample, which was allowed to clot for 4 hours before centrifuging using Uniscope Laboratory Centrifuge (Model SM 112, Surgifriend Medicals, England) at 2000 revolution per minute for 15minutes to separate the sera from clotted blood cells. Each serum was carefully separated in the plain bottles that were well label accordingly at room temperature of 23-26°C. The activities of AST, ALP and ALT were estimated as described by Reitman and Frankel (1957). The activities of T. Bil were determined by colorimetric method using a kit supplied by Randox test kit (UK). The blood urea was determined using urease-Berthelot (enzymatic) colorimetric method and serum total protein was evaluated based on the Gornall et al (1949) method.

#### 2.3.2 Gross and histopathology

The organs kidney and liver were sectioned and rinsed in normal saline. The tissue was fixed in 10% formal-saline, dehydrated with 100% ethanol solution and embedded in paraffin and sectioned at 5µm, stained using H&E method, cleared in xylene and mounted in a mountant (Akanbi&Taiwo 2014). Using the magnification of 400x.

## 3. RESULTS

### 3.1 Pilot study

The pilot study showed that there was no mortality even at 5000mg/kg, no toxic sign at 1000mg/kg but dullness and reduced feeding at 3000mg/kg and 5000mg/kg has shown in table 1.

**Table 1 Pilot study on the Toxic effects of *H. madagascariensis* in Rats**

Group	Dose	Dead rats	Toxic sign observed
A	Distilled water	0	None
B	1000mg/kg	0	None
C	3000mg/kg	0	Dullness and reduced feeding
D	5000mg/kg	0	Dullness and reduced feeding

Comment [M6]: 10 days is not enough to judge

### 3.2.1 Effect of Ethyl acetate extract of *H.madagsacariensis* (500mg/kg, 200mg/kg and 100mg/kg doses) in combination with Ascorbic acid 200mg/kg

In the hepatoprotective group, the combination of Ethyl acetate extract 500mg/kg with Ascorbic acid show significant decrease (P=.0001) in the level of AST and ALP , ALT (P=.01); T.BIL, GGT and CRT (P=.05), 200mg/kg show decrease (P=.05) in ALT, ALP, AST and BUN only, in 100mg/kg there was slight decrease (P=.05) in BUN only when compared with Acetaminophen group.

In comparison with sylimarin, there was significant decrease (P=.0001) in serum ALP of rats treated with Ethyl acetate extract 500mg/kg and 200mg/kg in combination with ascorbic acid. The 100mg/kg combination with ascorbic showed significance increase (P=.002) in AST and ALP only but no significance difference in other parameters when compared to Sylimarin group as shown in Table 2.

**Table 2 . Effect of *H.madagascariensis* in combination with Ascorbic acid.**

Parameters	Groups					
	I	II	III	IV	V	VI
<b>T.P RO</b>	6.67±0.15	7.47±0.67	6.95±0.35	6.9±0.23	7.4±0.56	8.56±0.20
ALB	2.9±0.1	3.27±0.38	2.85±0.21	2.96±0.05	3.05±0.49	3.43±0.25
GLO	3.7±0.05	4.67±0.78	4.1±0.14	4.3±0.45	4.35±0.07	4.8±0.43
A.G ratio	0.7±1.36	0.7±0.22	0.65±0.07	0.67±0.05	0.65±0.66	0.7±1.35
AST	37.3±1.53	47±1.41	41±2.82	40±1	45.5±3.53	48.66±5.50
ALT	26±1.00	35.25±0.95	31±2.82	29±3.21	33.5±2.12	35.66±1.15
ALP	80±6.08	127.75±0.5	101.5±6.36	107.7±4.7	124±2.82	125±6.65
BUN	15.63±0.15	19.05±0.19	18±0.42	17.6±0.25	18.5±0.28	17.4±0.36
CRT	0.533±0.1	0.75±0.05	0.6±0	0.63±0.06	0.8±0	0.7±1.35
T.BIL	0.23±0.05	0.475±0.05	0.35±0.07	0.33±0.05	0.3±0	0.4±6.79
GGT	0.23±0.02	0.375±0.02	0.26±0.02	0.26±0.05	3.05±0.35	3.43±0.6

I-Normal control group; II-Acetaminophen group; III-Silymarin 100mg/kg; IV- Ethyl acetate extract (500mg/kg) and ascorbic acid; V-Ethyl acetate extract (200mg/kg) and Ascorbic acid; VI-Ethyl acetate extract (100mg/kg) and Ascorbic acid

### 3.2.2 Effect of Ethyl acetate extract of *H. madagascariensis* in combination with Selenium 1mg/kg.

In the hepatoprotective group as indicated in Table 3, the combination of Ethyl acetate extract (500mg/kg) with Selenium shows significant decreased in the level of ALP (P=.0001) only, at 200mg/kg and 100mg/kg of EHM in combination with selenium, there was significance decrease in serum ALT (P=.0001), AST and ALP (P=.0001), slight decrease in BUN and T. Bil (P=.01). But there was no significance difference (P=.9500) in other parameters compared to acetaminophen group.

When compared with Silymarin, 500mg/kg of EHM combination with selenium showed significant decrease (P=.0001) in ALP, 200mg/kg EHM combination showed significance decrease in ALP and AST and (P≥0.0001) but no significance difference (P=.9500) in other parameters in the Ethylacetate extract with Selenium (1mg/kg) group in all the groups when compared with Silymarin group.

**Table 3** Effects of *H. madagascariensis* in combination with Selenium.

Parameters	Groups					
	II	I	III	IV	V	VI
T.PRO	6.67±0.15	7.47±0.67	6.95±0.35	7.36±0.5	6.4±0.17	7.3±0.62
ALB	2.9±0.1	3.27±0.38	2.85±0.21	3.36±0.2	2.63±0.15	2.96±0.05
GLO	3.7±0.05	4.67±0.78	4.1±0.14	4±0.26	3.76±0.05	4.33±0.58
A.G ratio	0.7±1.36	0.7±0.22	0.65±0.07	0.8±1.36	0.66±0.05	0.66±0.05
AST	37.3±1.53	47±1.41	41±2.82	44.6±2.5	36.33±0.5	41.33±1.5
ALT	26±1.00	35.25±0.95	31±2.82	33.3±3.0	27.33±0.5	30±4.58
ALP	80±6.08	127.75±0.5	101.5±6.3	110±13.8	110±4.35	116.6±1.1
BUN	15.63±0.1	19.05±0.19	18±0.42	18.2±0.5	17.2±0.2	16.5±0.85
CRT	0.533±0.0	0.75±0.05	0.6±0	0.7±0.1	0.7±1.35	0.63±0.05
T.BIL	0.23±0.05	0.475±0.05	0.35±0.07	0.33±0.0	0.2±3.39	0.33±0.23
GGT	0.23±0.02	0.375±0.01	0.26±0.02	0.32±0.0	2.7±0.2	2.3±0.28

I-Normal group; II- Acetaminophen group; III-Silymarin (100mg/kg); IV-Ethyl acetate extract (500mg/kg) and Selenium group (1mg/kg); V-Ethyl acetate extract (200mg/kg) and Selenium group (1mg/kg); VI- Ethyl acetate (100mg/kg) and Selenium (1mg/kg)

**Effect of Ethyl acetate extract (500mg/kg, 200mg/kg and 100mg/kg) of *H. madagascariensis* in combination with Allopurinol (50mg/kg)**

In this study, the combination of Ethyl acetate extract with Allopurinol significantly decreased (P=.0001) the level of ALP in the three groups when compared with the toxic group. The 500mg/kg EHM combination decreased the level of BUN, CRT and T.BIL; 200mg/kg decreased the level of AST, ALT and T.BIL but no significance difference (P=.0999) in other parameters in comparison to toxic group and at 100mg/kg when compared with the acetaminophen group there was no significant difference.

There was significant increase (P=.0001) in ALP in the three groups, and AST in the 100mg/kg and 500mg/kg of Ethyl acetate extract combination with Allopurinol group when compared with Silymarin group as shown in (Table 4).

**Table 4 Effects of *H. madagascariensis* in combination with Allopurinol.**

Parameters	Groups					
	II	I	III	IV	IV	IV
T.P RO	6.67±0.15	7.47±0.67	6.95±0.35	7.35±0.21	7.03±0.87	9.03±0.68
ALB	2.9±0.1	3.27±0.38	2.85±0.21	3.1±0.14	2.96±0.30	3.56±0.66
GLO	3.7±0.05	4.67±0.78	4.1±0.14	4.25±0.07	4.06±0.56	5.46±0.05
A.G ratio	0.7±1.36	0.7±0.22	0.65±0.07	0.7±0	0.73±0.05	0.6±0.1
AST	37.3±1.53	47±1.41	41±2.82	46.5±2.12	40.66±5.50	52.33±6.42
ALT	26±1.00	35.25±0.95	31±2.82	34.5±2.12	28.33±4.04	35±1.73
ALP	80±6.08	127.75±0.5	101.5±6.36	109±9.8	114.33±7.50	131±10.44
BUN	15.63±0.15	19.05±0.19	18±0.42	16.8±0	18.13±1.10	18.9±1.21
CRT	0.533±0.05	0.75±0.05	0.6±0	0.65±0.07	0.96±0.37	0.73±0.05
T.BIL	0.23±0.05	0.475±0.05	0.35±0.07	0.35±0.07	0.3±0.1	0.53±0.11
GGT	0.23±0.02	0.375±0.019	0.26±0.02	0.35±0.007	3.13±0.66	4.1±0.79

I-Normal control group;II-Acetaminophen group; III- Silymarin (100mg/kg); IV-Ethyl acetate extract (500mg/kg) and Allopurinol; V-Ethyl acetate extract (200mg/kg) and Allopurinol; VI- Ethyl acetate extract 100mg/kg and Allopurinol

**Histopathological effects of Ethyl acetate extracts of *H.madagascariensis* in combination with Ascorbic acid, Selenium and Allopurinol on Liver and Kidney.**

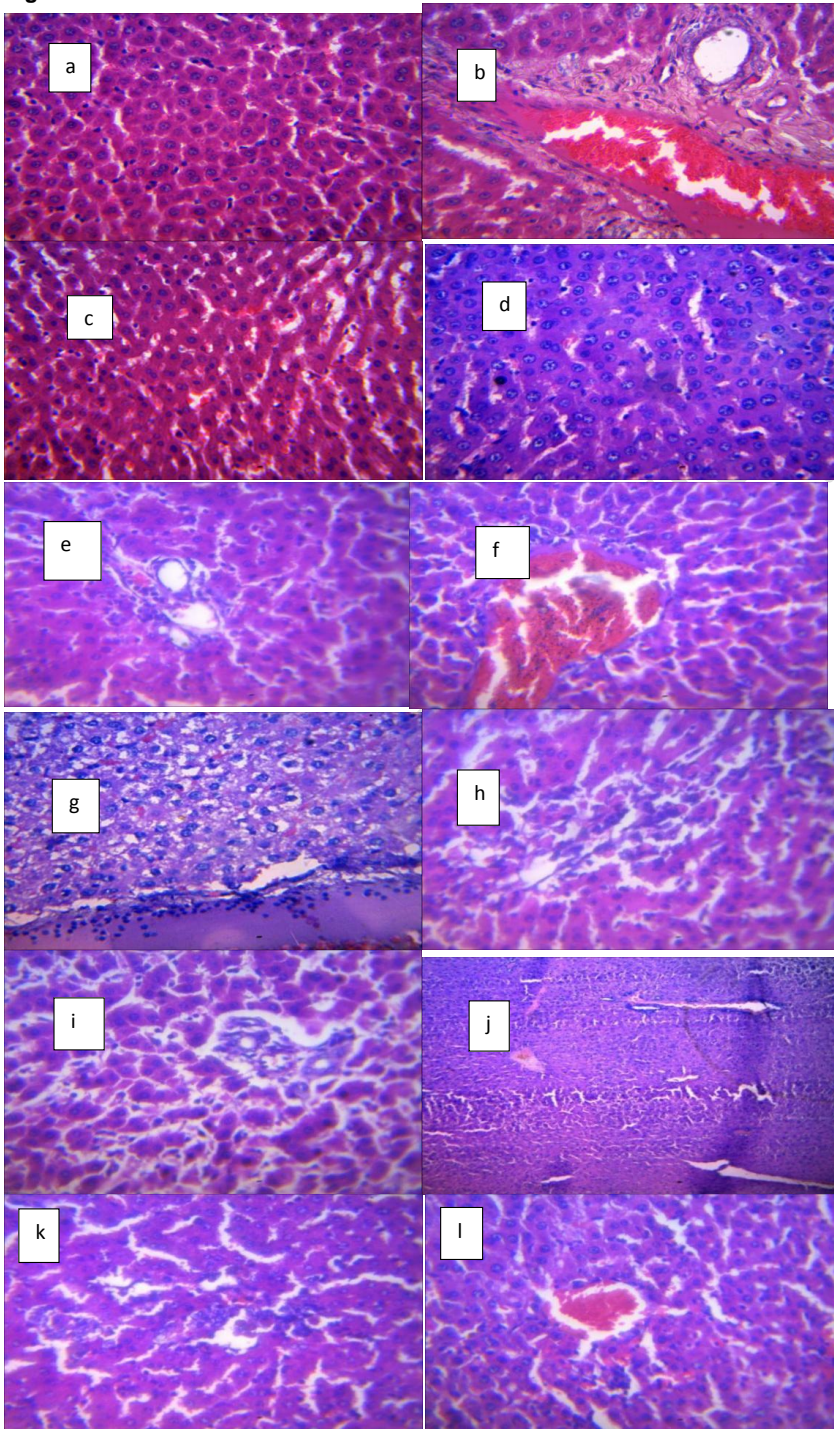
The combination of Ethyl acetate extract with Ascorbic acid (EHA) showed no lesion at 500mg/kg, moderate cellular periportal infiltration at 200mg/kg and venous congestion at 100mg/kg combination with Ascorbic acid (200mg/kg) in the liver. Acetaminophen showed severe liver congestion while the untreated group indicated no lesion as described in Fig 1.

Combination of Ethyl acetate extract with Selenium(1mg/kg) (EHS)at 500mg/kg showed moderate portal congestion with severe periportal cellular infiltration; EHS(200mg/kg) showed no lesion but at 100mg/kg, there is moderate periportal cellular infiltration.

The combination of the extract with Allopurinol (50mg/kg) (EHAL) at 500mg/kg showed very mild portal congestion, 200mg/kg EHAL showed no lesion but 100mg/kg showed mild portal and central venous congestion as described in Fig 1

In the kidney, the acetaminophen group showed severe diffuse tubular degeneration and necrosis, EHA (500mg/kg) showed moderate to severe interstitial congestion at the renal cortex; EHA (200mg/kg) showed no visible lesion but 100mg/kg showed mild to moderate interstitial congestion ; EHS and EHAL at the three doses did not show any visible lesion as described in Fig 2

**Fig 1. Effects on the Liver**

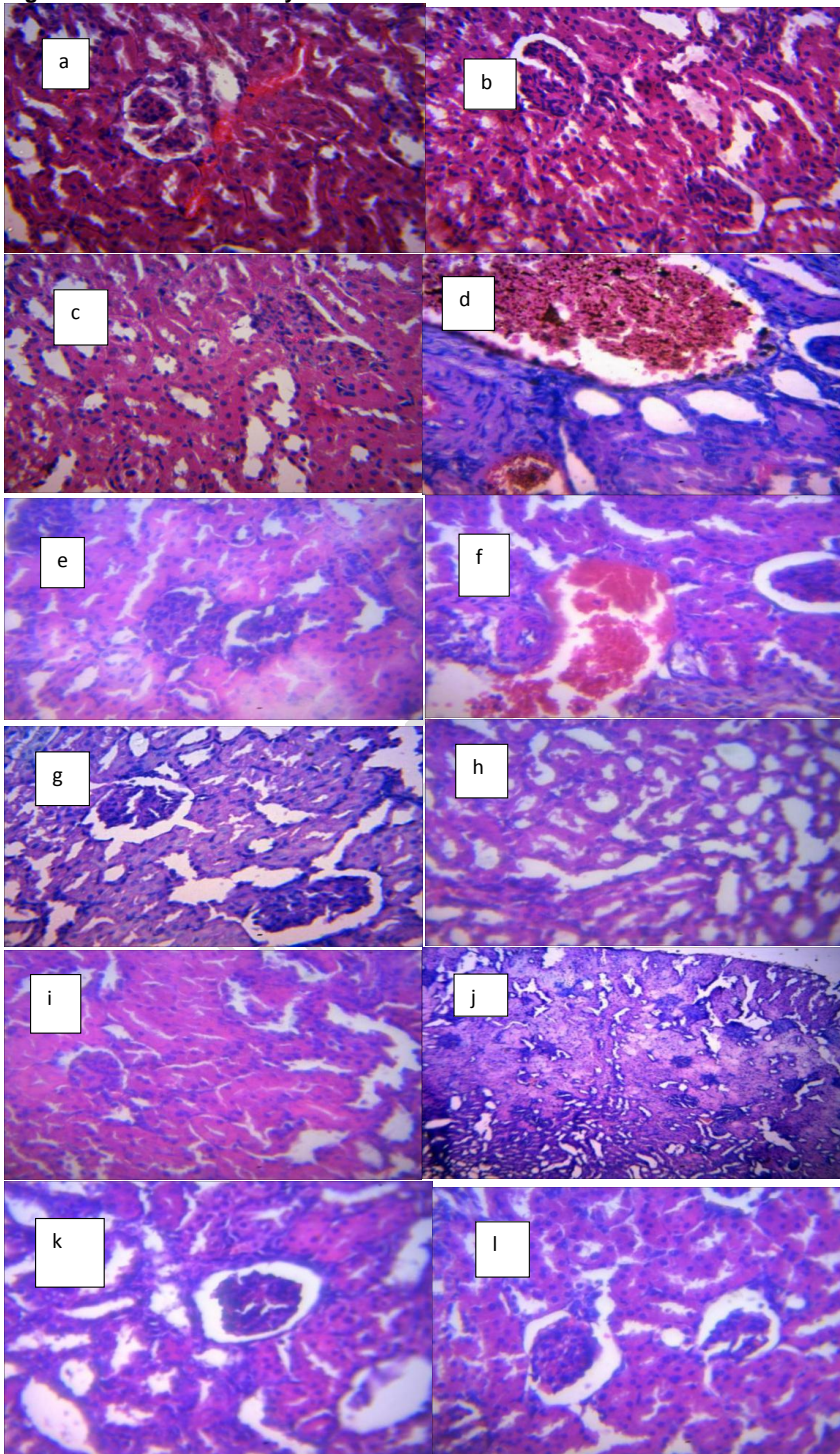


a. Normal group- There is no visible lesion. (H&E stained and magnification of x400)

- b. Acetaminophen group- There is moderate portal congestion with mild periportal cellular infiltration. There is also a moderate to severe portal fibrosis
- c. Sylimarin group- No visible lesion.
- d. EHA 500mg/kg group-No visible lesion seen. (H&E stained and magnification of x400)
- e. EHA 200mg/kg group- There is mild to moderate periportal cellular infiltration.
- f. EHA 100mg/kg group- Mild congestion and central venous congestion.
- g. EHS 500mg/kg group-There is a moderate portal congestion with severe periportal cellular infiltration.
- h. ETS 200mg/kg group- No visible lesion.
- i. ETS 100mg/kg group- There is moderate periportal cellular infiltration.
- j. ETAL 500mg/kg group- Very mild portal congestion (H&E staining and magnification of x100)
- k. ETAL 200mg/kg group- No visible lesion
- l. ETAL 100mg/kg group- There is a mild portal and central venous congestion.

UNDER PEER REVIEW

**Fig 2. Effects on the Kidney**



a. Normal group- There is no visible lesion in the kidney

- b. Acetaminophen group- There is severe diffuse tubular degeneration and necrosis.
- c. Sylimarin group- No visible lesion
- d. ETA 500mg/kg group- There is a moderate to severe interstitial congestion at the renal cortex.
- e. ETA 200mg/kg group- There is no visible lesion
- f. ETA 100mg/kg group- There is mild to moderate interstitial congestion
- g. ETS 500mg/kg group- There is no visible lesion seen.
- h. ETS 200mg/kg group- There is no visible lesion
- i. ETS 100mg/kg group- There is no visible lesion
- m. ETAL 500mg/kg group- There is no visible lesion (H&E staining and magnification of x100)
- j. ETAL 200mg/kg group- There is no visible lesion
- k. ETAL 200mg/kg group- There is no visible lesion

### Discussion

The liver carries out over 500 essential tasks [28] and therefore it is exposed to xenobiotics due to its functions [29]. Kidney is also an important organ that is involved in homeostasis. Most xenobiotics including alcohol, drugs (metabolites) and liquids are excreted through the urine. There is need to protect such vital organs from damage, injury, disease, inflammation and necrosis.

The pilot study showed the extract has a wide margin of safety because there was no mortality even at 5000mg/kg but the experimental animals showed dullness and reduced feeding.

This study shows that 500mg/kg of EHM with Ascorbic acid was able to protect the liver by stabilizing the biomarkers which are the liver enzymes and other parameters that signifies damage; the 200mg/kg was able to decrease some parameters thereby protecting only the kidney but showed increase in GGT and CRT. The ability of EHM at 500mg/kg and 200mg/kg combination with ascorbic acid to decrease the level of the biomarkers indicate the antioxidant activities of ascorbic acid and that of the phytochemicals present in the plant extract, both form synergy to protect the organs from the toxic effect of acetaminophen; this is similar to the work done by [30] that the combination of Ascorbic acid and ginger was able to preserve liver anatomy and its function in aluminium induced toxicity. The combination of the two can therefore protect the organs and the system from the damaging effects of the toxicants. This study also relates to the report of [31] where ascorbic acid was combined with sylimarin and the combination was able to protect the liver histopathology and function from lead poisoning. EHM (100mg/kg) could not protect the hepatocytes and nephrons as there was increase in the biomarkers and injury in both organs (Fig1&2). This may be due to the dose, it may be too low to produce protective effect on the organs. The synergy in the activities of Ethyl acetate extract of *H. madagascariensis* and ascorbic acid is therefore responsible for the protection of the organs at 500mg/kg and 200mg/kg doses. This is because ascorbic acid is an antioxidant and it is reported to be involved in scavenging free radicals which are released due to stress, inflammation and injury [15] in the system. Ascorbic acid can therefore prevent injury to tissues. Okwulu *et al.*, 2021 [3] reported ascorbic acid (200mg/kg) alone can protect and ameliorate liver and kidney injury. The phytochemicals in the plant including (terpenoids and anthraquinones) are reported to have antioxidant activities [25,32].

The combination of 500mg/kg of Ethyl acetate extract with Selenium (1mg/kg) was able to maintain the physiological level of some of the biomarkers that relates to the kidney (ALP, BUN, T.Bil and GGT) while the 200mg/kg and 100mg/kg combination maintained all the parameters but increased in CRT and GGT when compared to Acetaminophen group and no significance difference in T. proteins. Histopathology of 500mg/kg EHM combination showed no visible lesion in the kidney confirming the biochemical evaluation, while 200mg/kg showed no injury or lesion in the both organs; and 100mg/kg showed only moderate portal cellular infiltration in the liver, no lesion in the kidney.

This study shows that at 200mg/kg and 100mg/kg of EHM combination with selenium, there was effective protection of the liver and the kidney while the 500mg/kg of EHM could only protect the kidney.

Selenium being an important component of antioxidant enzymes, such as glutathione peroxidase (GPx), thioredoxin reductase (TrxR) and iodothyronine deiodinases (IDD) [33]. This

may be the reason for the increased protective effect observed with lower doses of EHM. This is as describe by [3]

The 500mg/kg of EHM in combination with Allopurinol 50mg/kg showed decreased in ALP, BUN, CRT and T.bil compared to the toxic group whereas EHM at 200mg/kg combination with Allopurinol maintained the levels of all biomarkers except T.proteins, CRT and GGT compared to the acetaminophen group where all the biochemical parameters were elevated. Allopurinol being an antioxidant, it inhibit the production of reactive oxygen species and inflammatory mediators [32], it combination with the plant extract therefore has effective protective efficacy against acetaminophen toxicity. This synergy lead to the protective activities observed even at 200mg/kg of the extract combination with Allopurinol. Histopathology confirm this with very mild portal congestion in the liver and no lesion in the kidney at 500mg/kg EHM with Allopurinol 50mg/kg. The 200mg/kg EHM combination shows no visible lesion in both organs. This relates with the report of Choiaet al.,2015 [33] where Allopurinol was combined with apocynin in kidney damage induced by ischemia-reperfusion in rats, they form synergy and protected the kidney. The 100mg/kg EHM combination with Allopurinol could not protect the organs because the biomarkers remain elevated compared to the acetaminophen group and the histo-anatomy showed severe lesion in the liver and kidney. This dose maybe too low to elicit protective measures in acetaminophen toxicity. The 500mg/kg of extract in combination with Allopurinol 50mg/kg protects the kidney but the liver partially while 200mg/kg combination showed complete protection in both organs. Another study show that Allopurinol alone can not protect the organs [10], the protective effects seen in this study is therefore as a result of synergy between the plant extract and Allopurinol.

### Conclusion

*Harunganamadagascariensis* been confirm again in this study to have hepatoprotective activities may be because of the antioxidants constituents. Ascorbic acid, Selenium and Allopurinol are good antioxidants their combination with *H. madagascariensis* has increase its efficacy in the Ethyl acetate extract to protect the liver and especially the kidney in acetaminophen toxicity. The 500mg/kg of the Ethyl acetate extract of the plant with ascorbic acid may be preferred in protecting the liver while 200mg/kg of the extract in combination with the three antioxidants has better protective effects on both organs in case of acetaminophen toxicity.

### ETHICAL APPROVAL

"All authors hereby declare that "Principles of laboratory animal care" (NIH publication No. 85-23, revised 1985) were followed, as well as specific national laws where applicable. All experiments have been examined and approved by the appropriate ethics committee" which was the University of Ibadan Animal Care and Use Research Ethics Committee (UI-ACUREC) with approval number UI-ACUREC 19/0121

### REFERENCES

1. Jose J.K., Kuttan R. (2000). Hepatoprotective activity of *Emblica officinalis* and *chyavanprash*. *J Ethanopharmacol.* 72:135–40.
2. Aparajita, D. and Arthur, I.C. 2006. Alcohol and oxidative liver injury.
3. Okwulu O.J., Abatan M.O. and Adedapo A.A (2021): Hepatoprotective and hepatoregenerative effects of ascorbic acid, selenium and allopurinol in acetaminophen-induced liver damage in rats. *Journal of Pharnacognosy and Phytochemistry.* 10(5); 28-33.
4. Bramstedt K. A.(2006). Living liver donor mortality: where do we stand? *Official journal of American College of Gastroenterology/ACG* 101(4)755-759.
5. Dambach DM, Andrews BA, Moulin F (2005): New technologies and screening strategies for hepatotoxicity: use of in vitro models. *ToxicolPathol* 33: 17-26.
6. Dancygier H. (2010).The liver as an immune organ. *ClinicalHepatology: Principles and Practice of Hepatobiliar Disease.* 141-152.

7. Groneberg DA, Grosse-Siestrup C, Fischer A (2002) In vitro models to study hepatotoxicity. *ToxicolPathol* 30: 394-399.  
*Hepatology*, vol 43, 63-74
8. Lee WM (1995) Medical progress: Drug-induced hepatotoxicity. *N Engl J Med* 333: 1118-1127.
9. Saba, A.B., Oridupa, O.A. and Ajibade, T.O. (2013). Drug-induced Hepatotoxicity and Treatment. Hand book; First Edition.
10. Oluwadunni, O., Adebisi, O.E., Adedapo, A.A. and Abatan, M.O. (2019). Hepatoprotective effects of Ethyl acetate and Chloroform extracts of *Harunganamadagascariensis* on acetaminophen-induced toxicity in rats. *Trop Vet* 37(2): 87-98.
11. Dabelstein W., Reglitzky A., Schütze A and Reders K (2007). "Automotive Fuels". *Ullmann's Encyclopedia of Industrial Chemistry*
12. Andres S, Pevny S, Ziegenhagen R, Bakhiya N, Schäfer B, Hirsch-Ernst KI, Lampen A (2018). "Safety Aspects of the Use of Quercetin as a Dietary Supplement". *Mol Nutr Food Res (Review)*. **62** (1).
13. Machala M., Kubinova R., Sushy V. (2001). Chemoprotective potentials of homoiso flavonoids and chalcones of *Dracaena cinnabarin*: modulation of drug metabolizing enzymes and antioxidant activity. *Phytother Res* vol 15: 114-8
14. Shigeoka S, Ishikawa T, Tamoi M, Miyagawa Y, Takeda T, Yabuta Y, (2002). Regulation and function of ascorbate peroxidase isoenzymes. *J Exp Bot.* 53:1305–19.
15. Bjelakovic G., Dimitrinka N., Gluud L.L., Christain S. (2012). Antioxidant supplements for prevention of mortality in healthy participants and patients with various diseases. *Conchrane database of systematic reviews*.
16. Brenneisen P, Steinbrenner H, Sies H (2005). Selenium, oxidative stress, health aspects. *Mol Aspects Med* ;26:256–67
17. Valko M, Rhodes CJ, Moncol J, Izakovic M, Mazur M (2006). Free radicals, metals, antioxidants in oxidative stress-induced cancer. *Chem Biol Interact*;160:1–40.
18. Tapiero H, Townsend DM, Tew KD (2003). The antioxidant role of selenium and seleno-compounds. *Biomed Pharm*;57:134–44.
19. Wang W., Chuan W., Ding X., Pan Y., Gu T., Wang M., Liu Y., Wang F., Weng S., and Kong L. (2013): Quercetin and allopurinol reduce liver thioredoxin-interacting protein to alleviate inflammation and lipid accumulation in diabetic rats. *British J. of Pharmacology* 169(6): 1352-1371
20. Butler R, Morris AD, Belch JJ, Hill A, Struthers AD (2000). Allopurinol normalizes endothelial dysfunction in type 2 diabetics with mild hypertension. *Hypertension*; 35 (3):746 –751.
21. Moronkola D.O., Yeboah S. O., Majinda R. R. T. and Sichilongo K. (2015). Composition of *Harunganamadagascariensis* Lam. Ex Poir leaf and stem essential oils. *Journal of chemical and Pharmaceutical Research*, 7(5):959-964
22. Anita B.S., Ita B. N., and Udo U.E. (2015): Nutrient composition and In vitro Antioxidant properties of *H. madagascariensis* stem bark extracts. *Medicinal food*, 18 (5).
23. Agnani H., Mbot E. J., Keita O., Fehrentz J., Ankli A., Garcia M., Gary Bobo M., Lebib J., Cresteil T. and Menut C. (2016). Antidiabetic potential of two medicinal plants used in Gabones folk medicine. *BMC Complementary and Alternative Medicine*; 16:71

Comment [M7]: Number of paper

Comment [M8]: Complete ref

24. Malan D.F, Neuba D.F.R and K.L.Kouakou (2015): Medicinal plant and traditional healing practices in ehotile people around the aby lagoon (eastern littoral of coteflvoire) *Ethonobiology and Ethnomedicine*vol 11(21).
25. Biapa P.C.N, Matie H., Balici S., Oben J.E., and Ngogang J.Y (2013): Protective effects of stem bark of *H. madagascariensis* on the red blood cell membrane. *BMC Complementray Medicine and Therapy*,13 (98).
26. Lorke D. (1983): A new approach to practical toxicity testing. *Archives of Toxicity* 54, 275-287.
27. Grosse-Siestrup C, Pfeffer J, Unger V, Nagel S, Witt C, (2002) Isolated in Vitro hemoperfused slaughterhouse livers as a valid model to study hepatotoxicity. *ToxicolPathol* 30: 749-754.
28. Osama A., Abdelhamid F., Elboshy M., Samir H. (2014). Studies on the protective effects of ginger extracts and in combination with Ascorbic acid against aluminium toxicity induced hematological disorder, oxidative stress and hepatorenal damage in rats. *Annals of veterinary and animal Science* ISSN 2313-5514
29. Shalana MG, Mostafab MS, Hassounab MM, Hassab EL, Nabic SE, EL-Refaiad AC(2005): Amelioration of lead toxicity on rats liver with Vitamin C and Sylimarin supplements
30. JianmingGuo, FengQian, Jianxin Li, QiangXu, Ting Chen, (2006).Identification of a New Metabolite of Astilbin, 3'-O-Methylastilbin, and Its Immunosuppressive Activity against Contact Dermatitis. *Archived from the original on 2011-06-07*. Retrieved 2009-08-30.
31. Marija D, Milica G, Paunovic, Brank I, Zorica SS (2018). Role of Selenium and VitaminC in mitigating oxidative stress induced by fenitrothion in rat liver. *Biomed and Pharmacology*; 106:232-238
32. Prieto-Moure A, Caraben-Redano A, Aliena-velaro DC. Allopurinol in renal ischemia. (2014). *Journals of Investigative surgery* 27(5) 304-316

Comment [M9]: Number of page