

## Original Research Article

### **Immunohistochemical Features of Prostatic Carcinoma in Southwest Nigeria: A Ten-Year Retrospective Study**

#### **Abstract**

**Background:** The diagnosis of prostatic adenocarcinoma relies on a constellation of architectural and cytological features. However, some cases may pose some diagnostic challenges especially where there are only small foci of cancer where only a few atypical glands are present, especially in needle biopsies. Therefore, immunohistochemistry may be used to differentiate benign from malignant proliferations, primary prostatic lesions and secondary lesions from other sources.

**Objectives:** To determine the immunohistochemical profile of prostatic carcinoma seen at the Department of Morbid Anatomy and Histopathology, Ladoké Akintola University of Technology Teaching Hospital, Osogbo, using high molecular weight cytokeratin, alpha-methylacyl co-enzyme A racemase and Ki-67 markers.

**Methods:** This was a retrospective study involving all cases of diagnosed prostatic carcinoma in the Department of Morbid Anatomy and Histopathology of the Ladoké Akintola University of Technology Teaching Hospital, Osogbo, Osun State, Nigeria. The histologic slides were reviewed for the histological variant of prostatic carcinoma as well as the Gleason histologic grade of the tumour and the presence of high-grade prostatic intraepithelial neoplasia (HGPIN). Immunohistochemistry was done using high molecular weight Cytokeratin (HMWCK), a basal cell marker, and alpha-methyl acyl CoA racemase (AMACR), a marker of malignant prostatic cells. Ki-67 antibody was used to assess the proliferating index of the tumour.

**Results:** The majority of cases (72.8%) were seen between the ages of 61 and 80 years while the peak age of frequency was the 71-80-year age group. Prostatic carcinoma constituted 4.4% of all tumours and 18.7 % of malignant tumours. A total of 204 (54.8%) cases were well-differentiated tumours, 104 (27.9%) moderately differentiated, and 64 (17.2%) were poorly differentiated. The most common histologic type (73.7%) was acinar adenocarcinoma, while colloid carcinoma was the least common variant (0.2%). HGPIN was seen in 111 cases (29.9%). Most of the cases of prostatic carcinoma (78.8%) were negative for Ki-67. All well-differentiated tumours were negative for the marker.

**Conclusion:** Prostatic carcinoma is the commonest malignant tumour in males in this environment with a frequency that increases with age. Poorly differentiated tumours are more like to be associated with a younger age at presentation. HGPIN appears to be a true precursor lesion. Immunohistochemistry with HMWCK and AMACR should be reserved for equivocal cases only. The Ki-67 marker may help segregate tumours with poorer prognosis.

**Keywords:** Immunohistochemistry, Prostate carcinoma, adenocarcinoma

UNDER PEER REVIEW

## Introduction

Prostatic adenocarcinoma is an invasive epithelial tumor consisting of secretory cells of the prostatic glands.<sup>1</sup> In the development of prostatic cancer, many genes associated with cell cycle regulation and proliferation have been implicated.<sup>2</sup> Numerous molecular abnormalities have been described, including chromosome loss or gain, gene amplification, mutations leading to increases or decreases in gene expression, and mutations leading to changes in the function of the protein product.<sup>3</sup> Telomerase reactivation has also been detected in a significant proportion of cases of prostatic cancer.<sup>4</sup> It has also been observed that telomerase RNA levels are higher in malignant tissues than in non-malignant ones.<sup>5</sup>

The product, E2F4, a transcription factor involved in cell proliferation, is overexpressed at the mRNA and protein levels in malignant radical prostatectomy specimens. There is also a possible significance for the development of prostate cancer from repeat polymorphism microsatellites (CAG and CGN) in the androgen receptor. Alleles of CAG microsatellites' repeat have been linked to an increased risk of advanced prostate cancer and diagnosis at a younger age.<sup>6</sup> The c-met protooncogene encodes the hepatocytes growth factor/scatter factor receptor. Its expression increases with Gleason's score and more than 90% of the metastatic specimen have been shown to be positive for the c-met proto-oncogene in contrast to 50% in primary tumors.<sup>7</sup>

The discovery of the HER2/neu (C-erbB2) oncogene in breast cancer led to speculation that it may also be important in prostate cancer.<sup>8</sup> However, it is expressed in more advanced diseases at lower levels.<sup>9</sup> Mutations of the p53 gene are common in prostatic cancers, particularly in advanced diseases. Abnormal accumulation of p53 protein is a negative prognostic factor for disease-free survival especially if the p53 positive nuclei were located near each other.<sup>10,11</sup> Loss of chromosome 17p (deleting a region that includes the p53 locus, but not BRCA) occurs in advanced stages of prostate cancer and metastatic disease.<sup>12</sup> It is now generally accepted that mutations of *p53* occur infrequently in early invasive carcinoma.<sup>13</sup>

PTEN, a tumour suppressor gene, located on chromosome 10q23 in a region frequently associated with loss of heterozygosity in prostate cancer and encoding a phosphatase that negatively regulates cell cycles may be mutated in prostatic carcinoma.<sup>14</sup> Loss of PTEN has been associated with higher Gleason's scores and the risk of clinical recurrence of the lesion.<sup>15,16</sup> Loss of PTEN at DNA and protein levels have been reported in 25–33% of advanced prostate tumours, and at varying frequencies, in clinically localized prostate cancer.<sup>17</sup>

Overexpression of *Bcl2* in prostate carcinoma cells is a hallmark of the advanced, hormone-refractory disease, and may account for the resistance to apoptosis that is characteristic of late stages of disease.<sup>18</sup> Although *Bcl2* expression is restricted to basal cells in the normal prostate, forced expression of *Bcl2* in locally advanced prostate carcinoma cells protects against apoptosis induced by androgen depletion.<sup>19,20</sup> Moreover, as is the case for *p53*, *Bcl2* expression may provide a prognostic marker that correlates with disease outcome.<sup>21</sup> Indeed, several preliminary studies have examined whether *Bcl2* inactivation may prevent tumor recurrence.<sup>21</sup> RUNX2 is a

transcription factor that prevents cancer cells from undergoing apoptosis thereby contributing to the development of prostate cancer.<sup>23</sup> The PI3k/Akt signaling cascade works with the TGF- $\beta$ /SMAD signaling cascade to ensure prostate cancer cell survival and protection against apoptosis.<sup>24</sup> Moreover, an X-linked inhibitor of apoptosis (XIAP) is hypothesized to promote prostate cancer cell survival and growth and is a target of research since it is possible that if this inhibitor can be shut down then the apoptosis cascade can carry on its function in preventing cancer cell proliferation.<sup>25</sup>

Macrophage inhibitory cytokine-1 (MIC-1) stimulates the focal adhesion kinase (FAK) signaling pathway which leads to prostate cancer cell growth and survival.<sup>26</sup> Numerous studies have provided evidence for familial clustering of prostate cancer, indicating that family history is a major risk factor for this disease.<sup>27</sup> Segregation analysis of familial prostate cancer suggests the existence of at least one dominant susceptibility locus and predicts that rare high-risk alleles at such loci account in the aggregate for 9% of all prostate cancers and more than 40% of early onset disease.<sup>28</sup> Analyses of genetic alterations in prostate cancer have demonstrated frequent duplication of DNA sequences on the distal long arm of chromosome 8, as well as loss of DNA sequences resulting in loss of heterozygosity (LOH) for the short arm of chromosome 8 and the long arm of the chromosome.

Preliminary investigations by linkage analysis of these regions as well as sites of known tumor suppressor genes have, however, not identified a susceptibility locus in prostate cancer.<sup>29</sup> In our local environment, the diagnosis of prostatic adenocarcinoma relies on a constellation of architectural and cytological features. Although the diagnosis of prostatic adenocarcinoma is straightforward, in some cases there may be benign lesions that mimic prostatic cancer histologically. In addition, the widespread use of various screening methods has made the diagnosis of early disease possible with pathologists being increasingly challenged in the diagnosis of small foci of cancer when only a few atypical glands are present, especially in needle biopsies. In difficult situations, therefore, immunohistochemistry may be used to differentiate between primary benign and malignant proliferations of the prostate on the one hand as well as between primary prostatic lesions and secondary lesions from other sources on the other hand.<sup>8</sup> Immunohistochemistry has, therefore, become an essential tool in the evaluation of such foci, especially by confirming the absence of basal cells.

## **Methodology**

### **Study design**

This study was a cross-sectional retrospective review of all cases diagnosed as prostatic carcinoma in the Department of Morbid Anatomy and Histopathology of the Ladoko Akintola University of Technology Teaching Hospital, Osogbo, Osun State, Nigeria between January 2005 and December 2014 were included in the study.

### **Study Technique**

The histologic slides were reviewed for the histological variant of prostatic carcinoma as well as the Gleason histologic grade of the tumours and the presence of High Grade Prostatic Intraepithelial Neoplasia (HGPIN). The Gleason's score was re-classified into prognostic groups A, B, and C depending on the Gleason scores. New slides were cut for immunohistochemistry and in cases where the old slides were missing, faded or broken. Immunohistochemistry was done using High Molecular Weight Cytokeratin (HMWCK), a basal cell marker, and Alpha Methyl Acyl Coa Racemase (AMACR), a marker of malignant prostatic cells. Ki-67 antibody was used to assess the proliferating index of the tumours.

Immunohistochemical studies were done by the indirect immunoperoxidase method on formalin-fixed paraffin-embedded sections (FFPE). Briefly 2-3 $\mu$ m thick sections of FFPE tissue blocks were made and mounted on charged slides. The tissue sections were deparaffinized through graded xylene and then rehydrated. The antigen was appropriately retrieved by heat retrieval method. Endogenous peroxidase activity was blocked with 3% hydrogen peroxide. The slides were then incubated with the primary antibody, rinsed and then followed up with the use of secondary detection systems using diaminobenzidine (DAB) as the chromogen. Haematoxylin was used as a counter stain to help locate the nuclei of cells. Both positive and negative controls were used. For the primary antibodies specific to the basal cells high molecular weight cytokeratin (HMWCK), were graded as Negative, or Positive.

Moreover, for the primary antibody specific for the prostatic cancer cells,  $\alpha$ -methyl acylCoA racemase (AMACR) was used and immunostaining was graded as strongly positive (grade 2) in all prostate cancers with continuous dark and diffuse cytoplasmic staining or those with a circumferential apical granular staining pattern. A focal apical pattern of staining was regarded as weakly positive (grade 1). Staining was considered negative where the cells were unstained (grade 0). Cells with little or no immune reactivity for AMACR were thus considered as benign glands. Ki-67 antibody from Novocastra was used as the proliferation marker. The staining pattern was graded as follows: 0 – Nil staining; 1 - <10% (mild staining); 2 - 10-30% (moderate staining); 3 - >30% (strong staining).

### **Data analysis**

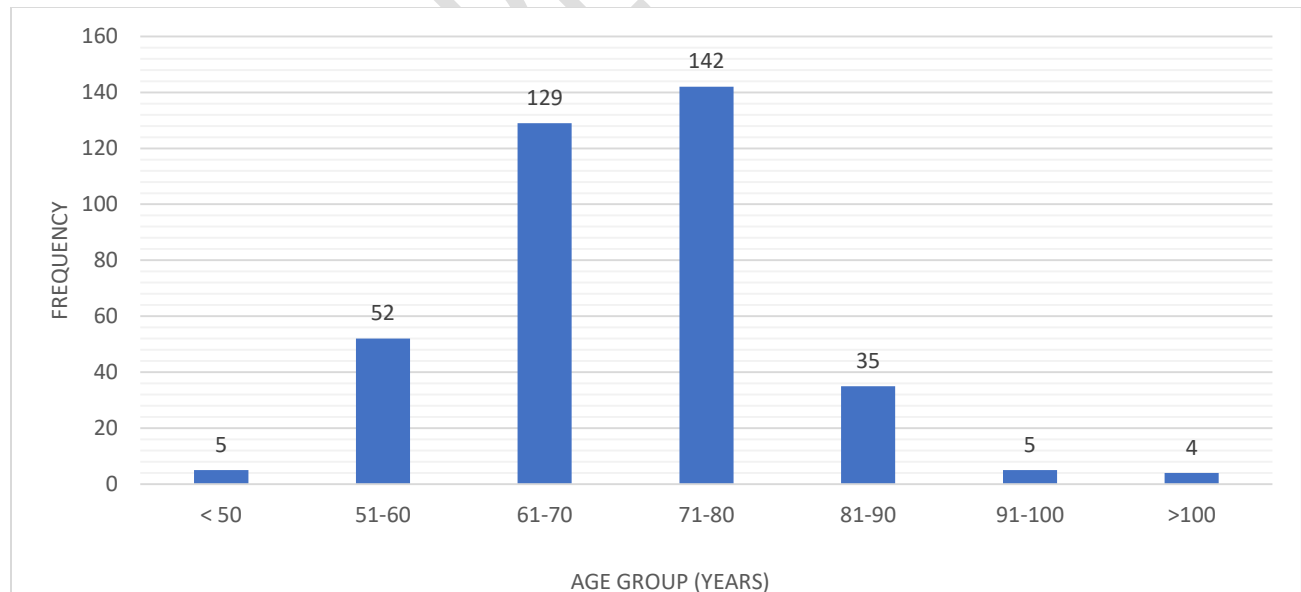
The data obtained were analyzed for differences in proportion using the Statistical Package for Social Sciences (SPSS) version 21. Chi-square was used to compare discontinuous variables. The level of statistical significance was set at  $p = <0.05$ .

## Results

A total number of 374 cases of prostatic carcinoma were diagnosed within the study period. However, only 372 were confirmed as prostatic carcinoma after immunohistochemical staining with HMWCK and AMACR. During this period, a total of 1,987 cases were diagnosed as malignant diseases out of a total of 8,517 neoplastic lesions received in the same department. Thus, prostatic carcinoma constituted 18.7% of all malignant diseases and 4.4% of all neoplastic disorders during the study period. However, other male malignancies were 300(15.1%). There were 159 (40.1%) prostatectomy samples, 221 (59.1%) prostatic biopsies and 3(0.8%) transurethral resection of prostate (TURP) samples. Surgical intervention was performed on account of benign prostatic hyperplasia (BPH) in 127 cases (35.8%) and carcinoma of the prostate (CAP) in 247 (64.2%). Most of the patients, however, patients presented with symptoms of bladder outlet obstruction.

The patients' ages ranged from 44 to 102 years. The mean age was 71.3 years  $\pm$  2.0 SD. According to figure 1, there was a steady rise in the frequency of prostatic carcinoma with each decade from the 5<sup>th</sup> decade of life up until the 8<sup>th</sup> decade from where the frequency begins a steady decline. The least frequency of cases was seen in patients older than 100 years old with 3 cases (0.8%) while the peak age frequency was the 71-80-year age group with 142 cases (38.1%). There were 129 and 52 cases in the 61 to 70-year and 51 to 60-year age groups respectively. A total of 271 cases (72.8%) were between the ages of 61 and 80 years. There were only five cases (1.3%) seen in patients younger than 50 years. No cases were recorded below the age of 40 years.

**Figure 1: Age frequency of patients with prostatic carcinoma**



mean age: 71.3  $\pm$  2.0SD

From table 1, sixty cases (16.1%) of prostatic carcinoma were completely negative for basal cells staining, 22 (21.2%) of which were moderately differentiated carcinomas while 38 (59.4%) were

poorly differentiated carcinomas and none were well differentiated. The remainder 312(83.9%) showed positive HMWCK immunoreactivity in apparently benign glands that were admixed with the negatively staining malignant glands. In this category of cases were 204 cases (54.8%) of prostatic carcinoma were well differentiated carcinomas, 82 (22.0%) were moderately differentiated and 26 (6.9%) were poorly differentiated carcinomas. The association of Gleason's histologic grade and immunoreactivity was found to be significant with a P value of < 0.005.

**Table 1: High molecular weight cytokeratin immunoreactivity and Gleason histologic grade.**

| Immunoreactivity Parameters | Geason's Histologic Grade |            |           |            |
|-----------------------------|---------------------------|------------|-----------|------------|
|                             | A                         | B          | C         | TOTAL      |
| Negative                    | -                         | 22(21.2%)  | 38(54.4%) | 60(16.1%)  |
| Positive                    | 204(100%)                 | 82(78.8%)  | 26(45.6%) | 312(83.9%) |
|                             | 204(54.8%)                | 104(27.9%) | 64(17.2%) | 372(100%)  |

(p< 0.05; Chi square= 308.466)

Out of all 374 cases diagnosed as prostatic carcinoma on H&E, only 2 (0.5%) were negative for AMACR and thus regarded as negative for carcinoma. The pattern of AMACR immunoreactivity is shown in table 2. According to this table, 187 cases (50.3%) of prostatic carcinoma showed 1+ reactivity to AMACR, 104 (55.6%) of which were well differentiated tumours and 78 (41.7%) were moderately differentiated tumours while only 5 (2.7%) were poorly differentiated carcinomas. There were 183 (49.2%) prostatic carcinomas with 2+ immunoreactivity to AMACR. Of these, 98 cases (55.6%) were well differentiated carcinomas, while 26 cases (14.2%) were moderately differentiated and 59 cases (32.4%) were poorly differentiated tumours. The association between Gleason grade and immunoreactivity for AMACR was found to be statistically significant with a p value of < 0.05 (Table 2)

**Table 2: Gleason Histologic grade and AMACR immunoreactivity**

| Gleason Histologic Grade | AMACR Immunoreactivity |            |           |            | p <0.05 ; Chi square= 370.783) |
|--------------------------|------------------------|------------|-----------|------------|--------------------------------|
|                          | -ve (%)                | 1+ (%)     | 2+ (%)    | Total (%)  |                                |
| <b>A</b>                 | 2                      | 104(55.6%) | 98(55.6%) | 206        |                                |
| <b>B</b>                 | -                      | 78(41.7%)  | 26(14.2%) | 104        |                                |
| <b>C</b>                 | -                      | 5(2.7%)    | 59(32.4%) | 64         |                                |
| <b>Total</b>             | 2 (0.5)                | 187(50.3)  | 183(49.2) | 374(100.0) |                                |

From table 3, 293 cases (78.8%) out of the 372 cases reviewed for this study showed a negative Ki-67 immunoreactivity. Out of these, a total of 204 cases (69.6%) were well differentiated carcinomas while 50 cases (17.7%) and 39 cases (13.3%) respectively were moderately and poorly differentiated tumours. Thus, none of the well differentiated tumours showed any

immunoreactivity for Ki-67. Of the moderately differentiated tumours, however, 45 (44.6%) and 6 (5.9%) respectively showed 1+ and 2+ immunoreactivity. Similarly, only 18 cases (26.9%) and 10 cases (14.9%) of poorly differentiated tumours respectively showed 1+ and 2+ immunoreactivity for Ki-67. There was a statistically significant association between the Gleason histologic grade and immunoreactivity for Ki-67 with a p-value less than 0.005 and Chi-square of 382.526. There was no 3+ immunoreactivity.

**Table 3: Gleason histologic grade and Ki-67 immunoreactivity**

| Gleason<br>Histologic<br>grade | Ki-67 Immunoreactivity |               |                |               | TOTAL      |
|--------------------------------|------------------------|---------------|----------------|---------------|------------|
|                                | -ve                    | 1+<br>(≤ 10%) | 2+<br>(10-20%) | 3+<br>(≥ 30%) |            |
| <b>A</b>                       | 204(100.0)             | -             | -              | -             | 204(100.0) |
| <b>B</b>                       | 50(49.5)               | 45(44.6)      | 6(5.9)         | -             | 101(100.0) |
| <b>C</b>                       | 39(58.2)               | 18(26.9)      | 10(14.9)       | -             | 67(100.0)  |
| <b>Total</b>                   | 293(78.8)              | 63(16.9)      | 16(4.3)        | -             | 372(100.0) |

(p<0.05; Chi square= 382.526)

## Discussion and Conclusion

Globally, prostate cancer has become the most common cancer in men with an ever increasing incidence and mortality in black African ancestry.<sup>6</sup> In fact, a report showed that prostate cancer incidence and mortality rates in Africans to be 23.2 and 17.0 per 100,000 respectively.<sup>30</sup> In Nigeria it has been shown to be the most common malignant tumour in males<sup>31</sup> This fact is further buttressed by this study which showed that prostate cancer constituted 18.7% of all malignant tumors and 4.4% of all neoplastic diseases diagnosed in our hospital. Thus, prostatic carcinoma contributes significantly to the health burden, not only in our local environment, but the entire nation at large. It therefore, becomes imperative that adequate well organized screening measures be instituted to ensure its early diagnosis as this will go a long way in ameliorating the challenges associated with the management of advanced tumours.

It is well recognized that age is a very important independent risk factor in the development of prostatic carcinoma. The disease is extremely rare before the age of 40 years but the risk increases greatly with age with more than 60% of cases diagnosed in men over the age of 65 years.<sup>25</sup> In this study, the patients ages ranged from 44 to 100 years while the mean age was 71.3 years  $\pm$  2.0 SD. The peak age incidence was found to be in the 71-80-year age group. The mean age according to this study, however, contrasts sharply with that from studies done by Oluwole et al in Lokoja, Eke et al in Port Harcourt, Osegbe in Lagos and Mohammed et al in Jos and Kano, where the mean age for patients with prostatic carcinoma was found to be 60 years.<sup>19, 30, 32, 33</sup> The reason for this disparity could possibly be due to patients in this study presented late to the hospital. Nevertheless, this disparity may actually suggest local geographic differences in the age of occurrence of prostatic carcinoma which may be due to differences in the biologic behaviour of prostatic carcinoma in our local environment. The earliest age at presentation in this study was in the fifth decade, precisely in a patient aged 44 years. This also sharply contrasts with various studies from different parts of Nigeria and Africa where the earliest presenting age was in the seventh decade.<sup>19, 32</sup>

The mean age in our study, however, is similar to that in a study carried out in the United Kingdom which put the mean age at 69 years  $\pm$  2.0 SD with a steady rise in the incidence of prostatic carcinoma from 50-54 years to a peak at 75-79 years followed by a steep decline by 80-84 years.<sup>25</sup> Similarly, our study revealed a steady rise in the incidence of prostatic carcinoma to a peak at 71-80 years followed by a sharp decline in individuals older than 80 years. This sharp decline could possibly be due to the short life expectancy in our country which has resulted in a marked reduction in the number of individuals over the age of 80 years as suggested by the Nigerian population structure.

Immunoreactivity of prostatic glands for High Molecular Weight Cytokeratin (HMWCK), even, when they appear highly suspicious histologically, typically suggests that they are benign in nature. However, a negative staining must be interpreted with caution because HMWCK is formalin sensitive and progressive loss of immunoreactivity can be seen in prolonged formalin fixation and successful immunostaining requires optimal antigen retrieval. HMWCK is known to stain basal cell in prostatic glands. These basal cells are typically absent from malignant prostatic glands but may be focally present in High Grade Prostatic Intraepithelial Neoplasia (HGPIN).

This study showed that in more than 80% of the cases the malignant glands were admixed with benign prostatic glands. In fact, this was more commonly associated with well differentiated tumours none of which was completely free of these benign glands. In two cases, however, the supposedly malignant glands were found to be benign on immunohistochemical analysis with HMWCK. This becomes especially important when assessing prostatic biopsies since benign glands could be misinterpreted as malignant for various reasons. On the other hand, well differentiated malignant glands could be misjudged as benign especially when admixed with benign glands. In addition, HMWCK positivity is typically discontinuous in a variety of benign lesions such as post atrophic hyperplasia, atypical adenomatous hyperplasia and high-grade prostatic intraepithelial neoplasia. It, therefore, becomes imperative that equivocal areas in biopsy specimens be subjected to immunohistochemistry for HMWCK in order to correctly establish their true nature. A study by Zhou et al affirms that lack of basal cells staining in supposed malignant glands should be supported by simultaneous demonstration of a positive basal cell layers in the adjacent unequivocal benign glands.<sup>15</sup> It has been shown that the application of HMWCK decreases the “atypical” diagnosis rate from 8.3% to 0.4%.<sup>12</sup>

From this study only two out of all the 374 cases histologically diagnosed as prostatic carcinoma on routine haematoxylin and eosin were found to be negative for Alpha Methyl Acyl Coa Racemase (AMACR), thus confirming their benign nature and giving a false positive rate of 0.53%. Various studies have shown similar findings.<sup>17-20</sup> A study by Herawi et al showed that 98.4% of the cases reviewed were confirmed as malignant prostatic disease after immunostaining for AMACR.<sup>8</sup> Typically, the specificity for AMACR is known to approach closely 100% while the sensitivity is about 92%.<sup>32</sup>

Thus, AMACR is considered to be a useful immunohistochemical marker for prostate cancer. However, because of non-standardized immunostaining protocols, interpretation criteria and heterogeneous staining patterns, there is a wide variation in the sensitivity and specificity of AMACR immunoreactivity in prostate biopsies. In addition, AMACR expression has been demonstrated in high-grade PIN, atypical adenomatous hyperplasia/adenosis and nephrogenic adenoma. Therefore, AMACR positivity must be evaluated with caution. It is recommended that AMACR is best restricted to the evaluation of morphologically highly suspicious foci in which negative immunoreactivity of basal cell markers alone is insufficient to establish a diagnosis of cancer. This fact is further emphasized by the very low false positive rate observed in this study.

This study showed that majority of the cases of prostatic carcinoma (78.8%) were negative for Ki-67, a proliferation marker. In addition to this, all well differentiated tumours were negative for this marker. Moreover, the less well differentiated the tumour was, the greater not only the proportion that was positive for the Ki-67 immunostain, but also the greater the proportion with higher staining intensities. These findings seem to agree with the widely held view that prostatic carcinoma is generally a slowly growing, indolent tumour especially when well differentiated. The fact that a significant proportion of the higher grade tumours in this study were still negative for the Ki-67 marker despite their poorer differentiation, seems to suggest that those tumours which are positive for Ki-67 are those more likely to show increased proliferative activity and

may, therefore, be those associated with the mutations that have been associated with poorer prognostic parameters.<sup>25-28</sup> Indeed, a study done by Cowen et al concluded that the Ki-67 marker was significantly associated with tumour stage T<sub>3</sub>/T<sub>4</sub> and Gleason's score 7-10 tumours especially when there is evidence of biochemical failure.<sup>34</sup> The Ki-67 marker may thus be a useful tool in the identification of tumours with poorer prognosis with a view to triaging them for more optimal treatment. It is concluded from this study that prostatic carcinomas are slow growing.

#### Ethical approval

Ethical approval was obtained from the ethical review committee of the Ladoke Akintola Teaching Hospital Osogbo Osun State.

## References

1. EpsteinJI, Algaba F, Allsbrook Jr WC , Bastacky S,. Boccon-Gibod AM , De Marzo AM.et al Tumours of the prostate: Pathology and Genetics of Tumours of the Urinary System and Male Genital Organs. WHO Tumours of the Urinary System and Male Genital Organs IARC Lyon 2004.
2. Meyer FJ, Gumerlock PH ,Chi SG, Borchers H ,Decters AD, Devere –White RW . Very frequent p53 mutations in metastatic prostate carcinoma and match primary tumors The Am cancer society Cancer 1998; 83(12)25394-25399
3. Roylance R, Spurr N, Sheer D The genetic analysis of prostate carcinoma. Seminars in Cancer Biology 1997, 8 37–44.
4. Meid FH, Gygi CM, Leisinger HJ, Bosman FT, Benhattar J. The use of telomerase activity for the detection of prostatic cancer cells after prostatic massage. Journal of Urology 2001; 165: 1802–1805.
5. Waghray A, Schober M, Feroze F, Yao F, Virgin J, Chen YQ. Identification of differentially expressed genes by serial analysis of gene expression in human prostate cancer. Cancer Research 2001; 61; 4283–4286.
6. Ingles Ingles SA, Ross RK, Yu MC, Irvine RA, La Pera G, Haile RW,et al. Association of prostate cancer risk with genetic polymorphisms in vitamin D receptor and androgen receptor. J Natl I Cancer Inst 1997; 89; 166–170.
7. Pisters LL, Troncoso P, Zhau HE, Li W, von Eschenbach AC, Chung LW. c-met proto-oncogene expression in benign and malignant human prostate tissues. J Urology 1995; 154: 293–298.
8. Herawi M, Parwin AV, Irie J, Epstein JL. Small glandular proliferation in needle biopsies; most benign mimickers of prostatic adenocarcinoma sent in for expert second opinion. Am J Surg Pathol 2005; 29(7): 874-80.
9. Jorda M, Morales A, Ghorab Z, Fernandez G, Nadji M, Block N. Her2NEU expression in prostatic cancer: a comparison with mammary carcinoma. J Urol 2002; 168: 1412–1414.
10. Leibovich Leibovich BC, Cheng L, Weaver AL, Myers RP, Bostwick DG Outcome prediction with p53 immunostaining after radical prostatectomy in patients with locally advanced prostate cancer. J Urol 2000; 163: 1756–1760.
11. Quinn DI, Henshall SM, Head DR, Golovsky D, Wilson JD, Brenner PC, et al. Prognostic significance of p53 nuclear accumulation in localized prostate cancer treated with radical prostatectomy. Cancer Res 2000; 60: 1585–1594.
12. Cher M., MacGrogan D, Bookstein R., Brown JA., Jenkins RB., Jensen RH. Comparative genomic hybridization, allelic imbalance, and fluorescence in situ hybridization on chromosome 8 in prostate cancer. Genes Chromosomes Cancer 1994; 11:153–162.
13. Henke RP, Kruger E, Ayhan N., Hubner D, Hammerer P, Hulan H. Immunohistochemical detection of p53 protein in human prostatic canceC J. Urol 1994; 152:1297–1301.
14. Cairns P, Okami K, Halachmni S, Halachmni N, Estellar M, .HermanJG, et.al. Frequent inactivation of PTEN/MMAC1 in primary prostate cancer. The AmJ Cancer 1997; 57: 4997-5000.
15. Menamin MC. Loss of PTEN expression in paraffin-embedded primary prostate cancer correlates with, high Gleason score and advanced stage. Cancer Res 1998; 59:4291–4296.

16. Zhou M, Jiang Z, Epstein JL. Expression and diagnostic utility of alpha-methyl acylCoA racemase (P504S) in a foamy glands pseudohyperplastic prostatic cancer. *Am J Surg Pathol* 2003; 27:772-778.
17. Cairns P, Cairns P, Okami K, Halachmi S, Halachmi N, Esteller M, Herman JG, et al. Frequent inactivation of PTEN/MMAC1 in primary prostate cancer. *Cancer Res* 1997; 57: 4997–5000.
18. Colombel M., Symmans F, Gil S, O'Toole KM., Chopin D, Benson M, et al. Detection of the apoptosis-suppressing oncoprotein bc1-2 in hormone-refractory human prostate cancers. *Am J Pathol* 1993; 143: 390-400.
19. Hockenbery DM, Zutter M, Hickey W, Nahm, Korsmeyer SJ. BCL2 protein is topographically restricted in tissues characterized by apoptotic cell death. *Proc. Natl. Acad. Sci* 1991; 88:6961–6965.
20. Raffo AJ, Perlman H, Chen MW, Day ML, Streitman JS, Buttyan R. Expression of bcl-2 protects prostate cancer cells from apoptosis in vitro and confers resistance to androgen depletion in vivo. *Cancer Res* 1995; 55:4438–4445.
21. Bubendorf L, Kononen J, Koivisto P, Schraml P, Moch H, Gasser TC, et al. Survey of gene amplifications during prostate cancer progression by high-throughput fluorescence in situ hybridization on tissue microarrays. *Cancer Res* 1999; 59:803–806.
22. Dorai T, Olsson CA, Katz AE, Buttyan R. Development of a hammerhead ribozyme against bcl-2. I. Preliminary evaluation of a potential gene therapeutic agent for hormone-refractory human prostate cancer. *Prostate* 1997;32:246–258.
23. Leav I, Plescia J, Goel HL, Li J, Jiang Z, Cohen RJ, et al, "Cytoprotective Mitochondrial Chaperone TRAP-1 As a Novel Molecular Target in Localized and Metastatic Prostate Cancer". *Am J Pathol* 2010; 176 (1): 393–401.
24. Zha J, Huang YF. TGF-beta/Smad in prostate cancer: an update. *Zhonghua Nan Ke Xue (in Chinese)* 2009; 15 (9): 840–843.
25. Senapati S, Rachagani S, Chaudhary K, Johansson SL, Singh RK, Batra SK. Overexpression of macrophage inhibitory cytokine-1 induces metastasis of human prostate cancer cells through FAK–RhoA signaling pathway. *Oncogene* 2010; 29 (9): 1293–1302
26. Watanabe SI, Miyata Y, Kanda S, Iwata T, Hayashi T, Kanetake H, et al. expression of X-linked inhibitor of apoptosis protein in human prostate cancer with or without neo-adjuvant therapy *J Cancer Res Clin Oncol* 2009;136;787-793.
27. Dimitropoulou P, Lophatananon A, Easton D, Pocock R., Dearnaley DP, Guy M. et al. The UK Genetic Prostate Cancer Study Collaborators, British Association of Urological Surgeons. Section of Oncology *BJU International*, 2009; 103: 178–185.
28. Michael F, Leitzmann MD, Elizabeth A, Platz SCD, Meior J, Stampfer MD, et al. Ejaculation Frequency and subsequent risk of prostatic cancer *JAMA* 2004;291:1578-1586.
29. Chevillat JC, Reznicek MJ, Bostwick DG. The focus of "atypical glands, suspicious for malignancy" in prostate needle biopsy specimens: incidence, histologic features, and clinical follow-up of cases diagnosed in a community practice. *Am J Clin Pathol* 1997;108:633–640.
30. Oluwole OP, Taiwo JO, Awani KU, Adugba EO. Studies on prevalence of prostate cancer in Lokoja metropolis. *Advance Tropical Medicine and Public Health International*. 2011; 2(1):15-20
31. Ekwere PD, Egbe SN: The changing pattern of prostatic cancer in Nigerians: current status in southeastern states. *J Natl Med Assoc* 2002;94:1340- 1343

32. Eke N, Saspira MK. Prostate cancer in Port Harcourt, Nigeria: features and outcome. Niger J Surg Res 2002; 4:34-44.
33. Osegbe DN. Prostatic cancer in Nigeria: facts and non facts. J Urol 1997; 157:1340-1343.
34. Cowen D, Troncoso P, Vincent S, Khoo, Gunar K, Zager S, et.al. Ki-67 staining is an independent correlate of biochemical failure in prostate cancer treated with radiotherapy. Clinical Cancer Research 2002; 8(5):275-280.

UNDER PEER REVIEW