

## Minireview Article

# The role of splenectomy in hematological diseases

Comment [DZC1]:

**Abstract:** Describe the current role of splenectomy in hematological diseases, its surgical technique, risks, and complications, and evaluate its results according to the approaches used.

**Study design:** Bibliographic review

**Materials and methods:** The Medline, PubMed, Cochrane, and Medigraphic databases were consulted using the keywords spleen, splenectomy, hematological diseases, postoperative complications, including systematic reviews, original articles, and management guidelines in this article.

**Results:** The spleen is formed in the 6th week of gestation by the dorsal mesogastric layer on the cephalic side fusing from multiple nodules. It is the largest lymphoid organ and is in the left hypochondrium, of reddish-purple color, measures between 10 and 12 cm and weighs between 150 and 200 grams. Since the first splenectomy was performed by Sutherland and Burghard, the laparoscopic approach is the reference for elective surgeries and emergency surgeries. The worldwide incidence of this surgery is reported to be 6 to 7 per 100,000 people per year. Complete laparoscopic splenectomy is currently the gold standard in both malignant and benign diseases, as in hematological disorders. There is no agreed definition of splenomegaly; however, the guidelines of the European Association of Endoscopic Surgery (EAES) consider it larger than 15cm and massive, larger than 20cm. Although there is no indication to perform it laparoscopically, it is considered that the larger the size, the greater the risk of complications. Splenectomy is the best second-line treatment in patients with hematological diseases. The most important and deadly complication in post-splenectomized patients is the so-called OPSI (overwhelming post-splenectomy infection).

**Conclusion:** Splenectomy, although it is performed in fewer numbers every day, continues to be an important tool for the treatment of hematological diseases, with minimally invasive techniques being the ones of choice.

Comment [DZC2]: A brief introduction of the topic followed by the aims of this review.

*Keywords: Spleen, Splenectomy, hematological diseases, postoperative complications.*

## Introduction:

### 1. EMBRYOLOGY AND ANATOMY:

The spleen is formed in the 6th week of gestation by the dorsal mesogastrium layer in the cephalic part, merging from multiple nodules. Hematopoietic cells of the spleen come from the yolk sac and the dorsal aorta, and in the 2nd trimester, they form erythrocytes and leukocytes that enter the bloodstream. (1)

The spleen is the largest lymphoid organ located in the left hypochondrium of the abdominal cavity. It has a purplish-red color and measures between 10 and 12 cm vertically, weighing

between 150 and 200 grams. It functions as a direct filter of the blood circulation and, under normal circumstances, cannot be palpated during physical examination. (1)

It has a connective tissue capsule and two surfaces: the diaphragmatic surface, which is smooth and convex (with impressions of the ribs), and the visceral surface, which is concave and irregular. The visceral surface contains the hilum and impressions of the stomach, kidney, and colon. The connective tissue of the capsule forms trabeculae throughout the parenchyma and contains myoepithelial cells that contract to pump stored blood into circulation when needed, such as during strenuous physical activity or severe hemorrhage. (1)

The spleen parenchyma consists of white pulp (25% of the content) composed of lymphoid tissue (T lymphocytes) and lymphatic nodules (B lymphocytes), and red pulp (75%) where the splenic venous sinuses, also called Billroth cords, are located. The red pulp also contains perisinusoidal macrophages. Both pulp types are separated by the marginal zone, which filters microorganisms to present them to lymphocytes. (1)

The spleen has a splenic artery that divides into 5 branches to form the vascular segmentation. It also has a splenic vein that joins the superior mesenteric vein to form the portal vein. Its innervation is provided by the celiac plexus, and its lymphatic drainage goes to the celiac lymph nodes. (1)

The most important functions of the spleen are the elimination of microorganisms and cellular waste, production of antigens to promote the removal of encapsulated bacteria, production of opsonins, elimination of defective erythrocytes and platelets, and serving as a reservoir for iron. In necessary cases, it can also have extramedullary hematopoietic function. (1)

## **2. SPLENECTOMY AS A PROCEDURE:**

Since the first splenectomy performed by Sutherland and Burghard, laparoscopic surgery has been increasingly used as a reference for both elective and emergency procedures, although with high conversion rates. (2)

In 1911, Emil Kocher recommended splenectomy for all splenic lesions, stating that it had no adverse effects, leading to its use in all cases. However, in 1919, Morris and Bullock observed an increased risk of infections associated with splenectomy. This finding was supported by King and Shumacker in 1952 when they reported sepsis in 5 pediatric patients who underwent splenectomy for hemolytic anemia. In 1962, a review was published on the incidence of infections in pediatric patients without a spleen, reporting a 10-fold higher risk compared to children without this surgery. (1)

The most common cause of infection in these patients is the absence of the natural filter against microorganisms and the decreased production of immunoglobulins. (1)

The worldwide incidence of splenectomy is reported to be 6 to 7 per 100,000 individuals per year, with trauma (25%) and hematological diseases (25%) being the main causes. (1)

Although splenectomy is usually performed as a treatment in most cases, it can also be used as a diagnostic and therapeutic option in patients for whom a diagnosis could not otherwise be made. Approximately 3% to 36% of splenectomies are performed for diagnostic purposes. (3)

In India, Pottakkat B et al. conducted a retrospective study from 1989 to 2004 to determine the indications for diagnostic splenectomy. They found that out of 211 patients, 39% had hematological diseases (mainly lymphoma), 34% had immune thrombocytopenic purpura, 24% had thalassemias, 17% had spherocytosis, 3% had hemolytic anemia, 3% had miscellaneous causes, and the remaining 19% underwent splenectomy for diagnostic purposes. The average age was 37 years, with 28 males and 13 females. All patients who underwent diagnostic splenectomy had an open approach. (3)

Up to 80% of cases of diagnostic splenomegaly are said to be due to malignant diseases, with lymphoma being the most frequent cause. The advantage of performing it is that, in

addition to the diagnosis, it improves the symptoms. However, it is important to know that imaging studies can sometimes be confusing in the diagnosis and may not always differentiate between hematological and non-malignant diseases. Malignant diseases sometimes present a pattern similar to that of a splenic infarction. Even today, splenectomy remains the gold standard for non-diagnostic splenomegaly. (3)

To assess the effectiveness of laparoscopic splenectomy in benign and malignant hematological diseases, a retrospective study was conducted in Belgium from 2008 to 2019, involving 50 patients. Among them, 19 belonged to the benign disease group and 21 to the malignant group, with idiopathic thrombocytopenic purpura and non-Hodgkin lymphoma being the most frequent in each group, respectively. The most common indications for surgery were thrombocytopenia (55%), anemia (26%), and symptoms (10%). The analysis showed no difference in surgical time, bleeding, conversion to open surgery, length of stay, early and late complications, or mortality. The success rate of the surgery was 83% and 79% for benign and malignant diseases, respectively, with no statistical difference, demonstrating the safety and efficiency of the technique for both types of diseases. The group with malignant diseases was found to have a higher mean age, more history of abdominal surgery, and a larger spleen size. (4)

In the case of patients with B-thalassemia, splenectomy has been observed to be detrimental to the disease. A study was conducted in Turkey to evaluate patients with thalassemia who underwent splenectomy and those who did not, along with a control group of healthy patients. There was no statistically significant difference in age and sex between the groups, but the levels of complement regulatory proteins were assessed. Patients who underwent splenectomy had lower levels of regulatory proteins and a worse outcome. (5)

The laparoscopic technique was first described in 1991 by Delaitre and Maignien. (6)

As a procedure in trauma cases, it was described 25 years ago and quickly gained importance. In 2006, Huscher et al. performed the first major series, describing anterior and semilateral approaches, achieving extraction through morcellation and a retrieval bag. (2)

Another study in 2015 compared open surgery against laparoscopic surgery in patients with splenic trauma and observed a longer operative time but with good results. (2)

However, the main difficulty and contraindication for laparoscopic splenectomy is the patient being hemodynamically unstable. (2)

It is rare to have an urgent non-traumatic indication for splenectomy, with only case reports available. Urgent indications may include splenic ischemia, rupture, torsion of the splenic pedicle, or even ectopic pregnancy with implantation in the spleen. (2)

Splenectomy can be performed in a partial form, preserving the parenchyma, which theoretically reduces patient morbidity. Reports of laparoscopic partial splenectomy for splenic rupture show good results in 21 cases. (2)

Partial splenectomy was first performed by Morgenstern and colleagues in 1980, and in 1995 it was performed laparoscopically for the first time. (7,8)

The spleen's blood supply is typically divided into 2 or 3 lobes and 3 to 5 segments, with few vascular anastomoses in the branches, providing an anatomical basis for partial splenectomy. (7)

Partial splenectomy has fewer complications, and its indications are limited to lesions in the poles or peripheral zone with a residual volume greater than 25%. However, a conversion rate to open surgery of 5% to 50% and a complete splenectomy conversion rate of 3.5% have been reported, along with longer surgical times but shorter hospital stays compared to complete resection, making it the main recommendation for pediatric patients. (7,8)

Preserving tissue generates an adequate immune response by maintaining 25-30% of the spleen. (8)

Currently, complete laparoscopic splenectomy is the gold standard for malignant, benign, and hematological disorders. (6)

However, the surgical risk can increase the morbidity and mortality of already weakened patients due to their underlying pathology. (9)

After surgery, there is an immediate reactive thrombocytosis and leukocytosis (mainly neutrophils), which usually resolves within 6 months to several years. There may also be alterations in B lymphocytes, leading to an increased predisposition to infections by gram-negative encapsulated bacteria. (1)

Factors that may cause complications during splenectomy include advanced age, thrombocytopenia, excessive bleeding, and significant splenomegaly. (9)

There is no universally agreed definition of splenomegaly; however, the European Association of Endoscopic Surgery (EAES) guidelines consider it to be greater than 15 cm and massive if greater than 20 cm. Although there is no indication for laparoscopic splenectomy based solely on size, larger spleens are associated with increased complication rates (20-60%), with a conversion rate to open surgery of 3% to 18%, primarily due to bleeding. In 1978, Goldstone defined massive splenomegaly as a spleen weighing more than 1500g or 10 times its normal weight. (6,10,11)

This is due to limited exposure and difficulty achieving adequate vascular control, which may contribute to increased bleeding. However, studies with massive spleens have shown similar results with laparoscopic procedures. (12)

Spleens weighing above 3200g or 30cm have been associated with a higher risk of conversion to open surgery. However, these patients often experience more significant improvement after splenectomy. (11)

A study in the United States observed postoperative outcomes of laparoscopic versus open splenectomy for non-traumatic diseases, assessing 30-day mortality and major morbidity in 1781 patients, with 49.1% undergoing laparoscopic and 50.9% open procedures, and 46.4% being male. The most common indication for laparoscopic splenectomy was hemolytic anemia or primary thrombocytopenia, while open splenectomy was often performed as an emergency procedure, with these patients having higher preoperative risk factors. The laparoscopy group had lower 30-day mortality and complications, along with shorter hospital stays and a lower likelihood of requiring blood transfusions during surgery, although the operative time was longer. (12)

Another study with 20 years of experience conducted in Boston, United States, evaluated elective splenectomy comparing spleens weighing over 500 grams with laparoscopic versus open surgery. They also compared conversion rates between patients with splenomegaly and massive splenomegaly (considered greater than 1 kilogram), finding no statistically significant difference (14% vs. 35%), although surgical times and readmission rates were higher in the laparoscopy group compared to the open group. (13)

Others have found higher perioperative morbidity in patients with massive spleens. However, the EAES does not recommend laparoscopy for massive splenomegaly due to the risk of complications, morbidity, and conversion rates. They suggest open or hand-assisted approaches instead. (13,14)

In light of this, a study conducted in Italy evaluated the use of laparoscopy in massive splenomegaly, collecting data from 1996 to 2017, where 175 patients underwent elective splenectomy with an average age of 47 years. The most common cause was malignant hematological disease, followed by idiopathic thrombocytopenic purpura and others. Two groups were created, one for laparoscopic and one for open procedures, and among them, they were further subdivided into normal spleen size and massive spleen size. There were 35 cases of massive spleens, 9 in the laparoscopic group and 26 in the open group, while 133 patients underwent laparoscopic splenectomy. In the laparoscopy group, statistically significant longer operative times and less intraoperative bleeding were observed, along with shorter hospital stays. Only 6 patients required conversion to open surgery, mainly due to bleeding, and only 1 due to advanced malignancy. There were 38 complications in 30 patients, with bleeding being the most common postoperative complication, with no significant difference between the groups. The overall mortality was 3.4%, all due to hematological neoplasms, and only 1 patient with Non-Hodgkin lymphoma died due to post-splenectomy sepsis, with no statistically significant difference between the groups. Among

laparoscopic splenectomies with massive spleens, there were no differences in outcomes between the groups to which they belonged. In conclusion, the feasibility of laparoscopy in cases of massive splenomegaly was supported. (14)

A prospective study conducted in China evaluated the use of hand-assisted laparoscopic splenectomy versus pure laparoscopic splenectomy from 2014 to 2017 in 91 patients with splenomegaly. There were no differences in sex, age, spleen diameter, or Child Pugh grade. Hand-assisted laparoscopic surgery was found to be shorter with less intraoperative bleeding, along with lower hospital expenses and a lower conversion rate. There were no differences in hospital stay and complications. The average maximum diameter in each group was 23.5cm for hand-assisted laparoscopic and 22.7cm for pure laparoscopic. The study concluded that hand-assisted laparoscopy maintains the advantages of laparoscopy. (15)

Although not the first-line treatment in hematological pathologies, if required, splenectomy is a unique measure currently associated with a mortality rate of up to 0%. Furthermore, it reduces morbidity, especially with vaccinations for encapsulated infections. (16)

A study in India, conducted at a tertiary-level hospital, evaluated the overall response to splenectomy at 30 days in patients with immune thrombocytopenic purpura, achieving an adequate response in terms of a platelet count greater than or equal to 30,000 or double the previous count without symptoms. The study included 45 patients who underwent splenectomy over a 20-year period, with only 9 surgeries performed in the last 10 years, observing a response rate of 89% at 5 years. (16)

In these patients, splenectomy is considered the best second-line treatment, in addition to being cost-effective. However, its frequency is expected to decrease due to advancements in medications. (16)

For idiopathic thrombocytopenic purpura, it has been found that splenectomy yields an initial response of over 90% in platelet counts in the short term and up to 100% in the long term. Moreover, the long-term effects are comparable between open and laparoscopic surgery, although some studies have reported short-term response rates ranging from 79% to 90% and long-term rates of only 66%. (6,17)

In the case of idiopathic thrombocytopenic purpura, the spleen is typically of normal size with normal vasculature, usually not associated with any coagulopathy. This makes the spleen useful for initiating the necessary surgical curve to achieve adequate results. (17)

It is essential to note that idiopathic thrombocytopenic purpura can be associated with pregnancy in up to 5% of cases. The American Society of Hematology considers surgery in these cases when the disease is refractory or bleeding occurs with platelet counts below 10,000, weighing the risks against the benefits, as the remission rate with medical treatment is less than 25%. (18,19)

Younger age in splenectomized patients predicts a better response to surgery, although not all reviews have observed this. (16)

A retrospective study was conducted in Poland to assess prognostic factors for remission after splenectomy in patients with idiopathic thrombocytopenic purpura. The study included 165 patients from 1998 to 2017 at a third-level hospital. There was no difference in gender between the groups, but the patients who achieved remission were significantly younger (under 41 years old) and had a BMI less than 24.3. Moreover, they had a preoperative platelet count greater than 97,000, which were independent factors. The study found no difference in disease duration and response to splenectomy, recommending splenectomy in patients who still respond to medical treatment for better results. (19)

One reported complication of splenectomy is venous thromboembolism, which can occur in 10-16% of cases. (16)

A study in Taiwan assessed the risk of cancer in splenectomized patients compared to a population of 4,898 and a group of 19,592 non-splenectomized individuals. The male gender had a 1.94 times higher likelihood of developing cancer in splenectomized patients compared to non-splenectomized patients. Depending on the cause of splenectomy,

different types of cancer were more frequent. Non-trauma-related splenectomies had a higher risk of esophageal, gastric, liver, and leukemia cancers, with the most common cancer being non-Hodgkin lymphoma, with a risk up to 15 times higher. Although the association is not clear, it is believed to be related to immunity due to the lack of immunological surveillance in splenectomized patients. (20)

In the case of sickle cell disease, an autosomal recessive genetic disorder, red blood cells become distorted, causing obstruction of small blood vessels and tissue damage, in addition to rapid elimination in the circulation by the spleen, leading to anemia. This condition is called splenic sequestration, defined by a drop of 2g/dL of hemoglobin and an enlarged spleen, which can occur acutely or chronically, also known as hypersplenism. It is said to be the second leading cause of death in the first decade of life, accounting for 14-44% of deaths in this period. (21)

The death rate of patients with a recurrence of the first attack in acute splenic sequestration is 20%. Its management includes blood transfusions and splenectomy. (21)

However, the use of transfusions, in addition to being costly and time-consuming, has adverse effects such as antibody formation, iron overload, blood infections, and allergic reactions. (21)

Unlike transfusion, splenectomy has the advantage of relieving the pain caused by splenomegaly. (21)

Infections caused by *Staphylococcus aureus*, *Haemophilus influenzae*, and *Streptococcus pneumoniae* (the most common cause with a mortality rate of up to 60%), as well as malaria, are more frequent in these patients. Patients who are asplenic are particularly vulnerable to infections, mainly caused by encapsulated organisms, which are more resistant to phagocytosis. The most significant and life-threatening complication post-splenectomy is called OPSI (overwhelming post-splenectomy infection). (1)

Other bacteria responsible for this condition include *Pseudomonas aeruginosa*, *Capnocytophaga canimorsus*, *Bartonella* spp., *Babesia* spp., and *Escherichia coli*. (1)

OPSI occurs within 24 to 48 hours after surgery, usually starting as a flu-like illness, followed by a deterioration in function, leading to fulminant septic shock with disseminated intravascular coagulation. It occurs in 0.1 to 0.5% of cases of splenectomy, but it has been reported in up to 4% of total splenectomy cases, with a mortality rate of up to 50%. The risk is higher in the first 3 years but continues throughout life, with pediatric patients, trauma surgery, cancer surgery, malignant hematological diseases, and immunocompromised patients being at higher risk. (1,8)

For the diagnosis of OPSI, blood cultures must be obtained, and empirical antibiotic management should be initiated, along with the use of corticosteroids due to the risk of causing bilateral adrenal hemorrhage. (1)

The British Committee for Standards in Hematology has established guidelines to prevent and treat infections in asplenic patients. (1)

Antibiotic prophylaxis is recommended after splenectomy in patients under 16 years old and over 50 years old with a history of invasive pneumococcus, surgery due to malignant hematological diseases, cancer, and thalassemia, during the first year after surgery, sickle cell anemia, and poor response to the 23-valent pneumococcal vaccine. (1)

It is usually initiated with daily amoxicillin-clavulanate, trimethoprim, or cefuroxime. (1)

Additionally, vaccination against pneumococcus, meningococcus, *Haemophilus influenzae* type B, and influenza is recommended due to the lower incidence of infections in vaccinated patients, either before or after surgery, on the day of discharge, or at day 14, with booster shots recommended every 3 to 5 years. Some also recommend revaccination 2 months after the initial dose for meningococcus and pneumococcus. (1,21)

Owusu O. & Remington T. (21) conducted a Cochrane review in the United Kingdom in 2015 to assess whether splenectomy performed for acute splenic sequestration improved survival and reduced morbidity in patients with sickle cell disease compared to blood transfusion. However, they found insufficient evidence to support the use of splenectomy to

improve survival and morbidity in these patients, with only some case series not providing sufficient strength to make any recommendations.

Acute splenic sequestration crisis is a significant complication causing mortality in pediatrics with sickle cell disease. Red blood cells get trapped in the spleen, causing splenomegaly, anemia, and intense abdominal pain. This condition can occur in up to 30% of children under 5 years old, with a mortality rate of up to 12% in the first episode, 50% experiencing a second episode, and a mortality rate of up to 20% for subsequent episodes. (22)

Alkhatrawi, T., & Elsherbini, R. (2020) recommend treating acute splenic sequestration with blood transfusions while scheduling elective splenectomy, which is generally recommended for children over 5 years old. However, the risk of post-splenectomy sepsis is up to 5% according to some data, but it can reach up to 10% in pediatric cases. Although vaccination against encapsulated organisms has reduced this incidence, the exact figure is still unknown, with the highest risk occurring within the first 2 years after splenectomy. Additionally, prophylaxis with penicillin is recommended for 10 years. (22)

Several reviews have not found a difference in the incidence of sepsis in patients with or without a spleen and recommend splenectomy in pediatric cases of sickle cell disease, which has shown good results without an increase in complications. (22)

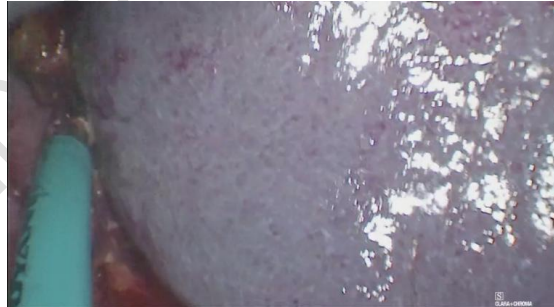The main indications for splenectomy in pediatric cases of sickle cell disease are hypersplenism and episodes of acute splenic sequestration, often requiring surgery if there are 2 attacks, generally in children over 5 years old, except when splenomegaly exceeds 10cm. (22)

Pediatric splenectomy is usually performed as a scheduled procedure, but there have been reported cases of emergency surgery in selected cases. For this reason, a retrospective study was conducted in Germany showing 12 cases of non-traumatic urgent splenectomy from 2000 to 2015, all related to hematological diseases. The urgent surgeries were performed due to the high mortality rate in these patients. Currently, the only indication for urgent surgery is persistent bleeding with low platelet counts. (23)

Perioperative steroids are recommended in cases where steroids have been used in the previous year to prevent acute adrenal insufficiency. (17)

### 3. SURGICAL TECHNIQUE:

Laparoscopic splenectomy technique: (6,17,22,24)



**Fig. 1. Laparoscopic Splenectomy. Source: Direct.**

1- Patient positioned in right lateral decubitus at 30° to 60°, in Anti-Trendelenburg, with or without a roll under the right torso, or in supine position. It has been observed that the lateral approach has resulted in shorter surgical time, less blood loss, and fewer complications. (24)

2- Surgery is recommended to be performed using the French technique. (24)

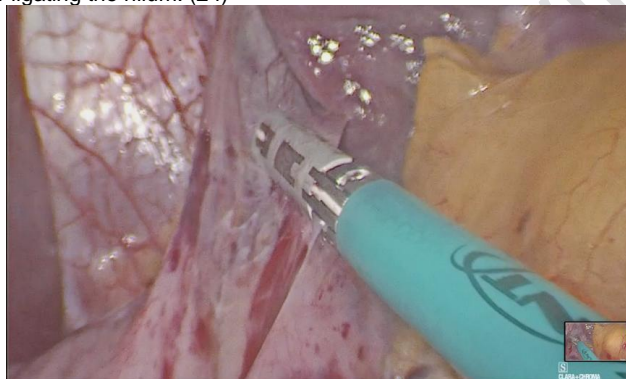
3- It is recommended to bend the right knee and keep the left leg straight to increase the surgical field. (24)

4- Placement of 3, 4, or 5 ports in supine position, one 10mm port in the left paraumbilical or umbilical region, one midline port between the umbilicus and xiphoid process, one subxiphoid port, one subcostal port in the anterior axillary line, and one mid-clavicular and middle or posterior axillary port, the latter two to be inserted as needed based on spleen size, with a lower insertion point required for significant splenomegaly. (25)

Another way to position the ports in the lateral approach is to place the first trocar 2cm below the costal margin in the anterior axillary line and follow the costal margin for placement of the remaining ports. (25)

5- Diagnostic laparoscopy is performed to identify any accessory spleens, if present, they are removed.

6- Ligament release, the most important being the short gastric vessels, which can cause bleeding, while not forgetting to section the splenocolic and phrenocolic ligaments to achieve sectioning of the splenorenal ligament, the splenodiaphragmatic ligament can be dissected before or after ligating the hilum. (24)



**Fig. 2. Dissection of the gastro-splenic ligament with advanced bipolar energy.**  
**Source: Direct.**

7- Dissect and ligate the splenic hilum, either with sutures or a vascular stapler. However, good results have been found with the use of advanced bipolar electrocautery for vessels up to 7mm, performing electrocoagulation or stapling 1-2cm away from the spleen. (24, 25)

One recommendation is to separately section both the artery and the vein or place a clip on the artery before sectioning the hilum to avoid the risk of arteriovenous fistulas. (25)

After obtaining vascular control of the splenic artery, the flow in the vein rapidly decreases, with a diameter of 1-2mm, making it easily manageable for stapling. (25)

Furthermore, ligating the artery first results in less manipulation in cases of very large spleens, as the blood is transfused back into circulation before ligating the venous return, providing some decompression. (11)

8- Remove the spleen within a plastic bag and extract it in a morcellated manner if possible, as it leads to better postoperative pain outcomes compared to the suprapubic incision. However, in cases of malignant disease, the entire specimen should be extracted. (24)

Intraoperative blood transfusion rates of 18% have been reported. (11)

The risk of splenic rupture with subsequent formation of splenic implants in the abdomen is infrequent in cases of splenectomy for symptoms. However, in cases of hemolytic anemia or idiopathic thrombocytopenic purpura, it can cause recurrence of the disease. (17, 25)

To evaluate the use of robotic surgery, a retrospective Italian single-center study was conducted to compare it against laparoscopy in diagnosing splenomegaly, including 39 patients operated between 2000 and 2017, with 27 undergoing laparoscopy and 12 robotic surgery. There was no difference in age between the groups, but the ASA classification was significantly higher in the laparoscopic group, with 3 points compared to 2 in the robotic group. The surgical time was significantly longer in the robotic group (270 minutes vs. 180 in the laparoscopic group), as well as the amount of bleeding, which was lower in the robotic group (100mL vs. 350mL), with statistical significance. There was no statistically significant difference in the conversion rate, morbidity, or mortality between the groups; however, this could be due to the small cohort size. It can be concluded that robotic approach is safe and comparable to laparoscopy; however, it continues to have longer surgical times due to the learning curve for the surgeons. (26)

#### 4. POST-SURGICAL COMPLICATIONS:

Due to the increasing risk of complications and potential increase in mortality in patients undergoing splenectomy, a retrospective study of splenectomies for hematological diseases, both benign and malignant, was conducted in California, United States, from 2009 to 2018 in adults. The mean weight of the spleen was 306.5g, and it was statistically higher in cases of malignant diseases, with open surgery, hand-assisted procedures, and conversions more frequently observed in this group. In the sample, 20% required intraoperative blood transfusion due to anemia, thrombocytopenia, or intraoperative bleeding. The mean length of hospital stay was 2 days, which was statistically higher in patients with malignant diseases. There was no difference in the incidence of complications between benign and malignant diseases, and no difference was found in the use of thromboprophylaxis. Mortality was significantly more frequent in patients with malignant diseases; however, it was not related to the surgery. On multivariate analysis, no demographic factors were associated with higher complications, but age was associated with higher mortality after surgery in benign diseases and thrombocytopenia in malignant diseases. (27)

The laparoscopic splenectomy is recommended even in patients with massive splenomegaly and concerning thrombotic medical treatment alone can be considered as a low-risk option, 67% will improve with this approach. (27)

The risk of thrombosis is believed to be due to the acute increase in platelets and the subsequent decrease in portal flow after splenectomy, in addition to the enlargement of the portal system (2 to 10% of patients), and meta-analyses have shown a decrease in portal thrombosis. (4, 27, 28)

To investigate this, a study was conducted in Australia evaluating patients who underwent splenectomy for all reasons from 1998 to 2006, assessing thrombotic events that occurred after 30 days. The study included 2473 patients, with 61.7% over 50 years old. It was found that 5.74% of patients had an event that required hospitalization, with age being the most important risk factor, with those over 50 years old having 2.76 times more likelihood of developing thrombosis compared to those under 50 years old. There was no difference in the cause of splenectomy. However, in other studies, it has been found that patients undergoing surgery for idiopathic thrombocytopenic purpura were at a higher risk. (29)

Thrombosis sites can occur in the lower and upper extremities, causing deep vein thrombosis, pulmonary thromboembolism, splenic vein, and portal thrombosis. (30)

In some series, prophylactic use of subcutaneous heparin for 1 month is recommended to prevent possible portal thrombosis after surgery. (25)

Older studies have mentioned the use of angiographic ablation before surgery; however, it was discontinued due to the intense pain it caused, as well as the risk of thrombosis. (17)

Other well-known complications include intraoperative bleeding in up to 5% and pancreatic fistula in up to 7%. (25)

During splenectomy, platelet transfusion, if needed (generally in counts below 50,000), is recommended to be performed after ligation of the splenic vessels; however, it is noted that there is no difference in performing it at that time or during anesthesia induction. (28)

## CONCLUSION

Splenectomy, despite being performed less frequently nowadays, remains an important treatment option for hematological diseases. Minimally invasive techniques are preferred due to their superior outcomes and fewer complications. However, patients must receive timely prophylactic treatment to prevent infections with high mortality rates.

## CONSENT

Formal informed consent is not required for this study.

## REFERENCES

1. Tahir F, Ahmed J, Malik F. Post-splenectomy Sepsis: A Review of the Literature. *Cureus*. 2020 Feb 6;
2. Sandri GBL, Spoletini D, Lamacchia G, Carlini M. Emergency splenectomy: is there a role for laparoscopy? Vol. 7, *Annals of Laparoscopic and Endoscopic Surgery*. AME Publishing Company; 2022.
3. Pottakkat B, Kashyap R, Kumar A, Sikora SS, Saxena R, Kapoor VK. Redefining the role of splenectomy in patients with idiopathic splenomegaly. *ANZ J Surg*. 2006 Aug;76(8):679–82.
4. Cadiere B, Grilli A, Bron D. Comparison of Laparoscopic Splenectomy Outcomes for Benign and Malignant Hemopathies. *Journal of Laparoendoscopic and Advanced Surgical Techniques*. 2020 Nov 1;30(11):1172–6.
5. Kurtoğlu AU, Koçtekin B, Kurtoğlu E, Yildiz M. The effect of splenectomy on complement regulatory proteins in erythrocytes in b-thalassemia major. *Archives of Medical Science*. 2019;15(1):191–5.
6. Kim-Koh MJ, Souza-Gallardo LM, Navarro MM. Esplenectomía laparoscópica como tratamiento para la púrpura trombocitopénica idiopática y la esplenomegalia masiva en un hospital de segundo nivel.
7. Bing Y, Sadula A, Xiu D, Yuan C. Laparoscopic middle segment splenectomy for central splenic hemangioma: A case report. *Int J Surg Case Rep*. 2020 Jan 1;77:925–9.
8. Esposito F, Noviello A, Moles N, Cantore N, Baiamonte M, Coppola Bottazzi E, et al. Partial splenectomy: A case series and systematic review of the literature. *Ann Hepatobiliary Pancreat Surg*. 2018;22(2):116.
9. Bickenbach KA, Gonen M, Labow DM, Strong V, Heaney ML, Zelenetz AD, et al. Indications for and efficacy of splenectomy for haematological disorders. *British Journal of Surgery*. 2013 May;100(6):794–800.
10. Spoletini D, Lisi G, Sandri GBL, Grieco M, Marcellinaro R, Sorrentino F, et al. Technique of laparoscopic splenectomy. *Ann LaparoscEndosc Surg*. 2020 Jul 20;5(July).
11. Lemaire J, Rosière A, Bertrand C, Bihin B, Donckier JE, Michel LA. Surgery for massive splenomegaly. *BJS Open*. 2017 Feb;1(1):11–7.
12. Musallam KM, Khalife M, Sfeir PM, Faraj W, Safadi B, Saad GSA, et al. Postoperative outcomes after laparoscopic splenectomy compared with open splenectomy. *Ann Surg*. 2013 Jun;257(6):1116–23.
13. Shin RD, Lis R, Levergood NR, Brooks DC, Shoji BT, Tavakkoli A. Laparoscopic versus open splenectomy for splenomegaly: the verdict is unclear. Vol. 33, *Surgical Endoscopy*. Springer New York LLC; 2019. p. 1298–303.

14. Casaccia M, Sormani MP, Palombo D, Dellepiane C, Ibatici A. Laparoscopic Splenectomy Versus Open Splenectomy In Massive and Giant Spleens: Should we Update the 2008 EAES Guidelines? [Internet]. 2019. Available from: [www.surgical-laparoscopy.com](http://www.surgical-laparoscopy.com)
15. Sun X, Liu Z, Selim MH, Huang Y. Hand-assisted Laparoscopic Splenectomy Advantages Over Complete Laparoscopic Splenectomy For Splenomegaly [Internet]. 2019. Available from: [www.surgical-laparoscopy.com](http://www.surgical-laparoscopy.com)
16. Mishra K, Kumar S, Sandal R, Jandial A, Sahu KK, Singh K, et al. Original Article Safety and efficacy of splenectomy in immune thrombocytopenia [Internet]. Vol. 11, Am J Blood Res. 2021. Available from: [www.AJBlood.us/](http://www.AJBlood.us/)
17. Schlinkert RT, Teotia SS. Laparoscopic Splenectomy [Internet]. Vol. 134, Arch Surg. 1999. Available from: <http://archsurg.jamanetwork.com/>
18. Thapar PM. Laparoscopic Splenectomy in Pregnancy-A Rescue Operation for Refractory Immune Thrombocytopenia: A Case Report OPEN ACCESS [Internet]. Vol. 6, Remedy Publications LLC., | World Journal of Surgery and Surgical Research. 2023. Available from: <http://surgeryresearchjournal.com>
19. Kwiatkowska A, Radkowiak D, Wysocki M, Torbicz G, Gajewska N, Lasek A, et al. Prognostic factors for immune thrombocytopenic purpura remission after laparoscopic splenectomy: A cohort study. *Medicina (Lithuania)*. 2019 Apr 1;55(4).
20. Sun LM, Chen HJ, Jeng L Bin, Li TC, Wu SC, Kao CH. Splenectomy and increased subsequent cancer risk: A nationwide population-based cohort study. *Am J Surg*. 2015 Aug 1;210(2):243–51.
21. Owusu-Ofori S, Remington T. Splenectomy versus conservative management for acute sequestration crises in people with sickle cell disease. Vol. 2017, *Cochrane Database of Systematic Reviews*. John Wiley and Sons Ltd; 2017.
22. Alkhatrawi T, Elsherbini R, Turkistani W. Laparoscopic splenectomy in children with sickle cell disease younger than 5 years old. *Annals of Pediatric Surgery*. 2020 Dec 1;16(1).
23. Samuk I, Segulier-Lipszyc E, Baazov A, Tamary H, Nahum E, Steinberg R, et al. Emergency or urgent splenectomy in children for non-traumatic reasons. *Eur J Pediatr*. 2019 Sep 1;178(9):1363–7.
24. Spoletini D, Lisi G, Sandri GBL, Grieco M, Marcellinaro R, Sorrentino F, et al. Technique of laparoscopic splenectomy. *Ann LaparoscEndosc Surg*. 2020 Jul 20;5(July).
25. Mutter D. Laparoscopic splenectomy: conventional technique and challenges. Vol. 4, *Laparoscopic Surgery*. AME Publishing Company; 2020.
26. Cavaliere D, Solaini L, Di Pietrantonio D, D'Acapito F, Tauceri F, Framarini M, et al. Robotic vs laparoscopic splenectomy for splenomegaly: A retrospective comparative cohort study. *International Journal of Surgery*. 2018 Jul 1;55:1–4.
27. Alobuia WM, Perrone K, Iberri DJ, Brar RS, Spain DA, Forrester JD. Splenectomy for benign and malignant hematologic pathology: Modern morbidity, mortality, and long-term outcomes. *Surg Open Sci*. 2020 Oct 1;2(4):19–24.
28. Bendaña JE, Salinas-Vallecillo LC. Laparoscopic splenectomy in patient with Evans syndrome. Vol. 45, *Revista Mexicana de Anestesiología*. Colegio Mexicano de Anestesiología A.C.; 2022. p. 135–7.
29. Dendle C, Spelman T, Sundararajan V, Chunilal S, Woolley I. An analysis of the thromboembolic outcomes of 2472 splenectomized individuals. Vol. 125, *Blood*. American Society of Hematology; 2015. p. 1681–2.
30. Szasz P, Ardestani A, Shoji BT, Brooks DC, Tavakkoli A. Predicting venous thrombosis in patients undergoing elective splenectomy. *Surg Endosc*. 2020 May 1;34(5):2191–6