

**Case report**

**Oral Squamous Cell Carcinoma of the Mandible  
with Management of Wide Excisi, Right  
Hemimandibulectomy, Mandibular  
Reconstruction, and Pectoralis Major  
Myocutaneous Flap: A Rare Case Report**

---

**ABSTRACT**

**Aims:** To report the case of man diagnosed with mandibular mucogingival SCC and present its case details, histopathological findings, and management.

**Presentation of Case:** A 35-year-old man with complaints of lumps and wound on the right side of the face that has been getting bigger since 9 months ago. The lump initially appeared the size of a marble on a loose tooth mark, then quickly grew to the size of tennis ball within a month. Physical examination revealed mass in the facial and colli region, ulcerated, solid, fixed, multiple masses of varying size. The first biopsy examination showed epulis pyogenicum, an interval of one month, the biopsy examination showed well-differentiated squamous cell carcinoma. The patient was treated with Mandibular Reconstruction surgery, Pectoralis Major Myocutaneous Flap, Wide Excision, and Hemimandibulectomy Dextra.

**Discussion:** Clinically, the possibility of misdiagnosing can occur due to various manifestations. SCC of the gingiva is often asymptomatic and the initial symptoms are usually an intraoral mass or swelling, ulceration, pain, ill-fitting dentures, tooth mobility or an extraction wound that does not heal. These tumors often resemble inflammatory lesions affecting the periodontium. Treatment of squamous cell carcinoma is mainly surgical excision followed by radiation therapy and chemotherapy as additional postoperative treatment modalities.

**Conclusion:** Squamous cell carcinoma is the most common malignant neoplasm of the oral cavity with various oral presentations. Correct and timely diagnosis is utmost importance and there is more possibility of misdiagnosis because the clinical presentation of oral squamous cell carcinoma can mimic gingival inflammatory lesions.

*Keywords: squamous cell carcinoma, mandibular, gingiva, oral*

## 1. INTRODUCTION

Various types of cancer develop in the mouth and maxillofacial (maxillofacial) area. Oral squamous cell carcinoma (OSCC) is the most common oral cancer with a variable clinical presentation accounting for up to 95% of all cancers in this anatomical location. It most commonly occurs on the tongue (40% of cases) and floor of the mouth (30%). Other sites include the buccal mucosa, gingiva, palate, and retromolar area [1–3]. Less commonly involved is the gingiva, which comprises about 10% of all OSCCs [4].

In recent years, the male-to-female ratio has changed from 5:1 to 2:1. This is related to the increasing number of women who smoke. The main risk factors for oral cancer include tobacco smoking, alcohol abuse, HPV infection, Epstein-Barr virus (EBV) infection, candidiasis, precancerous lesions, industrial pollution, occupational hazards, inadequate oral hygiene, improper dental prostheses, diet low in vitamins, fruits and vegetables, UV radiation exposure, pale skin, immunological defects and Plummer-Vinson syndrome [5,6].

These tumors usually occur in edentulous areas, although they can also develop in dentate areas. It is generally agreed that mandibular gingival carcinoma is more common than maxillary gingival carcinoma and 60% of these are located posterior to the premolars. The clinical presentation of gingival SCC can vary widely and therefore may be misdiagnosed as a benign tumor or other inflammatory response [4]. Here we report the case of a man diagnosed with mandibular mucogingival SCC. We present case details, histopathological findings, and management.

## 2. PRESENTATION OF CASE

A 35-year-old man came with complaints of lumps and sores on the right side of his face that had been getting bigger since 9 months ago. The lump initially appeared the size of a marble on a loose tooth mark, then quickly grew to the size of a tennis ball within a month. The lump does not bleed easily and is not painful, but the patient becomes difficult to eat and drink.

The patient has a history of biopsy and anatomical pathological examination with the results of Epulis Pyogenicum and excision was carried out in February 2021. The patient has a history of 6 times chemotherapy with Cisplatin 100 mg and Epirubicin 80 mg. The patient complained of the lump getting bigger after the 4th chemotherapy and forming a wound, then the patient was referred to the Surgical Oncology poly. The patient has lost 10 kg in weight in the last two months.

The patient's vital signs showed blood pressure 88/66 mmHg, pulse 108 beats/minute, breath 20 breaths/minute, temperature 36.7°C. The patient's body mass index was in the underweight category (18.36 kg/m<sup>2</sup>, weight: 50 kg; TB: 165cm). On examination of the thorax, abdomen, and extremities, there were no abnormalities. The patient's right and left conjunctiva looked pale. In the right facial region, an intraoral mass appeared infiltrating the right maxilla, buccal and submandibular masses, ulceration, solid mass fixed, well defined, lumpy, size 15 x 12 x 10 cm. In the right colli region, there was a mass at level 2, a fixed solid mass, multiple, with the largest size 2 x 1 x 1 cm.

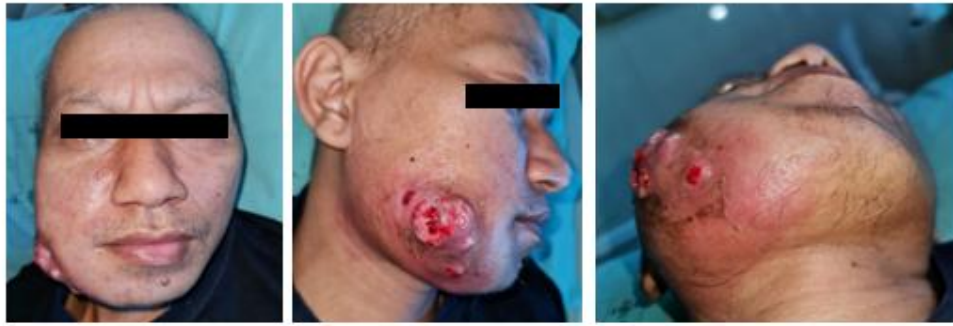

Fig. 1. Clinical Picture of the Patient in March 2021

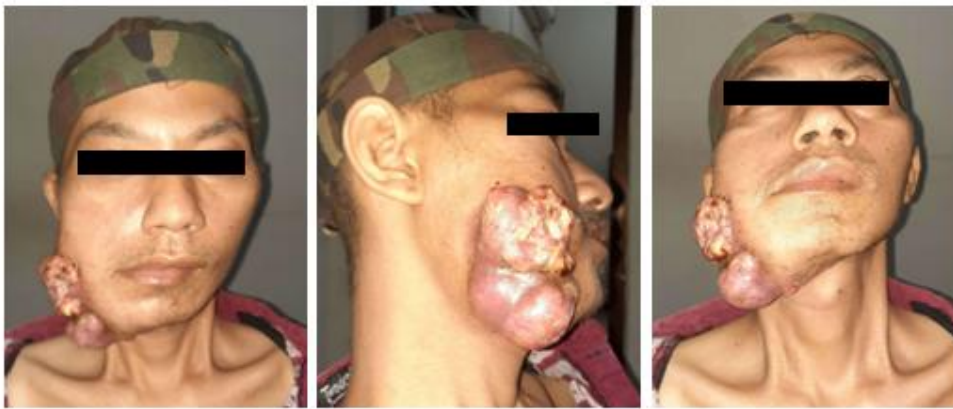

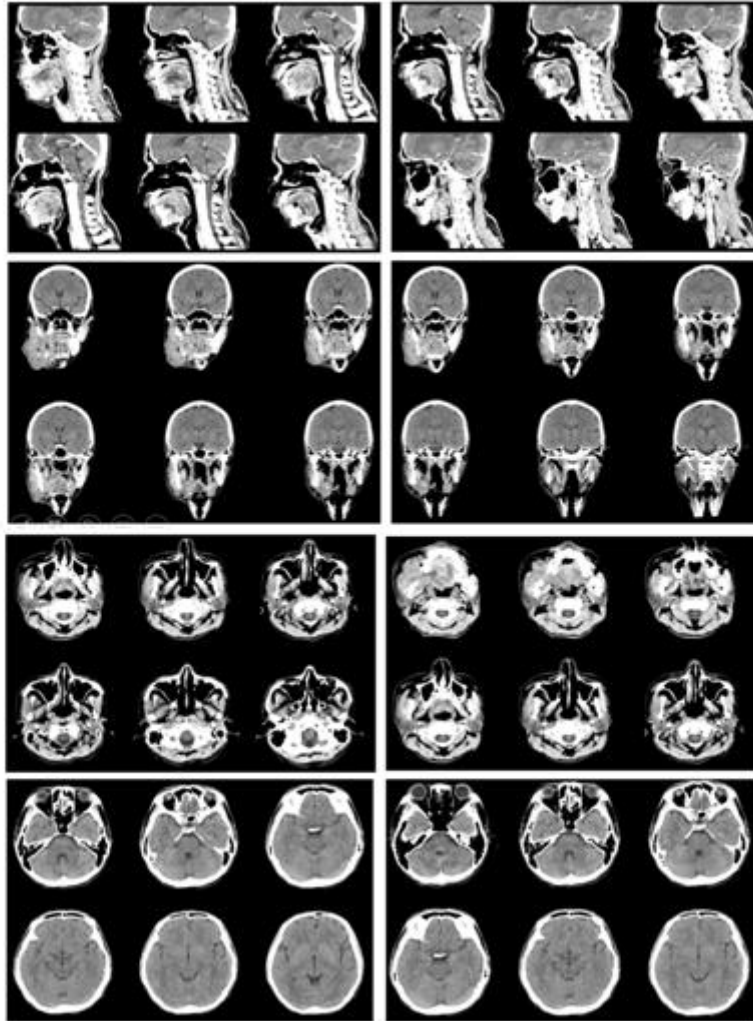
Fig. 2. Clinical Picture of the Patient in October 2021

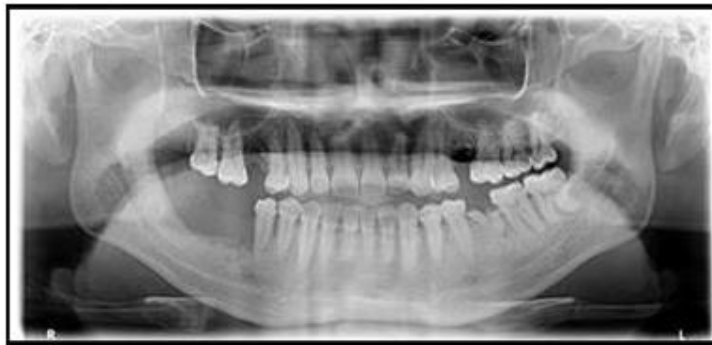

Fig. 3. Panoramic X-Ray Picture

In March 2021, another biopsy was performed with the results of anatomical pathology showing an image of tumor tissue fragments arranged solidly consisting of pleomorphic squamous epithelial cells, scanty cytoplasm, a nucleus with coarse chromatin and prominent nucleoli, abundant mitoses were found, and an image of horn pearls was obtained. Leads to well-differentiated squamous cell carcinoma.

Examination of the chest plain X-ray appeared normal. A CT scan of the head with contrast in October 2021 showed a mass of the right submandibular gland accompanied by air and intralesional fluid components with an air-fluid level picture that destroyed the body to the symphysis of the right mandibular bone, infiltrating the Right pterygomandibular muscle, Right platysma muscle, Right masseter muscle, Right angular depressor muscle, extending to the right buccal region and right oris cavity. There were also multiple lymphadenopathy in bilateral colli, bilateral submandibular and sublingual, conchae bullosa on the left middle nasal conchae, left ethmoidal rhinosinusitis, and cervical spondylosis.



**Fig. 4. MSCT Head with Contrast**

Laboratory examination in October 2021 showed low hemoglobin (8.7 g/dl, normal: 13.5-17.5 g/dl), low hematocrit (26%, normal: 33-45%), high leukocytes (12.1 thousand/ul, normal: 4.500-11.000/ul), normal platelet (289.000/ul, normal: 150.000-450.000/ul), low erythrocyte (2.88 million/ul, normal: 4.5- 5.9 million/ul). The patient's current blood glucose, creatinine, and urea were normal. The patient's PT, APTT, and INR values were normal.

The patient was diagnosed with Squamous Cell Carcinoma Mucogingiva Mandibular Dextra and Anemia. The patient was given a PRC 2 kolf transfusion and was scheduled to undergo Pro Wide Excision, Right Hemimandibulectomy surgery, Mandibular Reconstruction, and Pectoralis Major Myocutaneous Flap.

After surgery, the patient was given 0.9% NaCl infusion, Ampicillin injection 1 gr/8 hour, Metronidazole injection 500 mg/8 hour, Ketorolac injection 30 mg/8 hour, Omeprazole injection 40 mg/8 hour, Tranexamic Acid injection 500 mg/8 hour. Laboratory results after surgery showed low hemoglobin (12.4 g/dl, normal: 13.5-17.5 g/dl), normal hematocrit (36%,

normal: 33-45%), high leukocytes (17.700/ul, normal: 4.5-11.000/ul), normal platelet (289.000/ul, normal: 150.000-450.000/ul), low erythrocyte (4.18 million/ul, normal: 4.5- 5.9 million/ul).

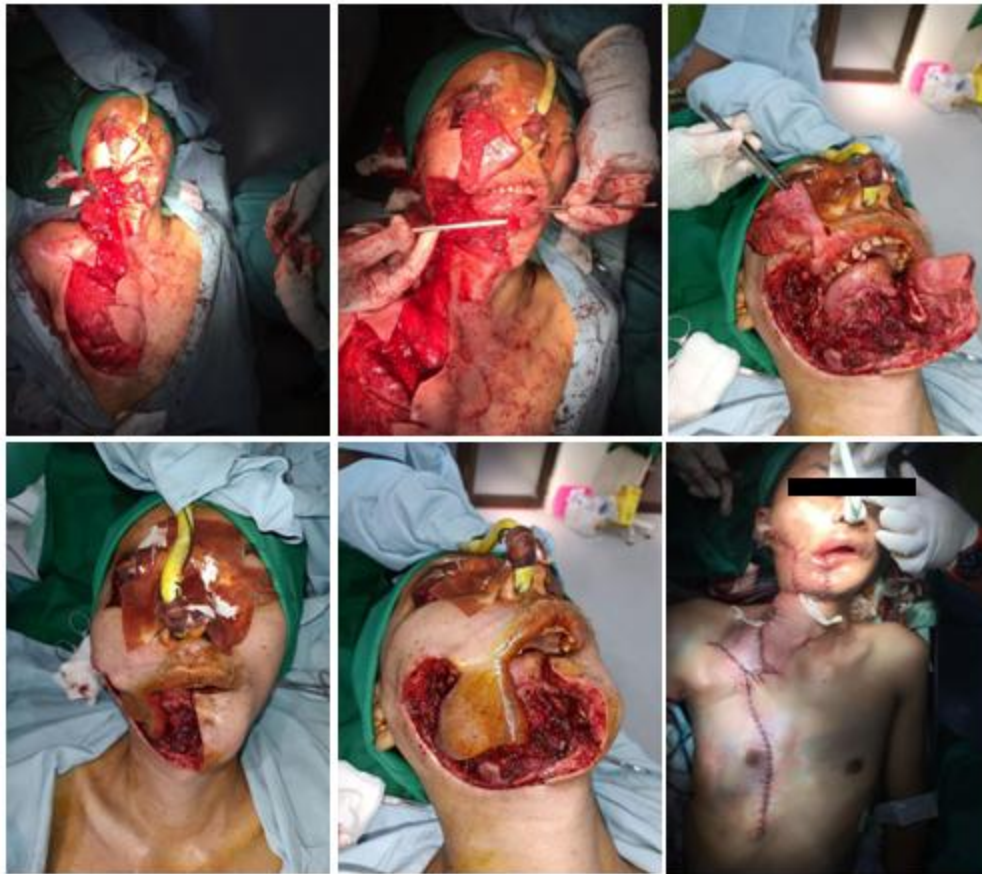

Fig. 5. Picture during Operation

### 3. DISCUSSION

Malignant neoplasms of the oral cavity are the sixth most common malignancy worldwide. Squamous cell carcinoma is considered the most common malignant neoplasm of the oral cavity, accounting for 70% to 90% of the total malignant neoplasms of the oral cavity. The tongue, oropharynx, and floor of the mouth are the most common sites for SCC, and SCC of the gingiva and lips is rarely seen. SCC of the mandibular gingiva is more common than that of the maxillary gingiva [3,7].

Carcinoma of the gingival region often resembles gingival desquamated lesions and other inflammatory gingival lesions. The gingiva is one of the most common sites for chronic inflammation as it is often associated with irritants such as calculus and abundant microbial flora. The attached gingiva is more involved than the free gingiva. Misdiagnosis is often

encountered in the absence of detailed clinical examination and radiographic investigation [8].

The mandibular alveolus is the second most common site for oral carcinoma. Oral cavity squamous cell carcinoma is seen more frequently in men than women because men are often exposed to habits such as smoking and chewing tobacco. Age is another important factor for oral SCC; with age, marked genetic and epigenetic changes occur [3].

SCC of the gingiva is often asymptomatic and the initial symptoms are usually an intraoral mass or swelling, ulceration, pain, ill-fitting dentures, tooth mobility or an extraction wound that does not heal. These tumors often resemble inflammatory lesions affecting the periodontium such as pyogenic granuloma, gingivitis, periodontitis or benign conditions such as xanthoma verruciform. In the early stages, the lesions often resemble advanced periodontitis associated with minimal pain and may cause diagnostic delay [9].

Clinically, the possibility of misdiagnosing can occur because of its varied appearance. Gingival carcinoma in particular tends to present with a benign appearance, and this leads to delayed diagnosis or even misdiagnosis [10]. In this case, a 35-year-old male patient with lesions initially diagnosed with epulis pyogenicum, a condition of reactive hyperplasia of connective tissue in response to local irritation [11], which then increased in size until the lesion was finally diagnosed with SCC. Abraham et al. reported a case of oral SCC which initially resembled a desquamated lesion in the right lower back tooth region [3]. Cheung et al. reported a case of oral SCC in which signs, symptoms, and initial radiographic findings were compatible with an odontogenic infection associated with impacted wisdom teeth. However, after further analysis, the patient's condition proved to be SCC of the oral cavity [2].

There are many imaging techniques that can be used to diagnose cancer in the oral cavity. The most common modalities used for diagnosis and treatment planning include magnetic resonance imaging (MRI), computed tomography (CT) and positron emission tomography (PET). In addition, biopsy samples are often taken [5]. In this patient, a CT scan showed a mass of right submandibular gland accompanied by air and intralesional fluid components with an air-fluid level image that destroyed surrounding structures. Biopsy examination confirmed the mass was a well-differentiated squamous cell carcinoma.

Treatment of squamous cell carcinoma is mainly surgical excision followed by radiation therapy and chemotherapy as additional postoperative treatment modalities. Radical neck dissection is often required in cases of lymph node metastases. Marginal resection is considered a treatment option when the bony defect does not extend beyond the mandibular canal and segmental resection if it extends beyond the mandibular canal [12].

The prognosis of gingival carcinoma depends on the histologic subtype and the clinical extent of the tumor. Well-differentiated types are generally considered to have a good prognosis. However, the most important prognostic indicator is the clinical stage of the disease. If the neoplasm is small and localized, the 5-year cure rate is about 60%–70%, but if cervical node metastases occur, the survival rate drops to about 25% indicating that early diagnosis is essential [4].

#### **4. CONCLUSION**

Squamous cell carcinoma is the most common malignant neoplasm of the oral cavity with various oral presentations. Therefore, a clinician must know the characteristics of the disease. Correct and timely diagnosis is of utmost importance and there is more possibility of

misdiagnosis because the clinical presentation of oral squamous cell carcinoma can mimic gingival inflammatory lesions.

### **CONSENT**

All authors declare that written informed consent was obtained from the patient for the use of his medical information and photographs in publication of this case report. A copy of the written consent is available for review by the Editorial office/Chief Editor/Editorial Board members of this journal.

### **ETHICAL APPROVAL**

All authors hereby declare that all experiments have been examined and approved by the appropriate ethics committee and have therefore been performed in accordance with the ethical standards laid down in the 1964 Declaration of Helsinki

UNDER PEER REVIEW

## REFERENCES

1. Irani S. Pre-Cancerous Lesions in the Oral and Maxillofacial Region: A Literature Review with Special Focus on Etiopathogenesis. *Iran J Pathol.* 2016 Fall;11(4):303-322. PMID: 28855922; PMCID: PMC5563928.
2. Cheung J, Al Afif A, Bullock MJ, Robertson C, Hart R, Goodday R. An Unusual Case of Mandibular Squamous Cell Carcinoma in Intimacy with an Impacted Wisdom Tooth. *Case Rep Surg.* 2019 Apr 11;2019:8360357. doi: 10.1155/2019/8360357. PMID: 31110834; PMCID: PMC6487125.
3. Abraham S, Mallika B, Reshma A, Kassim RM. An Atypical Case of Oral Squamous Cell Carcinoma of Mandibular Alveolus. *Case Rep Dent.* 2019 Nov 13;2019:2521685. doi: 10.1155/2019/2521685. PMID: 31815021; PMCID: PMC6877988.
4. Bharanidharan R, Dineshkumar T, Raghavendhar K, Kumar AR. Squamous cell carcinoma of the gingiva: A diagnostic enigma. *J Oral Maxillofac Pathol.* 2015 May - Aug;19(2):267. doi: 10.4103/0973-029X.164558. PMID: 26604512; PMCID: PMC4611944.
5. Palasz E, Wysocka A, Gasiorska A, Chalimoniuk M, Niewiadomski W, Niewiadomska G. BDNF as a promising therapeutic agent in parkinson's disease. *Int J Mol Sci.* 2020 Feb 10;21(3):1170. doi: 10.3390/ijms21031170. PMID: 32050617; PMCID: PMC7037114.
6. Park HK, Kim TS, Geum DH, Yoon SY, Song JM, Hwang DS, et al. Mandibular intraosseous squamous cell carcinoma lesion associated with odontogenic keratocyst: a case report. *J Korean Assoc Oral Maxillofac Surg.* 2015 Apr;41(2):78-83. doi: 10.5125/jkaoms.2015.41.2.78. Epub 2015 Apr 23. PMID: 25922819; PMCID: PMC4411732.
7. Effiom OA, Adeyemo WL, Omitola OG, Ajayi OF, Emmanuel MM, Gbotolorun OM. Oral Squamous Cell Carcinoma: A Clinicopathologic Review of 233 Cases in Lagos, Nigeria. *J Oral Maxillofac Surg.* 2008 Aug;66(8):1595-9. doi: 10.1016/j.joms.2007.12.025. PMID: 18634945.
8. Ildstad ST, Bigelow ME, Remensnyder JP. Squamous cell carcinoma of the alveolar ridge and palate. A 15-year survey. *Ann Surg.* 1984 Apr;199(4):445-53. doi: 10.1097/0000658-198404000-00012. PMID: 6712321; PMCID: PMC1353364.
9. Gupta R, Debnath N, Nayak PA, Khandelwal V. Gingival squamous cell carcinoma presenting as periodontal lesion in the mandibular posterior region. *BMJ Case Rep.* 2014 Aug 19;2014:1-4. doi: 10.1136/bcr-2013-202511. PMID: 25139914; PMCID: PMC4139557.
10. Alsharif MJ, Jiang WA, He S, Zhao Y, Shan Z, Chen X. Gingival squamous cell carcinoma in young patients: report of a case and review of the literature. *Oral Surgery, Oral Med Oral Pathol Oral Radiol Endodontology.* 2009 May;107(5):696-700. doi: 10.1016/j.tripleo.2008.12.048. Epub 2009 Mar 9. PMID: 19272815.
11. Verma PK, Srivastava R, Baranwal H, Chaturvedi T, Gautam A, Singh A. "Pyogenic Granuloma - Hyperplastic Lesion of the Gingiva: Case Reports." *Open Dent J.* 2012 Oct 12;6(1):153-6. doi: 10.2174/1874210601206010153. Epub 2012 Oct 5. Erratum in: *Open Dent J.* 2012;6:188. PMID: 23091574; PMCID: PMC3474946.
12. Balaji SM. Oral squamous cell carcinoma: Advances in management. *Indian J Dent Res.* 2015 Nov-Dec;26(6):559. doi: 10.4103/0970-9290.176889. PMID: 26888230.